Mid-term Outcome of Total Knee Arthroplasty with Low-restricted Posterior-stabilized Prosthesis in Patients with Severe Fixed Valgus Deformity: A Case-Control Study

Jiani Gou
Sichuan university https://orcid.org/0000-0003-0698-3231

Xiaojun Shi (shixj83@163.com)
Sichuan University

Senhao Liu
Sichuan University

Jing Yang
Sichuan University West China Hospital

Pengde Kang
Sichuan University West China Hospital

Research article

Keywords: total knee arthroplasty, valgus deformity, soft tissue release,

Posted Date: August 11th, 2020

DOI: https://doi.org/10.21203/rs.3.rs-28304/v1

Abstract

Background: The intraoperative soft tissue balance in primary total knee arthroplasty (TKA) is particularly difficult to perform in patients with severe fixed valgus deformity above 20°, which may have an adverse effect on clinical outcomes. The purpose of our study was to determine whether the TKA with low-restricted posterior-stabilized prosthesis in patients with severe fixed valgus deformity could be as successful as in those with no preoperative deformities by comparing perioperative evaluations and mid-term outcomes.

Methods: 45 patients (group A) with severe valgus deformity were treated by TKA with low-restricted posterior- stabilized knee prosthesis; 90 patients (group B) without severe valgus deformity were treated with same surgery and were classified to match the cases in group A. The perioperative evaluations, clinical and radiographic outcomes were compared between the two groups. The postoperative stability was measured by the Kneelax 3 Arthrometer.

Results: The mean follow-up time was 7.64 years. There was no significant difference in age, gender, BMI between the two groups. There was no revision for any reason in either group. The mean operation time and blood transfusion rate were 114 minutes and 46.7% in group A, while 81 minutes and 11.1% in group B, respectively. There were significant differences in both parameters between the two groups ($p<0.001$). The incidence of residual valgus in group A was 20% and the complication rate was 22.2%, while 3.3% and 4.4% in group B, respectively. The incidence of residual valgus and the complication rate was significantly higher in group A than in group B ($p=0.004$). However, there was no statistical difference in Hospital for Special Surgery (HSS) score, range of motion, component fixation, or knee stability at the most recent follow-up.

Conclusion: Although total knee arthroplasty for severe fixed valgus deformity increases the difficulty of operation and the complication rate in perioperative period, low-restricted posterior-stabilized knee prosthesis with proper alignment and soft tissue balance can have satisfactory mid-term outcomes.

Level of evidence: Case-control study, Level III.

Background:

Approximately 10% to 30% of patients requiring total knee arthroplasty (TKA) have a valgus deformity (Krackow et al.1991, Ranawat et al. 2005), which is usually associated with hypoplasia of lateral femoral condyle and contracture of lateral soft tissue. In addition, secondary laxity of the corresponding medial structures occurs in extreme cases (Insall et al. 2001). Severe preoperative valgus deformities have been a challenge for surgeons to perform TKA with a high complication rate, and a variety of surgical techniques have been created to restore limb alignment and to balance soft tissues, such as different protocols of soft tissue release, medial/lateral condyle osteotomy and tibial tubercle osteotomy (Conjeski et al.2018, Tucker et al.2019, Scior et al.2018, Xie et al.2017). Also, in some cases, high-restricted knee

prosthesis may be required to prevent postoperative instability after extensive release, such as TC3 and rotating-hinge implants (Malcolm et al.2016, Stern et al.1991).

Although many studies have discussed the technical and clinical outcomes of valgus deformity, valgus ranges very widely, from 10° to 30°, with only a few cases exceeding 20° (Ranawat et al.2005, Clarke et al.2005, Elkus et al. 2004). There are only two articles that closely focus on patients with varus or valgus deformity ≥ 20°, but they have mixed the varus and valgus deformity (Karachalios et al.1994, Ritter et al.2004). The anatomical characteristics of these two deformities are completely different. Soft tissue balance is more challenging in severe valgus deformity than in varus deformity. Therefore, it is necessary to discuss the severe valgus deformity separately. Furthermore, several studies have shown that low-restricted knee prosthesis are suitable for these special deformities with extensive soft tissue release (Nikolopoulos et al. 2011, Miyasaka et al. 1997, Mou et al. 2018).

The purpose of this case-control study was to determine whether the TKA with low-restricted posterior-stabilized prosthesis in patients with severe fixed valgus deformity could be as successful as in those with no preoperative deformities by comparing the mid-term clinical and radiographic outcomes, operation time, transfusion rate, and complication rates of patients with and without severe fixed valgus deformity.

Methods:

Patients

Prior to the study, we received authorization from the Hospital Institutional Review Board. Data for this study were collected from the orthopedic database of the West China Hospital, Sichuan University. Between June 2007 and April 2012, all patients with a preoperative fixed valgus deformity above 20° were followed up after primary TKA. Patients were excluded if follow-up time was less than 5 years or if a high-restricted knee prosthesis (a TC3/LCCK/rotating-hinge implant) was used. 45 knees from 38 patients who met the inclusion criteria were included in this study, and all valgus deformities were classified as Krackow Type I or II (group A) (Krackow et al.1991). Low-restricted posterior-stabilized prostheses were used in all cases, including PFC-Sigma (Press-fit condylar; DePuy, Warsaw, IN) and Scorpio NRG posterior stabilized prosthesis (Non-Restrictive Geometry, Stryker Orthopedics, Mahwah, NJ).

Once the study group was established, a patient-matched control group (group B) was created by matching each joint in the study group with two joints that did not have obvious varus or valgus deformity. The control group was matched to the study group by age, gender, BMI, diagnosis, prosthesis type and date of operation. More detailed demographics were provided in Table 1.

Surgical technique

The operation was performed by the same group surgeons through a standard midline incision with a medial parapatellar approach. First, initial femoral resection was performed at 5° of valgus using an intramedullary distal femoral cutting guide rod, with the amount resected based on the more normal medial condyle to prevent medial laxity. Second, the proximal tibia was cut 10-12 mm from the uninvolved plateau through the extramedullary alignment system, perpendicular to the mechanical axis of tibia in the frontal plane with 5° posterior inclination. Again, individual femoral external rotating osteotomy was completed with the comprehensive consideration of transepicondylar axis, Whiteside line and tibial plateau plane. Osteophyte resection was performed meticulously, especially the posterior femoral condyle and posterolateral angle of tibial plateau.

After completion of osteotomy and osteophyte resection, the lower extremities were kept extended to identify the most constricted ligamentous structures, which were palpated to determine the ligamentous structures that limited correction to normal alignment. In all cases, the lateral soft tissue structures were contracted and required release. The longitudinally oriented fibers were severed at the joint line with a scalpel under direct vision and tension generated by a laminar flow expander. First, the posterolateral capsule was incised from under the tibial periosteum to completely remove the osteophytes, cut the bone margin, and release the gap. Second, through the iliotibial bundle and the lateral capsule, multiple horizontal needle incisions, called pie-crusting, were created. Third, the gastrocnemius lateralis was dissected in subperiosteum from posterosuperior part of lateral condyle and biceps femoris tendons was released by using pie-crusting technique. The lateral collateral ligament (LCL) and popliteus tendon (PLT) were kept intact during the extensive soft tissue release. In the most severe valgus knee, these steps were sufficient to correct valgus deformity. However, in some severe fixed valgus deformities, the medial and lateral soft tissue tension remained asymmetric, almost all due to medial laxity. We performed a medial condylar sliding osteotomy to reconstruct medial/lateral soft tissue balance, as described in detail by Mou et al. (2018). At each step, the balance of extension and flexion gaps was carefully assessed to determine the structures and extent of ligament release. All cases had lateral release of posterolateral capsule, ITB, lateral gastrocnemius muscle and biceps femoris tendon, and 7 cases were osteotomized with an endocondylar sliding osteotomy.

Once the knee was considered to be well balanced, final preparation of the bone surface and implantation of the trial components was performed. A final assessment of the medial and lateral soft tissue tension was performed once the trial components had been implanted and the optimal polyethylene implant had been selected. Patellar tracking was assessed using the no-thumbs test, and maltracking of the patella were identified in 38 cases, all with patellar trimming, release of the lateral patellar support band, or even patellar replacement until good patellar tracking was achieved. Patellar resurfacing was performed in 13 cases. Finally, the knee was irrigated and the real component was implanted. In all cases, cement was used for fixation of all components, and the capsule was closed in flexion over a drain.

Postoperative rehabilitation

Patients in group A had a slight pressure bandage applied to the wound to keep the joint flexed and avoid peroneal nerve paralysis, while group B required a taut bandage and an extended position. All details of perioperative antibiotic prophylaxis, thromboprophylaxis, and postoperative rehabilitation procedures were identical for all knees, except for 7 knees with a sliding medial condyle osteotomy. The 7 knees were required to perform partial weight-bearing activities using an extension brace and walking frame for at least 12 weeks as part of the postoperative rehabilitation program. Both groups had no restrictions on extension and flexion in a no-load condition.

Clinical and Radiographic Evaluation

Postoperative patients were required to receive annual outpatient follow-up. Clinical function was evaluated using the Hospital for Special Surgery (HSS) score. Range of motion was measured using a goniometer with reliable repeat measurements as previously described (Shi et al., 2013). In addition, standard anterior and posterior lateral radiographs of the knee were obtained at the annual follow-up. Alignment variation was determined from preoperative and postoperative radiographs and recorded as the tibiofemoral angle, which was the angle formed at the knee joint by the longitudinal axis of the femoral shaft and tibial shaft. The patellofemoral section was visible as a patellar subluxation or dislocation. Radiolucent lines and their progression were recorded according to the Knee Society's Radiographic Evaluation System (Ewald et al. 1989). To assess the stability of the knee joint, the Kneelax 3 arthrometer (Netherlands Monitoring Rehabilitation Systems) was used to test postoperative anterior and posterior translation of the tibia at 30° and 90° of knee flexion (Shi et al. 2013). In addition, evaluation for objective instability of the surgical joint was required, and lateral stress testing was performed to determine coronal plane stability at a recent outpatient follow-up, with an extended knee more than 15° in any direction considered to have severe medial or lateral laxity and between 5° and 15° in any direction considered to have moderate laxity (Karachalios et al. 1994).

Statistical Analysis

All data were analyzed with the Statistical Package for the Social Sciences (SPSS) version 17.0 (SPSS, Chicago, USA). All categorical variables were analyzed with the chi-squared test. According to the distribution, Student's t test or Mann-Whitney U test was used to evaluate continuous variables. For all comparisons, $P < 0.05$ was considered statistically significant.

Result:

Demographic details and summary comparisons of preoperative data between the two groups were shown in Table 1. There was no loss of follow-up and no modifications were made for any reason. The mean follow-up time of this study was 7.64 years, and there were no significant differences between the two groups except for the preoperative valgus deformity and HSS score. The mean valgus angle was 26.7° in group A and 5.7° in group B preoperatively ($p<0.001$).The intra-observer and inter-observer

correlation coefficients (ICC) for X-ray measurements, goniometer measurements and Kneelax 3 Arthrometer measurements ranged from 0.85 to 0.98 with good measurement accuracy.

Table 1
Demographic data of the patients in the two groups

	Group A	Group B	P value
Age(years)	62.9	63.1	.907
Gender(female/male)	23/15	46/34	.755
BMI	26.5	26.3	.981
Preoperative valgus angle (degree)	26.7	5.7	<.001
Preoperative HSS	38	42	<.001
Preoperative ROM	88	90	.293
Diagnosis			1
rheumatoid arthritis	22	44	
osteoarthritis	23	46	
Type of implants			1
PFC	25	50	
NRG	20	40	
Mean follow-up time (years)	7.6	7.7	.762

Clinical outcome

The mean operative time and perioperative blood transfusion rate differed between the two groups.The mean operative time was 114 minutes in group A and 81 minutes in group B ($p<0.001$).The perioperative blood transfusion rate was 46.7% (21/45) and 11.1% (10/90) in groups A and B, respectively ($p<0.001$).This indicated that knee valgus is much more difficult to operate on. However, there was no significant difference in HSS score or ROM between the two groups. There were no complaints of knee instability in either group, and no patients were adjudged to have mild to moderate laxity on physical examination at a recent outpatient follow-up visit. In additiom, there was no significant difference in tibial anterior-posterior translation at 30° or 90° of flexion between the two groups. ($p=0.078$ and $p=0.143$, respectively, Table 2).

Table 2
Comparison of clinical outcome between the two groups

	Group A (n=45)	Group B (n=90)	p value
Operation time (minutes)	114	81	<.001
Blood transfusion rate (%)	46.7	11.1	<.001
postoperative tibiofemoral angle (degree)	6.8	5.6	<.001
Residual valgus deformity	9	3	.004
postoperative HSS	91	92	.124
postoperative ROM	104	105	.555
AP translation at 30°flexion (mm)	7.0	6.9	.078
AP translation at 90°flexion (mm)	5.0	5.1	.143
complications	10	4	.004
instability	0	0	
Flap edge necrosis	2	0	
superficial infection	1	2	
subcutaneous hematoma	5	1	
common peroneal nerve plasy	1	0	
develop venous thrombosis	1	1	

Radiographic outcome

The mean postoperative tibiofemoral angle was 6.8 ° and 5.6 ° in group A and group B respectively (p<0.001). Meanwhile, 9 knees in group A had residual valgus deformity, of which 1 knee had tibiofemoral angle of 10 °, 2 knees > 9 °, 3 knees > 8 ° and 3 knees > 7 °. In group B, only three knees had residual valgus deformity with tibiofemoral angle less than 8 °. The incidence of postoperative residual valgus deformity in group A (20.0%) was significantly higher than that in group B (3.3%) (p=0.004). No loosening of radiation parts was found in the two groups. However, the radiolucent line (≤1mm) was detected in two knees in group A and five knees in group B (p=0.890). The radiolucent line was predominantly limited in zones 1, 2, and 4 of the femoral component on the lateral radiography and in zones 1 and 4 of the tibial component on the AP views, but there was no progressive course or osteolysis.

Complication

In group A, there were 10 cases of postoperative complications, including 2 cases of flap edge necrosis, 1 case of superficial infection (wound healed quickly after debridement and suture), 5 cases of moderate subcutaneous hematoma, 1 case of temporary paralysis of the common peroneal nerve due to traction and hematoma compression (the knee fully recovered after 2 months), and 1 case of deep vein thrombosis without further injury. And there were 4 complications in group B, including 1 case of superficial infection, 2 cases of subcutaneous hematoma, and 1 case of asymptomatic deep venous thrombus, and all healed uneventfully. The incidence of postoperative complication in group A (22.2%) was much higher than that in group B (4.4%) ($p=0.004$). There was no poor patellofemoral joint trajectory, dislocation or deep periprosthetic infection in either group.

Discussion:

Soft tissue balance is challenging in TKAs with severe fixed valgus deformity, which raises the concern that whether low-restricted posterior-stabilized knee prosthesis is suitable for these difficult cases. This study found that although the surgical difficulty and complications of severe valgus knees are much higher than those of non-deformed knees, low restriction posterior approach stabilized knee prostheses have satisfactory mid-term outcomes, as postoperative HSS scores, ROM and stability were similar to those of non-deformed knees.

Postoperative instability after TKA is a severe complication, and extensive soft tissue release is a risk factor of instability. The reported incidence of instability was up to 24% in patients with preoperative valgus angulation of ≥ 10° or more due to the extensive lateral ligament release (Miyasaka et al. 1997). However, in this study, although all knees had an extensive lateral release, there was no case of instability. This may be due to the different soft tissue release techniques and evaluation of intraoperative lateral release, especially the integrity of LCL and PLT. However, some authors found that even in severe valgus deformity, the release of the lateral ligament did not result in clinical instability, and joint stability did not deteriorate over time (Whiteside et al. 1999).

In recent decades, many techniques have been invented to correct valgus deformity. However, there is no consensus on the release order of lateral elements. Insall et al. (2001) described a soft tissue balancing technique in which the ITB was divided transversely above the joint line, while the LCL and PLT were detached from the lateral femoral condyle. Whiteside et al. (1999) recommended sequential releases of the ITB, PLT, LCL, and posterolateral capsule. Krackow et al. (1991) recommended standard anteromedial approach with the lateral release of ITB, LCL, PLT, and posterolateral capsule, medial soft tissue advancement was performed in some severe fixed valgus deformity. Polliti et al. (2004) reported a lateral cruciform retinacular release technique to achieve soft-tissue balance and got good-to-excellent results, in which the LCL and PLT usually were not released. Keblish et al. (1991) described the lateral approach to the valgus knee with 53 cases over a two-year follow-up evaluation and found that 94.3% of cases had good/excellent results, and the knee stability was enhanced. Other authors took lateral approach for valgus deformity, and also got the good clinical result, but the local complication was a difficult problem,

such as hematoma, skin necrosis, fracture or postoperative translocation of the tibial tubercle (Nikolopoulos et al.2011, Piedade et al.2008, Fiddian et al.1998).

The residual valgus deformity is a potential risk of successful TKA, with a reported incidence of 10% (Stern et al. 1991). In a retrospective study of primary TKAs in severe valgus deformity, Koskinen et al. (2011) found that residual valgus was the main cause of the early revision. In this study, the incidence of the residual valgus deformity was much higher than that in the control group, but the valgus alignment didn't deteriorate or become unstable during the follow-up period. This finding was confirmed by other authors. Nikolopoulos et al. (2011) compared the clinical outcome of different surgical approaches in fixed valgus knee deformity of larger than 10°, and found that although the occurrence of residual valgus deviation was higher in standard medial parapatellar approach, the postoperative IKSS scores had no significant difference between the groups, and no late-onset instability was displayed. Ritter et al (2004) also reported that the occurrence of the residual valgus deformity was slightly higher in a valgus knee, and there was no impact on postoperative function scores, alignments and revision rate.

In this study, one person was found to have peroneal nerve palsy. Fortunately, it recovered within two months without weakness or paraesthesia. Peroneal nerve palsy has been reported as a rare complication following correction of valgus deformity, while nerve stretching and hematoma compression associated with correction of valgus deformity and lateral retinaculum release may cause ischemic injury (Keblish et al.1991, Cree et al. 1998). Studies demonstrated that valgus contracture more than 20° was a significant risk factor for common peroneal nerve palsy (Asp et al.1990). It is important to note that posterolateral release can directly cause nerve damage. Mihalko et al. (2000) found that the common peroneal nerve was only 6 to 12 mm away from the joint surface of the posterolateral corner in full extension, so the lateral release with the 'pie crust' technique should be performed meticulously. In order to prevent nerve injury, some authors performed prophylactic nerve exploration and release at the time of arthroplasty for the valgus deformity (Cree et al.1998).

This study has several limitations. First, this is a retrospective case-control study, and the inherent selection bias may have adversely affected the final conclusions. Prospective randomized controlled trials may be needed in the future. Second, the sample size in the study group is small. Nevertheless, it is argued that this was due to the decision to focus on patients with severe fixed valgus deformities, which comprise less than 2% of osteoarthritis. Third, we subjectively excluded patients using high-restricted knee prosthesis. This is because the purpose of this study was to explore the clinical effect of a common low-restricted knee prosthesis in these difficult cases with extensive soft-tissue releasing technique.

Conclusion:

Total knee arthroplasty with low-restricted posterior-stabilized prosthesis could have a satisfied mid-term outcome in severe fixed valgus knees as well as those without obvious deformities. Slight residual valgus deformity didn't affect knee function and mid-term revision rate, but the long-term outcome should be monitored. In addition, the perioperative complications are high and should be managed cautiously.

List Of Abbreviations

TKA
Total Knee Arthroplasty
BMI
Body Mass Index
HSS score
Hospital for Special Surgery scores
ITB
Iliotibial Band
LCL
Lateral Collateral Ligament
PLT
Popliteus Tendon
ICC
Intraclass Correlation Coefficient
ROM
Range of Motion
IKSS scores
International Knee Society Score

Declarations

Ethics approval and consent to participate

All experiments were approved by the Institutional Review Board of West China Hospital, Sichuan University and carried out according to the corresponding principles and ethical standards. Consent to participate is not applicable.

Consent for publication

Not applicable.

Availability of data and materials

The datasets used and/or analysed during the current study are available from the corresponding author on reasonable request.

Competing interests

No benefits in any form have been or will be received from any commercial party related either directly or indirectly to the subject of this manuscript.

Funding

This work as supported by Health Industry Special Scientific Research Projects Ministry of Health, China (No. 201302007) which helped to get access to scientific literature, establish the program and finish this literature.

Authors' contributions

Gou and Liu contribute equally to this work. Gou and Shi planned the study. Kang, Yang and Shi were responsible for the surgical operation, Gou and Liu completed the data collection, wrote the first draft of the paper, and revise the paper. All authors read and approved the final manuscript.

Acknowledgements

Not applicable.

References:

1. Asp PL, Rand JA. Peroneal nerve palsy after total knee arthroplasty. Clin Orthop Relat Res. 1990;261:233–7.
2. Clarke HD, Fuchs R, Scuderi GR, Scott WN, Insall JN. Clinical results in valgus total knee arthroplasty with the “Pie Crust” technique of lateral soft tissue releases. J Arthroplasty. 2005;20(8):1010–4.
3. Conjeski JM, Scuderi GR. Lateral femoral epicondylar osteotomy for correction of fixed valgus deformity in total knee arthroplasty: a technical note. J Arthroplasty. 2018;33(2):386–90.
4. Cree AK, Coolican MRJ, Tonkin MA. Prevention of common peroneal nerve palsy after surgery for valgus deformity about the knee. Knee. 1998;5:261–5.
5. Elkus M, Ranawat CS, Rasquinha VJ, Babhulkar S, Rossi R, Ranawat AS. Total knee arthroplasty for severe valgus deformity: five to fourteen-year follow-up. J Bone Joint Surg Am. 2004;86-A(12):2671–6.
6. Ewald FC. The knee society total knee arthroplasty roentgenographic evaluation and scoring system. Clin Orthop Relat Res. 1989;248:9–12.
7. Fiddian NJ, Blakeway C, Kumar A. Replacement arthroplasty of the valgus knee. A modified lateral capsular approach with repositioning of vastus lateralis. J Bone Joint Surg Br. 1998;80:859–61.
8. Insall JN, Easley ME. Surgical techniques and instrumentation in total knee arthroplasty. In: Insall JN, Scott WN, editors. Surgery of the knee. Philadelphia: Churchill Livingstone; 2001. p. 1553.

9. Karachalios T, Sarangi PP, Newman JH. Severe varus and valgus deformities treated by total knee arthroplasty. J Bone Joint Surg Br. 1994;76:938–42.
10. Keblish PA. The lateral approach to the valgus knee: Surgical technique and analysis of 53 cases with over two-year follow-up evaluation. Clin Orthop Relat Res. 1991;271:52–62.
11. Koskinen E, Remes V, Paavolainen P, Harilainen A, Sandelin J, Tallroth K, Kettunen J, Ylinen P. Results of total knee replacement with a cruciate-retaining model for severe valgus deformity—A study of 48 patients followed for an average of 9 years. Knee. 2011;18(3):145–50.
12. Krackow KA, Mihalko WM. Flexion-extension joint gap changes after lateral structure release for valgus deformity correction in total knee arthroplasty: a cadaveric study. J Arthroplasty. 1999;14(8):994–1004.
13. Krackow KA, Jones MM, Teeny SM, Hungerford DS. Primary total knee arthroplasty in patients with fixed valgus deformity. Clin Orthop Relat Res. 1991;273:9–18.
14. Malcolm TL, Bederman SS, Schwarzkopf R. Outcomes of varus valgus constrained versus rotating-hinge implants in total knee arthroplasty. Orthopedics. 2016;39(1):e140-8.
15. Matsueda M, Gengerke TR, Murphy M, Lew WD, Gustilo RB. Soft tissue release in total knee arthroplasty. Cadaver study using knees without deformities. Clin Orthop Relat Res. 1999;366:264–73.
16. Mihalko WM, Krackow KA. Anatomic and biomechanical aspects of pie crusting posterolateral structures for valgus deformity correction in total knee arthroplasty: a cadaveric study. J Arthroplasty. 2000;15(3):347–53.
17. Miyasaka KC, Ranawat CS, Mullaji A. 10- to 20-Year followup of total knee arthroplasty for valgus deformities. Clin Orthop Relat Res. 1997;345:29–37.
18. Mou P, Zeng Y, Yang J, Zhong H, Yin SJ, Li RB. The effectiveness of medial femoral epicondyle up-sliding osteotomy to correct severe valgus deformity in primary total knee arthroplasty. J Arthroplasty. 2018;33(9):2868–74.
19. Nikolopoulos DD, Polyzois I, Apostolopoulos AP, Rossas C, Moutsios-Rentzos A, Michos IV. Total knee arthroplasty in severe valgus knee deformity: comparison of a standard medial parapatellar approach combined with tibial tubercle osteotomy. Knee Surg Sports Traumatol Arthrosc. 2011;19(11):1834–42.
20. Peters CL, Mohr RA, Bachus KN. Primary total knee arthroplasty in the valgus knee: creating a balanced soft tissue envelope. J Arthroplasty. 2001;16(6):721–9.
21. Piedade SR, Pinaroli A, Servien E, Neyret P. Tibial tubercle osteotomy in primary total knee arthroplasty: A safe procedure or not? Knee. 2008;15(6):439–46.
22. Politi J, Scott R. Balancing severe valgus deformity in total knee arthroplasty using a lateral cruciform retinacular release. J Arthroplasty. 2004;19(5):553–7.
23. Ranawat AS, Ranawat CS, Elkus M, Rasquinha VJ, Rossi R, Babhulkar S. Total knee arthroplasty for severe valgus deformity: surgical technique. J Bone Joint Surg Am. 2005;87(Suppl 1(Pt 2):271–84.

24. Ritter MA, Faris GW, Faris PM, Davis KE. Total knee arthroplasty in patients with angular varus or valgus deformities of > or = 20 degrees. J Arthroplasty. 2004;19(7):862–6.
25. Scior W, Hilber F, Hofstetter M, Graichen H. Short-term and mid-term results of lateral condyle sliding osteotomy in the treatment of valgus total knee arthroplasty: a successful therapy option in grade 2 valgus total knee arthroplasty. Knee. 2018;25(3):466–72.
26. Shi X, Shen B, Kang P, Zhou Z, Pei F. The effect of posterior tibial slope on knee flexion in posterior-stabilized total knee arthroplasty. Knee Surg Sports Traumatol Arthrosc. 2013;21(12):2696–703.
27. Stern SH, Moeckel BH, Insall JN. Total knee arthroplasty in valgus knees. Clin Orthop Relat Res. 1991;273:5–8.
28. Tucker A, O'Brien S, Doran E, Gallagher N, Beverland DE. Total knee arthroplasty in severe valgus deformity using a modified technique-a 10-year follow-up study. J Arthroplasty. 2019;34(1):40–6.
29. Whiteside LA. Selective ligament release in total knee arthroplasty of the knee in valgus. Clin Orthop Relat Res. 1999;367:130–40.
30. Xie K, Lyons ST. Soft tissue releases in total knee arthroplasty for valgus deformities. J Arthroplasty. 2017;32(6):1814–8.

Figures

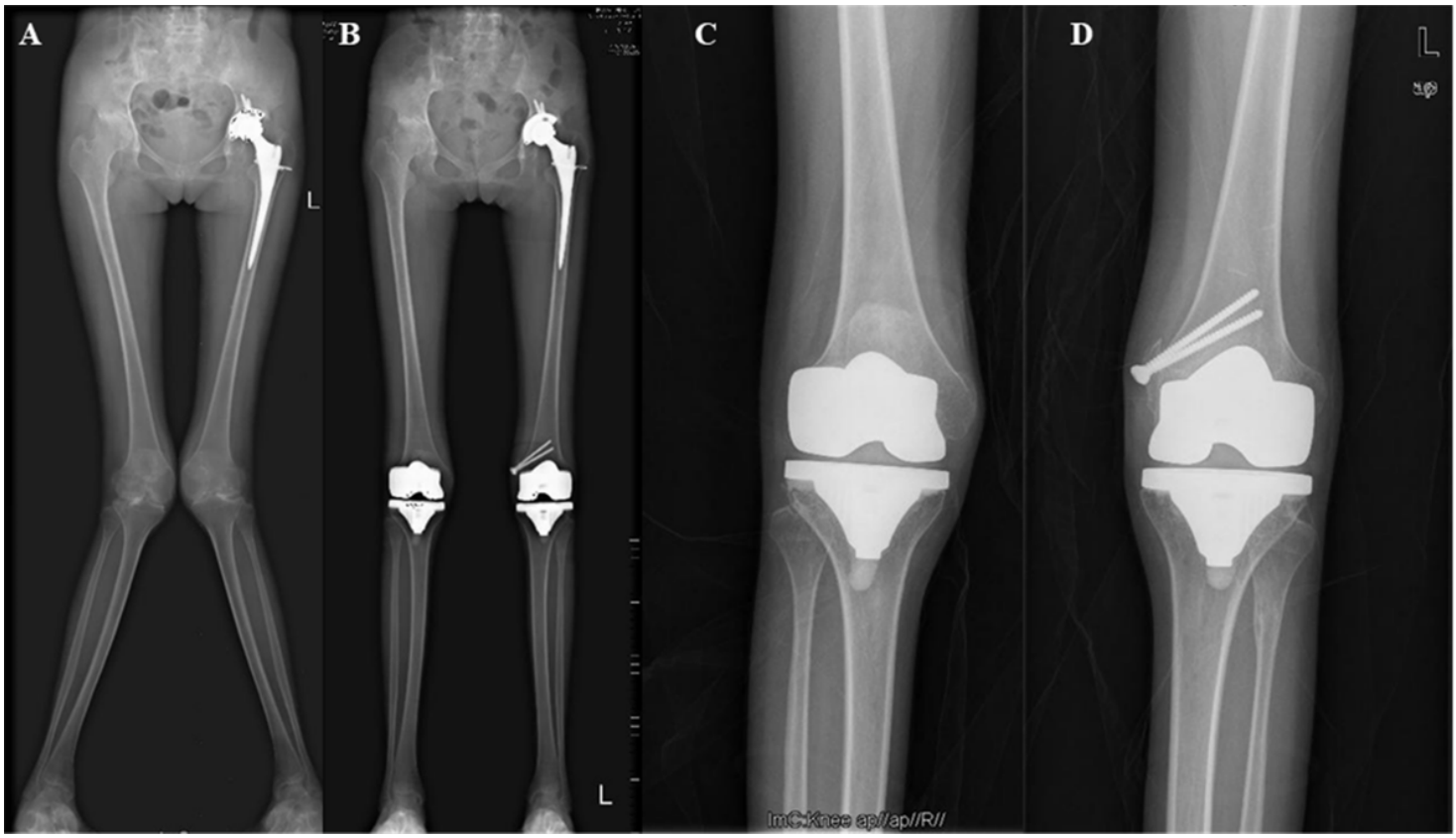

Figure 1

Radiograph of a 38-year-old female with diagnosis of rheumatoid arthritis. Preoperative anteroposterior full-length standing radiograph show severe valgus deformity with tibiofemoral angle 30° in both knee joints (A). Full-length standing radiograph at 6 years after surgery with low-restricted posterior-stabilized knee prosthesis demonstrate excellent restoration to neutral alignment (B). Anteroposterior radiograph of right (C) and left (D) knee at postoperative 6 years show good component fixation and bony healing of medial condyle sliding osteotomy (D).