Research Square

Preprints are preliminary reports that have not undergone peer review. They should not be considered conclusive, used to inform clinical practice, or referenced by the media as validated information.

A Novel Method for Internal Fixation of Fifth Metatarsal Tuberosity Avulsion Fractures

Taicheng Zhan
Tongji University School of Medicine
Kunpeng Zhu
Tongji University School of Medicine
Jianping Hu
Tongji University School of Medicine
Tao Cai
Tongji University School of Medicine
Lei Zhang (kobe1234566@sina.com)
Tongji University School of Medicine https://orcid.org/0000-0002-7903-8970
Chunlin Zhang (shzhangchunlin123@163.com)
Tongji University School of Medicine

Research article

Keywords: fifth metatarsal, tuberosity avulsion fractures, suture anchor, headless cannulated scre

Posted Date: May 18th, 2020

DOI: https://doi.org/10.21203/rs.3.rs-28309/v1

License: This work is licensed under a Creative Commons Attribution 4.0 International License.
Read Full License

Abstract

Background:

The purpose of this study is to introduce a novel technique of fixation with a suture anchor combined with a headless cannulated screw.

Patients and Methods:

Ninepatients with fifth metatarsal tuberosity avulsion fractures were recruited and surgically treated witha suture anchor combined with headless cannulated screw fixation. Those patients were seen for follow-up visits monthly. Clinical and radiological outcomes were evaluated after surgery, at 4, 6 and 8 weeks, and monthly thereafter. The functional outcome was graded using the American Orthopedic Foot and Ankle Society (AOFAS) midfoot scoring system at the final follow-up visit.

Results:

The mean interval to bone union observed radiologically was 5.6 weeks (range 4–8 weeks). No case of delayed union/nonunion or refracture was detected. No screw migration or implant breakage occurred. The mean interval to daily living activities was 8.2 (range 6 to 12) weeks after surgery.The mean AOFASscore improved from 30.8 (range 10 to 45) points preoperatively to 92.3 (range 87 to 98) points at the final follow-up visit.

Conclusions:

A suture anchor combined with a headless cannulated screw is a reliable technique with good outcomes and can potentially allow for early bone union.

Introduction

The fifth metatarsal basal fracture, first described by Sir Robert Jones,[1] is the most common of the metatarsal fractures and is classified into 3 zones by Lawrence and Botte.[2] Zone I is a proximal avulsion fracture. Zone II is a fracture between the metaphysic and diaphysis, including articulation with the fourth metatarsal. Zone III is a proximal diaphyseal fracture. Zones I and II are fractures due to acute injury, whereas Zone III fractures are usually pathologic stress fractures. Fifth metatarsal tuberosity avulsion fractures (Zone I) were the most familiar fractures, accounting for approximately 93% of all fifth metatarsal fractures.[2]

Although undisplaced fifth metatarsal tuberosity avulsion fractures (Zone I) usually respond well to conservative treatment, such as a walking cast,[3] investigators have shown that undisplaced Zone I fractures can require ≤ 12 weeks for bone union.[4] In addition, for acute fractures in athletic or active patients and fractures with displacements of > 2 mm, delayed union, painful nonunion and refracture have been reported.[5–8]

Operative fixation is recommended for displaced fifth metatarsal tuberosity avulsion fractures and can decrease the delayed union/nonunion rates associated with these fractures.[9] However, several studies have reported failure after fixation with screws. Wright[10] found that failure seemed to be correlated with the fracture dimensions, as an increased length and width raised the failure rate (a combination of refracture and nonunion) up to 5% in athletic patients. Granata[11] reported a 7.3% failure rate after surgical treatment, mainly due to refractures. Therefore, other methods for fixation have been developed to achieve better stability and a lower rate of complications. Kirschner wire fixation combined with a tension band[12] or ulna hook plate[13] has been used with similar outcomes. There have been many studies regarding fifth metatarsal basal fracture; however the most appropriate surgical treatment remains controversial.

This report describes and discusses a novel method for internal fixation of fifth metatarsal tuberosity avulsion fractures via a combination of a suture anchor combined with a headless cannulated screw.

Patients and Methods

Nine patients who sustained displaced fifth metatarsal tuberosity avulsion fractures were recruited and surgically treated with a suture anchor combined with a headless cannulated screw fixation form January 2017 to September 2018.

The study protocol and consent forms were approved by our institutional review board. All patients provided written informed consent for the present study and were informed that the necessary data and photographs would be submitted for publication without patient identification.

Those patients were seen for follow-up visits every 4 weeks, and clinical and radiological outcomes were evaluated. They were followed up for a mean of 11.8 (range 8 to 16) months. Of the 9 patients, 6 were male and 3 were female. Their mean age was 37.9 (range 18 to 55) years. All patients had sustained displaced fifth metatarsal tuberosity avulsion fractures. Radiographs were obtained after surgery, at 4, 6 and 8 weeks, and monthly thereafter. The functional outcome was graded using the American Orthopedic Foot and Ankle Society (AOFAS) midfoot scoring system preoperatively and at the final follow-up visit.

Surgical technique

The operation was performed in the supine position after anesthesia induction. Intraoperative fluoroscopic imaging was used to guarantee appropriate drilling position, depth and guide wire placement. After sterile draping and prepping of the surgical site, a 3 cm long longitudinal incision was implemented on the lateral border of the fifth metatarsal bone, parallel to the plantar surface. The entry point for the anchor was created at the distal metatarsal shaft, 1 cm past the fracture site and perpendicular to the metatarsal shaft. Next, a suture anchor (2.8 mm, Smith & Nephew, Andover, USA) was inserted into the fifth metatarsal fracture shaft. Once the suture anchor was completely inserted, the sutures were released from the anchor. The two groups of suture threads were then sewn into the soft tissue sleeve of the proximal fragments and the termination of the peroneus brevis tendon. Reduction

was verified under direct vision before knotting the first group of sutures (Fig. 1). A guide wire was inserted perpendicular to the fracture line at the tip of the fifth metatarsal basal part. A second guide needle was implanted to prevent rotation of the fracture fragment. The placement of the guide wire and the reduction of the fracture were confirmed under fluoroscopic imaging. Then, through the first guide wire, a cannulated drill was advanced down the medullary canal and passed through the fracture site. A headless cannulated screw (2.4 mm × 14 mm, Osteomed, Addison, USA) was then placed into the intramedullary canal and advanced until compression was obtained. The placement of the headless cannulated screw and the reduction of fracture were confirmed again under fluoroscopic imaging. Then, the other suture was knotted to strengthen the fixation. The incision was closed using sutures after irrigating the wounds.

The postoperative protocol consisted of non-weight-bearing restrictions and crutches for 4 weeks. The radiographs were examined for evidence of fracture healing, implant failure or migration, and fragmentation of the distal fifth metatarsal. Radiographic fracture healing was defined as any evidence of normalization of the medullary or obliteration of the fracture lines. Gradual weightbearing was allowed until the radiographs revealed evidence of union. All patients were allowed to return to full activity when they were clinically asymptomatic and had demonstrated radiographic union.

Results

The present study has demonstrated that good clinical and radiological outcomes can be achieved for displaced fifth metatarsal tuberosity avulsion fractures treated with a suture anchor combined with headless cannulated screw (Fig. 2).

A total of 9 patients, 3 females and 6 males, were treated from January 2017 to September 2018. The average age was 37.9 years at the time of injury (range 18 to 55). Eight patients sustained twisting injuries during sport activity, and 1 patient sustained a crushing injury from a wheel rolling over the foot. All patients had sustained displaced fifth metatarsal tuberosity avulsion fractures.

The mean follow-up period was 11.8 (range 8 to 16) months. The average time to fracture healing observed radiologically was 5.6 weeks (range 4–8 weeks). No case of nonunion or repeat fracture was detected. Deep infection or paresthesia was not found. No fixation loss, such as screw migration or implant breakage, occurred. The mean interval to daily living activities was 8.2 (range 6 to 12) weeks after surgery. The mean AOFAS score improved from 30.8 (range 10 to 45) points preoperatively to 92.3 (range 87 to 98) points at the final follow-up visit (Table 1).

Table 1
Details of Patients With fifth metatarsal tuberosity avulsion fractures Treated With a suture anchor combined with a headless cannulated screw

case	Gender	Age	Cause of trauma	Follow-up time,mo	Time to Healing on Radiograph, wk	Return to activities of daily living,wk	AOFAS before surgery	AOFAS at the final follow-up visit
1	M	18	twisting injurie	8	4	6	45	98
2	F	38	twisting injurie	10	6	8	25	91
3	M	31	twisting injurie	12	6	8	33	95
4	M	35	twisting injurie	11	4	8	38	92
5	M	38	twisting injurie	10	6	8	31	90
6	F	55	crushing injury	12	8	12	10	91
7	M	43	twisting injurie	13	6	8	32	95
8	F	47	twisting injurie	16	6	8	29	87
9	M	36	twisting injurie	14	4	8	34	92
Mean	/	37.9	/	11.8	5.6	8.2	30.8	92.3

Discussion

There have been many studies regarding fifth metatarsal basal fracture; however, the most appropriate surgical treatment remains to be controversial. The mechanism of fracture has been described as a large directed force applied to the forefoot while the ankle is plantar flexed.[2] Because the fifth metatarsal has the widest motive range compared to other metatarsals, while the base is tightly fixed by ligamentous connections, fifth metatarsal tuberosity avulsion fractures will occasionally result in displacement and carry a risk of delayed union/nonunion.[14] The different arterial supply to the proximal diaphysis and the base of the fifth metatarsal create a potential relative avascularity region, resulting in poor prognosis for fracture healing.[15]

Initially, most fifth metatarsal tuberosity avulsion fractures of the fifth metatarsal were treated with immobilization and non-weight-bearing approaches, such as walking cast or bandaging.[4] However,

conservative treatments exhibit a high rate of delayed union/nonunion. It has been reported that 8 of 44 patients managed nonsurgically required subsequent surgical intervention due to delayed union, while no delayed union occurred in the surgical group.[16] It has also been reported that the mean time to return to activity was 7.9 weeks in the surgical group compared to 15 weeks in the non-surgical group.[3]

Various methods for surgical management have been reported, including tension band wiring[12, 17, 18]; ulna hook plates,[19] crossed Kirschner wires,[20] intramedullary screw fixation[5] and suture anchor.[21] Tension band wiring fixation has become a well-documented surgical management for the treatment of patients with sustained acute fifth metatarsal fractures.[18] This technique used 1.6/1.8 mm intramedullary Kirschner wires implanted longitudinally in the metatarsal bone from the tuberosity. One of the Kirschner wires engaged the medial cortex 2 to 3 cm distal to the fracture. A optimal tension band wire (0.6 to 1 mm in diameter) was implanted again 1–2 cm distal to the fracture and around the K-wires in figure-8 format.[17] However, hardware fatigue was the main problem of fixation with tension band wiring, especially in athletic patients. Fixation needed to be removed due to this problem. Pain and paresthesia over the insertion point were also reported.[12] A case of stress fracture of the fifth metatarsal base caused by tension band wiring was reported. They described a 26-years-old athlete who sustained a stress fracture after surgery while the initial fracture had already healed, they believed that the Kirschner wires ware a stress contributor and that they should be removed within 6 to 12 months after bone union.[22] Direct compression at the fracture site was limited when treated with tension band wiring.

In addition, intramedullary screws have long been used to treat fifth metatarsal base fractures. The most frequently used screw was 4.0/4.5 mm screw to provide fracture site compression. Biomechanical studies have been carried out to indicate that there is no significant difference between 4.0 mm and 4.5 mm screws.[5] An isolated intramedullary screw had poor resistance to dorsal flexion forces; it resulted in a high risk of implant breakage or micromotion of the fracture site, and caused pain due to stimulation of the surrounding soft tissues.[23]

To improve the compression at the fracture site, researchers are inclined to use a thicker screw, even though it can disintegrate the fracture fragment. We used 2.4 mm diameter screws to effectively prevent iatrogenic fracture fragmentation. The suture sewn into the peroneus brevis tendon can act as a tension band, a substitute for reduction that can effectively reduce the risk of iatrogenic fracture fragmentation and enhance the resistance to dorsal flexion forces. The compression at the fracture site provided by the isolated tension band or screw is imitated. The lateral traction engendered by the tension band can be transmitted to the fracture site by the screw to strengthen the compression. Enhanced compression and good reduction can shorten the fracture healing time. The mean interval to union of fractures has been reported to be 5.3 to 7.8 weeks[24, 25]; our result of 5.6 weeks is similar to that in the first study.[24] However, the differences were not statistically significant.

The creation of a suture anchor combined with a headless cannulated screw allows minimal insalivation to soft tissue, which is useful for preserving the blood supply to fractures that have already been proved hypovascularized. The procedure is more likely to reduce the risk of delayed union/nonunion by

protecting and preserving the blood supply compared to other more aggressive interventions. To the best of our knowledge, the present study is the first to report displaced fifth metatarsal tuberosity avulsion fractures treated successfully with a suture anchor combined with a headless cannulated screw. The concept of this technique is to combine the reduction of the suture and the direct compression of the screw. This new approach has not yet been widely used clinically; however, it has been shown to be effective and reliable. Biomechanically tested and contrastive studies need to be carried out to prove its superiority compared to other techniques.

The limitation of the present study is the small sample size and lack of contrast. We intend to launch a contrastive study to define the difference between this new technique and other techniques in the future. Another limitation of this technique is the higher expense of using a suture anchor combined with a headless cannulated screw.

It is highly recommended that this technique should be used in athletic and active patients. This is because of their requirements of better function and higher biomechanical stress on the fracture site, and an isolated intramedullary screw will raise the possibility of failure of fixation. Therefore, it is credible to use a combination of a suture anchor and headless cannulated screw to achieve a more stable coalescence. Fixation with a suture anchor combined with a headless cannulated screw is an effective surgical management for acute displaced fifth metatarsal tuberosity avulsion fractures. Furthermore, delayed union/nonunion of fifth metatarsal fractures may be another indication due to its advanced biological requirement.

Conclusions

Displaced fifth metatarsal tuberosity avulsion fractures are common. The most appropriate surgical treatment remains controversial. We have illustrated a novel method of internal fixation of displaced fifth metatarsal fractures with a combination of a suture anchor and headless a cannulated screw. We believe it is a reliable technique with good outcomes and can potentially allow for early bone union.

Declarations

Funding:

This project was supported by Grant from the National Natural Science Foundation of China (No. 81572630, No. 81872174), Shanghai science and technology talents program (No. 19XD1402900) and Fundamental Research Funds for the Central Universities (No. 22120180385).

Conflicts of interest:

The authors have no personal financial or institutional interest in the materials or methods described in this paper.

Ethical Approval:

The study received ethical approval from the Institutional Review Board of Shanghai Tenth People's Hospital affiliated to Tongji University.

Consent to participate:

Written informed consent was obtained from all patients before surgical treatment including the fact that the data may be included in future publications.

Consent for publication:

Written informed consent for publication was obtained from all participants.

Availability of data and material:

The data used to support the findings of this study and the datasets used and/or analyzed during the present study are available from the corresponding author upon request.

Authors' contributions:

Lei Zhang and Chunlin Zhang contributed the central idea; Taicheng Zhan analysed most of the data, and wrote the initial draft of the paper. The remaining authors contributed to carrying out additional analyses and finalizing this paper.

References

1. Jones R. I. Fracture of the Base of the Fifth Metatarsal Bone by Indirect Violence. Annals of surgery. 1902;35(6):697–700.692.
2. Lawrence SJ, Botte MJ. Jones' fractures and related fractures of the proximal fifth metatarsal. Foot ankle. 1993;14(6):358–65.
3. Mologne TS, Lundeen JM, Clapper MF, O'Brien TJ. Early screw fixation versus casting in the treatment of acute Jones fractures. Am J Sports Med. 2005;33(7):970–5.
4. Egol K, Walsh M, Rosenblatt K, Capla E, Koval KJ. Avulsion fractures of the fifth metatarsal base: a prospective outcome study. Foot Ankle Int. 2007;28(5):581–3.
5. Raikin SM, Slenker N, Ratigan B. The association of a varus hindfoot and fracture of the fifth metatarsal metaphyseal-diaphyseal junction: the Jones fracture. Am J Sports Med. 2008;36(7):1367–72.

6. Zwitser EW, Breederveld RS. Fractures of the fifth metatarsal; diagnosis and treatment. Injury. 2010;41(6):555–62.
7. Clapper MF, O'Brien TJ, Lyons PM. **Fractures of the fifth metatarsal. Analysis of a fracture registry**. *Clinical orthopaedics and related research* 1995(315):238–241.
8. Husain ZS, DeFronzo DJ. Relative stability of tension band versus two-cortex screw fixation for treating fifth metatarsal base avulsion fractures. The Journal of foot ankle surgery: official publication of the American College of Foot Ankle Surgeons. 2000;39(2):89–95.
9. Roche AJ, Calder JD. Treatment and return to sport following a Jones fracture of the fifth metatarsal: a systematic review. Knee surgery sports traumatology arthroscopy: official journal of the ESSKA. 2013;21(6):1307–15.
10. Wright RW, Fischer DA, Shively RA, Heidt RS Jr, Nuber GW. Refracture of proximal fifth metatarsal (Jones) fracture after intramedullary screw fixation in athletes. Am J Sports Med. 2000;28(5):732–6.
11. Granata JD, Berlet GC, Philbin TM, Jones G, Kaeding CC, Peterson KS. Failed Surgical Management of Acute Proximal Fifth Metatarsal (Jones) Fractures: A Retrospective Case Series and Literature Review. Foot Ankle Spec. 2015;8(6):454–9.
12. Lee KT, Park YU, Young KW, Kim JS, Kim JB: **Surgical results of 5th metatarsal stress fracture using modified tension band wiring**. *Knee surgery, sports traumatology, arthroscopy: official journal of the ESSKA* 2011, **19**(5):853–857.
13. Ismat A, Rupp M, Knapp G, Heiss C, Szalay G, Biehl C. Treatment of proximal fifth metatarsal fractures with an ulna hook plate. Foot. 2019;42:101653–3.
14. Rammelt S, Heineck J, Zwipp H. Metatarsal fractures. Injury. 2004;35(2 SUPPL.):77–86.
15. Smith JW, Arnoczky SP, Hersh A. The intraosseous blood supply of the fifth metatarsal: implications for proximal fracture healing. Foot ankle. 1992;13(3):143–52.
16. Josefsson PO, Karlsson M, Redlund-Johnell I, Wendeberg B. Closed treatment of Jones fracture. Good results in 40 cases after 11–26 years. Acta Orthop Scand. 1994;65(5):545–7.
17. Sarimo J, Rantanen J, Orava S, Alanen J. Tension-band wiring for fractures of the fifth metatarsal located in the junction of the proximal metaphysis and diaphysis. Am J Sports Med. 2006;34(3):476–80.
18. Nolte P, Anderson R, Strauss E, Wang Z, Hu L, Xu Z, Steen RG. Heal rate of metatarsal fractures: A propensity-matching study of patients treated with low-intensity pulsed ultrasound (LIPUS) vs. surgical and other treatments. Injury. 2016;47(11):2584–90.
19. Lee SK, Park JS, Choy WS. Locking compression plate distal ulna hook plate as alternative fixation for fifth metatarsal base fracture. The Journal of foot ankle surgery: official publication of the American College of Foot Ankle Surgeons. 2014;53(5):522–8.
20. Thomas JL, Davis BC. Three-wire fixation technique for displaced fifth metatarsal base fractures. The Journal of foot ankle surgery: official publication of the American College of Foot Ankle Surgeons. 2011;50(6):776–9.

21. Hong CC, Nag K, Yeow H, Lin AZ, Tan KJ. Suture Anchor Fixation for Fifth Metatarsal Tuberosity Avulsion Fractures: A Case Series and Review of Literature. The Journal of foot ankle surgery: official publication of the American College of Foot Ankle Surgeons. 2018;57(5):1030–3.
22. Mofidi A, Hamer P, Thomas RH, Hemmadi SS. Stress fracture of the fifth metatarsal base caused by tension band wiring: an isolated case report. Foot Ankle Spec. 2009;2(2):79–82.
23. Tsukada S, Ikeda H, Seki Y, Shimaya M, Hoshino A, Niga S. Intramedullary screw fixation with bone autografting to treat proximal fifth metatarsal metaphyseal-diaphyseal fracture in athletes: a case series. Sports Med Arthrosc Rehabil Ther Technol. 2012;4(1):25–5.
24. Mahajan V, Chung HW, Suh JS. Fractures of the proximal fifth metatarsal: percutaneous bicortical fixation. Clinics in orthopedic surgery. 2011;3(2):140–6.
25. Kim J-B, Song I-S, Park B-S, Ahn C-H, Kim C-U. Comparison of the Outcomes Between Headless Cannulated Screw Fixation and Fixation Using a Locking Compression Distal Ulna Hook Plate in Fracture of Fifth Metatarsal Base. The Journal of foot ankle surgery: official publication of the American College of Foot Ankle Surgeons. 2017;56(4):713–7.

Figures

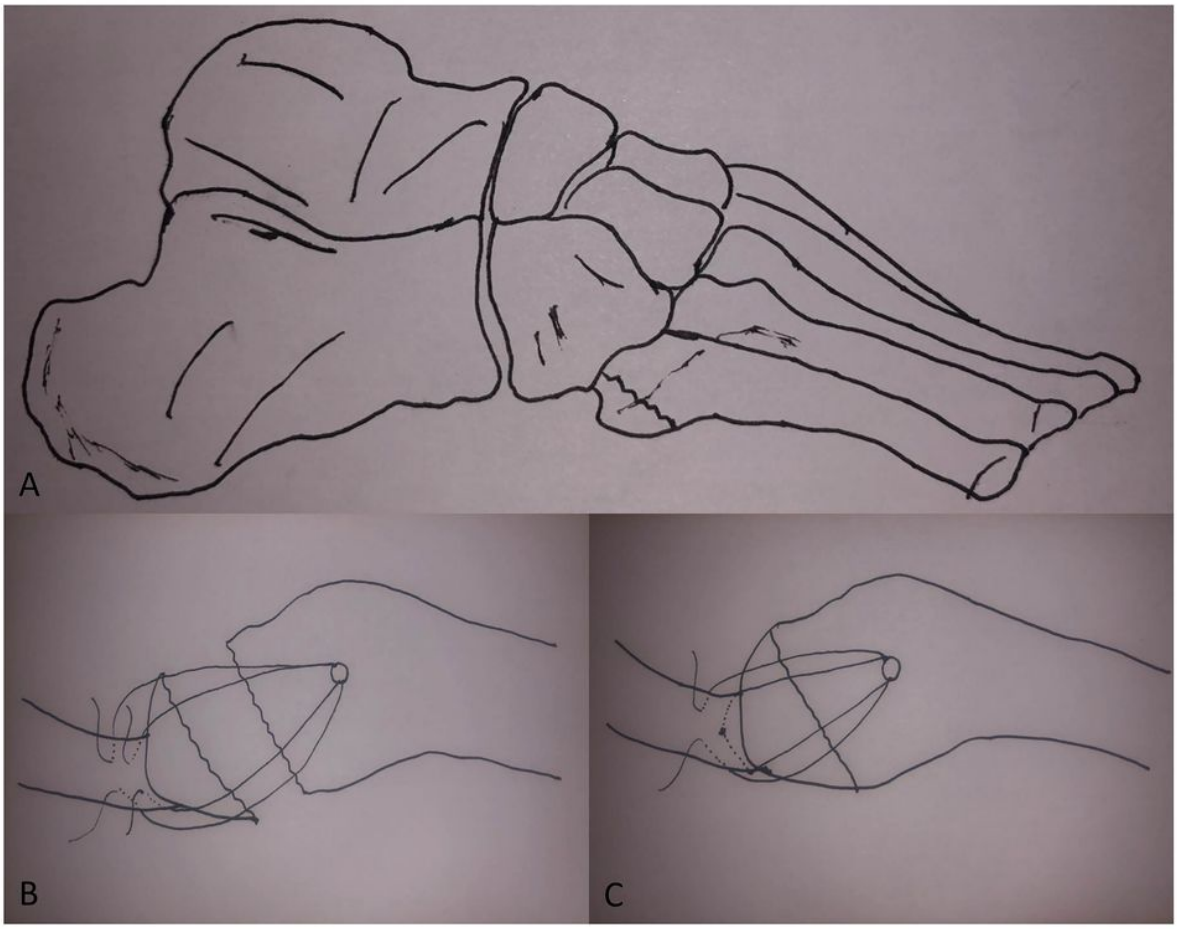

Figure 1

Illustrations showing (A) fifth metatarsal base fracture, (B) suture anchor deployed at the distal metatarsal shaft, 1 cm past the fracture siteand perpendicular to the metatarsal shaft with its sutures passing through the soft tissue sleeve of fractured fragment andthe suture threads were then sewn into the termination of the peroneus brevis tendon, and (C) reduction of the fractured fragment with tightening of the first group of sutures.

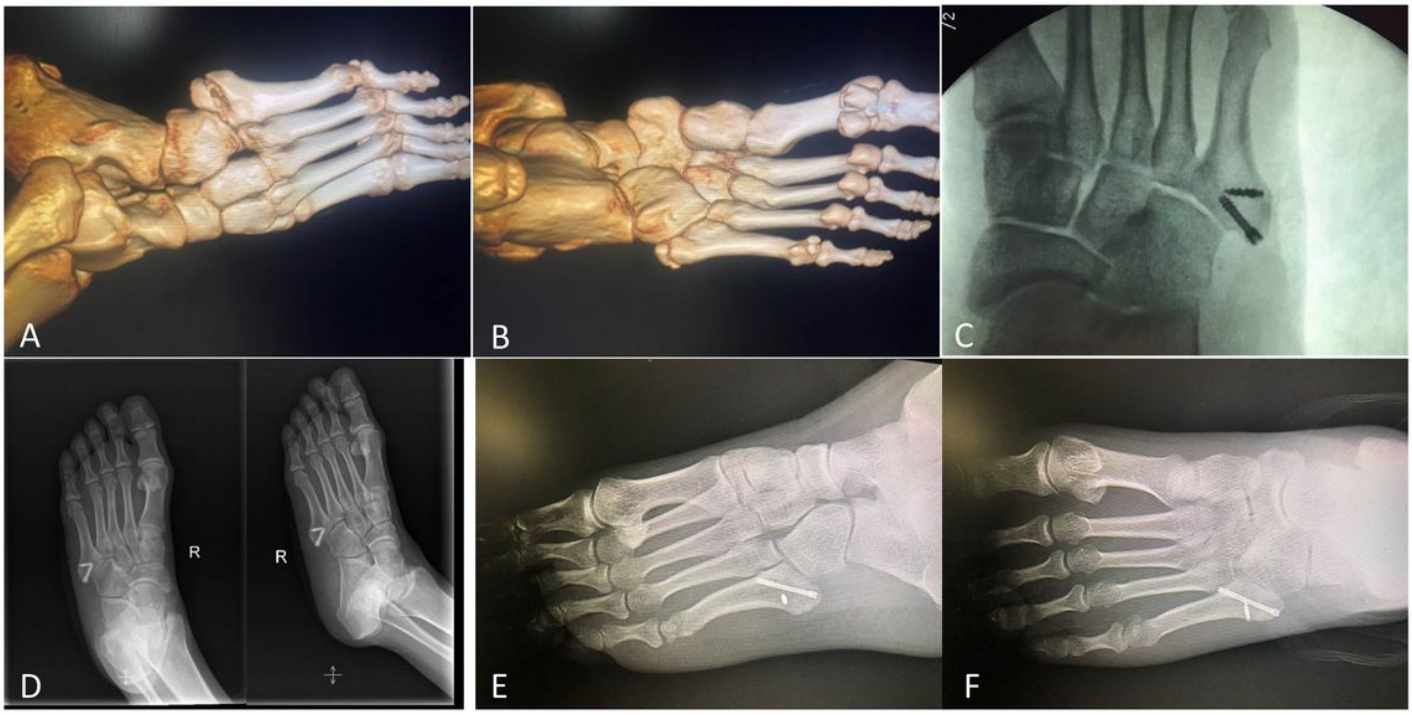

Figure 2

(A, B)Views of an18-year-old male witha fifth metatarsal base fracture. Preoperative computed tomographyscan showing a displaced fifth metatarsal tuberosity avulsion fractures.(C) Radiograph during surgery showing satisfactory fracture reduction and internal fixation.(D)Radiograph taken 4weeks after surgery showing bone union. (E) Views of a35-year-old male witha fifth metatarsal base fracture,radiograph taken 4 weeks after surgery showing satisfactory fracture reduction and internal fixation. (F) Radiograph taken 6 weeks after surgery showing bone union.