High-level resection of the infundibulopelvic ligament during epithelial ovarian cancer surgery: Is it necessary?

Chunfei Wang
Junying Zhou
Haozheng Yan
Lei Li
Zhengyu Li (zhengyuli01@126.com)
Sichuan University West China Second University Hospital https://orcid.org/0000-0002-2295-2059

Research Article

Keywords: Infundibulopelvic ligament, High-level resection, Epithelial ovarian cancer, Metastases, Cytoreductive surgery

Posted Date: April 14th, 2021

DOI: https://doi.org/10.21203/rs.3.rs-283444/v1

Abstract

Objectives

To identify potential metastases in the infundibulopelvic (IP) ligament and evaluate the necessity of high-level resection of the ligament during surgical treatment of epithelial ovarian cancer.

Methods

In this prospective study, 50 female patients with confirmed epithelial ovarian cancer underwent high-level resection of the IP ligament (10 cm or greater) as part of cytoreductive surgery. The resected IP ligaments were sectioned longitudinally at 10-mm intervals and labeled. Each segment was sectioned serially at a thickness of 4 μm, stained with hematoxylin and eosin (H&E), and examined by experienced pathologists for metastatic cells.

Results

Fifty pairs of IP ligaments were examined. Metastatic cells were found in the IP ligaments of 11 patients (22%) with FIGO stage III or IV epithelial ovarian cancer, 3–7 cm from the visual ovarian margin.

Conclusions

Our study demonstrates that metastases were occasionally present in the IP ligament of advanced epithelial ovarian cancer, and therefore, high-level resection of the IP ligament (10 cm or greater) is necessary as part of cytoreductive surgery to reduce residual tumors for advanced epithelial ovarian cancer.

Introduction

Ovarian cancer is the most lethal gynecological malignant disease, with a mortality rate surpassing that of cervical and endometrial cancers [1]. Cytoreductive surgery is the main treatment for ovarian cancer [2]. Therefore, ongoing work is important to improve the survival rate associated with ovarian cancer by improving surgical protocols.

Epithelial ovarian cancer (EOC) can metastasize via the lymphatic, hematogenous, and transcoelomic routes [3]. When spreading through the lymphatic system, one pathway that the metastatic cells travel along consists of the lymph vessels that accompany the ovarian artery and vein in the infundibulopelvic (IP) ligament toward the paraaortic and pelvic lymph nodes [4–6]. Besides, EOC can spread by direct extension into the IP ligament. Therefore, potential metastases in the IP ligament should be considered as part of EOC management.

There are no published studies evaluating metastases in the IP ligament of patients diagnosed with EOC to recommend an appropriate length of resection of the IP ligament during surgery. Even the NCCN Clinical Practice Guidelines in Oncology have not defined an optimal length of IP ligament resection for EOC [7]. This study therefore aims to evaluate the necessity of high-level resection of the IP ligament during surgery for EOC by evaluating the incidence of metastases in this tissue, and to formulate recommendations for cytoreductive surgery to reduce residual tumors after operations and improve survival rates.

Materials And Methods

Patients

This was a prospective study involving 50 female patients with FIGO stage I to IV EOC undergoing high-level resection of the IP ligament (10 cm or greater) during cytoreductive surgery via laparotomy at West China Second University Hospital, Sichuan University, Chengdu, China.

The study was approved by the Regional Ethics Committee of the West China Second University Hospital; all participants provided written informed consent.
All surgeries were performed by the same gynecological oncology team. Patients who did not require high-level resection of the IP ligament during surgery and specimen which did not remain intact were excluded from the study. Baseline clinicopathological patient data were extracted from medical records. Standard measurements taken included the following: IP ligament length in vivo; fixed specimen length after resection; dissemination of metastatic cells into IP ligament (cm).

Procedure

On entering the abdomen, surgeries were performed in accordance with the principles of surgery outlined by the NCCN. The only difference was the inclusion of a high-level resection of the IP ligament during salpingo-oophorectomy. Prior to resection, the broad ligament of uterus was incised, and the IP ligament was isolated and clamped using vascular forceps at least 10 cm or greater away from the visible ovarian margin (Fig. 1). The IP ligament was then ligated with 0 Vicryl and a stitch placed to identify the distal edge from the uterus (Fig. 2). Specimens that remained intact were measured and fixed in 10% neutral buffered formalin. In the laboratory, the fixed specimens were sectioned longitudinally at 10-mm intervals, and each segment was labeled (Fig. 3). Each segment was embedded in conventional paraffin and further sectioned horizontally. Each segment was sectioned serially at a thickness of 4 μm for hematoxylin and eosin (H&E) staining. The 4-μm-thick sections were examined by experienced pathologists, and any segments of the IP ligament where metastatic cells were microscopically identified were recorded. With these data, the distance at which metastatic cells spread microscopically away from the visual margin of the ovary was determined to the closest section of the IP ligament.

Results

Fifty pairs of IP ligaments were included in the study. Metastatic cells were found in the IP ligaments of 11 patients (22%); no metastatic cells were found in the remaining 39 patients (78%). All patients in whom metastatic cells were detected were diagnosed with FIGO stage III or IV EOC; no metastatic cells were found in the IP ligament of patients diagnosed with stage I or II EOC.

Of the 11 patients with metastatic cells in their IP ligaments, six were observed with paraaortic and pelvic lymph node spread; two with paraaortic lymph node spread; one with pelvic lymph node spread; and two without lymphatic metastases. Seven of the 11 patients received neoadjuvant chemotherapy before surgery. The extent of metastatic cells found in the IP ligament was 3–7 cm from the visual ovarian margin (3 cm in eight patient, 4 cm in one patient and 7 cm in two patients). The length of the IP ligaments in vivo was 10 cm or greater; however, when measured on the fixed specimen, the length shrank from 1 cm to 4 cm (Table 1).

Discussion

Our study found that metastases were occasionally present in the IP ligament of advanced EOC. Metastatic cells were found 7 cm from the visual ovarian margin in three of the samples in our study, raising concerns about the likelihood of microscopic residual disease when the IP ligament was not resected at a length of 10 cm during surgery.

Resection of the IP ligament is a common component of salpingo-oophorectomy in both benign and malignant gynecological diseases. A recent study defines resection of the IP ligament at ≥ 2 cm away from the visual ovarian margins against residual ovarian tissue [8]. The NCCN Clinical Practice Guidelines in Oncology suggest removing 2 cm of the proximal IP ligament during risk- reducing salpingo-oophorectomy [7]. To our knowledge, this study is the first that attempts to define an adequate length of the resected IP ligament during cytoreductive surgery based on the potential for metastases to occur in the IP ligament of patients diagnosed with EOC.

Complete cytoreduction to eliminate residual tumors is one of the most important factors influencing survival in patients with EOC [2]. Removal of all tumors is the goal for all surgeons; however, depending on the naked eye and palpation to evaluate the degree of metastasis is unreliable. One study showed that the possibility of microscopic peritoneal metastases in patients with EOC after complete macroscopic cytoreductive surgery was 98.14%, and this could cause peritoneal tumor recurrence [9]. Conducting microscopic cytoreductive surgery in addition to conventional surgery may improve survival rates [9]. Our study found microscopic metastases in the IP ligament; therefore, patients who underwent high-level resection of the IP ligament (at ≥ 10 cm away from the visible ovarian margin) are more likely to achieve complete microscopic cytoreduction. Further studies should assess the impact of high-level resection of the IP ligament on the survival of patients with EOC.

Standard treatments for EOC include primary cytoreductive surgery (PCS) followed by platinum-based chemotherapy.

Neoadjuvant chemotherapy may also be considered for patients who are doubtful about the ability of complete cytoreduction to completely remove the tumor or for patients who are unsuitable for surgery. Thus, patients with stage III or IV EOC should be assessed by gynecological oncologists to determine whether PCS or neoadjuvant chemotherapy is the more promising primary course of action [2, 10].

Irrespective of whether surgery was performed before or after neoadjuvant chemotherapy, our study found microscopic metastases only in the IP ligament of patients with FIGO stage III or IV EOC. Thus, we argue that high-level resection of the IP ligament is particularly necessary for patients with advanced-stage EOC. In addition, most patients with lymphatic metastases also had metastatic cells in the IP ligament. Further studies should therefore investigate the association between potential metastases in the IP ligament and lymphatic system.

All surgeries were performed by the same gynecological oncology team, and the high-level resection of the IP ligament had no impact on the operation time, bleeding volume, and short-term complications. Thus, high-level resection of the IP ligament as part of cytoreductive surgery would not put an additional burden on surgeons or patients.

Overall, metastases were occasionally present in the IP ligament of advanced EOC,and therefore, high-level resection of the IP ligament (10 cm or greater) is necessary as part of cytoreductive surgery to further reduce residual tumors for advanced EOC. Besides, metastases may be present in the IP ligament of cervical cancer and endometrial cancer. Further study should further evaluate the incidence of metastases in the IP ligament of gynecological malignant diseases and investigate the optimal length of resected IP ligament in the surgery.

Declarations

Ethics declaration

Funding

None.

Conflict of interest statement

The authors declare that they have no conflict of interests.

Ethic approval

All procedures performed in studies involving human participants were in accordance with the ethical standards of the institutional and/or national research committee and the 1964 Helsinki declaration and its later amendments or comparable ethical standards.

Consent to participate

Written informed consent was signed by every participant.

Author Contributions

CW: Study concepts, Study design, Data interpretation, Manuscript drafting. JZ: Study design, Data collection, Data interpretation. HY: Data collection. LL: Quality control of pathological examination. ZL: Study concepts, Study design, Manuscript editing, Critical discussion. All authors have read and approved the final manuscript.

References

[1] R.L. Siegel, K.D. Miller, A. Jemal, Cancer statistics, CA Cancer J. Clin. 70 (2020) 7-30. https://doi.org/10.3322/caac.21590.

[2] L. Kuroki, S.R. Guntupalli. Treatment of epithelial ovarian cancer. BMJ 371 (2020) m3773. https://doi.org/10.1136/bmj.m3773. PMID: 33168565.

[3] D.S. Tan, R. Agarwal, S.B. Kaye, Mechanisms of transcoelomic metastasis in ovarian cancer. Lancet Oncol. 7 (2006) 925-934. https://doi.org/10.1016/S1470-2045(06)70939-1.

[4] M. Kleppe, T. Wang, T. Van Gorp, B.F. Slangen, A.J. Kruse, R.F. Kruitwagen, Lymph node metastasis in stages I and II ovarian cancer: a review. Gynecol. Oncol. 123 (2011) 610-614. https://doi.org/10.1016/j.ygyno.2011.09.013.

[5] M. Kleppe, A.C. Kraima, R.F. Kruitwagen, T. Van Gorp, N.N. Smit, J.C. van Munsteren, M.C. DeRuiter, Understanding Lymphatic Drainage Pathways of the Ovaries to Predict Sites for Sentinel Nodes in Ovarian Cancer. Int. J. Gynecol. Cancer 25 (2015) 1405-1414. https://doi.org/10.1097/IGC.0000000000000514.

[6] M. Kleppe, B. Brans, T. Van Gorp, B.F.M. Slangen, A.J. Kruse, I.N.A. Pooters, M.G. Lotz, K.K. Van de Vijver, R.F. Kruitwagen. The detection of sentinel nodes in ovarian cancer: a feasibility study. J. Nucl. Med. 55 (2014) 1799-1804. https://doi.org/10.2967/jnumed.114.144329.

[7] D.K. Armstrong, R.D. Alvarez, J.N. Bakkum-Gamez, L. Barroilhet, K. Behbakht, A. Berchuck, L.M. Chen, M. Cristea, M. DeRosa, E.L. Eisenhauer, D.M. Gershenson, H.J. Gray, R. Grisham, A. Hakam, A. Jain, A. Karam, G.E. Konecny, C.A. Leath, J. Liu, H. Mahdi, L. Martin, D. Matei, M. McHale, K. McLean, D.S. Miller, D.M. O'Malley, S. Percac-Lima, E. Ratner, S.W. Remmenga, R. Vargas, T.L. Werner, E. Zsiros, J.L. Burns, A.M. Engh. Ovarian Cancer, Version 2.2020, NCCN Clinical Practice Guidelines in Oncology. J Natl Compr Canc Netw. 19(2021) 191-226. https://doi.org/10.6004/jnccn.2021.0007. PMID: 33545690.

[8] I.A. Fennimore, N.L. Simon, G. Bills, V.L. Dryfhout, A.M. Schniederjan. Extension of ovarian tissue into the infundibulopelvic ligament beyond visual margins. Gynecol. Oncol. 114 (2009) 61-63. https://doi.org/10.1016/j.ygyno.2009.03.006.

[9] H. Azaïs, A.S. Vignion-Dewalle, M. Carrier, J. Augustin, E. Da Maïa, A. Penel, J. Belghiti, M. Nikpayam, C. Gonthier, L. Ziane, S. Mordon, P. Collinet, G. Canlorbe, C. Uzan. Microscopic Peritoneal Residual Disease after Complete Macroscopic Cytoreductive Surgery for Advanced High Grade Serous Ovarian Cancer. J Clin Med. 10(2020) 41. https://doi.org/10.3390/jcm10010041. PMID: 33375564; PMCID: PMC7795826.

[10] A.A. Wright, K. Bohlke, D.K. Armstrong, M.A. Bookman, W.A. Cliby, R.L. Coleman, D.S. Dizon, J.J. Kash, L.A. Meyer, K.N. Moore, A.B. Olawaiye, J. Oldham, R. Salani, D. Sparacio, W.P. Tew, I. Vergote, M.I. Edelson. Neoadjuvant chemotherapy for newly diagnosed, advanced ovarian cancer: Society of Gynecologic Oncology and American Society of Clinical Oncology Clinical Practice Guideline. J. Clin. Oncol. 34 (2016) 3460-3473. https://doi.org/10.1200/JCO.2016.68.6907.

Tables

Table 1

Clinical and pathological characteristics of EOC patients with metastatic cells in the IP ligament.

FIGO stage	Fixed specimen measure of IP (cm)	Extent of metastatic cells in IP (cm)	Histological type	Neoadjuvant chemotherapy	Lymphatic metastasis
FIGO Stage III					
#1	L 8	3	Serous	Yes	Para-aortic
#2	R 6.5	3	Non-serous	No	Para-aortic and pelvic
#3	L 6	3	Serous	No	No
#4	L 9	7	Serous	Yes	Para-aortic and pelvic
#5	R 6	4	Serous	Yes	Para-aortic and pelvic
#6	L 8	3	Serous	No	Para-aortic
#7	L 7	3	Serous	Yes	No
#8	R 6/L 8	3/ 3	Non-serous	Yes	Pelvic
#9	R 8	3	Non-serous	Yes	Para-aortic and pelvic
FIGO Stage IV					
#10	R 7.5/ L 7	7/ 7	Non-serous	Yes	Para-aortic and pelvic
#11	R 6	3	Serous	No	Para-aortic and pelvic

EOC=epithelial ovarian cancer, R=right, L=left, IP=infundibulopelvic ligament.

Figures

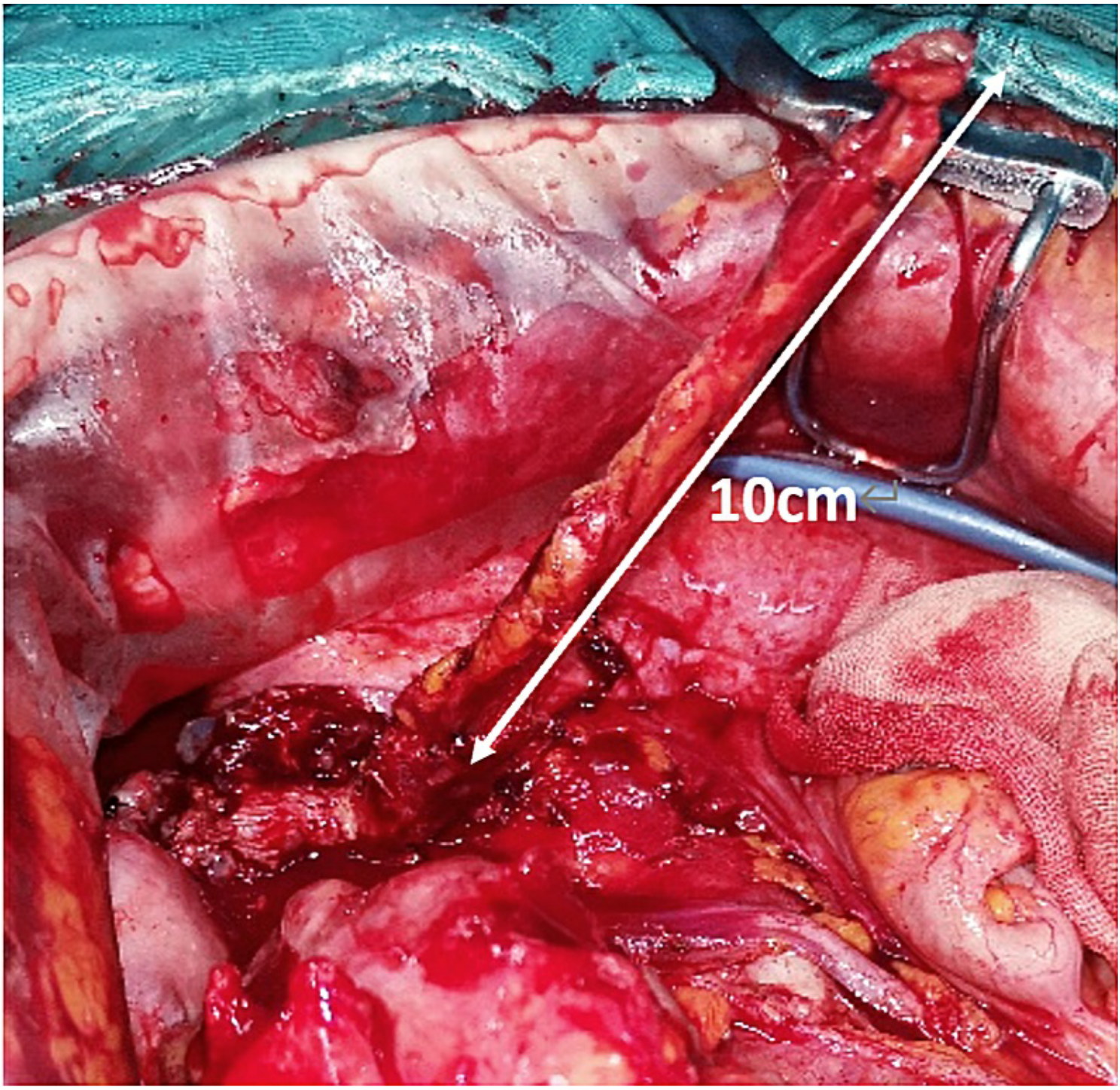

Figure 1

An IP ligament was isolated and clamped by vascular forceps at ≥10 cm away from the visible ovarian margin

Figure 2

The resected IP ligament was ligated with a stitch placed to identify the distal edge from the uterus.



Figure 3

The fixed IP ligament was sectioned longitudinally at 10-mm intervals and each segment labeled.

Supplementary Files

This is a list of supplementary files associated with this preprint. Click to download.

- ConflictofintereststatementCW.docx
- ConflictofintereststatementHY.docx
- ConflictofintereststatementJZ.docx
- ConflictofintereststatementLL.docx
- ConflictofintereststatementZL.docx