Perception, Knowledge and Attitudes Towards Molar Incisor Hypomineralization Among Spanish Dentists: A Cross-sectional Study.

Clara Serna-Muñoz
Universidad de Murcia

Yolanda Martinez-Beneyto (yolandam@um.es)
University of Murcia https://orcid.org/0000-0002-1523-9415

Amparo Pérez-Silva
Universidad de Murcia

Andrea Poza-Pascual
Servicio Murciano de Salud

Francisco Javier Ibáñez-López
Universidad de Murcia

Antonio J. Ortiz-Ruiz
Universidad de Murcia

Research article

Keywords: Molar Incisor Hypomineralization, knowledge, perception, general dental

Posted Date: May 27th, 2020

DOI: https://doi.org/10.21203/rs.3.rs-28433/v1

Version of Record: A version of this preprint was published on September 18th, 2020. See the published version at https://doi.org/10.1186/s12903-020-01249-6.

Abstract

Background: Molar Incisor Hypomineralization (MIH) is a growing problem, and its treatment is a challenge. The purpose was to evaluate and compare the perceptions, knowledge and clinical experiences of MIH between general dental practitioners (GDPs) and pediatric dentists (PDs) in Spain.

Methods: All dentists belonging to the College of Dentists of the Region of Murcia, in the South-East of Spain, were invited to participate in a cross-sectional survey. They were asked to complete a 2-section questionnaire including socio-demographic profiles and knowledge, experience, and perceptions of MIH. Data were analyzed using the Pearson chi-square test, Fisher´s exact test and Cramer´s V test.

Results: The overall response rate was 18.6% (214/1147). Most respondents were aged 31-40 years (44.86%), with more than 15 years of professional experience (39.72%). They worked mainly in the private sector (84.58%) and were licensed in Dentistry (74.30%): 95.45% of pediatric dentists had detected an increase in the incidence of MIH in recent years ($p<0.001$). Only 23.80% of GDPs claimed to have had some training course in MIH. With respect to the etiology, chronic medical conditions ($p<0.05$) and environmental pollutants ($p<0.001$) were the only factors that showed significant between-group differences. Durability ($p<0.01$) and remineralization potential ($p<0.05$) were the factors where there was a between-group difference when choosing the material for restoration. In the case of post-eruptive fractures and opacities the preferred material for both groups was resin-modified glass ionomer (RMGIC). However, in incisor lesions, composite was the material of choice for both groups, with significant differences ($p<0.05$) in the use of glass ionomer. Most respondents expressed a need for continuing education on MIH.

Conclusion: Spanish dentists perceived an increase in the incidence of MIH. The material of choice is RMGIC for non-aesthetic sectors and composite for incisors. Both GDPs and PDs believe they need more training on the etiology, diagnosis and treatment of MIH.

Background

The term molar incisor hypomineralization (MIH) was described by Weerheijm, et al. in 2001 and adopted by the international dental community, as a result of a consensus, at the Congress of the European Academy of Paediatric Dentistry in Athens in 2003[1]. MIH is defined as a clinical condition of a qualitative enamel developmental defect of systemic origin that affects one or more first permanent molars with or without the involvement of permanent incisors[1]. When it appears in primary teething it is called hypomineralized second primary molar (HSPM), which most affects the second molars and canines and is regarded a predictive factor for MIH in the permanent teething [2].

Historically, in the dental literature a wide variety of terminology and definitions for enamel defects in hypomineralized molars, with or without post-eruptive enamel fractures have been used: opacity of the enamel not caused by fluoride, internal hypoplasia of the enamel, non-endemic enamel speckling, opaque stains, idiopathic opacities of the enamel, opacity of the enamel, or molars of the enamel. Some terms

simply describe the pathology, while others bear the name of the causal agent [3]. Despite the many reports on its etiology, the factors that cause MIH remain unclear [4].

Clinically, the form of presentation and the severity of MIH-affected teeth may be asymmetrical in the same patient and vary from mild opacities to severe post-eruptive breakdown that may affect from one to four first permanent molars [5]. MIH can be difficult to diagnose, and clinicians may confuse it with other conditions such as enamel hypoplasia, fluorosis and amelogenesis imperfecta. In addition, the diagnosis can be complicated by secondary cavity lesions due to its rapid formation and progression in a highly porous substrate [6].

The global recorded prevalence of MIH ranges from 2.4–40% and differs between countries [7,8]. There are a limited number of studies on the prevalence of MIH in Spain in which the prevalence varies from 7. 94% [9], to 11.1% [10], 17.8% [11] and 21.8% [12].

The high prevalence and incidence of MIH, the poor quality of life of child patients and the difficult clinical management, have led to numerous studies on the perception, diagnosis and management of MIH through surveys of dentists, both general dental practitioners (GDPs) and pediatric dentists (PDs) [13–22]. In Spain, despite the high prevalence described in some areas, no studies have been conducted on how dentists act in the face of MIH. The objective of this study was to evaluate perception and knowledge about the diagnosis and management strategies of MIH of GDPs and PDs in the Region of Murcia, in the south east of Spain.

Methods

Sample and procedures

The study was approved by the Bioethics Committee of Murcia University (Reference Number: 2255/2019). Google Survey software was used to develop the survey that was subsequently emailed to all members of College of Dentists of Murcia (n = 1,147) in March 2019. Participation was anonymous and voluntary. Participants were asked to complete the online questionnaire on their own time. A reminder email was sent two weeks after initial distribution. The survey was online for one month.

A pilot version of the questionnaire was tested by six teachers and six postgraduate students of the master’s degree in Integrated Pediatric Dentistry, University of Murcia, to ensure the questions had been correctly prepared, were easily understandable and did not entail a prolonged response time.

Survey Instrument (supplementary file 1)

The questionnaire was divided into two main sections. The first section covered demographics, educational background, perception, clinical appearance, prevalence, participants´ attitudes and practice in MIH management and finally restorative options in MIH management.

In the second part of the questionnaire, two clinical situations with illustrative photographs and a written case description were suggested to dentists (Figs. 1 and 2).

Data Analysis

Study data were processed and analyzed using the *R* statistical package. To identify significant differences and search for relationships based on sociodemographic variables, Pearson's chi-square test was applied in contrasts where the required assumptions were met, and Fisher's exact test in which they were not (p-value less than 0.05 and significance level 0.05). Cramer’s test was used to determine whether the relationship was strong or weak.

Results

Of the 1,147 dentists invited to participate, 216 responded. Two surveys were eliminated because they were not completed correctly, resulting in a response rate of 18.66% (n-214): 61.4% were with GDPs or other specialties (n = 148), and 38.6% were PDs (n = 66).

Of participants, 44.9% were aged 31–40 years, 39.7% had > 15 years of practical experience, and 84.6% worked in the private sector and 74.3% were licensed in Dentistry (Table 1).

Table 1
Demographic characteristics of study participants

	Total	GDPs	PDs
Characteristics	**n (%)**	**n (%)**	**n (%)**
Age group	214 (100)	148 (100)	66 (100)
< 30	56 (26.17)	37 (25.00)	19 (28.79)
31–40	96 (44.86)	67 (45.27)	29 (43.94)
41–50	33 (15.42)	23 (15.54)	10 (15.15)
> 50	29 (13.55)	21 (14.19)	8 (12.12)
Years of practice	214 (100)	148 (100)	66 (100)
< 5	47 (21.96)	35 (23.65)	12 (18.18)
6–10	37 (17.29)	24 (16.22)	13 (19.70)
11–15	45 (21.03)	33 (22.30)	12 (18.18)
> 15	85 (39.72)	56 (37.84)	29 (43.94)
Work Sector	214 (100)	148 (100)	66 (100)
Public sector	7 (3.271)	3 (2.027)	4 (6.05)
Private Sector	181 (84.579)	130 (87.83)	51 (77.26)
Combined	26 (12.150)	15 (10.13)	11 (16.67)
Degree Level			
Stomatologist	23 (10.75)	18 (12.162)	5 (7.57)
Dentistry Licenciated (up to 2010)	159 (74.30)	104 (70.270)	55 (83.33)
Dentistry Graduated (later than 2010)	32 (14.95)	26 (17.568)	6 (9.08)
GDPs: General Dental Practitioners. PDs: Paedriatric Dentists			

The perception of GDPs and PDs about MIH is shown in Table 2: 59.6% of GDPs diagnoses MIH on a monthly basis, while 72.6% of PDs diagnosed MIH on a weekly basis.

Table 2
MIH perception, clinical appearance and prevalence according to study participants

	Total	GDPs	PDs	
Question	**n (%)**	**n (%)**	**n (%)**	**p-Value**
How often do you notice hypomineralized teeth in your practice?	214 (100)	148 (100)	66 (100)	
Weekly	88 (41.12)	40 (27.02)	48 (72.73)	
Monthly	104 (48.59)	88 (59.46)	16 (24.24)	
Annually	22 (10.28)	20 (13.50)	2 (3.03)	
Approximately what percentage of your patients present this defect?	214 (100)	148 (100)	66 (100)	
< 10%	104 (48.59)	88 (59.45)	16 (24.24)	
10–25%	87 (40.65)	54 (36.48)	33 (50)	
> 25%	23 (10.74)	6 (4.05)	17 (25.76)	
Do you perceive that the incidence of MIH has increased in recent years?	214 (100)	148 (100)	66 (100)	< 0.001
No	41 (19.15)	38 (25.67)	3 (4.54)	
Yes	173 (80.84)	110 (74.32)	63 (95.45)	
What do you most frequently notice in your practice?	214 (100)	148 (100)	66 (100)	
White demarcated opacities	78 (36.45)	58 (39.19)	20 (30.30)	
Yellow/brown demarcated opacities	129 (60.28)	86 (58.11)	43 (65.16)	
Post-eruptive enamel breakdown	7 (3.27)	4 (2.7)	3 (4.54)	
How frequently do you notice this defect in the second primary molar?	210 (100)	144 (100)	66 (100)	

GDPs: General Dental Practitioners. PDs: Paedriatric Dentists

	Total	GDPs	PDs
More often	9 (4.28)	5 (3.47)	4 (6.06)
Equally as often	15 (17.14)	12 (8.33)	3 (4.54)
Less often	186 (88.57)	127 (88.19)	59 (89.39)
GDPs: General Dental Practitioners. PDs: Paedriatric Dentists			

In terms of prevalence, 59.4% of GDPs found that < 10% of their patients had MIH, while 50% of PDs said that between 10–25% of their patients had MIH. In addition, 95.4% of PDs had detected an increase in the incidence of MIH in recent years ($p < 0.001$) in dental consultations.

Y*ellow-brown demarcated opacities* were the most common clinical forms detected, both by PDs (65.1%) and GDPs (58.1%) and were most often diagnosed in the permanent teething.

The knowledge of respondents regarding the etiology of MIH is shown in Table 3. Many factors were mentioned, but chronic medical conditions affecting children ($p < 0.05$) and environmental pollutants ($p < 0.001$) were the only factors showed significant differences between the two groups of professionals.

Table 3
MIH management considerations, source of information, and clinical training demand according to study participants.

	Total	GDPs	PDs	
Question	**n (%)**	**n (%)**	**n (%)**	**p-Value**
Which factors do you think are involved in the etiology of MIH?	**827 (100)**	**535 (100)**	**292 (100)**	
Genetic factors	107 (12.93)	77 (14.39)	30 (10.27)	
Acute medical condition that affects the mother during pregnancy	110 (13.30)	74 (13.83)	36 (12.32)	
Acute medical condition that affects the child involved	93 (11.24)	61 (11.40)	32 (10.95)	
Antibiotics/medications taken by the mother during pregnancy	90 (10.88)	56 (10.46)	34 (11.64)	
Antibiotics/medications taken by the child involved	115 (13.90)	73 (13.64)	42 (14.72)	
Chronic medical condition that affects the mother during pregnancy	75 (9.06)	47 (8.78)	28 (9.58)	
Chronic medical condition that affects the child involved	76 (9.18)	45 (8.41)	31 (10.61)	< 0.05
Environmental contaminants	96 (11.60)	57 (10.65)	39 (13.35)	< 0.001
Fluoride exposure	65 (7.85)	45 (8.41)	20 (6.85)	
Do you think the management of MIH is a challenge?	**213 (100)**	**148 (100)**	**65 (100)**	
Yes, very difficult	72 (33.80)	52 (35.13)	20 (30.76)	
Yes, somewhat difficult	127 (59.62)	86 (58.10)	41 (63.07)	
No	14 (6.57)	10 (6.76)	4 (6.15)	
Which are the biggest difficulties?	**649 (100)**	**439 (100)**	**210 (100)**	
Diagnosis	42 (6.47)	29 (6.60)	13 (6.19)	

GDPs: General Dental Practitioners. PDs: Paedriatric Dentists

	Total	GDPs	PDs	
Esthetics	66 (10.17)	42 (9.57)	24 (11.42)	
Long-term success of restoration	173 (26.65)	120 (27.33)	53 (25.23)	
Correct determination of restoration margins	124 (19.10)	89 (20.27)	35 (16.66)	
Achieving correct local anesthetic	72 (11.09)	42 (9.57)	30 (14.28)	< 0.001
Providing correct restoration	144 (22.18)	100 (22.77)	44 (20.95)	
Other	28 (4.31)	17 (3.87)	11 (5.29)	
Do you receive any information on MIH?	**213 (100)**	**147 (100)**	**66 (100)**	
Yes	74 (34.74)	35 (23.80)	39 (59.09)	
No	139 (65.25)	112 (76.19)	27 (40.90)	
Where do you obtain the information	**194 (100)**	**130 (100)**	**61 (100)**	
Journals	34 (17.52)	24 (18.46)	10 (16.39)	
Continuing education	54 (27.83)	27 (20.77)	27 (44.26)	
Brochures	4 (2.06)	4 (13.07)	0 (0)	
Internet	58 (29.89)	47 (36.15)	11 (18.03)	
Books	10 (5.15)	5 (3.84)	5 (8.19)	
Others	31 (15.98)	23 (17.69)	8 (13.11)	
Where do you think more information is necessary?	**212 (100)**	**146 (100)**	**66 (100)**	
Etiology	19 (8.96)	8 (5.47)	11 (16.66)	
Diagnosis	1 (0.47)	0 (0)	1 (1.51)	

GDPs: General Dental Practitioners. PDs: Paedriatric Dentists

	Total	GDPs	PDs
Treatment	69 (32.54)	51 (34.93)	18 (27.27)
All	123 (58.01)	87 (59.59)	36 (54.54)
GDPs: General Dental Practitioners. PDs: Paedriatric Dentists			

As for the difficulty of managing MIH, the most frequent response was that it is considered a difficult challenge and that GPDs (76.2%) had not received any information on this. PDs stated that the information they obtain on MIH basically comes from face-to-face continuing education (44.3%), while the Internet was the source of choice for GDPs (36.1%), with widespread demand for information on the etiology, diagnosis and treatment of MIH.

The results on the restorative treatments carried out in MIH are shown in Table 4. Significant differences in the choice of material characteristics were identified, such as durability ($p < 0.01$) and remineralization potential ($p < 0.05$) between GDPs and PDs. As for the material of choice in cases of post-eruptive fractures, RMGIC was the most widely used by both groups. However, there were significant differences in the use of Glass Ionomer Cement (GIC) ($p < 0.05$) between GDPs (12.2%) and PDs (18.4%). No significant differences were found in the materials used to restore opacity, with RMGIC again being the first choice in both groups. However, in the case of the treatment of lesions in incisors, composite was the material of choice in both groups, with significant differences ($p < 0.05$) in the use of RMGIC between GDPs and PDs.

Table 4
RESTORATIVE MANAGEMENT OPTIONS FOR MOLAR INCISOR HYPOMINERALIZATION (MIH)

	Total	GDPs	PDs	
Question	**n (%)**	**n(%)**	**n(%)**	**p-Value**
Factors in the choice of material	**577 (100)**	**392 (100)**	**185 (100)**	
Adhesion	137 (23.74)	96 (24.48)	41 (22.16)	
Durability	124 (21.49)	95 (24.23)	29 (15.67)	< 0.01
Experience	30 (5.20)	18 (4.59)	12 (6.48)	
Remineralization potential	146 (25.30)	93 (23.72)	53 (13.52)	< 0.05
Patient/parent preferences	8 (1.38)	6 (1.53)	2 (0.51)	
Sensitivity	84 (14.55)	53 (13.52)	31 (7.91)	
Research findings	48 (8.32)	31 (7.91)	17 (4.33)	
Material of choice for post-eruptive fractures	**387 (100)**	**262 (100)**	**125 (100)**	
Compomer	13 (3.35)	10 (3.81)	3 (2.4)	
Composite resin	88 (22.74)	59 (22.51)	29 (23.2)	
Flowable composite resin	18 (4.65)	15 (5.72)	3 (2.4)	
Stainless steel crown	38 (9.82)	26 (9.92)	12 (9.6)	
Silver diamine fluoride	6 (1.55)	4 (1.53)	2 (1.6)	
Cast restoration	23 (5.94)	16 (6.11)	7 (5.6)	
GIC	55 (14.21)	32 (12.21)	23 (18.4)	< 0.05
RMGIC	139 (35.91)	95 (36.25)	44 (35.2)	
Others	7 (1.81)	5 (1.90)	2 (1.6)	
Material of choice for opacities	**316 (100)**	**216 (100)**	**100 (100)**	
Amalgam	4 (1.26)	4 (1.85)	0 (0)	
Compomer	18 (5.69)	15 (6.94)	3 (3)	
Composite resin	87 (27.53)	61 (28.24)	26 (26)	
Flowable composite resin	25 (7.91)	17 (7.87)	8 (8)	
Stainless steel crowns	6 (1.89)	5 (2.31)	1 (1)	
Silver diamine fluoride	18 (5.69)	11 (5.09)	7 (7)	

	Total	GDPs	PDs	
GIC	42 (13.29)	25 (11.57)	17 (17)	
RMGIC	109 (34.49)	72 (33.33)	37 (37)	
Others	7 (2.21)	6 (2.77)	1 (1)	
Material of choice for hypomineralized incisors	**318 (100)**	**209 (100)**	**109 (100)**	
Compomer	12 (3.77)	8 (3.82)	4 (3.66)	
Composite resin	122 (38.36)	86 (41.14)	36 (33.02)	
Flowable composite resin	40 (12.57)	27 (12.91)	13 (11.95)	
Stainless steel crowns	1 (0.31)	1 (0.47)	0 (0)	
Silver diamine fluoride	3 (0.94)	2 (0.95)	1 (0.91)	
Resin infiltration	52 (16.35)	35 (16.74)	17 (15.59)	
GIC	15 (4.71)	7 (3.34)	8 (7.33)	
RMGIC	62 (19.49)	36 (17.22)	26 (23.85)	< 0.05
Other	11 (3.45)	7 (3.34)	4 (3.66)	
GDPs: General Dental Practitioners. PDs: Paedriatric Dentists. GIC: glass ionomer cement. RMGIC: resin-modified glass ionomer cement.				
In clinical case 1, dentists were asked which treatment they would prefer for a semi-erupted primary molar with moderate MIH, post-eruptive fracture and sensitivity in the tooth in a seven-year-old patient. The options were: (1) Fluoride varnish, (2) Restoration with glass ionomer cement (GIC) (3) Restoration with resin composite (4) Extraction of the tooth (5) I am not sure of the best option.				
In clinical case 2, dentists were asked about the best treatment for a delimited brown opacity without post-eruptive enamel fracture. The options were: (1A) Eliminate all tissue affected by MIH and restore with resin composite; (1B) Eliminate all affected tissue and restore with glass ionomer cement (GIC); (1C) Eliminate all affected tissue and make a temporary restoration; (2A) Eliminate only the most affected tissue and restore with composite; (2B) Eliminate only the most affected tissue and restore with glass ionomer; (2C) Eliminate only the most affected tissue and make a temporary restoration; (3A) Do not eliminate any dental tissue and restore with composite ;(3B) Do not eliminate any dental tissue and restore with glass ionomer (GIC); (3C) Do not eliminate any dental tissue and make a temporary restoration.				

In the second part of the questionnaire, in the first clinical case (Fig. 1), the material of choice for most respondents was GIC in both groups (GDPs: 56.1% – PD: 69.1%). In the second clinical case (Fig. 2), 51% of GDPs supported removal of only the most affected tissue and restoration with GIC. However, a more conservative attitude was observed among PDs (40.5%), who stated they would not remove any enamel and would restore with GIC.

Discussion

Despite the high prevalence and increased incidence of MIH in Spanish pediatric patients, this study is the first to provide information on the perception and knowledge of the etiology and diagnosis of MIH, and strategies in patient management of Spanish dentists, GDPs and PDs.

We used an online survey to avoid the low response rate obtained in postal survey [23]. The response rate was 18.6%, despite a reminder sent at two weeks, which was similar to that recorded in studies in other countries [8,13,16,19,21].

In Spain, dentistry is mostly private, which is reflected by the responders (84.58% private), unlike countries such as Norway [14] or Australia and Chile [19] where most of the dentists were public workers. We found that 69.16% of participants were GDPs and 30.84% PDs. PD training in Spain is not specialized, as in most European Union countries, but is a postgraduate master type of training. In both groups of dentists, the majority (74.30%) of practitioners were licensed in Dentistry, with mean age of 31–40 years (44.86%) and with more than 15 years of professional experience (39.72%). The professional profiles found in other studies vary in age and years of experience, with the study conducted in Hong Kong having the oldest professionals and the greatest professional experience [8].

We found that PDs had twice the perception of patients with MIH lesions compared with GDPs, a situation reflected in countries such as Iraq[15], Malaysia[22], Australia-New Zealand [18], Saudi Arabia [17], China [8] and the UK [20], where the prevalence of MIH is similar to Spain. Both in Spain and in other countries [15,17,18], the general perception of dentists is that there is an increase in the incidence of MIH, although in our case the perception is significantly higher in PDs than in GDPs. Thus, 59.45% of GDPs responded that the prevalence of MIH patients is < 10%. GDPs from countries such as the USA [21] India [16] and China [8] estimated the prevalence at < 5%. These results are closely related to the training of dentists and their diagnostic ability: 59.09% of PDs claimed to have training in MIH compared with 23.8% of GDPs. In addition, this training was received in continuous education courses, compared with the online self-training described by GDPs. In other countries, the training of PDs in MIH shows similar results, although GDPs had less training in MIH (7–8.8%) (16, 30). Despite these results, both PDs and GDPs in Spain require ongoing training courses on MIH [8,15,16, 19].

The most recognized MIH lesion in both study groups was yellow/brown lesions, as it was in other countries [13,15–18]. This may be because white-cream lesions can be mistaken for other lesions such as fluorosis or white spot cavities [20, 24]. The percentage of post-eruptive enamel fractures was low, possibly because they may be confused with extensive cavity lesions, with atypical restorations typical of this pathology, since the enamel breaks quickly after rupture [15, 25], or with enamel hypoplasia, although in this case the edges of the lesion are not as irregular as in MIH [20].

In 2012, hypomineralization of the primary teeth was described, mainly in the second primary molars (HSPM) [2]. This is known to be associated with an increased risk of hypomineralization in the permanent molars [2], although the absence of HSPM does not exclude future MIH. Most of our respondents report

detecting HSPM less frequently, with no differences between the two groups, as is the case in studies in the USA [21], Kuwait [13,] Saudi Arabia [17] and Australia-Chile [19], even though PDs have greater access to pediatric populations, where the diagnosis should be more common.

In general, and as in other studies [8, 15–18,21], dentists' responses reflect the hypothesis that the etiology may be multifactorial, with a diversity of responses. Most studies, when describing etiological factors, attribute MIH primarily to "chronic and acute medical conditioners affecting the mother and child" [8, 15, 16, 19]. In our study, 42.78% of dentists attributed the etiology to these factors, lower than the 80–100% found in other studies [8, 18]. The second cause, according to the dentists in our study, was the consumption of antibiotics by the child or mother during pregnancy (24.78%), figures similar to the Iran study [15] but below the studies in Hong Kong [8] and Australia-New Zealand [18]. Environmental pollutants were considered causal agents by 11.6%, with a different perception between GDPs and DPs.

A significant percentage of both GDPs and PDs responded that they found the management of MIH "somewhat difficult". This is because these patients have increased anxiety [26] and tooth hypersensitivity, even after local anesthesia. In fact, anesthesia is one of the procedures that mark significant differences between dentists, with GDPs finding it more difficult to achieve good anesthesia than PDs.

Achieving correct restoration and long-term success is what worries dentists the most (48.83%). It is known that etching with orthophosphoric acid creates faulty etched patterns [27], that resin penetration is defective and the adhesion force of the composite resins to the enamel affected by MIH is low [28], and that there is a high failure rate of this type of materials in molars with MIH [29]; in fact, the second most relevant factor in the choice of material by our dentists is the adhesion of the material (23.74%).

There are many reported treatment options for the restoration of teeth with MIH lesions: fluoride and/or CPP-ACP remineralization systems, silver diamine fluoride, pit and fissure sealants, resin infiltrations, conventional and modified glass ionomers with resin, resin composite, amalgam, preformed crowns, and even extractions, always depending on the severity of the lesion [30].

The potential for remineralization of material in restoration is the most relevant factor in the choice of materials (23.5%), significantly worrying GDPs more than PDs. In fact, the most commonly used material to restore post-eruptive fractures is RMGIC, followed by composite and both are used equally by GDPs and PDs. GIC is the third material of choice and is used proportionally more by PDs than GDPs. This may be because they treat younger children and use it as filling material in atraumatic restorative treatments or for interim restorations. Durability, which is one of the most relevant factors in material choice, is therefore significantly less decisive for PDs than for GDPs.

There are studies using GIC (81%) more than RMGIC (44.3%), which is justified by the greater fluoride release [18]. However, a recent systematic review shows that the rate of failures in restoration materials in the treatment of MIH is higher with the use of amalgams and glass ionomers, and the highest success rate is achieved with indirect restorations, preformed stainless steel crowns (SSC) and composite

restorations [43]. In other studies, composite was the material of choice [8, 13, 17, 18], and was recommended by Lygidakis et al. [25] in moderate lesions. In our study, the number of SSCs was very low, compared with other studies [8, 16, 18] in which it was the treatment of choice in fractures for most PDs. Some authors recommend them for moderate and severe MIH lesions instead of GIC and RMGIC [25].

With respect to enamel opacity, the materials chosen were the same in both groups, first RMGIC followed by composite. However, in incisor lesions, composite was the material of choice, due to aesthetic concerns, followed by RMGIC and resin infiltrations. PDs use significantly more RMGIC to restore incisor enamel lesions.

The adhesion, durability and potential for remineralization were also decisive in the choice of material by most professionals from other countries [8, 16, 18]. We left open the possibility of "other materials" where dentists could introduce other options used in combination with those defined in the survey. However, there were only 1.81–3.45% of responses. In contrast, in the Hong Kong study, 96.3% of PDs used fluoride varnishes and 64% pit fissure sealants [8].

In clinical case 1 (Fig. 1), where a post-eruptive enamel fracture was presented in a semi-erupted tooth, the material selected by both groups for treatment was GIC, followed by composite, similar to the results of the Norwegian study[14]. Difficult moisture control in a semi-erupted molar and fluoride release were the main reasons for choosing GIC. The limited mechanical properties of GIC mean it should be considered an interim therapeutic restoration and that must be replaced by another, definitive material (composite or preformed crowns) when eruption is complete [26].

In clinical case 2, the preferred option for GDPs was to remove the tissue seemingly most affected and restore with glass ionomer, compared with PDs whose option was to not to remove any dental tissue and use glass ionomer to restore. This shows a trend towards less invasive treatment by PDs, as described by other reports [14].

Conclusion

Spanish dentists have the perception that the incidence of MIH has increased in recent years. They think it is difficult or very difficult to manage this type of lesion, since the long-term success of restorations of MIH lesions is compromised because resin adhesion is not good. They use RMGICs more frequently, taking advantage of their remineralizing potential, except in incisors, where they use composites. Both GDPs and PDs think they need more training on the etiology, diagnosis and treatment of MIH. The introduction of national guidelines that serve as a reference manual for all continuing education courses would improve the management of MIH.

Abreviations

MIH: Molar Incisor Hypomineralization

GDPs: General Dental Practitioners

PDs: Pediatric Dentists

RMGIC: Resin-Modified Glass Ionomer

HSPM: Hypominerzlised second primary molar.

GIC: Glass Ionomer Cement

UK: United Kingdom.

SSC: Stainless Steel Crowns.

Declarations

Ethics and consent to participate.

The questionaire was anonimous and the consent to participate was written aceptting to answer the survey.

Consent for publication:

The authors warrant that the article titled: “Perception, knowledge and attitudes towards molar incisor hypomineralization among Spanish dentists: a cross-sectional study.”, has been submitted solely to BMC Oral Health and that is not currently under consideration for publication in another journal. The submitted work, is original. All of the named authors have been involved in the work leading to the publication of the paper and have read the paper before it submission for publication.

Competing Interest:

We declare that we have no proprietary, financial, professional or other personal interest of any nature or kind any product, service and/or company that could be construed as influencing the position presented in, or the review of, the manuscript entitled “Perception, knowledge and attitudes towards molar incisor hypomineralization among Spanish dentists: a cross-sectional study”.

Funding:

This research did not receive any specific grant from funding agencies in the public, commercial, or not-for-profit sectors.

Availability of Data and Materials:

The datasets used for the current study are available from the corresponding author on reasonable request.

Authors´contributions:

C.S.M., A.J.O.R. and Y.M.B investigated the idea of the study, developed de protocol and carried out the fieldwork. F.J.R.L conducted data analysis. A.P.S and A.P.P prepared figure and tables. All authors wrote and review the manuscript.

Aknowledgement:

The authors acknowledge to the College of Dentists of Murcia for facilitating dissemination of the survey among its members.

References

1. Weerheijm KL, Duggal M, Mejàre I, Papagiannoulis L, Koch G, Martens LC, Hallonsten AL. Judgement criteria for molar incisor hypomineralisation (MIH) in epidemiologic studies: a summary of the European meeting on MIH held in Athens. Eur J Paediatr Dent. 2003;4:110–3.
2. Elfrink ME, ten Cate JM, Jaddoe VW, Hofman A, Moll HA, Veerkamp JS. Deciduous molar hypomineralization and molar incisor hypomineralization. J Dent Res. 2012;91(6):551–5.
3. Weerheijm KL, Jälevik B, Alaluusua S. Molar-incisor hypomineralisation. Caries Res. 2001;35(5):390–1.
4. Serna C, Vicente A, Finke C, Ortiz AJ. Drugs related to the etiology of molar incisor hypomineralization: A systematic review. J Am Dent Asso. 2016;147(2):120–30.
5. Meligy O, Alaki SM, Allazzam SM. Molar-incisor hypomineralisation in children: a review of literature. J Oral Hyg Health. 2014;2:139.
6. Garg N, Jain AK, Saha S, Singh J. Essentiality of early diagnosis of molar incisor hypomineralization in children and review of its clinical presentation, etiology and management. Int J Clin Pediatr Dent. 2012;5(3):190–6.
7. Elfrink ME, Ghanim A, Manton DJ, Weerheijm KL. Standardised studies on Molar Incisor Hypomineralisation (MIH) and Hypomineralised Second Primary Molars (HSPM): a need. Eur Arch Paediatr Dent. 2015;16(3):247–55.
8. Gamboa GCS, Lee GHM, Ekambaram M, Yiu CKY. Knowledge, perceptions, and clinical experiences on molar incisor hypomineralization among dental care providers in Hong Kong. BMC Oral Health. 2018;18(1):217.

9. Hernández M, Boj JR, Espasa E, Peretz B. First Permanent Molars and Permanent Incisors Teeth by Tooth Prevalence of Molar-Incisor-Hypomineralisation in a Group of Spanish Schoolchildren. Acta Stomatol Croat. 2018;52(1):4–11.
10. Negre-Barber A, Montiel-Company JM, Boronat-Catalá M, Catalá-Pizarro M, Almerich-Silla JM. Hypomineralized Second Primary Molars as Predictor of Molar Incisor Hypomineralization. Sci Rep. 2016;6:31929. doi:10.1038/srep31929.
11. Martínez Gómez TP, Guinot Jimeno F, Bellet Dalmau LJ, Giner Tarrida L. Prevalence of molar-incisor hypomineralisation observed using transillumination in a group of children from Barcelona (Spain). Int J Paediatr Dent. 2012;22(2):100–9.
12. Garcia-Margarit M, Catalá-Pizarro M, Montiel-Company JM, Almerich-Silla JM. Epidemiologic study of molar-incisor hypomineralization in 8-year-old Spanish children. Int J Paediatr Dent. 2014;24(1):14–22.
13. Alanzi A, Faridoun A, Kavvadia K, Ghanim A. Dentists' perception, knowledge, and clinical management of molar-incisor hypomineralisation in Kuwait: a cross-sectional study. Oral Health. 2018;18:34.
14. Kopperud Simen E, Cecilie K, Pedersen G, Espelid I. Treatment decisions on Molar-Incisor Hypomineralization (MIH) by Norwegian dentists – a questionnaire study. BMC Oral Health. 2017;17:3.
15. Ghanim A, Morgan M, Mariño R, Manton D, Bailey D. Perception of molar-incisor hypomineralisation (MIH) by Iraqi dental academics. Int J Paediatr Dent. 2011;21(4):261–70.
16. Upadhyay S, Kumar G, Dhillon JK, Gill NC. Perception of Indian Dental Surgeons regarding Molar Incisor Hypomineralization. Int J Clin Pediatr Dent. 2018;11(2):116 121.
17. Silva MJ, Alhowaish L, Ghanim A, Manton D. Knowledge and attitudes regarding molar incisor hypomineralisation amongst Saudi Arabian dental practitioners and dental students. Eur Arch Paediatr Dent. 2016;17(4):215–22.
18. Crombie FA, Manton DJ, Weerheijm KL, Kilpatrick NM. Molar incisor hypomineralization: a survey of members of the Australian and New Zealand Society of Paediatric Dentistry. Aust Dent J. 2008;53(2):160–6.
19. Gambetta-Tessini K, Mariño R, Ghanim A, Calache H, Manton DJ. Knowledge, experience and perceptions regarding molar-incisor hypomineralisation (MIH) amongst Australian and Chilean public oral health care practitioners. BMC Oral Health. 2016;16(1):75. DOI 10.1186/s12903-016-0279-8.
20. Kalkani M, Balmer RC, Homer RM, Day PF, Duggal MS. Molar incisor hypomineralisation: experience and perceived challenges among dentists specialising in paediatric dentistry and a group of general dental practitioners in the UK. Eur Arch Paediatr Dent. 2016;17(2):81–8.
21. Tagelsir A, Dean JA, Eckert GJ, Martinez-Mier EA. U.S. Pediatric Dentists' Perception of Molar Incisor Hypomineralization. Pediatr Dent. 2018;40(4):272–8.

22. Knowledge,. Hussein AS, Ghanim AM, Abu-Hassan MI, Manton DJ. management and perceived barriers to treatment of molar-incisor hypomineralisation in general dental practitioners and dental nurses in Malaysia. Eur Arch Paediatr Dent. 2014;15(5):301–7.
23. Locker D, Grushka M. Response trends and nonresponse bias in a mail survey of oral and facial pain. J Public Health Dent. 1988;48:20–5.
24. Ghanim A, Manton D, Mariño R, Morgan M, Bailey D. Prevalence of demarcated hyomineralisation defects in second primary molars in Iraq. Int J Paediatr Dent. 2013;23:48–55.
25. Lygidakis NA, Wong F, Jälevik B, Vierrou AM, Alaluusua S, Espelid I. Best Clinical Practice Guidance for clinicians dealing with children presenting with Molar-Incisor-Hypomineralisation (MIH): An EAPD Policy Document. Eur Arch Paediatr Dent. 2010;11(2):75–81.
26. Jälevik B, Klingberg G. Treatment outcomes and dental anxiety in 18-year-olds with MIH, comparison with healthy controls-a longitudinal study. Int J Pediatr Dent. 2012;22(2):85–91.
27. Bozal CB, Kaplan A, Ortolani A, Cortese SG, Biondi AM. Ultrastructure of the surface of dental enamel with molar incisor hypomineralization (MIH) with and without acid etching. Acta Odontol Latinoam. 2015;28:192–8.
28. Lagarde M, Vennat E, Attal J-P, Dursun E. Strategies to optimize bonding of adhesive materials to molar-incisor hypomineralization-affected enamel: A systematic review. Int J Paediatr Dent. 2020. https://doi.org/10.1111/ipd.12621.
29. Kotsanos N, Kaklamanos EG, Arapostathis K. Treatment managements of first permanent molars in children with molar-incisor hypomineralisation. Eur J Paediatr Dent. 2005;6(4):179–84.
30. Elhennawy K, Schwndicke F. Managing molar-incisor hypomineralization: A systematic review. J Dent. 2016;55:16–24.

Figures

	FLUORIDE VARNISH	GIC	COMPOSITE	EXTRACTION	DON´T KNOW/NO ANSWER
GDPs	16,3 %	56,1 %	17,7 %	1,37 %	8,2 %
PDs	9,1 %	69,1 %	18,5 %	0 %	3,1 %

Figure 1

In clinical case 1, dentists were asked which treatment they would prefer for a semi-erupted primary molar with moderate MIH, post-eruptive fracture and sensitivity in the tooth in a seven-year-old patient. The options were: (1) Fluoride varnish, (2) Restoration with glass ionomer cement (GIC) (3) Restoration with resin composite (4) Extraction of the tooth (5) I am not sure of the best option.

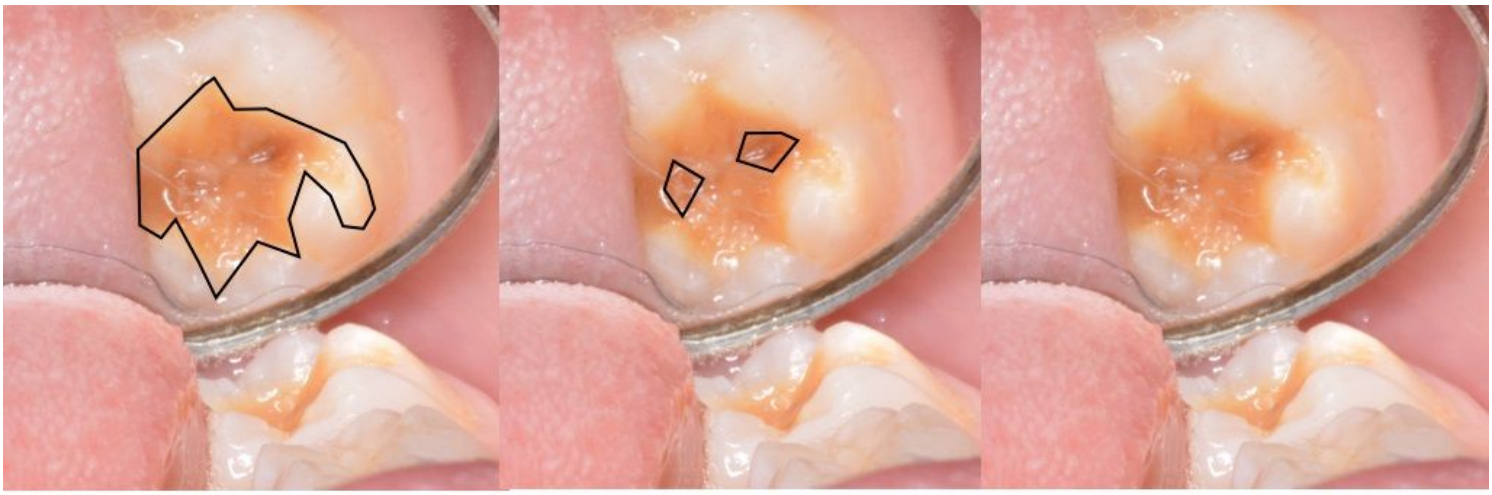

1.Eliminate all tissue affected by MIH until the healthy margin is reached	2. Eliminate only the most affected tissue	3. Do not eliminate any dental tissue
a. Composite restoration GDP (n 40; 27,4%) PD (n 15; 25%) b. Glass Ionomer Restoration GDP (n 28; 19,2%) PD (n 13; 20,3%) c. Temporary restoration GDP (n4; 2,7%) PD (n 0; 0%)	a. Composite restoration GDP (n 10; 6,7%) PD (n 4; 6,2%) b. Glass Ionomer Restoration GDP (n 75; 51,3%) PD (n 20; 31,2%) c. Temporary restoration GDP (n4; 2,7%) PD (n 0; 0%)	a. Composite restoration GDP (n 6; 4%) PD (n 0; 0%) b. Glass Ionomer Restoration GDP (n 25; 17%) PD (n 26; 40,5%) c. Temporary restoration GDP (n 6; 4%) PD (n 6; 9,3%)

Figure 2

In clinical case 2, dentists were asked about the best treatment for a delimited brown opacity without post-eruptive enamel fracture. The options were: (1A) Eliminate all tissue affected by MIH and restore with resin composite; (1B) Eliminate all affected tissue and restore with glass ionomer cement (GIC); (1C) Eliminate all affected tissue and make a temporary restoration; (2A) Eliminate only the most affected tissue and restore with composite; (2B) Eliminate only the most affected tissue and restore with glass ionomer; (2C) Eliminate only the most affected tissue and make a temporary restoration; (3A) Do not eliminate any dental tissue and restore with composite ;(3B) Do not eliminate any dental tissue and restore with glass ionomer (GIC); (3C) Do not eliminate any dental tissue and make a temporary restoration.

Supplementary Files

This is a list of supplementary files associated with this preprint. Click to download.

- SupplementaryFile1.pdf