Primary Hepatic Choriocarcinoma in a Male Patient: A Case Report and Literature Review

Ke Zhao

Department of Thoracic Surgery, Peking Union Medical College Hospital, Chinese Academy of Medical Sciecnce and Peking Union Medical College https://orcid.org/0000-0001-7910-2453

Ke Rao

Peking Union Medical College Hospital

Xin Chen

Peking Union Medical College Hospital Department of Obstetrics and Gynecology

Si Chen

Peking Union Medical College Hospital Department of Anesthesiology

Haifeng Xu (xuhf781120@sina.com)

Peking Union Medical college Hospital, Chinese Academy of Medical Science & Peking Union Medical College https://orcid.org/0000-0002-6976-1129

Case report

Keywords: choriocarcinoma, liver tumor, hepatic choriocarcinoma, case report

Posted Date: March 10th, 2021

DOI: https://doi.org/10.21203/rs.3.rs-284626/v1

Abstract

Background

Choriocarcinoma is a rare malignant tumor and rarely occurs outside the gonads. Primary hepatic choriocarcinoma is more infrequent, with hidden clinical manifestations, rapid progress, and extremely poor prognosis. Only more than 10 cases were publicly reported in the world. Therefore, there is still a lack of deep understanding of the diagnosis and treatment of the disease.

Case presentation

We report a case of primary hepatic choriocarcinoma in a man diagnosed by pathology. A 65-year-old male patient presented with fever and anorexia, nothing but mild jaundice of the skin and sclera was found on physical examination. Abdominal enhanced magnetic resonance imaging (MRI) showed a huge mass in the right hepatic lobe. Fludeoxyglucose-positron emission tomography-computed tomography (FDG-PET/CT) scan showed increased uptake in the liver and sigmoid colon and no uptake in the testes. The patient underwent the right hepatectomy, and postoperative pathology showed that the tumor was primary hepatic choriocarcinoma. Then he received one course of adjuvant chemotherapy. Then he developed severe myelosuppression and was transferred to the intensive care unit for further treatment. He eventually died of severe liver failure about 100 days after surgery. Primary hepatic choriocarcinoma is extremely rare, and its diagnosis is challenging.

Conclusions

Primary hepatic choriocarcinoma is a rare and highly malignant tumor with a poor prognosis. We believe that this differential diagnosis should be considered in liver tumor patients. The effective treatment for this disease is still to be explored.

Introduction

Choriocarcinoma is a rare malignant tumor that originates from germ cells. The specific feature of patients with choriocarcinoma is elevated serum human chorionic gonadotropin (hCG) levels. Choriocarcinoma typically occurs in the gonad and uterus in women of child-bearing age. Less commonly, choriocarcinoma can occur in extragonadal sites. It is rare in men, accounting for only 1% of all germ cell tumors(1). Most previously reported primary extragonadal choriocarcinomas are in the midline structure, such as mediastinum and stomach(2–4). Only a minimal number of such choriocarcinomas occur in the liver primarily. And we searched the English and Chinese databases including Pubmed, Embase, Wanfang Data, and China National Knowledge Infrastructure (CNKI) with the keywords of "choriocarcinoma," "liver choriocarcinoma," "hepatic choriocarcinoma," we found that a total of 17 primary hepatic choriocarcinoma cases have been published publicly(5–17). The existing reports were mainly from Asia. Therefore, the understanding of the disease is very fragmented, and neither the

pathogenesis nor the treatment is discussed in-depth and systematically. We report the current case of a 65-year-old male patient with primary hepatic choriocarcinoma.

Case Presentation

Chief complaints

A 65-year-old Asian man presented to the emergency department due to anorexia, which lasted for three weeks, and fever for four days.

History of present illness

The patient developed anorexia symptom for three weeks accompanied by the jaundice of the skin and sclera, without nausea, vomiting, fever, abdominal pain, abdominal distension, or other uncomfortable symptoms. 4 days before admission, the patient developed fever without chills, the temperature could be as high as 40℃. He received anti-inflammatory, antipyretic, and fluid rehydration treatments in the outpatient clinic. The patient still complained of anorexia when he was admitted to the hospital, he still had a low-grade fever below 38℃ every afternoon, and he lost 5 kg in weight in the last month.

History of past illness

The patient suffered from type 2 diabetes and hypertension for more than ten years but denied a history of hepatitis and allergy.

Personal and family history

The patient also had a smoking history of 40 years, 20 cigarettes a day, a history of drinking 40 years, and 150ml liquor a day. The patient denied a family history of liver cancer and other tumors.

Physical and laboratory examinations

Only mild jaundice of the skin and sclera was found on physical examination. The patient's laboratory examinations showed his alpha-fetoprotein (AFP) rose to 98.75ng/ml. After admission, the patient underwent a hepatitis virus test, and the result suggested hepatitis B core antibody (HBcAb) positive, hepatitis B emission antibody (HBeAb) positive, hepatitis B surface antigen (HBsAg) positive, whose value are 10.82S/CO, 0.03S/CO and 76.56IU/ml respectively.

Imaging examinations

His abdominal enhanced MRI showed a mixed density high signal on T2 weighted imaging (T2WI), a high signal on diffusion weighted imaging (DWI), and a low signal on T1 weighted imaging (T1WI), which was unevenly strengthened at the edge of the lesion during the enhanced scanning arterial phase, and decreased during the portal and delayed phase. The FDG-PET/CT scan showed abnormally increased uptake in the liver, and sigmoid colon, whose standard uptake value maximum (SUVmax) was 19.7 and 9.6, respectively. Therefore, he underwent a colonoscopy to clarify the lesion's nature, which showed there was no colon cancer.

To identify whether the patient can tolerate the right hepatectomy, the patient also received the indocyanine green (ICG) excretion test and liver volume measurement in abdominal CT, which showed ICG clearance is 0.105/min, the 15-minute retention rate is 19.9%, the left liver volume is 626cm^3, and the right liver volume without tumor is 786cm^3.

Final diagnosis

Histological findings of the resected tumor showed poorly differentiated cancer with large necrosis areas, and syncytiotrophoblast and vascular tumor thrombus can be found. Immunohistochemical results showed AFP (-), CK7(partial+), hepatocyte(-), Ki-67(index80%), hCG (syncytiotrophoblast+), GATA3(+), HpL (syncytiotrophoblast+), P63(partial+), P40(partial+) and SALL-4(weak+), which highly supported the diagnosis of choriocarcinoma rather than hepatocellular carcinoma.

Treatment

Based on the patient's clinical manifestations and examination results, we believed that the patient was more likely to suffer primary hepatic carcinoma. And according to the patient's preoperative examination results, we thought that he could tolerate the right hepatectomy and performed the operation for him. After the procedure, he received treatment including nutritional support, acid suppression, liver protection, and anti-infection, and his preoperative symptoms disappeared entirely.

Given this surprising pathological result, he underwent FDG-PET/CT again about a month after surgery, which revealed multiple nodules with increased uptake in the liver, lungs, and upper abdominal wall of both sides. He also tested his serum hCG, and the results suggested hCG +DT rose to 8453.0 mIU/ml at the same time, and this number rose to 17174 mIU/ml a week later.

Then the liver surgeons and gynecologists of our hospital formulated the chemotherapy regimen for this patient, which is FAEV regimen including vincristine (VCR) 2mg, floxuridine (FUDR) 1375mg*1d+1250mg*4d, dactinomycin (KMS) 400ug*1d+300ug*4d and etoplatin (VP-16) 160mg*5d. He underwent the first chemotherapy course 37 days after surgery, and he denied any uncomfortable symptoms during the process.

Outcome and follow-up

On the third day after the end of chemotherapy, the patient's blood routine test showed third-degree myelosuppression, WBC 1.57×109/L, neutrophil (NEUT) 0.73×109/L, platelet (PLT) 86×109/L. Despite immediately applying recombinant human granulocyte stimulating factor, recombinant human interleukin-11, recombinant human thrombopoietin, and platelet transfusion, the patient's myelosuppression still developed rapidly, and his blood routine result was PLT 24×109/L, WBC 0.36×109/L, NEUT 0.01×109/L 5 days later, and high fever and the symptoms of shock appeared, so he was transferred to the intensive care unit (ICU) for further treatment. The patient received anti-shock, anti-infection, and liver protection treatments at ICU, but the patient's condition did not improve significantly, and he was still in severe liver failure. After a brief treatment in the ICU, the patient was transferred to a lower-level hospital to continue receiving limited symptomatic treatment and hospice care. He died of liver failure about 100 days after the operation.

Discussion And Conclusions

Choriocarcinoma is a rare invasive trophoblastic malignancy, most commonly found in women in pregnancy; male patients only occupy a small percentage of all patients. For male adults, it is most commonly seen in the testes(1). Choriocarcinoma that originates from the liver is even rarer. We searched the English and Chinese databases such as Pubmed, Embase, Wanfang Data, and CNKI, then found that a total of 17 primary hepatic choriocarcinoma cases have been published publicly(5–18); this one is the 18th case.

Based on past cases, we can draw some conclusions. The primary hepatic choriocarcinoma patients are mostly Asians, and male patients accounted for 72.2% (13/18). More than half of patients have symptoms of abdominal pain. Besides, anorexia, fever, and abdominal distension are also common symptoms. Although hCG is highly specific for the diagnosis of choriocarcinoma, not all patients were tested for serum hCG at the initial visit due to the rarity of primary liver choriocarcinoma. However, as long as the test is performed, even if surgery or chemotherapy has been completed, hCG is higher than the normal value, and individual differences are considerable. Some patients have also been tested for other tumor markers. Except for the present case, the AFP value of the remaining patients has not increased. This abnormality may be explained as the consequence of patients with cirrhosis, but the AFP decreased to an average level after surgery, which is puzzling.

Due to its extremely low morbidity, there is currently no standardized treatment, and the significance of surgery and chemotherapy is not clear. Seven patients had undergone surgical treatment before. However, the surgical procedures are not uniform, and the scope of resection depends on the size of the tumor and the extent of invasion. The smallest resection was hepatic tumor resection, and the largest one was extended left hepatectomy with partial resection of the diaphragm, cholecystectomy, and hepaticojejunostomy. In this case, the patient underwent the right hepatectomy, and his performance status improved significantly after surgery.

As already mentioned, we ultimately selected the FAEV chemotherapy regimen for him; this regimen is highly cytotoxic and has never been used in similar patients before. Based on previous experience in treating choriocarcinoma and the patient's condition, we made this chemotherapy regimen. The patient still has a high hCG level after the operation, and multiple metastatic nodules are found in the postoperative PET/CT, which indicated that the patient's condition developed very quickly, so we chose a highly cytotoxic quadruple chemotherapy regimen. However, judging from the patient's treatment results, this regimen may be terminated early due to serious side effects and may not be the best choice for such patients. Also, some clinicians chose to use the EMA/CO (Etoposide, Methotrexate, Actinomycin D, Cyclophosphamide, Vincristine) regimen, whose effect varies greatly(10, 15). And some literature pointed out that vinblastine and cisplatin are popular substances(13).

Most previously reported tumors have similar histopathological characteristics, mostly hemorrhagic with necrosis on the cut surface. The tumor cells consisted of typical syncytiotrophoblastic cells mainly. Immunohistochemical studies are more conducive to the confirmation of this diagnosis. All cases that reported immunohistochemistry results were positive for hCG and HpL staining, specific(5–8, 10–17). Its Ki-67 proliferation index is very high, with an average value of about 74%(50%-90%)(10, 14, 17), which shows that this tumor's growth is very active. Most patients, including this one, did not stain positive for AFP, and only Heaton(5) reported two patients with positive staining for AFP.

The lack of tumor-specific interstitium can lead to an early vascular invasion, leading to distant metastasis(19). It is also because of this feature that primary hepatic choriocarcinoma is highly malignant and has a poor prognosis. In all cases where a clear outcome is reported, the median overall survival (OS) of the disease is 2.5 months. And the most prolonged OS in these patients is only 18 months, and this one underwent surgical resection, seven courses of chemotherapy of EMA-CO, and four courses of EMA-EP(15). The results of this case confirmed the previous clinical experience, and the rapid progression of the disease led to an inferior prognosis.

All in all, primary hepatic choriocarcinoma is a rare and highly malignant tumor. Among middle-aged male patients with aggressive liver tumors, in addition to common liver tumor markers, serum hCG levels should also be considered. As liver surgeons, we should be alert to this rare differential diagnosis. The prognosis of the disease is inferior, and there is no standardized treatment proven to be effective at present. The mechanism and effective treatment of this disease are still to be explored.

Abbreviations

hCG, human chorionic gonadotropin; CNKI, China National Knowledge Infrastructure; AFP, alpha-fetoprotein; HBcAb, hepatitis B core antibody; HBeAb, hepatitis B emission antibody; HBsAg, hepatitis B surface antigen; T2WI, T2 weighted imaging; DWI, diffusion weighted imaging; T1WI, T1 weighted imaging; MRI, magnetic resonance imaging; FDG-PET/CT, Fludeoxyglucose-positron emission tomography computed tomography; SUVmax, standard uptake value maximum; ICG, indocyanine green;

VCR, vincristine; FUDR, floxuridine; KMS, Dactinomycin; VP-16, etoplatin; NEUT, neutrophil; PLT, platelet; ICU, intensive care unit; OS, overall survival.

Declarations

Ethics approval and consent to participate

Not applicable

Consent for publication

The patient has approved the consent for publication of this case report.

Availability of data and materials

The datasets used and/or analyzed during the current study are available from the corresponding author on reasonable request.

Competing interests

The authors declare that they have no competing interests.

Funding

Not applicable

Authors' contributions

Ke Zhao is responsible for conception and design, collection and assembly of data, data analysis and interpretation, and manuscript writing.

Ke Rao is responsible for data analysis and interpretation, and manuscript writing.

Xin Chen is responsible for data analysis and interpretation, and manuscript writing.

Si Chen is responsible for data analysis and interpretation.

Haifeng Xu is responsible for administrative support, provision of study materials or patients, and revised manuscript.

All authors read and approved the final manuscript.

Acknowledgements

Not applicable

References

1. Scholz M, Zehender M, Thalmann GN, Borner M, Thöni H, Studer UE. Extragonadal retroperitoneal germ cell tumor: evidence of origin in the testis. Annals of oncology: official journal of the European Society for Medical Oncology. 2002;13(1):121–4.
2. Moran CA, Suster S. Primary mediastinal choriocarcinomas: a clinicopathologic and immunohistochemical study of eight cases. Am J Surg Pathol. 1997;21(9):1007–12.
3. Kobayashi A, Hasebe T, Endo Y, Sasaki S, Konishi M, Sugito M, et al. Primary gastric choriocarcinoma: two case reports and a pooled analysis of 53 cases. Gastric cancer: official journal of the International Gastric Cancer Association the Japanese Gastric Cancer Association. 2005;8(3):178–85.
4. Luo M, Peng H, Song M, Zhou Q, Long Y, Chen P. [Primary mediastinal choriocarcinoma: A case report and literature review]. Zhong nan da xue xue bao Yi xue ban = Journal of Central South University Medical sciences. 2017;42(10):1222–7.
5. Heaton GE, Matthews TH, Christopherson WM. Malignant trophoblastic tumors with massive hemorrhage presenting as liver primary. A report of two cases. Am J Surg Pathol. 1986;10(5):342–7.
6. Fernández Alonso J, Sáez C, Pérez P, Montaño A, Japón MA. Primary pure choriocarcinoma of the liver. Pathology, research and practice. 1992;188(3):375-7; discussion 8–9.
7. Takemori Y, Noda Y, Ohta G. [Primary hepatic choriocarcinoma]. Ryoikibetsu shokogun shirizu. 1995(7):378–80.
8. Arai M, Oka K, Nihei T, Hirota K, Kawano H, Kawasaki T, et al. Primary hepatic choriocarcinoma–a case report. Hepato-gastroenterology. 2001;48(38):424–6.
9. Wang Q, Ma Q, Wang C. A case of primary choriocarcinoma of liver. JOURNAL OF THE FOURTH MILITARY MEDICAL UNIVERSITY. 2002;23(21):1936-.
10. Shi H, Cao D, Wei L, Sun L, Guo A. Primary choriocarcinoma of the liver: a clinicopathological study of five cases in males. Virchows Archiv: an international journal of pathology. 2010;456(1):65–70.
11. Bakhshi GD, Borisa AD, Bhandarwar AH, Tayade MB, Yadav RB, Jadhav YR. Primary hepatic choriocarcinoma: a rare cause of spontaneous haemoperitoneum in an adult. Clinics practice. 2012;2(3):e73.
12. Sekine R, Hyodo M, Kojima M, Meguro Y, Suzuki A, Yokoyama T, et al. Primary hepatic choriocarcinoma in a 49-year-old man: report of a case. World journal of gastroenterology. 2013;19(48):9485–9.
13. Malikov M, Shin E, Cho JY, Han H-S, Yoon Y-S, Choi YR, et al. Primary hepatic choriocarcinoma in a female patient. Korean J Clin Oncol. 2015;11(1):33–6.
14. Fukagawa A, Fujita N, Ohira K, Fujimoto H, Goto N, Nozawa A. Primary hepatic choriocarcinoma in an 83-year-old woman. Pathology international. 2017;67(8):425–30.
15. Ahn Y, Kim JH, Park CS, Kim TE, Hwang S, Lee SG. Multidisciplinary approach for treatment of primary hepatic choriocarcinoma in adult male Patient. Annals of hepato-biliary-pancreatic surgery.

2018;22(2):164–8.

16. Kohler A, Welsch T, Sturm AK, Baretton GB, Reissfelder C, Weitz J, et al. Primary choriocarcinoma of the liver: a rare, but important differential diagnosis of liver lesions. Journal of surgical case reports. 2018;2018(4):rjy068.
17. Li S, Qiu J, Deng K. A case of primary choriocarcinoma of the liver. Journal of Bengbu Medical College. 2020;45(3):420,3.
18. Fine G, Smith RW Jr, Pachter MR. Primary extragenital choriocarcinoma in the male subject. Case report and review of the literature. Am J Med. 1962;32:776–94.
19. Inagaki Y, Sugimoto K, Shiraki K, Yoshizawa N, Tameda M, Ogura S, et al. Sarcomatous hepatocellular carcinoma with remittent fever. Intern Med (Tokyo Japan). 2012;51(21):3025–9.

Figures

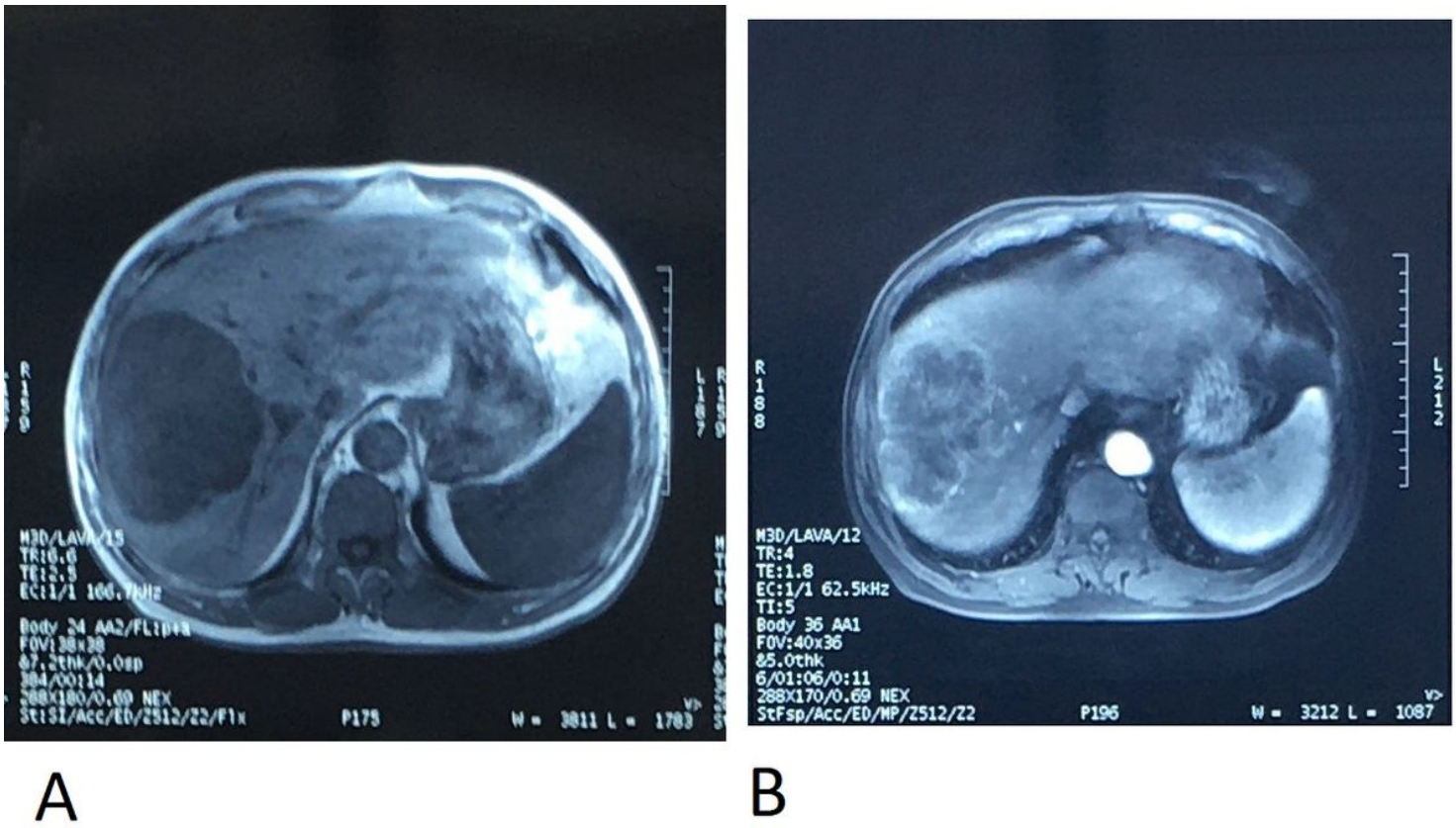

Figure 1

The preoperative enhanced MRI of this patient. A low signal on T1WI (Figure-1A) was unevenly strengthened at the lesion's edge during the enhanced scanning arterial phase (Figure-1B).

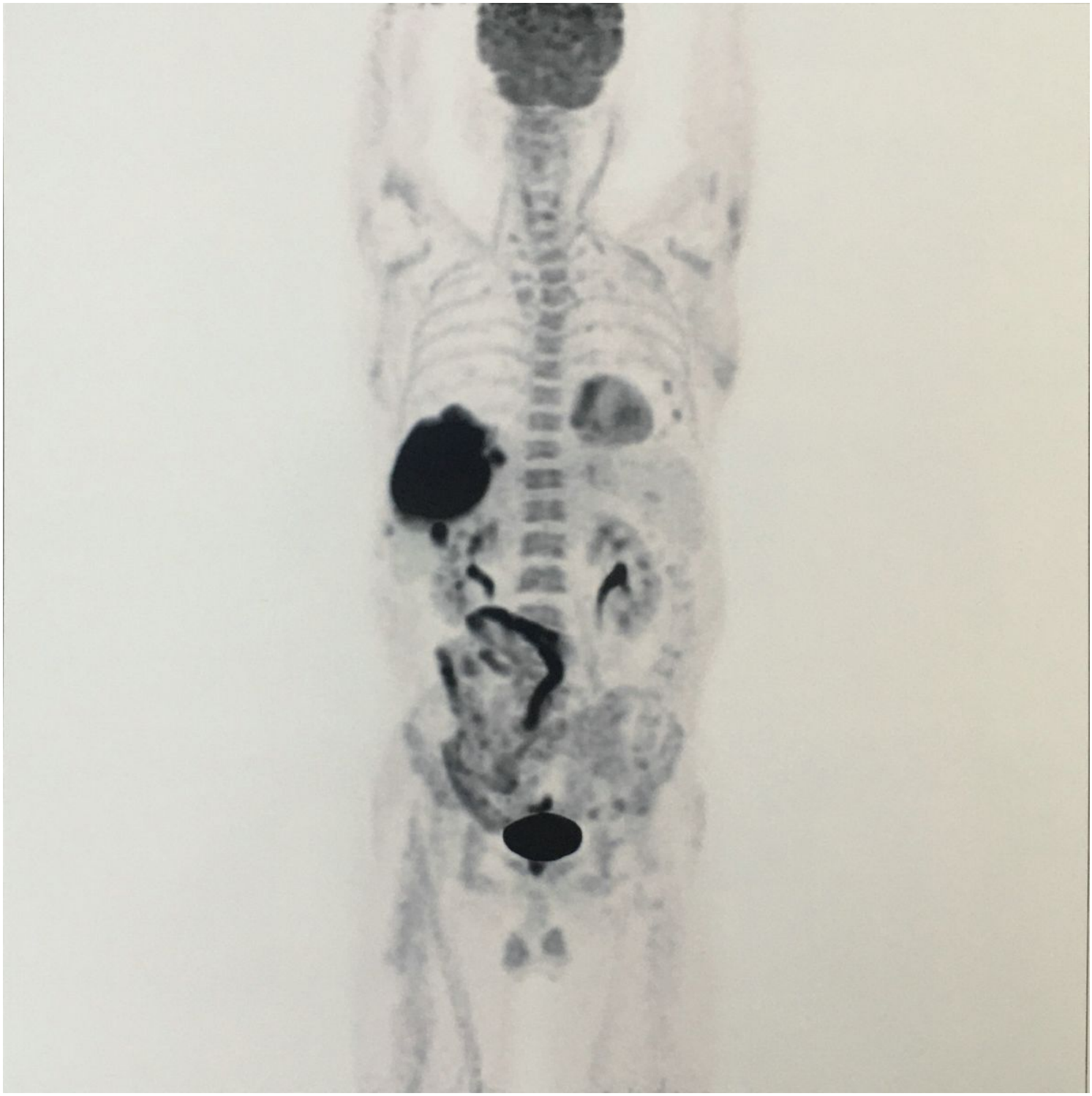

Figure 2

The preoperative FDG-PET/CT of this patient, which showed high uptake in the liver.