Long-term Survival Following Radiofrequency Ablation of Lung Metastases in an Elderly Patient With Calcaneal Osteosarcoma: a Case Report and Review of the Literature

Hiroyuki Futani (h-futani@hyo-med.ac.jp)
Hyogo College of Medicine https://orcid.org/0000-0003-4669-6210

Haruyuki Takaki
Hyogo College of Medicine: Department of Radiology

Tatsuo Sawai
Hyogo College of Medicine Department of Orthopaedic Surgery

Junichi Taniguchi
Hyogo College of Medicine: Department of Radiology

Yasukazu Kako
Hyogo College of Medicine: Department of Radiology

Yoshi-Hiro Ide
Hyogo College of Medicine: Department of Surgical Pathology

Koichiro Yamakado
Hyogo College of Medicine: Department of Radiology

Toshiya Tachibana
Hyogo College of Medicine Department of Orthopaedic Surgery

Case report

Keywords: Osteosarcoma, radiofrequency ablation, metastasis, lung

Posted Date: March 6th, 2021

DOI: https://doi.org/10.21203/rs.3.rs-285306/v1

Abstract

Background: Lung metastases are the primary cause of death from osteosarcomas. Complete resection of lung metastases can prolong the survival. However, complete surgical resection in elderly patients is often difficult due to high risk of peri-operative complications. Radiofrequency ablation (RFA) is a minimally invasive technique to destroy tumor nodules using heat. Here, we present an elderly patient with osteosarcoma in calcaneus a scapular osteochondroma, who metachoronusly developed multiple lung metastases. Subsequently, he has been surviving a relatively long period by the use of percutaneous computed tomography (CT)-guided lung RFA against his lung metastases.

Case presentation: A 74-year-old male presented with 1-year history of heel pain. Imaging analysis demonstrated a mixture of osteolytic and osteosclerotic lesions in the calcaneus with extraskeletal lesions. The histology of the biopsy specimen showed osteoid matrix with malignant spindle cells, which was diagnosed as a conventional high-grade osteosarcoma. Below-knee amputation was performed. However, 6 lung metastases were found in both lungs 1 year after surgery. During 4.5 years from the initial percutaneous CT-guided lung RFA, 18 lung metastases were treated in 8 procedures. Lung RFA was performed under moderate sedation and local anesthesia. The most frequent complication was pneumothoraxes in 3 procedures followed by pleuritis with pneumothorax in 1 procedure. Chest tube drainage was required in 2 of 8 (25%) lung RF procedures. Mean duration of hospital stay for lung RFA was 5.3 ± 2.1 days (range, 3-10 days). The patient has been alive with disease for 5.5 years after initial surgery.

Conclusion: Our experience indicates that lung RFA is effective for elderly patients with lung metastases of osteosarcoma without serious complications.

Background

Osteosarcoma is a high-grade malignant bone neoplasm that commonly occurs in the metaphysis of long bones in the second and third decade of life [1]. Despite the advent of combined surgical and chemotherapeutic interventions, the prognosis of patients with lung metastases of osteosarcomas is still poor [2], especially in patients older than 65 years [3, 4]. Complete resection of lung metastases can improve life prognosis [5]. However, metastasectomy in elderly patients is often performed with considerable hesitation due to lack of adequate respiratory reserve, high risk of perioperative complications, or other medial co-morbidities [6].

Radiofrequency ablation (RFA) is a technique to destroy tumor nodules using heat. The major advantage of RFA is a minimally invasive and relatively safe technique. Recently, a few papers reported the usefulness of this technique against lung metastases of osteosarcomas [7–9]. However, the feasibility of this technique has not been reported for elderly patients.

Here, we describe an elderly patient with osteosarcoma in calcaneus, who metachoronusly developed multiple lung metastases. Subsequently, he has been surviving a relatively long period (5.5 years) by the

use of percutaneous CT-guided lung RFA against his lung metastases.

Case Presentation

A 74-year-old male presented with a right heel pain for 1 year. A tumor was found by radiography taken at a regional hospital when he noted increased heel pain. At presentation of our department, physical examination showed tenderness at the medial and lateral aspects of the calcaneal body. Radiography revealed an ill-defined osteolytic and osteoblastic lesion in the calcaneus with extension into soft tissues on the plantar aspect (Fig. 1A, B). Computed tomography (CT) images clearly demonstrated an expanding osteolytic and osteoblastic lesion with extra-osseous lesions (Fig. 2). Magnetic resonance imaging (MRI) revealed a 2.8 x 2.5 x 1.8 cm well-defined mass. The inferior cortical margin was destroyed with extra-osseous tumor. An area of low signal intensity was found by T1-weighted images (Fig. 3A). On T2-weighted images, the tumor had a high signal intensity area including a low signal intensity area (Fig. 3B). Those findings indicated a malignant tumor. Furthermore, positron emission tomography (PET)/CT images clearly demonstrated an abnormal fluorodeoxyglucose F 18 (18F-FDG) uptake of the distal aspect of the left femur with maximum standardized uptake (SUVmax) value of 14.81, indicating a malignant bone tumor (Fig. 4). No evidence of distant metastases was found.

A needle biopsy was performed. The histology of the specimen showed osteoid matrix with malignant spindle cells, which was diagnosed as a conventional high-grade osteosarcoma (Fig. 5). Neoadjuvant chemotherapy was not applicable since adverse effects were expected due co-morbidities of hypertension, diabetes mellitus, and renal dysfunction in addition to high age. A right below-knee amputation was performed to achieve a wide margin. Two months postoperatively, the patient regained the ability to walk with lower limb prosthesis.

However, 6 lung metastases with a mean diameter of 6.3 ± 2.5 mm (range, 4–11 mm) were found in both lungs at 1 year after surgery. Surgical intervention for lung metastases was abandoned because of tumor multiplicity and high-risk surgery. Therefore, lung RFA was chosen to treat lung metastases. Lung RFA was performed under moderate sedation and local anesthesia. Real-time CT fluoroscopy (SOMATOM, Siemens, Forchheim, Germany) was used to place the RF electrode in the tumors. An internally cooled electrode (Cool-Tip RF Ablation System, Covidien, Boulder, CO, USA) was used for the procedures. After the electrode was connected with the generator (Series CC, Covidien, Boulder, CO, USA), the RF energy was applied for 10–12 minutes at each site of the tumors using an impedance-control algorithm. The 6 lung metastases were treated by 2 RFA procedures, 3 in each procedure (Fig. 6).

Six months after initial lung RFA, new lung metastases developed. Therefore, additional lung RFA was performed. In 4.5 years from the initial lung RFA, a total of 18 lung metastases with a mean diameter of 10.7 ± 6.8 mm (range, 4–25 mm) were treated in 8 lung RF procedures. The most frequent complication was pneumothoraxes in 3 procedures followed by pleuritis with pneumothorax in 1 procedure. Chest tube drainage was required in 2 of 8 (25%) lung RF procedures. Mean duration of hospital stay for lung RFA was 5.3 ± 2.1 days (range, 3–10 days). Due to the large tumor embolism of right inferior pulmonary vein,

removal of the vein and the right lower lobectomy were also required. The patient has been alive with disease for 5.5 years after the initial surgery.

Discussion

Recently, the number of osteosarcomas has been increasing in elderly patients due to human longevity. In a nationwide Japanese database from 2006 to 2013, 183 out of 1497 patients (22%) with osteosarcomas were found in the age of more than 65 years old [4]. The need for studies on elderly patients with osteosarcomas is therefore increasing. Several papers have reported on poor prognosis of the elderly patients with osteosarcomas [3, 4, 10]. Longhi et al. reported that the median survival and 5-year overall survival were 19 months and 22%, respectively, in 43 patients who had high-grade osteosarcoma and were older than 65 years.

Lung metastases are the primary cause of death from osteosarcomas. Complete surgical resections of all pulmonary lesions contribute to prolonged survival [5]. However, surgical resection in elderly patients with osteosarcomas is not always applicable. In fact, multiple surgical series have reported greater perioperative mortality in the elderly [11, 12].

Percutaneous CT guided RFA has been reported to provide a safe and effective minimally invasive treatment for lung metastases [13]. Lung RFA was introduced in 2000 [14], and applied to patients with osteosarcoma in 2009 [9]. Thereafter, several authors have reported the feasibility of this technique in patients with lung metastases from osteosarcomas (Table 1). However, no paper has reported any patient older than 65 years with high-grade osteosarcoma and with lung metastases treated by percutaneous CT-guided lung RFA. In addition, the importance of the present case is the longest follow-up among patients with osteosarcomas treated by this technique (Table 1).

In our institute, RFA is applied to tumor size of 3 cm or less. Basically, the electrode is placed in the center of the tumor when the tumor size is 2 cm or less. When the tumor size is larger than 2 cm, the electrode is placed sequentially at 2–4 different sites in the tumor based on size and shape [13]. A maximum of 3 lung tumors, developing in one lung, can be treated on the same day.

The advantage of RFA is that it allows ablation of tumors without major damage to the surrounding normal parenchyma. It has been demonstrated that RFA does not change lung function parameters and is possible even in patients with severe respiratory dysfunction [15]. In addition, this technique can be performed percutaneously under moderate sedation and local anesthesia. It can be applied several times in patients with severe co-morbidities or/and elderly patients. In the present case 8 lung RF procedures could be performed.

The risk of failure of RFA is in patients with large pulmonary lesions. In such a case, surgical resection should be considered. The advantages and disadvantages of RFA and surgical resection for the patient with sarcoma lung metastases are summarized in Table 2. The usefulness of combination therapy of

RFA and surgical resection has been shown against lung metastases for improvement of curability [7, 16].

The most frequent complication is pneumothorax requiring chest tube drainage, which occurs in approximately in 10–23% of the procedures [6–8]. Nakamura et al. reported the feasibly of RFA in elderly patients more than 65 years old with soft tissue and bone sarcomas. In their series, chest tube drainage was required in 15 out of 65 procedures (23%) in 12 patients, which was not statistically different from the results of sarcoma patients younger than 65 years. In the present osteosarcoma case, pneumothorax occurred in 4 of 8 (50%) and chest tube drainage was needed in 2 of 8 (25%) lung RF procedures. However, no serious clinical deterioration was found.

In conclusion, percutaneous CT-guided lung RFA is a less invasive and safe technique for the elderly patient of more than 65 years, with lung metastases of osteosarcoma. The present patient has been alive with disease for 5.5 years after initial surgery.

Abbreviations

RFA: Radiofrequency ablation; MRI: Magnetic resonance imaging; PET: positron emission tomography; 18F-FDG: SUVmax; fluorodeoxyglucose; maximum standardized uptake

Declarations

Ethics approval and consent to participate

The need for approval was waived by the ethics committee of Hyogo College of Medicine.

Consent for publication

Written consent was obtained from the patient and his family for publication of this study.

Availability of data and materials

All data generated or analyzed during this study are included in this published article.

Competing interests

No authors have any conflict of interest in regard to this study.

Authors’ contributions

HF and TS performed surgery of limb. HF, HT, JT, YK and YY performed CT guided RFA. YI made histological diagnosis. HF and HT collected the patient’s clinical data, performed literature review, and drafted the manuscript. KY and TT assisted in data collection and literature review. ST, JT, YK, YI, KY, and TT helped revision of the manuscript. All authors read and approved the final manuscript.

Funding

None of the authors have any sources of funding to disclose.

Acknowledgements

This work was supported in part by a Grant-in-Aid (C] (20K09444] from the Ministry of Education, Culture, Sports, and Science.

References

1. Unni KK, Inwards CY, editors. Dahlin's Bone Tumors: General Aspects and Data on 10,165 Cases. 6th. Lippincott; Williams & Wilkins, Philadelphia, PA. Osteosarcoma; pp 122-57, 2010
2. Kempf-Bielack B, Bielack SS, Jürgens H, Branscheid D, Berdel WE, Exner GU, et al. Osteosarcoma relapse after combined modality therapy: an analysis of unselected patients in the Cooperative Osteosarcoma Study Group (COSS). J Clin Oncol. 2005;23(3):559-68.
3. Longhi A, Errani C, Gonzales-Arabio D, Ferrari C, Mercuri M. Osteosarcoma in patients older than 65 years. J Clin Oncol. 2008;26(33):5368-73.
4. Fukushima T, Ogura K, Akiyama T, Takeshita K, Kawai A. Descriptive epidemiology and outcomes of bone sarcomas in adolescent and young adult patients in Japan. BMC Musculoskelet Disord. 201819(1):297-304.
5. Bacci G, Rocca M, Salone M, Balladelli A, Ferrari S, Palmerini E, et al. High grade osteosarcoma of the extremities with lung metastases at presentation: treatment with neoadjuvant chemotherapy and simultaneous resection of primary and metastatic lesions. Surg Oncol. 2008;98(6):415-20.
6. Nakamura T, Matsumine A, Yamakado K, Takao M, Uchida A, Sudo A. Clinical significance of radiofrequency ablation and metastasectomy in elderly patients with lung metastases from musculoskeletal sarcomas. J Cancer Res Ther. 2013;9(2):219-23.
7. Yevich S, Gaspar N, Tselikas L, Brugières L, Pacquement H, Schleiermacher G, et al. Percutaneous Computed Tomography-Guided Thermal Ablation of Pulmonary Osteosarcoma Metastases in Children. Ann Surg Oncol. 2016;23(4):1380-6.
8. Saumet L, Deschamps F, Marec-Berard P, Gaspar N, Corradini N, Petit P, et al. Radiofrequency ablation of metastases from osteosarcoma in patients under 25 years: the SCFE experience. Pediatr Hematol Oncol. 2015;32(1):41-9.
9. Hoffer FA, Daw NC, Xiong X, Anghelescu D, Krasin M, Yan X, et al. A phase 1/pilot study of radiofrequency ablation for the treatment of recurrent pediatric solid tumors. Cancer. 2009;115(6):1328-37.
10. Grimer RJ, Cannon SR, Taminiau AM, Bielack S, Kempf-Bielack B, Windhager R, et al. Osteosarcoma over the age of forty. Eur J Cancer. 2003;39(2):157-63.

11. Thomas P, Sielezneff I, Ragni J, Guidicelli R, Fuentes P. Is lung cancer resection justified in patients aged beyond 70 years? Eur J Cardiothorac Surg. 1993;7(5):246-50.
12. Powell HA, Tata LJ, Baldwin DR, Stanley RA, Khakwani A, Hubbard RB. Early mortality after surgical resection for lung cancer: an analysis of the English National Lung cancer audit. Thorax. 2013;68(9):826-34.
13. Nakamura T, Matsumine A, Yamakado K, Matsubara T, Takaki H, Nakatsuka A. Lung radiofrequency ablation in patients with pulmonary metastases from musculoskeletal sarcomas. Cancer. 2009;115(16):3774-81.
14. Jaskolka JD, Kachura JR, Hwang DM, Tsao MS, Waddell TK, Asch MR. Pathologic assessment of radiofrequency ablation of pulmonary metastases. J Vasc Interv Radiol. 2010;21(11):1689–96.
15. de Baère T, Palussière J, Aupérin A, Hakime A, Abdel-Rehim M, Kind M, et al. Midterm local efficacy and survival after radiofrequency ablation of lung tumors with minimum follow-up of 1 year: Prospective evaluation. Radiology. 2006;240(2):587-96.
16. Sano Y, Kanazawa S, Mimura H, Gobara H, Hiraki T, Fujiwara H, et al. A novel strategy for treatment of metastatic pulmonary tumors: radiofrequency ablation in conjunction with surgery. J Thorac Oncol. 2008;3(3):283-8.

Tables

Due to technical limitations, table 1 & 2 xls are only available as a download in the Supplemental Files section.

Figures

Figure 1

A lateral radiograph demonstrates radiolucency with an extraosseous mineralized mass in the calcaneal body.

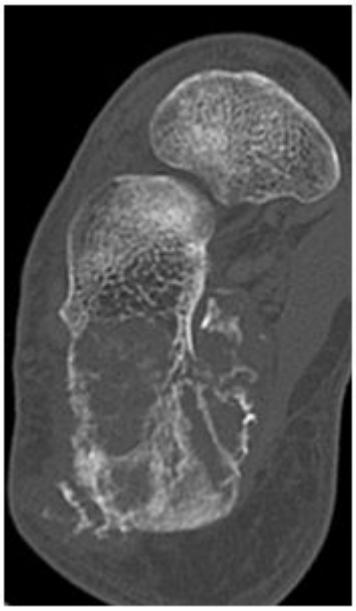

Figure 2

An axial CT image demonstrates osteolytic and ostosclerotic lesions with partial cortical destruction and fracture.

Figure 3

A sagittal T1-weighted MRI shows the area of decreased signal intensity area in the calcaneal body and the extraosseous mass.

Figure 4

An anterior view of 18F-FDG PET/CT images reveals an increased uptake in the calcaneus (SUVmas 6.6). No metastasis was found.

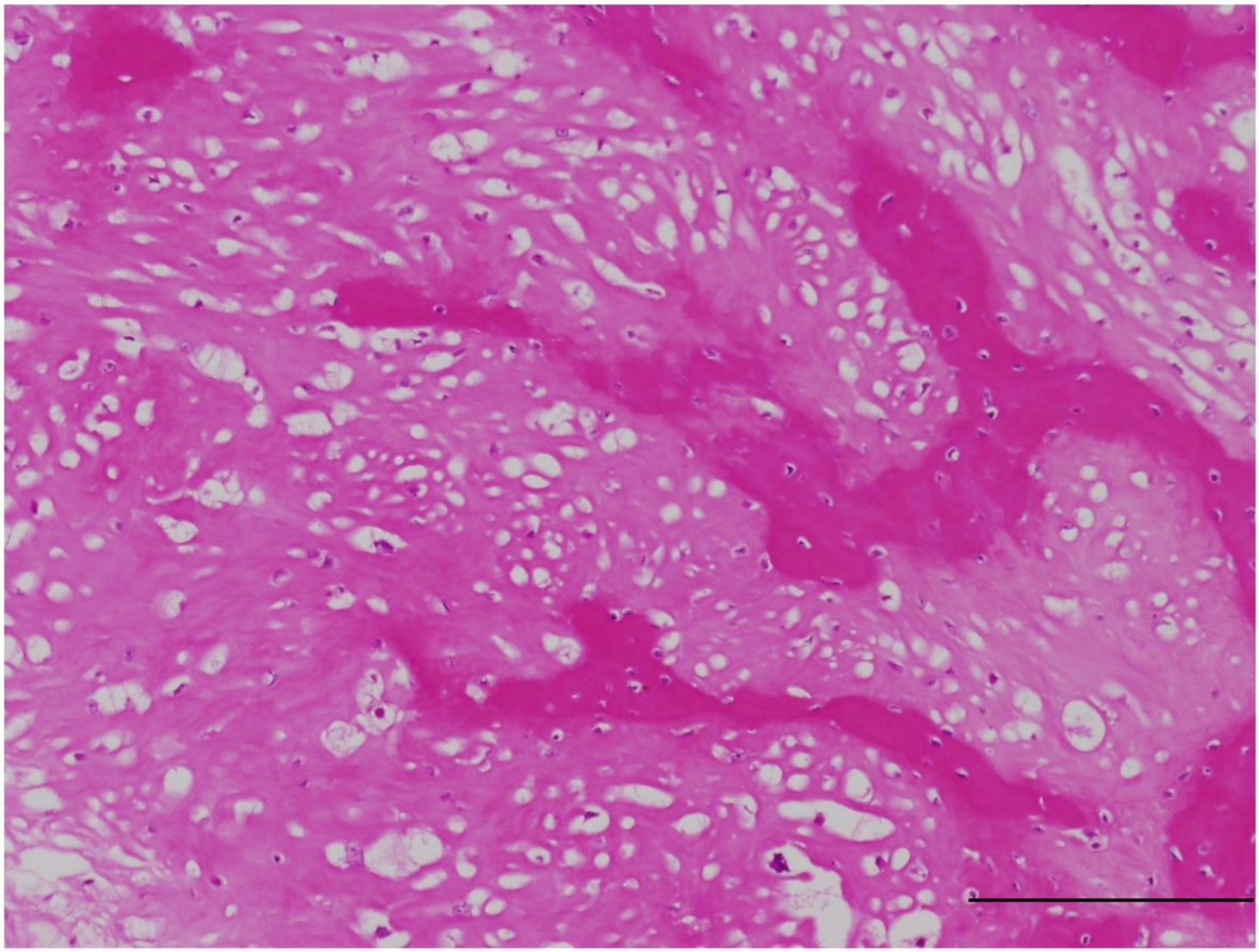

Figure 5

Histology of the biopsy specimen reveals malignant stromal cells forming osteoid (Bar=200 μm).

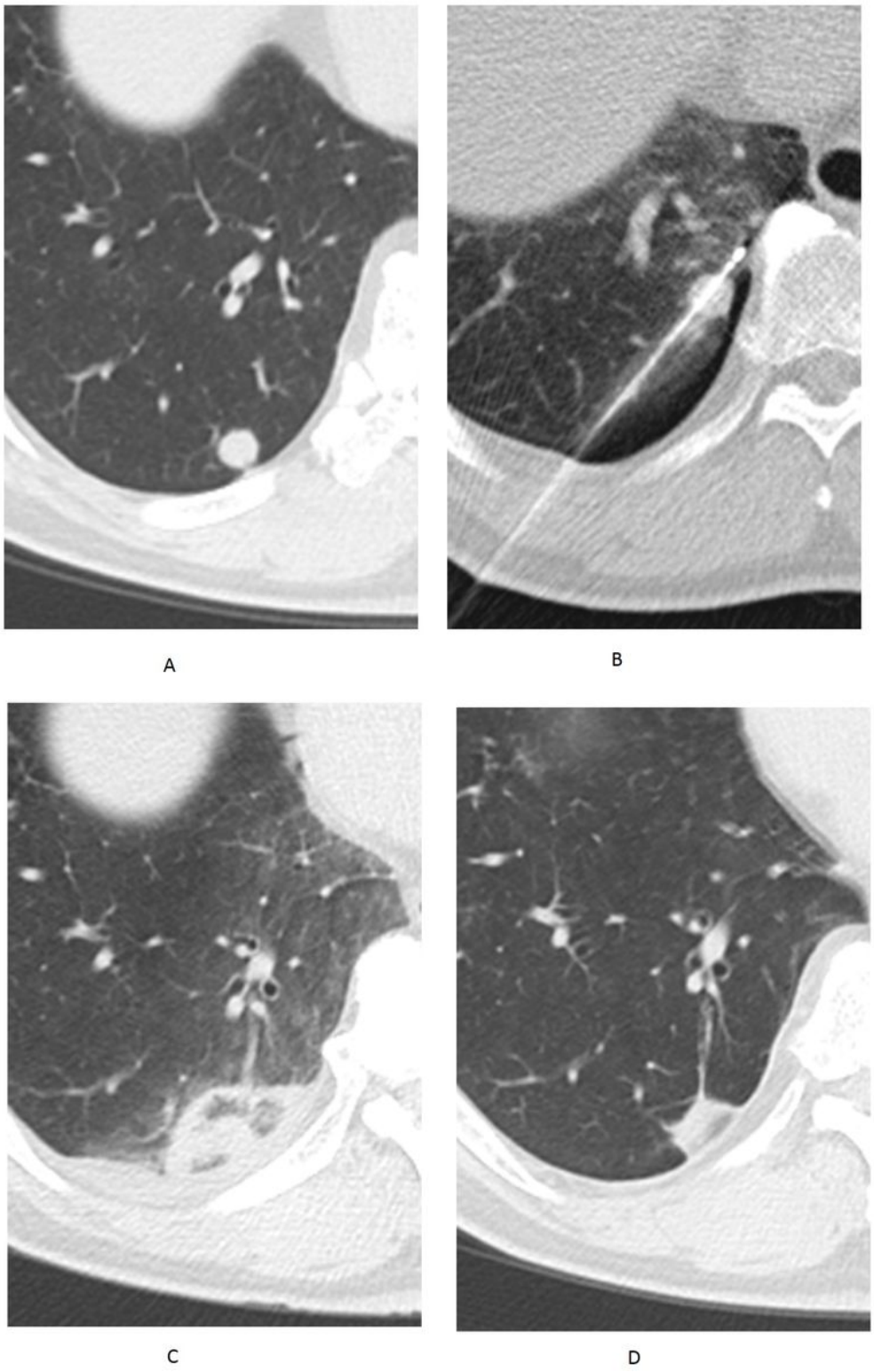

Figure 6

Sequential axial CT images before RFA (A), during RFA (B), at 3 days (C), 1 year (D) after RFA show dissolving of metastasis.

Supplementary Files

This is a list of supplementary files associated with this preprint. Click to download.

- Table1.xls
- Table2.xls