Radiotherapy efficacies for vertebral hemangioma patients with severe spinal cord compression and cauda equina syndrome

Yi-Lun Chen
National Taiwan University Hospital
Shih-Huang Yang
National Taiwan University Hospital
Sung-Hsin Kuo (shkuo101@ntu.edu.tw)
National Taiwan University Hospital https://orcid.org/0000-0003-0054-887X

Short report

Keywords: Spine Tumor, Spinal Canal Encroachment, Tomotherapy, Volumetric Modulated Arc Therapy

Posted Date: March 22nd, 2021

DOI: https://doi.org/10.21203/rs.3.rs-292408/v1

Abstract

Background: Although vertebral hemangioma is the most common benign spine tumor, rare patients may experience spinal cord compression accompanied by pain and neurological deficits, in whom surgery remains the standard treatment option. For patients with comorbidities who cannot tolerate operation, radiotherapy may be an alternative treatment, however, previous studies suggested that if spinal cord cannel was aggressively compressed by vertebral hemangioma, the efficacies of radiotherapy were suboptimal.

Methods and results: Herein, we presented two patients with vertebral hemangioma who developed spinal cord compression, first patient with underlying congenital heart disease had spinal canal encroachment of 63.4% at *ninth thoracic vertebra*, and second patient failed to transcatheter arterial embolization for treating total encroachment of sacrum plexus. The first patient underwent radiotherapy with 44 Gy at 20 fractions using Tomotherapy and became fully recovered from the severe neurological deficits at 5.5 months after completing radiotherapy. The second patient benefited from neurological symptoms relief at 6 months after completion of radiotherapy using 42 Gy at 21 fractions using volumetric modulated arc therapy (VMAT) technique.

Conclusions: Our results indicate that radiotherapy with 42 to 44 Gy using conventional fractions could efficiently cause tumor regressions and improve neurological symptoms resulted from vertebral hemangioma-causing spinal cord compression.

Introduction

Vertebral hemangioma is the most common benign spine tumor with the prevalence rate of around 12%, which enriched with blood-filled cavities and mostly occurred in the thoracic and lumbar spine [1-3]. Vertebral hemangioma, causing thickened vertebral trabeculae, is classically characterized by polka dot and corduroy sings in the radiographical images of computed tomography (CT) scans [4,5]. The pictures of vertebral hemangioma in magnetic resonance imaging (MRI) imaging often manifest as hyperintense signals, in which the values of signal are dependent on the composition of adipocyte, edematous tissue, and vascularity of the vertebral hemangioma [6].

Although vertebral hemangioma is a benign tumor in nature, some patients developed spinal cord compression accompanied by pain symptoms and subsequent neurological deficits [1,7]. Surgery remains the mainstay of approach treating patients with vertebral hemangioma who developed spinal cord compression. However, for patients with comorbidities who are ineligible for operation, treatment options become limited. Herein, we presented two cases of inoperable aggressive vertebral hemangioma with prominent spinal cord compression causing severe neurological deficits who responded to radiotherapy (RT) and fully recovered neurological symptoms later.

Case Series

Case 1

A 17-year-old boy presented with dysesthesia of right foot and unsteady gait for 1 month. Later, he experienced progressive dysesthesia and weakness of bilateral lower extremities, in which neurologic examination revealed the Medical Research Council's scale (MRC scale) of muscle power were four out of five. As symptoms progressed (MRC scale muscle power: 3), the patient became dependence on wheelchair for ordinary daily-living activities. The CT scan image showed the polka dot and corduroy sign at *ninth thoracic vertebra* (T9) (**Fig. 1A, 1B**). MRI disclosed a T2-weighted hyperintensity, and T1-weighted hypointensity with obvious gadolinium enhancement expansile lesion at T9, in which the lesion caused spinal cord compression (**Fig. 1C, 1D**). According to the classical radiographically findings, he was diagnosed with the vertebral hemangioma of T9. The patient was not suitable for surgery due to cyanotic heart defect. Therefore, he underwent RT with 44 Gy in 20 fractions using Tomotherapy and concurrent administration of dexamethasone (**Fig. 2**). Upon completion of RT, he had subjectively improved bilateral lower limbs dysesthesia without treatment-related adverse toxicities. At 5.5 months after completion of RT, he had fully been recovered from neurologic symptoms (MRC scale muscle power of lower extremities returned to five) and ordinary daily-living activities, and the follow MRI also showed good partial regression of vertebral hemangioma at T9. He remained neurological deficits-free at 16 months after completion of RT, when MRI revealed almost complete remission of T9 vertebral hemangioma for him (**Fig. 3**).

Case 2

A 36-year-old man initially complained of right buttock numbness for 5 months. Afterwards, he experienced right leg pain and numbness accompanied by anal tone loosen while defecation. An MRI image disclosed a T2-weighted hyperintensity and Gadolinium-enhanced T1-weighted lesion at sacrum causing cortical destruction and total sacral nerve roots encasement (**Fig. 4A**). The pathology of sacral tumor biopsy revealed hemangioma, confirming a sacral hemangioma wit cauda equina syndrome. He then underwent transcatheter arterial embolization (TAE), but he had persisted symptoms with slightly enlarged tumor after TAE (**Fig. 4B**). Hence, the patient underwent RT for sacral hemangioma with 42 Gy in 21 fractions using volumetric modulated arc therapy (VMAT) technique. During RT treatment, he had subjectively improvement of right leg pain and numbness. Soon after the completion of RT, his anal tone was dramatically recovered. Only grade 1 or 2 dermatitis and fatigue were observed during and after RT. The follow-up MRI disclosed partial remission of hemangioma at 2 years after completing RT, and persisted good partial remission of sacral lesion at 5.8 years after completing RT (Fig.4C).

Discussion

In addition to surgery, previous studies reported that RT may serve as an alternative treatment option for vertebral hemangioma (**Table 1**) [8-12]. Rades et al. analyzed 117 patients with vertebral hemangioma, and categorized them into high-RT dose (36-44 Gy) group and low-RT dose (20-34 Gy) group according to the equivalent dose in 2 Gy fraction per fraction (EQD2), in which an α/β ration of 3 was applied because

vertebral hemangioma is a low proliferating benign disease [8]. Rades et al revealed that high-RT dose group patients achieved a better symptom control (up to 82%) without increase of toxicities [8]. Similar radiation dose schedule was also endorsed by two large retrospective studies [9,10], in whose reports suggested the RT dose was at least 36 Gy in 2 Gy per fraction could offer feasible treatment outcome for patients with vertebral hemangioma. In a follow-up study of 10 patients with symptomatic vertebral hemangioma over five years, Parekh et al. showed that RT with a mean dose of 47 Gy provided a 90% of tumor control rate, and recommended a favored RT dose of 45 Gy in a 1.8 Gy per fraction schedule for treating vertebral hemangioma [11]. The aforementioned results should be interpreted with cautions since the endpoints of most studies focused on pain relief, but did not specifically describe the improvement of neurological deficits, and some patients also underwent surgical intervention before RT (**Table 1**).

Another case series conducted by Jiang et al who analyzed the treatment outcome of 29 vertebral hemangioma patients with neurologic deficits [12], in whom two of 10 patients receiving RT alone required further surgical intervention for progressive neurologic deficit. However, the dose of RT was not mentioned in Jiang et al' reports [12]. Wang et al assessed the clinical outcomes of 20 patients with vertebral hemangioma who had mild neurological deficits (defined as MRC scale muscle power greater than three out of five) and were treated with RT using 40-50 Gy in 20-25 fractions, and reported that thirteen patients (65%) achieved complete resolution of neurologic symptoms without recurrence after a minimum follow-up of 20 months (**Table 1**) [13]. Wang et al also revealed that among vertebral hemangioma patients receiving RT with 40 to 50 Gy, 7 patients who experienced progressive or stable neurological symptoms after RT had more serious vertebral canal encroachment greater than 40% at initial MRI examination, whereas 13 patients who responded to RT had an encroachment ratio less than 40% (**Table 1**) [13]. However, our first presented case had a spinal canal encroachment of 63.4% and became completely free of neurological symptoms at 5.5 months after completing RT. The other case had the complete encroachment (100%) of sacrum plexus by sacral hemangioma and achieved good partial remission of tumor with recovery of anal tone after completing RT.

In conclusion, we and other investigators' studies demonstrated that RT using at least conventional dose of 40 Gy could result in predominant neurologic symptoms improvement (**Table 1**). The use of RT can be an alternative treatment strategy for inoperable patient with vertebral hemangioma even if this disease behaves as violent spinal cord compression accompanied by neurologic deficits.

Abbreviations

VMAT: volumetric modulated arc therapy; CT: computed tomography; MRI: magnetic resonance imaging; RT: radiotherapy; MRC: Medical Research Council's; T9: *ninth thoracic vertebra*; TAE: transcatheter arterial embolization; $EQD_{2:}$ equivalent dose in 2 Gy fraction per fraction.

Declarations

Ethical Approval and Consent to participate

This study was designed and conducted in accordance with the principles outlined in the Declaration of Helsinki and within the guidelines of Good Clinical Practices. The patients provided written informed consent for the case details and images to be published.

Consent for publication

All authors agree to this submission.

Availability of supporting data

The datasets supporting the conclusions of this article are included within the article.

Competing interests

All authors declare that they have no conflicts of interest statement.

Funding

This research was funded by Ministry of Science and Technology, Taiwan, No. MOST 107-2314-B-002-217-MY3, No. MOST 108-2811-B-002-616-, No. MOST 109-2314-B-002-200-, and No. MOST 109-2811-B-002-565-; and National Taiwan University Hospital, Taiwan, No. NTUH 110-S4965.

Acknowledgements

None.

References

1. Gaudino S, Martucci M, Colantonio R, et al. A systematic approach to vertebral hemangioma. Skeletal Radiol. 2015;44(1):25-36.
2. Slon V, Stein D, Cohen H, Sella-Tunis T, May H, Hershkovitz I. Vertebral hemangiomas: their demographical characteristics, location along the spine and position within the vertebral body. European Spine Journal. 2015;24(10):2189-2195.
3. Fox MW, Onofrio BM. The natural history and management of symptomatic and asymptomatic vertebral hemangiomas. J Neurosurg. 1993;78(1):36-45.
4. Rodallec MH, Feydy A, Larousserie F, et al. Diagnostic imaging of solitary tumors of the spine: what to do and say. Radiographics. 2008;28(4):1019-1041.
5. Zito G, Kadis GN. Multiple vertebral hemangiomas resembling metastases with spinal cord compression. Arch Neurol. 1980;37(4):247-248.
6. Baudrez V, Galant C, Vande Berg BC. Benign vertebral hemangioma: MR-histological correlation. Skeletal Radiol. 2001;30(8):442-446.
7. Dang L, Liu C, Yang SM, et al. Aggressive vertebral hemangioma of the thoracic spine without typical radiological appearance. European Spine Journal. 2012;21(10):1994-1999.

8. Rades D, Bajrovic A, Alberti W, Rudat V. Is there a dose-effect relationship for the treatment of symptomatic vertebral hemangioma? Int J Radiat Oncol Biol Phys. 2003;55(1):178-181.
9. Heyd R, Seegenschmiedt MH, Rades D, et al. Radiotherapy for symptomatic vertebral hemangiomas: results of a multicenter study and literature review. Int J Radiat Oncol Biol Phys. 2010;77(1):217-225.
10. Miszczyk L, Tukiendorf A. Radiotherapy of painful vertebral hemangiomas: the single center retrospective analysis of 137 cases. Int J Radiat Oncol Biol Phys. 2012;82(2):e173-180.
11. Parekh AD, Amdur RJ, Mendenhall WM, Morris CG, Zlotecki RA. Long-term Tumor Control With Radiotherapy for Symptomatic Hemangioma of a Vertebral Body. Spine. 2019;44(12):E731-E734.
12. Jiang L, Liu XG, Yuan HS, et al. Diagnosis and treatment of vertebral hemangiomas with neurologic deficit: a report of 29 cases and literature review. The Spine Journal 2014;14(6):944-954.
13. Wang B, Meng N, Zhuang H, et al. The Role of Radiotherapy and Surgery in the Management of Aggressive Vertebral Hemangioma: A Retrospective Study of 20 Patients. Med Sci Monit. 2018;24:6840-6850.

Table

Table 1. Results of radiotherapy treatment for patients with vertebral hemangioma from different institutions

Series (Institution)	N	RT (Gy)	Complete Pain relief	Neurological deficits improvement	Notes
University Hospital Eppendorf [8]					≥ 36 Gy resulted in better pain relief
Group A	62	20-34 (2 Gy/fx)	39%	NA	
Group B	55	36-44 (2 Gy/fx)	82%	NA	
Multicenter German Study [9]	84	4.5-45 (median 34 Gy/17 fx)	62%	CR = 79%; PR=21%	≥ 34 Gy resulted in better pain relief
Maria Sklodowska-Curie Center [10]	137	8-30 (81% 24 Gy/12 fx)	64% at 1.5 ys	NA	Increase RT dose and fx size resulted in better pain relief
Peking University Third Hospital [13]	20	40-50 (20-25 fx)	NA	CR = 65%	VCE > 40% resulted in poor RT response
University of Florida [11]	10	28.8-59.8 (median 45 Gy/25 fx)	NA	NA	90% local tumor control at 30 ys

Abbreviations: N, number; RT, radiotherapy; fx, fraction; NA, non-analysis; CR, complete response; PR, partial response; ys, years; VCE, vertebral canal encroachment

Figures

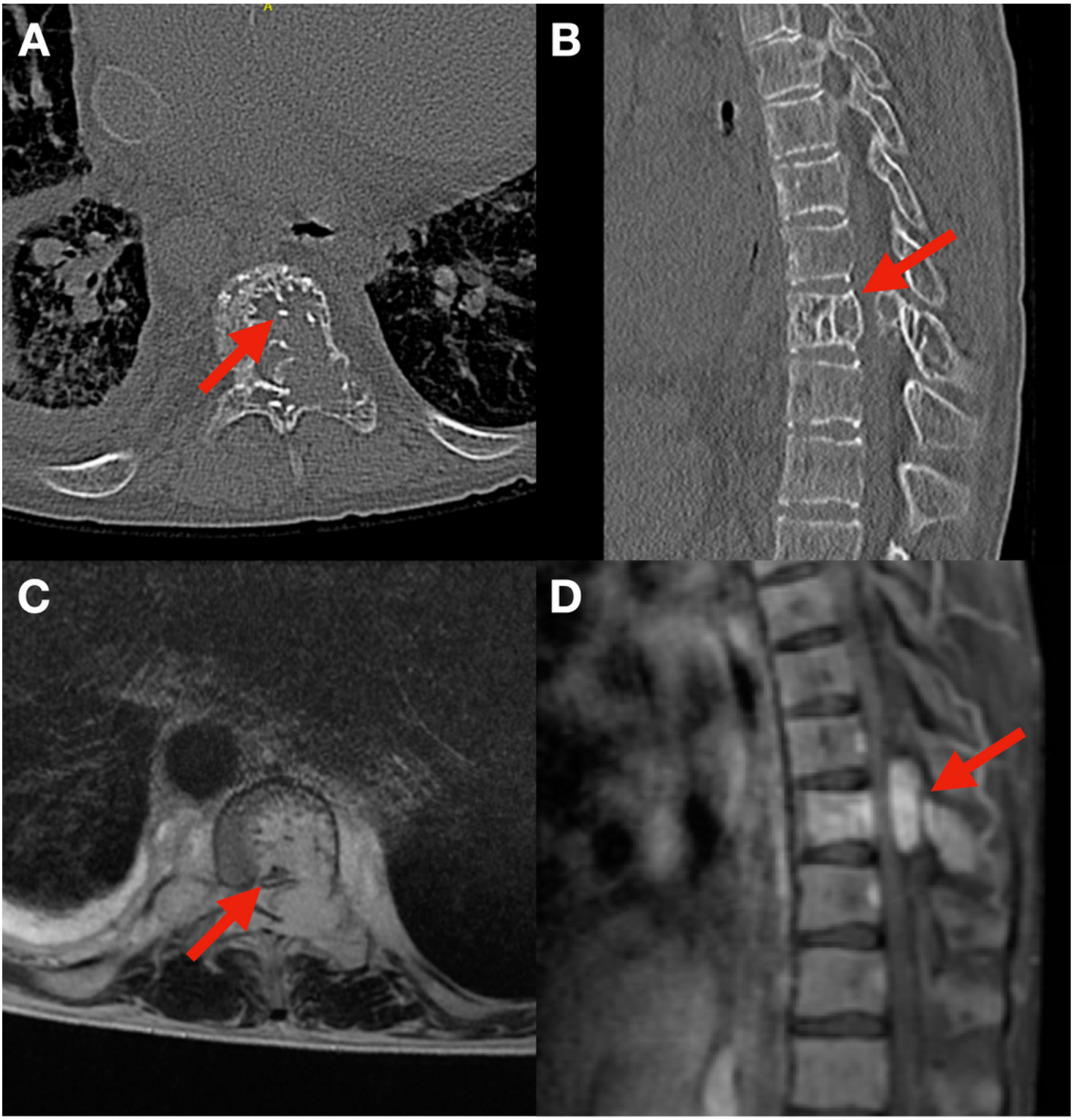

Figure 1

The imaging finding of spine hemangioma of case 1 (A) Axial CT disclosing classic Polka-Dot sign at T9 (red arrow) (B) Sagittal CT showing classic Corduroy sign at T9 (red arrow). CT, computed tomography; T, thoracic spine. The MRI finding of spine hemangioma of case 1 (C) T2-weighted image (T2WI) prior to radiotherapy demonstrating severe cord compression (red arrow) (D) T1-weighted image (T1WI) with contrast disclosing an enhancing lesion at T9 (red arrow). MRI, magnetic resonance imaging.

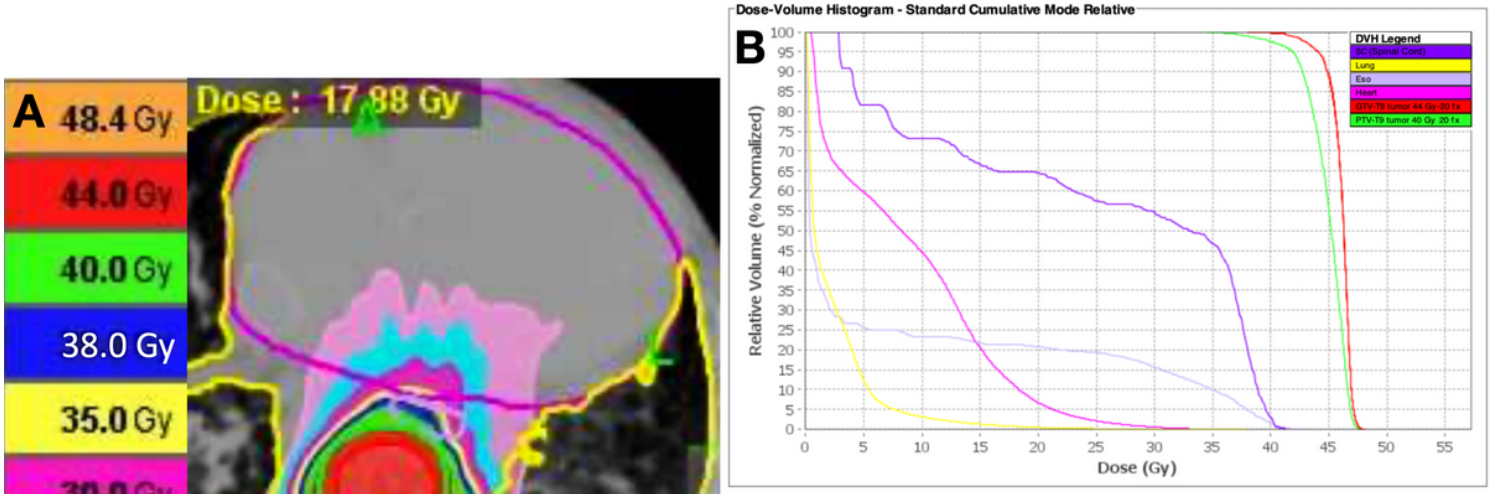

Name	Max Dose [Gy]	Min Dose [Gy]	Median Dose [Gy]	Avg Dose [Gy]	StdDev Dose [Gy]	Physical Vol [cc]
Spinal Cord	41.25	2.78	32.95	25.13	14.33	4.46
Lung	37.91	0.10	0.74	2.24	3.23	1,446.59
Esophagus	42.88	0.06	0.39	7.99	13.63	41.00
Heart	36.88	0.43	8.22	8.79	7.24	1,013.70
GTV-T9 tumor 44 Gy 20 fx	48.06	37.98	46.28	46.02	1.06	22.36
PTV-T9 tumor 40 Gy 20 fx	48.06	34.47	45.21	44.84	1.78	70.38

Figure 2

A treatment planning of T9 spine hemangioma using Tomotherapy (A) Radiotherapy dose distribution for the T9 spine hemangioma. Gross target volume (GTV) is defined as the tumor volume visualized under CT images. Planning target volume (PTV) is defined as the GTV with a 5-mm expansion. (B) Dose-volume histogram of the T9 spine hemangioma. GTV was prescribed with 44 Gy in 20 fractions, whereas PTV was prescribed with 40 Gy in 20 fractions.

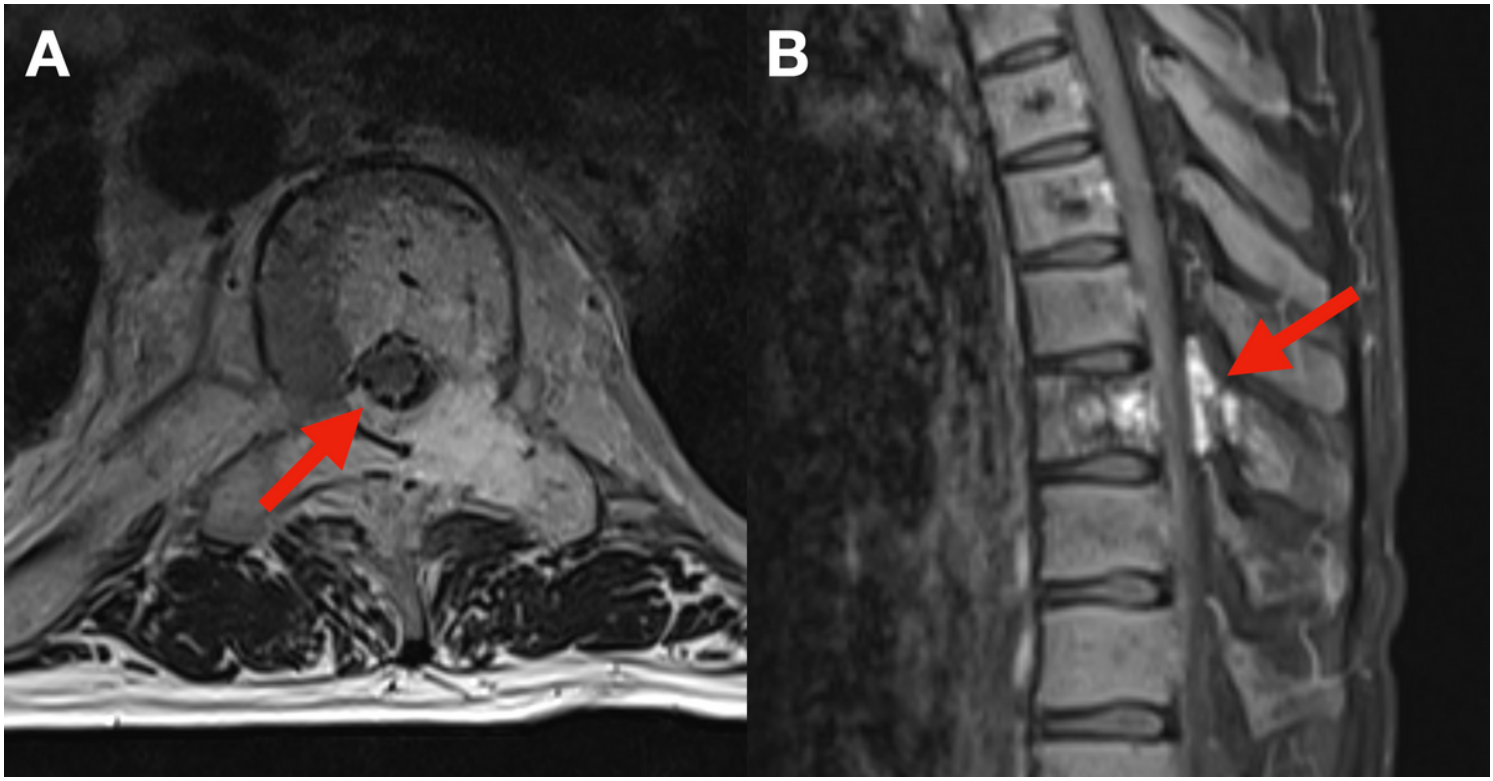

Figure 3

The MRI finding of spine hemangioma of case 1 after radiotherapy (A) T2WI 16 months after radiotherapy revealing resolution of tumor in the spinal canal (red arrow) (B) T1WI with contrast 16 months after radiotherapy revealing almost complete remission of tumor at T9 (red arrow). MRI, magnetic resonance imaging.

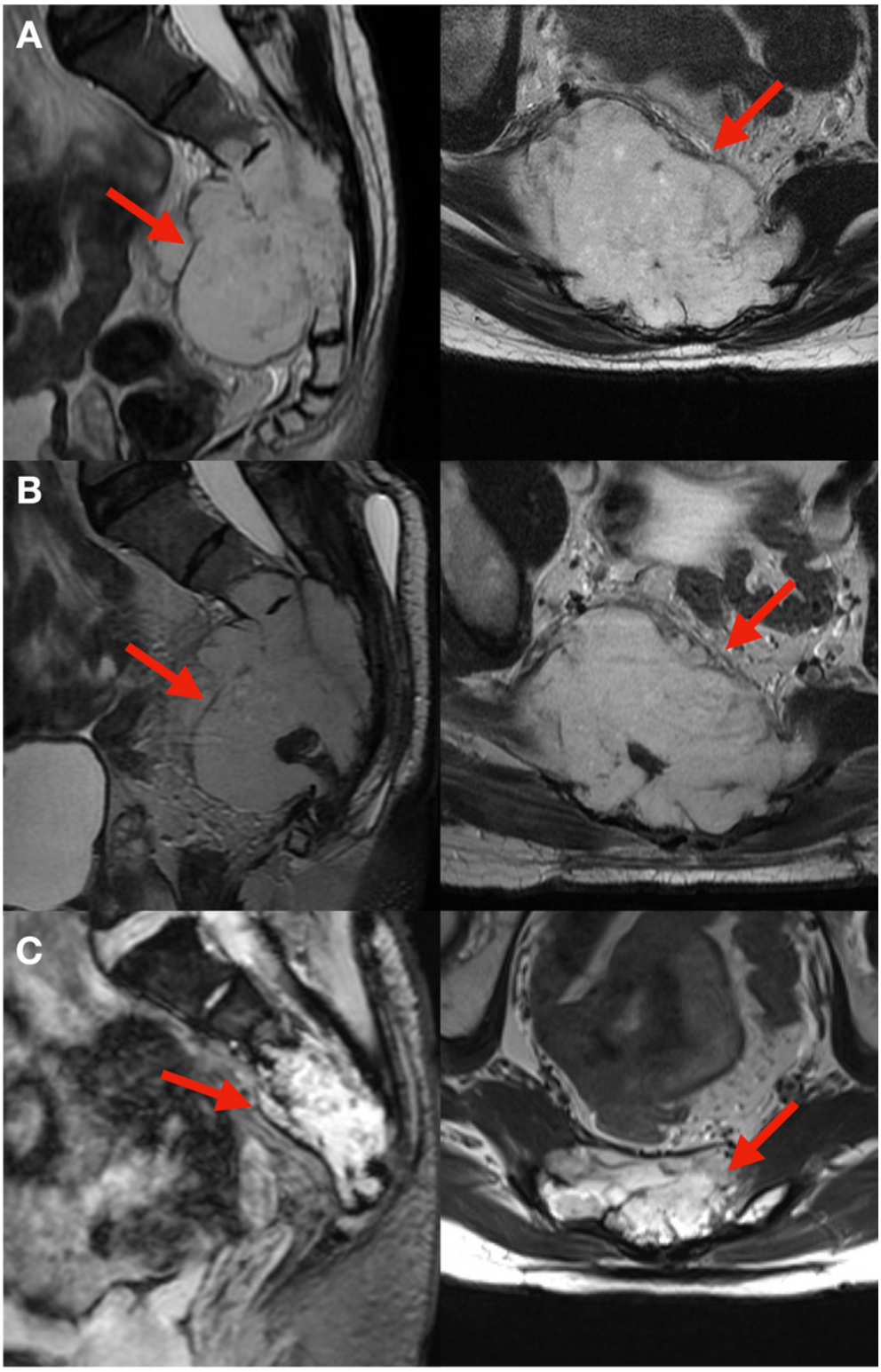

Figure 4

The MRI finding of spine hemangioma of case 2 (A) An irregular-shaped lesion with diameter up to 8.4 cm (red arrow) causing bony destruction and nerve root encasement at T2WI imaging (B) T2WI showing slightly enlarged lesion (red arrow) with diameter over 9 cm 1.5 months after TAE (C) T2WI demonstrating significant tumor size reduction (red arrow) without tumor recurrence 5.8 years after radiotherapy. MRI, magnetic resonance imaging; TAE, transcatheter arterial embolism.