Successful Outcomes of Single-Port Insufflation Endoscopic Breast-Conserving Surgery for Breast Cancer

Zi-Han Wang
Capital Medical University Affiliated Beijing Friendship Hospital
Shan-Shan Wu
Capital Medical University Affiliated Beijing Friendship Hospital
Tian-Ran Gang
Capital Medical University Affiliated Beijing Friendship Hospital
Guo-Xuan Gao
Capital Medical University Affiliated Beijing Friendship Hospital
Fang Xie
Beijing Hospital of Traditional Chinese Medicine
Xiang Qu (cqx3968@ccmu.edu.cn)
Capital Medical University Affiliated Beijing Friendship Hospital https://orcid.org/0000-0002-7969-1056

Research Article

Keywords: Breast cancer, Breast-conserving surgery, Endoscopic, Endoscopy, Endoscopy-assisted

Posted Date: March 17th, 2021

DOI: https://doi.org/10.21203/rs.3.rs-297576/v1

Abstract

Purpose

In the surgical treatment of breast cancer, the goal of surgeons is to continuously create and improve minimally invasive surgical methods to increase the quality of life of the patient. Currently, routine breast-conserving surgery is performed using two obvious incisions. Here, we compare the clinical efficacy and aesthetic perspectives between a novel technique using one incision called single-port insufflation endoscopic breast-conserving surgery and conventional breast-conserving surgery in early stage breast cancer.

Methods

A total of 180 patients with stage I or stage II breast cancer participated in this study. Single-port insufflation endoscopic breast-conserving surgery was performed on 63 patients, while conventional breast-conserving surgery was performed on 117 patients. The evaluation of the aesthetic outcome was carried out by the BREAST-Q scale. Logistic regression was conducted to assess the risk of local recurrence and metastasis.

Results

There were significant differences between the two groups for chest well-being, psychological well-being, and adverse effects of radiation. The scores for satisfaction of breasts and sexual well-being showed no statistical differences between the two groups. There was no statistical significance in local recurrence or metastasis between the two groups. Single-port insufflation endoscopic breast-conserving surgery did not increase the risk of local recurrence or metastasis.

Conclusion

The novel surgical technique, single-port insufflation endoscopic breast-conserving surgery, is a feasible and safe surgery and has advantages in terms of cosmetic outcome and psychological status.

Introduction

Breast cancer is the most common malignancy in women worldwide [1–3]. To surgically treat breast cancer, surgeons have continuously created and improved minimally invasive procedures such as breast-conserving surgery, sentinel lymph node biopsy, and endoscopic surgery. Due to these advanced techniques, patients diagnosed with breast cancer increasingly adopt the minimally invasive breast-conserving therapy over mastectomy. Multiple studies have observed a faster recovery and better body image satisfaction in women who chose breast-conserving therapy while also showing similar survival rates for breast-conserving therapy and mastectomy [4–7]. When surgery is indicated for treatment and the patient choses conventional breast-conserving surgery (C-BCS), the surgery is performed by creating two obvious incisions. One incision is used for local extended lumpectomy and the other for sentinel

lymph node biopsy or axillary lymph node dissection. These obvious incisions can cause patient dissatisfaction and poor body image. Therefore, we designed a novel surgical technique called single-port insufflation endoscopic breast-conserving surgery (SIE-BCS), which combines the advantages of being minimally invasive and breast-conserving without an obvious incision on the breast. In this retrospective cohort study, we compare the clinical efficacy and aesthetic outcomes between SIE-BCS and C-BCS.

Materials And Methods

Ethics Statement

All of the surgical procedures and informed consent details were approved by the Ethics Committee of the Beijing Friendship Hospital, Capital Medical University (Beijing, China) (document number: 2016-P2-070-02).

Patients and methods

Procedures were performed on breast cancer patients (*N* = 180) from March 2017 to July 2019 at the Beijing Friendship Hospital (Table 1). SIE-BCS was performed on 63 patients. C-BCS was performed on 117 patients. The following inclusive criteria were used: (1) diagnosis of stage I or II invasive breast cancer; (2) the tumor was constrained to the mammary gland (magnetic resonance imaging confirmed); (3) lesions ≤ 3 cm in diameter and the distance between the lesion and the nipple areola complex > 3 cm; (4) axillary lymph nodes were not significantly fused with the axillary vein or brachial plexus nerves; (5) patients with adequate glandular volume; (6) age between 18 and 70 years old; (7) Eastern Cooperative Oncology Group scoring grade from 0 to 2; and (8) normal function of the liver, kidney, and bone marrow. The following exclusive criteria were used: (1) comorbidities including cardiovascular disease, myocardial infarction, and cerebrovascular disease; (2) patients who could not receive general anesthesia or surgical treatment; (3) tumor history within the past five years; (4) pregnant or lactating women; (5) the tumor invaded the skin or subcutaneous tissue (confirmed by magnetic resonance imaging or physical examination); (6) widespread disease that cannot be incorporated by local excision of a single region or segment of breast tissue that achieves negative margins with a satisfactory cosmetic result; (7) unable to guarantee performance of radiological therapy after the operation; and (8) persistently positive pathologic margin.

Table 1
Clinical data of the 180 patients

Variable	SIE-BCS (*n* = 63)	C-BCS (*n* = 117)	*p*-value
Age in years (range)	52.8 (35.0–66.0)	54.0 (19.0–70.0)	0.961
Premenopausal, *n* (%)	24 (38.1%)	41 (35.0%)	0.770
Neoadjuvant chemotherapy, *n* (%)	7 (11.1%)	10 (8.5%)	0.381
cTNM stage, *n* (%)			0.510
I	32 (50.8%)	49 (41.9%)	
IIA	22 (34.9%)	47 (40.1%)	
IIB	9 (14.3%)	21 (18.0%)	
PR, *n* (%)			0.061
Positive	47 (74.6%)	71 (60.7%)	
Negative	16 (25.4%)	46 (39.3%)	
ER, *n* (%)			0.619
Positive	51 (80.9%)	91 (77.8%)	
Negative	12 (19.1%)	26 (22.2%)	
HER2, *n* (%)			0.011
Positive	5 (7.9%)	27 (23.1%)	
Negative	58 (92.1%)	90 (76.9%)	
Tumor location, *n* (%)			0.285
Lateral upper quadrant	42 (66.7%)	67 (57.3%)	
Lateral lower quadrant	2 (3.2%)	8 (6.8%)	
Medial upper quadrant	17 (26.9%)	31 (26.5%)	
Medial lower quadrant	2 (3.2%)	11 (9.4%)	

HER2 status was estimated by immunohistochemistry or in situ hybridization. Tumors were considered to be HER2 positive if the average immunohistochemistry showed (+++). *HER2* gene/chromosome 17 ratio was 2, and the average *HER2* gene copy number was 6. SIE-BCS: Single-port insufflation endoscopic breast-conserving surgery; C-BCS: Conventional breast-conserving surgery; cTNM: Clinical tumor, node, and metastasis; ER: Estrogen Receptor; PR: Progesterone receptor; HER2: Human epidermal growth factor receptor type 2.

Surgical procedures

All surgeries in both groups were performed by Dr. Xiang Qu. Patients were placed in the supine position with the ipsilateral arm in abduction at 90°. First, we injected 0.2 mL of methylene blue around the mammary areola to identify the sentinel lymph node. To endoscopically confirm the extent of tumor removal, we injected 5 mL of methylene blue 1 cm away from the tumor margin (Fig. 1). After fifteen minutes, a 2.5 cm single-port incision was made along the wrinkles in the axilla. Second, we performed the sentinel lymph node biopsy through this incision, and the intraoperative frozen pathology determined whether axillary lymph node dissection was necessary.

SIE-BCS procedure

A total of 63 cases were performed by the same team and the same surgeon (X. Qu). The laparoscopy equipment kit (Olympus Optical Co., Tokyo, Japan) included optic and endoscopic instruments and were reusable after disinfection. For SIE-BCS, we used the same short axillary incision that was used to perform the sentinel lymph node biopsy. First, we injected 0.5 mg of adrenaline mixed with 250 mL of 0.9% sodium chloride into the subcutaneous layer between the skin flap and the mammary gland to reduce blood loss. Second, we inserted a tunneler (Fig. 2) into the subcutaneous layer to reveal the potential space between the skin flap and the mammary gland. Third, we created an adequate working space by insufflating 8 mmHg of pressure and 8 L of carbon dioxide per minute through the single-port insufflation kit (HTKD-Hang T Port, China) (Fig. 3), which also had four plastic trocars on the surface. We inserted the laparoscopic tools from the single-port insufflation kit. Then, we dissected the Cooper's ligament with laparoscopic tissue scissors until the skin flap and the mammary gland were totally separated (Fig. 4). Next, we used electrocautery to vertically section from the surface of the mammary gland to the pectoral fascia. The excision range was determined *via* the prior methylene blue injection (Fig. 5). Finally, the retromammary space was separated with electrocautery, and the pectoral muscle fascia was removed laparoscopically. To prevent metastasis from the incision, the tumor and surrounding tissues were removed through the single-port insufflation kit (Fig. 6).

An intraoperative cryosection was performed around the edges of the specimen to confirm the extent of infiltration of the tumor. If the result implied residual tumor cells, then additional resection was performed until no residual tumor cells were found. If the cryosection pathology was positive more than twice, then a mastectomy was considered and performed immediately.

Titanium clips were placed around the incisal margin of the tumor for subsequent radiotherapy. A running suture of absorbable monofilament 3 – 0 barbed thread was used to close the residual cavity of the mammary gland. The surgical field was irrigated, and one drainage was placed. The single axillary incision was sutured intradermally with a 4 – 0 absorbable suture. The 63 patients who received SIE-BCS also received postoperative radiotherapy according to the National Comprehensive Cancer Network guideline [8].

C-BCS procedure

In addition to the axillary incision, a second spindle-shaped incision on the surface of the tumor was created. The tumor and the surrounding glandular tissues within 1cm of the lesion were removed. An intraoperative cryosection of the incised margin around the tumor and the basal tissue of the tumor was performed. If the pathological findings indicated the presence of residual tumor cells, then the resection was extended until the pathological results indicated the incised margin was negative. Titanium clips were placed in the residual cavity to locate the tumor area for postoperative radiotherapy. The surgical field was irrigated, drainage was placed, and the incision was sutured layer by layer.

Cosmetic Evaluation and Patient Satisfaction

The aesthetic satisfaction of patients was evaluated by the BREAST-Q [9, 10] scale six months after the operation. The BREAST-Q included questions about the patients' satisfaction with their breasts, psychosocial well-being, chest well-being, adverse effects of radiation, and sexual well-being. We compared the answers between the two groups.

Statistical Analysis

Measurement data were described by mean ± standard deviation (normal distribution) or median (upper quartile, lower quartile) (non-normal distribution). Differences in patient age, tumor size, operative time, hospitalization days, incision length, cosmetic effect score, blood loss, the total flow, and drainage tube indwelling time were determined using the independent sample t-test (normal distribution) or the Mann-Whitney U nonparametric test (non-normal distribution). Count data, such as lesion site, tumor stage, and hormone receptor, were described in absolute numbers and percentages. Fisher's exact test was used to determine differences for the intraoperative cryosections, local recurrence, and metastasis between the two groups. Baseline data differences between the two groups were compared using the Chi-square test. The methods of operation, size, age, and HER2 status were analyzed by logistic regression. SPSS 22.0 statistical software was used for all statistical analyses. There was a significant difference when $p < 0.05$.

Results

No laparoscopic-related complications such as subcutaneous emphysema were observed. The mean incision length was 3.4 cm in the SIE-BCS group and 8.6 cm in the C-BCS group. The difference between the two groups was statistically significant ($t = 19.59$, $p < 0.001$) (Table 2). The difference in mean operation time between the two groups was statistically significant ($T = 8.788$, $p < 0.001$) (Table 2). The difference in mean operation time in lateral quadrant and medial quadrant surgeries in both groups was not statistically significant (SIE-BCS group: $t=-0.343$, $p = 0.733$; C-BCS group: $t=-0.716$, $p = 0.475$). The difference in mean operation time between the two groups was not statistically significant. None of the patients in the SIE-BCS group had positive pathological resection margins. However, two patients (1.7%) in the C-BCS group were initially positive during operation. However, after an additional resection, the resection margin was negative for residual tumor cells. Postoperative pathological resection margins were negative in all patients.

Table 2
Perioperative clinicopathologic features of patients

Variable	SIE-BCS	C-BCS	*p*-value
SLNB or ALND, *n* (%)			0.452
SLNB only	49 (77.8%)	85 (72.6%)	
SLNB and ALND	14 (22.2%)	32 (27.4%)	
Operation time (min)	194.9 (59.0-410.0)	140.3 (21.0-400.0)	< 0.001
Intraoperative blood loss (mL)	24.3 (5.0-100.0)	20.9 (2.0–50.0)	0.701
pTNM staging, *n* (%)			0.672
pT_1	45 (71.4%)	80 (73.8%)	
pT_2	18 (28.6%)	37 (26.2%)	
pTNM staging, *n* (%)			0.517
pN_0	46 (73.0%)	80 (68.4%)	
pN_1	17 (27.0%)	37 (31.6%)	
Degree of tumor differentiation, *n* (%)			0.930
G_1	6 (9.5%)	12 (10.3%)	
G_2	52 (82.5%)	94 (80.3%)	
G_3	5 (8.0%)	11 (9.4%)	
Tumor types, *n* (%)			0.731
Invasive ductal carcinoma	54 (85.7%)	102 (87.2%)	
Mucinous carcinoma	3 (4.8%)	3 (2.6%)	
Preinvasive carcinoma	6 (9.5%)	12 (10.2%)	
Size of tumor (cm)	1.90 (0.60–3.20)	1.95 (0.60-4.00)	0.440
Intraoperative cryosection of the tumor, *n* (%)			0.542
Positive	0	2 (1.7%)	
Negative	63 (100%)	115 (98.3%)	
Margin of the tumor, *n* (%)			

SIE-BCS: Single-port insufflation endoscopic breast-conserving surgery; C-BCS: Conventional breast-conserving surgery; SLNB: Sentinel lymph node biopsy; ALND: Axillary lymph node dissection; pTNM: Pathological tumor, node, metastasis.

Variable	SIE-BCS	C-BCS	*p*-value
Positive	0	0	
Negative	63 (100%)	117 (100%)	
Incision length (cm)	3.4 (2.5-4.0)	8.6 (8.0–15.0)	< 0.001
Drainage duration (day)	4.3 (1.0–10.0)	4.4 (2.0–8.0)	0.596
Total drainage volume (mL)	124.5 (14.0-517.0)	87.5 (8.0-250.0)	0.041
Local recurrence, *n* (%)	2 (3.2%)	0	0.121
Metastasis, *n* (%)	1 (1.5%)	6 (5.1%)	0.424

SIE-BCS: Single-port insufflation endoscopic breast-conserving surgery; C-BCS: Conventional breast-conserving surgery; SLNB: Sentinel lymph node biopsy; ALND: Axillary lymph node dissection; pTNM: Pathological tumor, node, metastasis.

In the SIE-BCS group, 49 patients underwent sentinel lymph node biopsy only. The average number of sentinel lymph nodes was 4.63. The other 14 patients underwent axillary dissection. The mean number of axillary lymph nodes was 15.21. In the C-BCS group, 85 patients underwent sentinel lymph node biopsy, with an average sentinel lymph node number of 4.38. The other 32 patients underwent axillary dissection, with an average of 14.69 axillary lymph nodes detected (Table 2).

Six months after the surgery, we conducted a questionnaire survey using the BREAST-Q scale on all of the patients from the two groups. The differences between the scores in the SIE-BCS group and the C-BCS group for adverse effects of radiation (46.2 ± 27.2 *vs* 60.1 ± 23.1, respectively, $p = 0.030$), chest well-being (85.2 ± 19.8 *vs* 64.7 ± 15.8, respectively, $p < 0.001$), and psychological well-being (86.9 ± 16.4 *vs* 75.2 ± 19.2, respectively, $p = 0.006$) were statistically significant. The differences between the scores in the SIE-BCS group and C-BCS group for satisfaction of breasts (73.7 ± 18.3 *vs* 68.8 ± 15.9, respectively, $p = 0.120$) and sexual well-being (61.6 ± 28.1 *vs* 64.1 ± 24.0, respectively, $p = 0.600$) were not statistically significant. (Table 3).

Table 3
BREAST-Q scale score of patients

	SIE-BCS group (n = 63)	C-BCS group (n = 117)	p-value
Adverse effects of radiation	46.2 ± 27.2	60.1 ± 23.1	0.003
Chest well-being	85.2 ± 19.8	64.7 ± 15.8	< 0.001
Psychological well-being	86.9 ± 16.4	75.2 ± 19.2	0.006
Satisfaction of breasts	73.7 ± 18.3	68.8 ± 15.9	0.120
Sexual well-being	61.6 ± 28.1	64.1 ± 24.0	0.600

BREAST-Q® VERSION 2.0 © Memorial Sloan Kettering Cancer Center and The University of British Columbia, 2017. SIE-BCS: Single-port insufflation endoscopic breast-conserving surgery; C-BCS: Conventional breast-conserving surgery.

The patients were followed up until October 2020.
Two patients in the SIE-BCS group had local recurrence (3.2%), while no patients in the C-BCS group had local recurrence (0%). One patient in the SIE-BCS group had metastasis (1.6%), while six patients in the C-BCS group had metastasis (5.1%) (Table 2). The differences between the SIE-BCS group and C-BCS group for local recurrence (p = 0.121) and metastasis (p = 0.424) were not statistically significant.

Different surgical methods, tumor size, age, and HER2 status were included in logistic regression analysis. The surgical method choice of SIE-BCS did not increase the risk of local recurrence or metastasis [odds ratio (OR) = 0.975, 95% confidence interval (CI): 0.229, 4.149, p = 0.973]. Tumor size (OR = 1.221, 95%CI: 0.516, 2.887, p = 0.650), age (OR = 1.013, 95%CI: 0.944, 1.088, p = 0.717), and HER2 status (OR = 1.305, 95%CI: 0.250, 6.815, p = 0.752) were not independent risk factors for local recurrence and metastasis in this study (Table 4).

Table 4
Logistic analysis of multiple factors associated with local recurrence and metastasis

Variable	Wald	p-value	OR	95%CI
SIE-BCS	0.001	0.973	0.975	0.229, 4.149
Tumor size (cm)	0.206	0.650	1.221	0.516, 2.887
Age	0.131	0.717	1.013	0.944, 1.088
HER2 positivity	0.100	0.752	1.305	0.250, 6.815

OR: Odds ratio; CI: Confidence interval; SIE-BCS: Single-port insufflation endoscopic breast-conserving surgery.

Discussion

Breast-conserving surgery is becoming the first choice for patients when they are diagnosed with early-stage breast cancer [11, 12]. However, traditional open breast-conserving surgery requires two obvious surgical incisions, which have a negative impact on postoperative aesthetics and quality of life for patients [13–15]. For this reason, patient quality of life and well-being after breast surgery are important factors to evaluate as clinical outcomes and to consider when developing diagnosis and treatment techniques. Due to the continuing development of laparoscopy in general surgery, surgeons have begun integrating the technology in breast-conserving surgery for the treatment of early breast cancer [16, 17]. In this study, we developed and introduced SIE-BCS. We previously described a noninflatable laparoscopic breast-conserving surgery [18]. However, this novel use of the insufflation technique from this report allowed an increase in sufficient surgical space and an increase in satisfactory exposure compared to our previous report.

All patients successfully completed endoscopic breast-conserving surgery, and there were no transfers to open surgery. Unexpectedly, when performing the intraoperative cryosection of the margin of the tumor, the residual tumor cell rates in both groups were low (0% in the SIE-BCS group and 1.7% in the C-BCS group). In addition, there were no residual tumor cells at the resection margin after postoperative pathology. This is in contrast to other studies [19, 20] that found residual tumor cells at the resection margin in approximately 6.3% of cases. We hypothesize that the low positive residual tumor cell rate in our study was related to how our group determines the resection range. Before surgery, we palpate the tumor edge and then inject methylene blue around the tumor with a 1 cm margin that was used as the boundary for surgical resection. Postoperative gross pathology shows that palpation leads to a size larger than the actual tumor compared to other detection methods, such as ultrasound. Therefore, the method of palpation and adding a 1-cm border may explain the nonexistent residual tumor cell rate in both groups.

The SIE-BCS group had a significantly shorter incision length than the C-BCS group (3.4 cm *vs* 8.6 cm, respectively, $p < 0.001$). This novel single-port endoscopic surgical technique reduced the length of the incision and the number of incisions. Additionally, this single-port incision was created along the wrinkles of the axilla, which is then hidden by the upper limb and the axillary fossa (Fig. 7A). Routine breast-conserving surgery typically requires two obvious incisions. The incision on the surface of the breast greatly reduces the aesthetic satisfaction of the patient (Fig. 7B). The mean operation time of C-BCS was significantly shorter than the operation time of SIE-BCS and C-BCS. When we compared the operation times of the lateral quadrant and the medial quadrant in each group, we found that there was no statistically significant difference. This indicates that the length of operation time was related to the operation method. It has been shown in other fields, such as gastrointestinal [21], hepatobiliary [22], and thyroid surgery [23], that the use of endoscopy increases the operation time when compared to conventional surgery.

The BREAST-Q scores at six months after the surgery showed that there were statistically significant differences in chest well-being and psychological well-being between the SIE-BCS group and the C-BCS group. This could be due to avoiding an incision on the breast surface. These results indicate that

choosing SIE-BCS may bring a better psychological status and higher quality of life to the patient. We observed that there was no statistically significant difference breast satisfaction between the two groups. The reason may be that both groups received breast-conserving surgery. Surprisingly, we observed that the SIE-BCS group had a better score than the C-BCS group for adverse effects of radiation. By removing one incision for SIE-BCS, there is no longer a scar on the breast surface that may cause discomfort from scar contracture during radiotherapy. The reduction of side effects from radiotherapy and an improvement in chest well-being in SIE-BCS patients likely contributed to the improvement of psychological well-being.

Because the HER2 positivity rate was different between the two groups, logistic regression analysis was performed. HER2 positivity rate, method of operation, tumor size, and age were included in the analysis. The results showed that choosing SIE-BCS did not increase the risk of local recurrence or metastasis. HER2 positivity rate, tumor size, and age were not independent risk factors for local recurrence and metastasis in this study. However, other studies have found that HER2 status, tumor size, and age are risk factors for recurrence [24, 25]. This inconsistency is likely due to a small sample size and short follow-up period in our report. A future prospective study has been designed to further clarify this finding.

Conclusion

In this study, we introduced a novel single-port endoscopic method of breast-conserving surgery called SIE-BCS that reduced the length and number of incisions. SIE-BCS patients reported significantly better scores for adverse effects of radiation, chest well-being, and psychological well-being compared to C-BCS patients. Logistic regression analysis showed that SIE-BCS did not increase the risk of local recurrence and metastasis. Because this study was a retrospective study with a short follow-up time, we have designed a prospective study to further prove the feasibility and success of this novel breast-conserving method.

Declarations

Abbreviations

C-BCS
Conventional breast-conserving surgery
CI
Confidence interval
OR
Odds ratio
SIE-BCS
Single-port insufflation endoscopic breast-conserving surgery

Declarations

Funding: This work is supported by the grants of: (1) Capital's Funds for Health Improvement and Research (2020-2-1112); and (2) Research Foundation of Beijing Friendship Hospital, Capital Medical University (yyqdkt2018-11).

Conflicts of interest/Competing interests: The authors declare that the research was conducted in the absence of any commercial or financial relationships that could be construed as a potential conflict of interest.

Ethics approval: All of the surgical procedures were approved by the Ethics Committee of the Beijing Friendship Hospital, Capital Medical University (Beijing, China) (document number: 2016-P2-070-02) and were performed in line with the principles of the Declaration of Helsinki.

Consent to participate: All informed consent details were approved by the Ethics Committee of the Beijing Friendship Hospital, Capital Medical University (Beijing, China) (document number: 2016-P2-070-02).

Consent for publication: Consent to publish was included in the informed consent details approved by the Ethics Committee of the Beijing Friendship Hospital, Capital Medical University (Beijing, China) (document number: 2016-P2-070-02).

Availability of data and material: Not applicable

Code availability: Not applicable

Authors' contributions: Zi-Han Wang was responsible for manuscript writing. Fang Xie and Xiang Qu were responsible for concept and protocol development. Shan-Shan Wu was responsible for statistical analysis. Tian-Ran Gang and Guo-Xuan Gao were responsible for recruitment of study patients. All authors were responsible for final approval of the manuscript and were accountable for all aspects of the work.

References

1. Bray F, Ferlay J, Soerjomataram I et al (2018) Global cancer statistics 2018: GLOBOCAN estimates of incidence and mortality worldwide for 36 cancers in 185 countries. CA Cancer J Clin 68:394–424. https://doi.org/10.3322/caac.21492
2. DeSantis CE, Ma J, Gaudet MM et al (2019) Breast cancer statistics, 2019. CA Cancer J Clin 69:438–451. https://doi.org/10.3322/caac.21583
3. Chen W, Zheng R, Baade PD et al (2016) Cancer statistics in China, 2015. CA Cancer J Clin 66:115–132. https://doi.org/10.3322/caac.21338
4. Sinnadurai S, Kwong A, Hartman M et al (2019) Breast-conserving surgery versus mastectomy in young women with breast cancer in Asian settings. BJS Open 3:48–55. https://doi.org/10.1002/bjs5.50111

5. Chen R, You S, Yin Z et al (2019) Non-doctoral factors influencing the surgical choice of Chinese patients with breast cancer who were eligible for breast-conserving surgery. World J Surg Oncol 17:189. https://doi.org/10.1186/s12957-019-1723-4
6. Kelsall JE, McCulley SJ, Brock L et al (2017) Comparing oncoplastic breast conserving surgery with mastectomy and immediate breast reconstruction: Case-matched patient reported outcomes. J Plast Reconstr Aesthet Surg 70:1377–1385. https://doi.org/10.1016/j.bjps.2017.05.009
7. Ye JC, Yan W, Christos PJ et al (2015) Equivalent Survival With Mastectomy or Breast-conserving Surgery Plus Radiation in Young Women Aged < 40 Years With Early-Stage Breast Cancer: A National Registry-based Stage-by-Stage Comparison. Clin Breast Cancer 15:390–397. https://doi.org/10.1016/j.clbc.2015.03.012
8. National Comprehensive Cancer Network (2017) Clinical Practice Guidelines in Oncology. Breast Cancer. http://www.nccn.org/professionals/physician_gls/pdf/breast.pdf. Accessed 6 Apr 2017
9. Pusic AL, Klassen AF, Scott AM et al (2009) Development of a new patient-reported outcome measure for breast surgery: the BREAST-Q. Plast Reconstr Surg 124:345–353. https://doi.org/10.1097/PRS.0b013e3181aee807
10. Cano SJ, Klassen AF, Scott AM et al (2012) The BREAST-Q: further validation in independent clinical samples. Plast Reconstr Surg 129:293–302. https://doi.org/10.1097/PRS.0b013e31823aec6b
11. van Dongen JA, Voogd AC, Fentiman IS et al (2000) Long-term results of a randomized trial comparing breast-conserving therapy with mastectomy: European Organization for Research and Treatment of Cancer 10801 trial. J Natl Cancer Inst 92:1143–1150. https://doi.org/10.1093/jnci/92.14.1143
12. Abdulkarim BS, Cuartero J, Hanson J et al (2011) Increased risk of locoregional recurrence for women with T1-2N0 triple-negative breast cancer treated with modified radical mastectomy without adjuvant radiation therapy compared with breast-conserving therapy. J Clin Oncol 29:2852–2858. https://doi.org/10.1200/JCO.2010.33.4714
13. Tenofsky PL, Dowell P, Topalovski T, Helmer SD (2014) Surgical, oncologic, and cosmetic differences between oncoplastic and nononcoplastic breast conserving surgery in breast cancer patients. Am J Surg 207:398–402. https://doi.org/10.1016/j.amjsurg.2013.09.017 discussion 402.
14. Wang Z, Han X (2019) Clinical significance of breast-conserving surgery for early breast cancer and its impact on patient life quality of life. J BUON 24:1898–1904
15. Gold M, Dunn LB, Phoenix B et al (2016) Co-occurrence of anxiety and depressive symptoms following breast cancer surgery and its impact on quality of life. Eur J Oncol Nurs 20:97–105. https://doi.org/10.1016/j.ejon.2015.06.003
16. Xu S, Tang P, Chen X et al (2016) Novel technique for laparoscopic harvesting of latissimus dorsi flap with prosthesis implantation for breast reconstruction: A preliminary study with 2 case reports. Med (Baltim) 95:e5428. https://doi.org/10.1097/MD.0000000000005428
17. Takahashi H, Fujii T, Nakagawa S et al (2014) Usefulness of endoscopic breast-conserving surgery for breast cancer. Surg Today 44:2037–2044. https://doi.org/10.1007/s00595-013-0767-2

18. Wang Z-H, Ng H-I, Teng C-S et al (2019) Outcomes of single-port gasless laparoscopic breast-conserving surgery for breast cancer: An observational study. Breast J 25:461–464. https://doi.org/10.1111/tbj.13249
19. Camp ER, McAuliffe PF, Gilroy JS et al (2005) Minimizing local recurrence after breast conserving therapy using intraoperative shaved margins to determine pathologic tumor clearance. J Am Coll Surg 201:855–861. https://doi.org/10.1016/j.jamcollsurg.2005.06.274
20. Jacobs L (2008) Positive margins: the challenge continues for breast surgeons. Ann Surg Oncol 15:1271–1272. https://doi.org/10.1245/s10434-007-9766-0
21. Ammori BJ, Asmer H, Al-Najjar H et al (2020) Laparoscopic Versus Open D2 Gastrectomy for Gastric Cancer: A Case-Matched Comparative Study. J Laparoendosc Adv Surg Tech 30:777–782. https://doi.org/10.1089/lap.2020.0023
22. Al-Saif F, Aldekhayel M, Al-Alem F et al (2019) Comparison study between open and laparoscopic liver resection in a Saudi Tertiary Center. SMJ 40:452–457. https://doi.org/10.15537/smj.2019.5.24086
23. Chen C, Huang S, Huang A et al (2018) Total endoscopic thyroidectomy versus conventional open thyroidectomy in thyroid cancer: a systematic review and meta-analysis. TCRM Volume 14:2349–2361. https://doi.org/10.2147/TCRM.S183612
24. Mosayebi A, Mojaradi B, Bonyadi Naeini A, Khodadad Hosseini SH (2020) Modeling and comparing data mining algorithms for prediction of recurrence of breast cancer. PLoS ONE 15:e0237658. https://doi.org/10.1371/journal.pone.0237658
25. Lertsithichai P, Sakulchairungreung B, Chirappapha P et al (2016) Effect of young age, positive margins, and triple negative status on disease recurrence after breast conserving therapy. Gland Surg 5:15–23. https://doi.org/10.3978/j.issn.2227-684X.2015.05.08

Figures

Figure 1

Injection of methylene blue to identify sentinel lymph nodes and tumor margin. The sentinel lymph nodes were identified by injecting methylene blue into the areola. To determine the resection range, methylene blue was injected 1 cm away from the tumor margin. The single-port incision was marked along the wrinkles in the axilla



Figure 2

Tunneler used for single-port insufflation endoscopic breast-conserving surgery. The tunneler was inserted into the subcutaneous layer to reveal the potential space between the skin flap and the mammary gland



Figure 3

The single-port insufflation kit. Carbon dioxide was introduced into the body cavity to create adequate working space. The base plate is adjustable

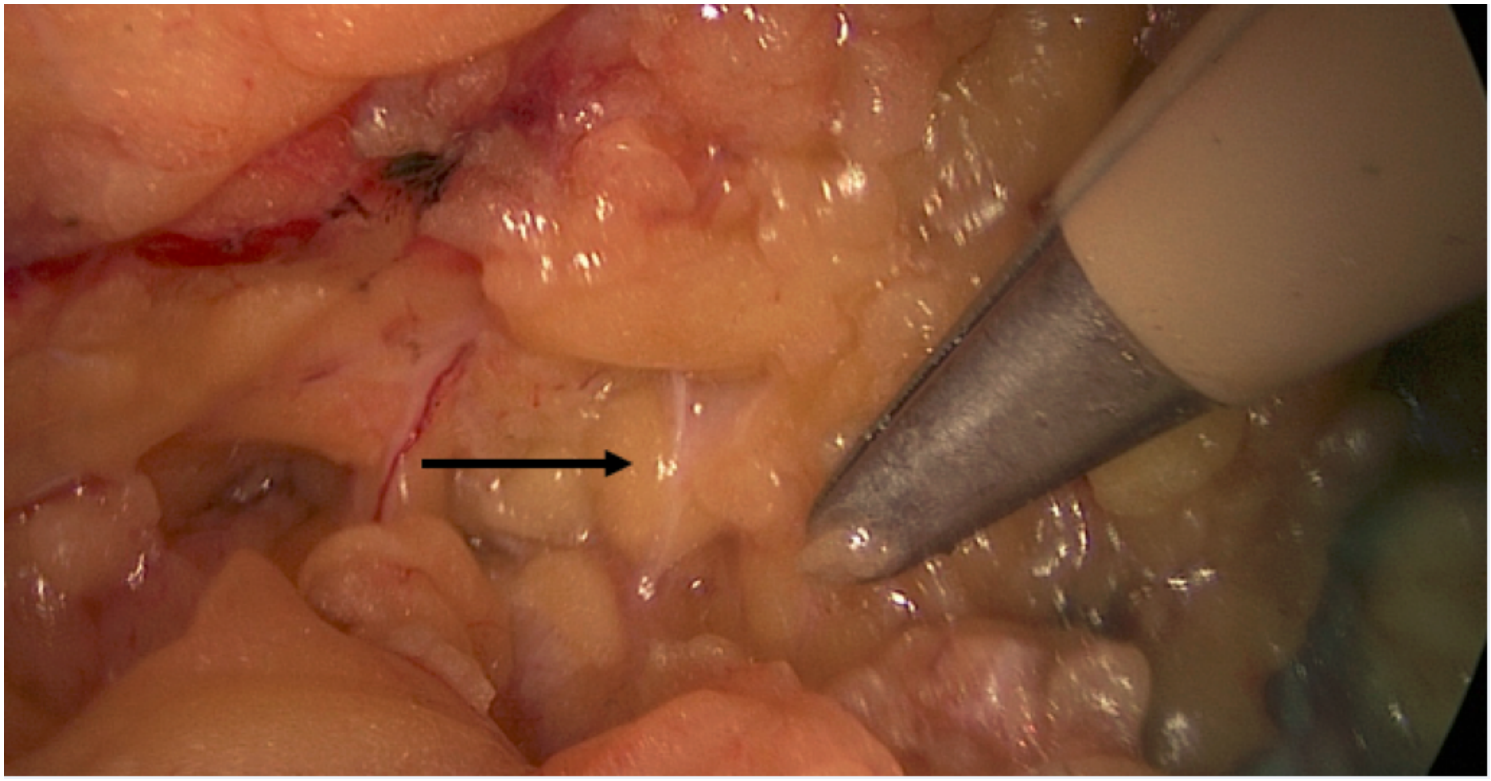

Figure 4

After insufflation, the Cooper's ligament was revealed between the skin flap and the mammary gland. The black arrow indicates the Cooper's ligament under laparoscopic view

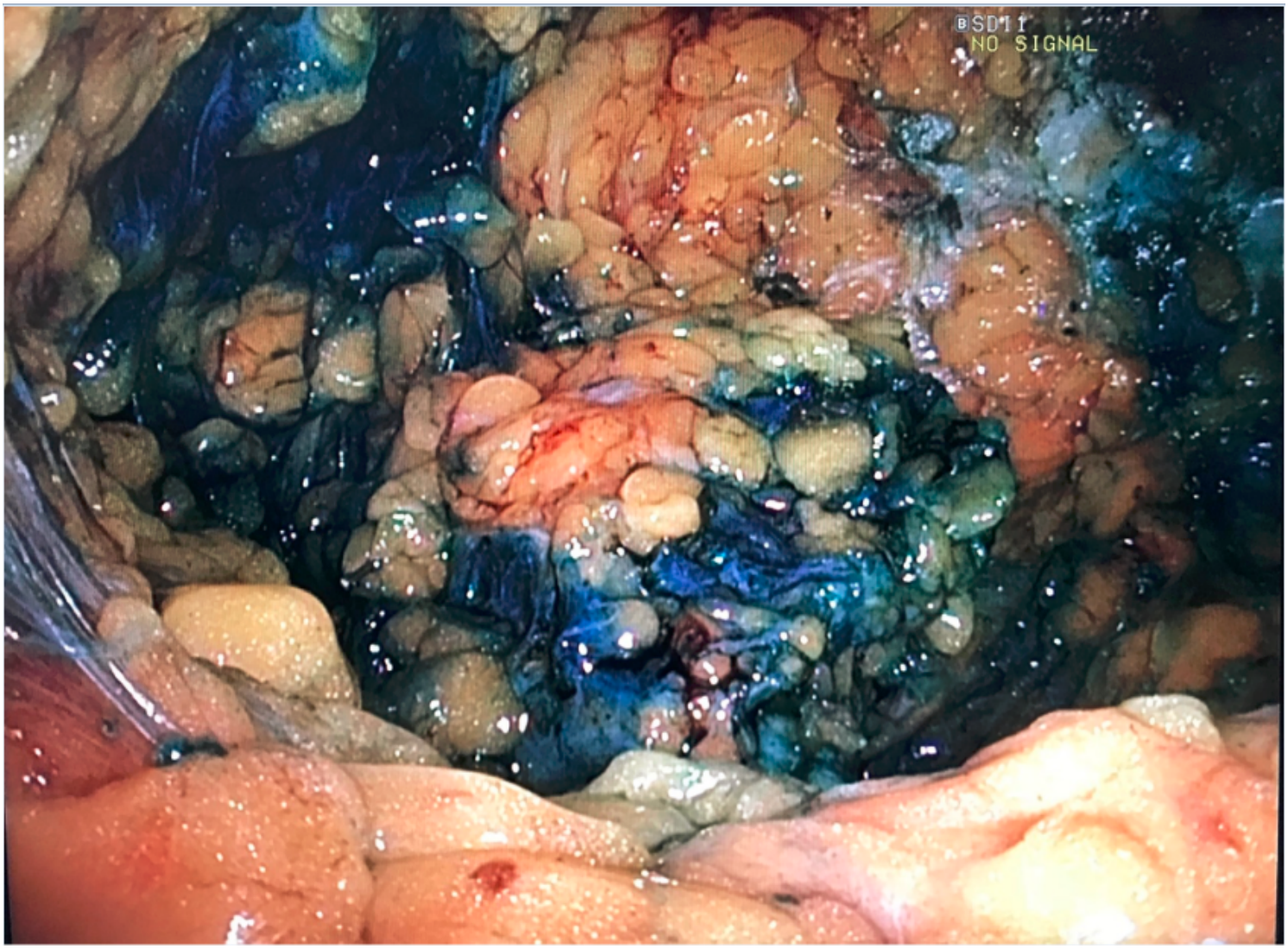

Figure 5

The surface of the mammary gland to the pectoral fascia was vertically sectioned. The yellow star indicates the tumor location, and the yellow arrows show the dissection range, which was marked by methylene blue

Figure 6

The single-port incision and the specimen

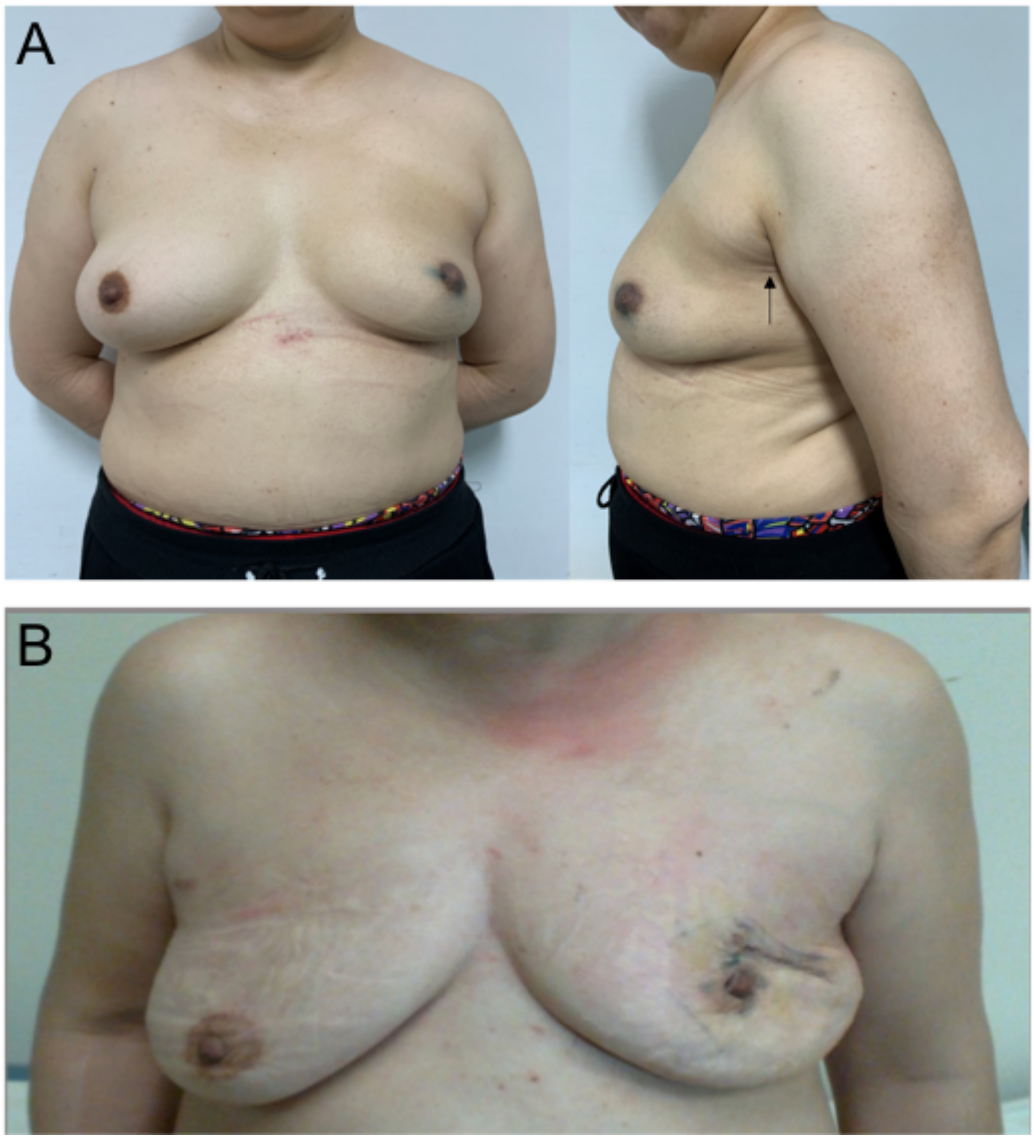

Figure 7

A) The single-port incision was hidden by the upper limb and axillary fossa. The elegant appearance after the operation was evident from the frontal and lateral photographs. No scar was observed from the front. The black arrow indicates the hidden single-port scar in the lateral photo. B) Routine breast-conserving surgery leaves two obvious incisions on the axillary fossa and the breast surface