Treatment Of Ruptured Tiny Intracranial Aneurysms By Electrocoagulation With Guidewire Manipulation:12 Cases Report

Lixia Xia
Zhongfei Hao
Hongjun Wang
Yan Feng
Yongxuan Zhan
Minghui Chen
Peng Xie
Qingbin Li
Ruiyan Li
Yang Liu
Feng Wang
Yuequn Fang
Youxiang Li (liyouxiang@263.net)
Yongli Li (liyongli9999@163.com)

Research

Keywords: Intracranial aneurysm, Rupture, Guidewire manipulation, Endovascular intervention, Tiny aneurysm, Electrocoagulation

Posted Date: June 17th, 2020

DOI: https://doi.org/10.21203/rs.3.rs-30106/v1

Abstract

Background: Ruptured tiny intracranial aneurysm (RTIA) is particularly rare seen. Treatment of RTIA is more difficult and not under control.

Methods: We hereby present twelve rare cases of RTIA that were diagnosed based on DSA. These patients were found due to spontaneous or traumatic SAH, 11 of whom were treated only by electrocoagulation, and one of whom was treated by stent-assisted coiling and electrocoagulation.

Results: There were eight patients with aneurysms located in posterior circulation and four patients with aneurysms located in anterior circulation. 11 patients were cured only by electrocoagulation merely: ten patient' RTIA disappeared completely and immediately and another patient's RTIA was thrombosed two months later. The twelfth patient was carried out stent-assisted coiling and electrocoagulation. The twelve patients' average follow-up time was 12.5 months and the outcomes were all surprisingly excellent. No revascularization of aneurysm was found.

Conclusions: Electrocoagulation with guidewire manipulation is a suitable method to treat RTIA. While large-scale studies with long-term follow-up are required to validate these promising results.

Background

RTIA, generally considered to be those of 3mm diameter or smaller, pose special technical challenges for endovascular surgeons. RTIA is particularly rare seen, representing approximately 1% of all intracranial aneurysms, and 0.5–2% of all ruptured aneurysms [1]. With the widespread adoption of three-dimensional (3D) rotational angiography, RTIA has been more frequently diagnosed, which has previously been considered to have a high rate of intraprocedural ruptures. It is a tough problem for neurosurgeons to choose appropriate operations because of more aggressive behaviors compared with saccular aneurysms and more occurred intra-operative complications [2].There are more probabilities to recur and rebleed in perioperative period. A previous meta-analysis that included only seven studies observed is latively high complication rate, especially in terms of periprocedural rupture risk [3]. Electrocoagulation was applied to treat non-intracranial aneurysm in 19 th century, which could promote thrombosis in aneurysm. Youxiang Li was the first to cure intracranial aneurysms through electrocoagulation technology [4].

Baseline Characteristics

We enrolled 12 patients with tiny intracranial aneurysms in our department to adopt endovascular treatment with guidewire electrocoagulation technology from January 2017 to October 2019, and all patients suffered subarachnoid hemorrhage (SAH). There were five male patients and seven female patients, with the ages ranging from six years old to 60 years old. The six-year-old female patient was found due to traumatic subarachnoid hemorrhage and the others were middle-aged and elder patients found because of spontaneous SAH. The twelve patients were examined based on Hunt-Hess grades that

six patients suffered with grade I, four patients with grade II and two patients with grade III. All patients received endovascular treatment within seven days after symptom onset.

Aneurysms Image

All patients took intracranial computerized tomography (CT) to verify SAH before endovascular treatment. RTIA was confirmed by Digital Subtraction Angiography (DSA) in multi-angular rotation. Table 1 showed that there were eight patients with aneurysms located in posterior circulation and four patients with aneurysms located in anterior circulation. Common coiling method was difficult for this kind of aneurysms.

Table 1
Details of all twelve patients

Age(years)	Aneurysms Location	Aneurysms Size(mm)	Clinical Outcomes	Follow-up Time(months)
6	ICA	0.7*1.2	Cured	27
39	AComA	1*2.6	Cured	12
57	BA	0.5*0.8	Cured	10
47	BA	0.6*1.2	Cured	13
48	BA	0.7*0.9	Delayed Cure	14
52	AChA	0.6*1.4	Cured	12
43	SCa	1.2*1.8	Cured	13
50	BA	0.7*1.5	Cured	6
55	AICA	1.2*2.5	Cured	15 (telephone)
58	AChA	0.5*1.0	Cured	8 (telephone)
60	BA	2.0*2.9	Cured	10 (telephone)
49	BA	0.8*0.9	Cured	10 (telephone)

Operation

The endovascular treatment was carried out under general anesthesia and systemic heparinization to prevent arterial thromboses. The operator performed right femoral artery Seldinger puncture and put into a 6F artery sheath. After reshaping the tip of guidewire according to the angle between aneurysm and parent artery, we introduced the Traxcess 14 guidewire (Microvention, Columbia Aliso Viejo, USA) into the RTIA, advanced the microcatheter close to the pedicle, connected Traxcess to the Solitaire stent detachment system (ev3 Neurovascular, Irvine, USA) at about 4V and 1.0 mA electronic current, and passed current through it for 4 min, which was repeated for 3-5 times. 11 patients were carried out above

procedure. But for the 6-year-old girl, we performed right femoral artery Seldinger puncture and put into a 5F artery sheath, DSA showed aneurysm was enlarged from 0.7×1.2mm(Fig 1a) to 3×3mm(Fig 1b) in two weeks, so that the risk of rebleeding increased. The RTIA was filled with 4 coils(Fig 1c) (Axium QC-2-6-Helix, NC-2-6-Helix, QC-1.5-4-Helix, APB-1-3 -HX-ES), then using jailing technique with a LVIS stent(3.5-15, Microvention, Columbia Aliso Viejo, USA). However there was a small cavity in the inflow tract, no more coils could be filled into it. The Nylon coil was in our expectation to promote thrombosis. One week later, unfortunately, the cavity was enlarged again(Fig 1d). The operator expected electrocoagulation would take effect, which we carried out three times(Fig 1e), then the cavity disappeared completely and immediately.

Postoperative Treatment and Follow-up

After the procedure, heparin was neutralized naturally, and the patient returned to NICU after waking up under anesthesia. Analgesia, hypotensive medical treatment and nimodipine, a kind of anti-vasospasm medicine, were given; intracranial CT was performed again within one day after the procedure. It was recommended that follow-up DSA should be performed in the third month and at the end of the first year. Patients, who are unable to receive follow-up DSA, should be instructed to receive CTA and followed up by telephone review(Table 1).

Results

It was found in the patients by DSA that RTIAs were located at the initial site of tiny perforating branch artery or the wall of the unbranched blood vessel. Embolization was effective in treating aneurysms with guidewire electrocoagulation technology(Fig 2). In general, decreasing times of electrocoagulation were found in patients with the narrower aneurysm neck, which made aneurysms occluded faster. Through DSA, complete embolization of aneurysms was seen in 11 patients and incomplete embolization of aneurysms at aneurysm neck was seen in 1patient. The latter received follow-up DSA within two months and the result showed the aneurysm was delayed to be cured(Fig 3).

No complications existed in all patients. High-density thrombus image was seen by DSA after endovascular treatment with guidewire electrocoagulation technology in some patients, and it was not implicated in the parent artery and peripheral perforating branch artery. Meanwhile, it was observed the thrombus in aneurysms would not reach the parent artery for 15 min during the procedure. Except for the six-year-old girl, anticoagulant or antiplatelet medical therapy was not applied to the thrombus in aneurysms after the procedure. The six-year-old girl was required to take 75mg Plavix orally each day for three months and 50mg Aspirin orally each day for six months. Symptoms of hemorrhage and ischemic stroke were not found in all patients and they were discharged from hospital within two weeks after endovascular treatment with guidewire electrocoagulation technology.

Follow-up Results

The twelve patients' average follow-up time was 12.5 months(Table 1). Five patients received follow-up by DSA; three patients received follow-up by CTA and four patients received follow-up by telephone. Recurrent aneurysms were not found in those patients who had received image examination, and all patients had favorable clinical outcomes and did not have SAH again during follow-up period.

Discussions

Because of the small diameter of the RTIA, it is difficult to clip. During the cliping process, it is easily to tear the neck of the RTIA and the clip is easily to loosen or fall off. Compared with the clipping group, it was less frequently for the endovascular treatment related complications to occur. Furthermore, the following technical factor is closely associated with the successful endovascular treatment with a low risk of intraprocedural rupture [5]. The International Subarachnoid Aneurysm Trial (ISAT) showed better independent survival at one year for patients with coiled ruptured intracranial aneurysms compared with clipping [6].

Endovascular treatment offers a lower morbidity–mortality rate compared with surgical approaches, but the process is also difficult. For example, it is difficult to make microcatheter into aneurysm; even if it is successful, the stability is poor; the rate of rerupture during the filling process is high; it is difficult to compact embolization, and the rate of rebleeding after operation is high. Coil embolization of RTIA is particularly challenging due to the thin fragile wall of small intracranial aneurysms, with limited space to obtain a stable microcatheter position for coil deployment [7, 8]. Recently, multilayer flow-diverting stents appear to be a promising strategy [9] , but covered stent technology can only be used in limited cases because perforator artery is probably covered by the stent. It is difficult to treat RTIA with conventional methods, and the electrocoagulation shows the advantages of being easy to operate and getting reliable results in our department' treatment of 12 patients.

Here summarized the technical points of electrocoagulation:

1. The tip of the microcatheter is close to the opening of the aneurysm, so it does not need to enter the aneurysm cavity so as to reduce the risk of perforation.
2. Select conductive micro guidewires, such as Traxcess14, Asahi, to enter the aneurysm cavity.
3. The positive wire is connected to the uncoated part at the tail end of the micro guiedwire, and the negative wire is connected to the steel needle which is tied in the groin skin.
4. Choose 4V DC battery pack and Solitaire stent detachment system (ev3 Neurova- scular, Irvine, USA).
5. Electrocoagulation for 4min each time, generally 3-5 times.
6. Because of the high risk caused by too many times electrocoagulation, the patients who did not form complete thrombus immediately after electrocoagulation could wait for delayed thrombus formation.

The main concern about this guidewire electrocoagulation technology is its durability. But the twelve patients' average follow-up time was 12.5 months which fully proved the excellent short-term effectiveness. Guidewire manipulation provides a new thought when microcatheter could not be

navigated into the aneurysm. With the exception of RTIA whether it can be applied to other vascular diseases, like arteriovenous malformation, dural arteriovenous fistulas or other small vascular diseases, needs further exploration.

Conclusion

Electrocoagulation with guidewire manipulation represents a new thought in the technique of RTIA treatment, which is effective and safe through short-term observation. Larger studies with long-term follow-up are required to validate these promising results.

Abbreviations

CT: Computed tomography;

DSA: Digital subtraction angiography;

SAH: Subarachnoid hemorrhage;

RTIA: Ruptured tiny intracranial aneurysm

Declarations

Ethics approval and consent to participate

This study has been approved by the Ethics Committee in the hospital and the authors obtained informed consent from the patient and his family.

Consent for publication

The authors obtained consent for publication from the patient.

Competing interests

The authors declare that they have no competing interests.

Funding

The authors received no funding related to this paper.

Availability of data and materials

Not applicable.

Acknowledgements

Not applicable.

Authors’ contributions

Yongli Li and Youxiang Li are both the corresponding author; Lixia Xia make substantial contributions to conception and design, and acquisition of data, and analysis and interpretation of data; Zhongfei Hao and Hongjun Wang is a major contributor in writing the manuscript; Yan Fen, Yongxuan Zhan, Peng Xie and Minghui Chen participate in drafting the article; and Qingbin Li, Ruiyan Li, Feng Wang,Yang Liu and Yuequn Fang give final approval of the version to be submitted and any revised version; All authors have read and approved the final manuscript.

Authors' information

[1]Department of Neurosurgery, the Second Affiliated Hospital of Harbin Medical University, Harbin, Heilong Jiang Province, China

[2] Department of Neurosurgery, Wuchang Hospital of Traditional Chinese Medicine, Heilong Jiang Province, China

[3]Department of interventional neuroradiology, Beijing Neurosurgical Institute and Beijing Tiantan Hospital, Capital Medical University, Beijing, China

[4]Beijing Interventional Neuroradiology Engineering Technology Research Center, 6, Tiantan Xili, Chongwen, Beijing 100050, People ’s Republic of China

References

1. Lee BH, Kim BM, Park MS, Park SI, Chung EC, Suh SH,et al. Reconstructive endovascular treatment of ruptured blood blister-like aneurysms of the internal carotid artery. Journal of neurosurgery. 2009;110:431–6. https://doi.org/10.3171/2008.7.JNS08257.
2. Xu F. Treatment strategies for ruptured blood blister-like aneurysms of the internal carotid artery. Neurosurgery. 2014;74:E154–5. https://doi.org/10.1227/NEU.00000000 00000179.
3. Brinjikji W, Lanzino G, Cloft HJ, Rabinstein A, Kallmes DF. Endovascular treatment of very small (3 mm or smaller) intracranial aneurysms: report of a consecutive series and a meta-analysis. Stroke. 2010;41:116–21. https://doi.org/10.1161/STROKEAHA.109.566 356.
4. Jiang Y, Luo J, Zheng J, Li Y. Endovascular pure electrocoagulation of intracranial perforator blister-like aneurysm not accessible to microcatheter-New approach to treat small vessel hemorrhage disease. International journal of stroke: official journal of the International Stroke Society. 2016;11:NP60–61. https://doi.org/10.1177/174749301664 1953.
5. Wei M, Ren H, Yin L. The combinational use of dual microcatheter technique and new hypersoft helical coil for endovascular treatment of tiny intracranial aneurysm with difficult geometry.

Interventional neuroradiology: journal of peritherapeutic neuroradiology surgical procedures related neurosciences. 2016;22:18–25. https://doi.org/10.1177/1591019915609124.

6. Molyneux A, Kerr R, Stratton I, Sandercock P, Clarke M, Shrimpton J,et al. International Subarachnoid Aneurysm Trial (ISAT) of neurosurgical clipping versus endovascular coiling in 2143 patients with ruptured intracranial aneurysms: a randomised trial. Lancet. 2002;360:1267–74. https://doi.org/10.1016/s0140-6736(02)11314-6.
7. Nguyen TN, Raymond J, Guilbert F, Roy D, Berube MD, Mahmoud M,et al. Association of endovascular therapy of very small ruptured aneurysms with higher rates of procedure-related rupture. Journal of neurosurgery. 2008;108:1088–92. https://doi.org/10.3171/JNS/2008/108/6/1088.
8. Lim YC, Kim BM, Shin YS, Kim SY, Chung J. Structural limitations of currently available microcatheters and coils for endovascular coiling of very small aneurysms. Neuroradiology. 2008;50:423–7. https://doi.org/10.1007/s00234-008-0365-y.
9. Kuhn AL, Hou SY, Perras M, Brooks C, Gounis MJ, Wakhloo AK,et al. Flow diverter stents for unruptured saccular anterior circulation perforating artery aneurysms: safety, efficacy, and short-term follow-up. Journal of neurointerventional surgery. 2015;7:634–40. https://doi.org/10.1136/neurintsurg-2014-011237.

Figures

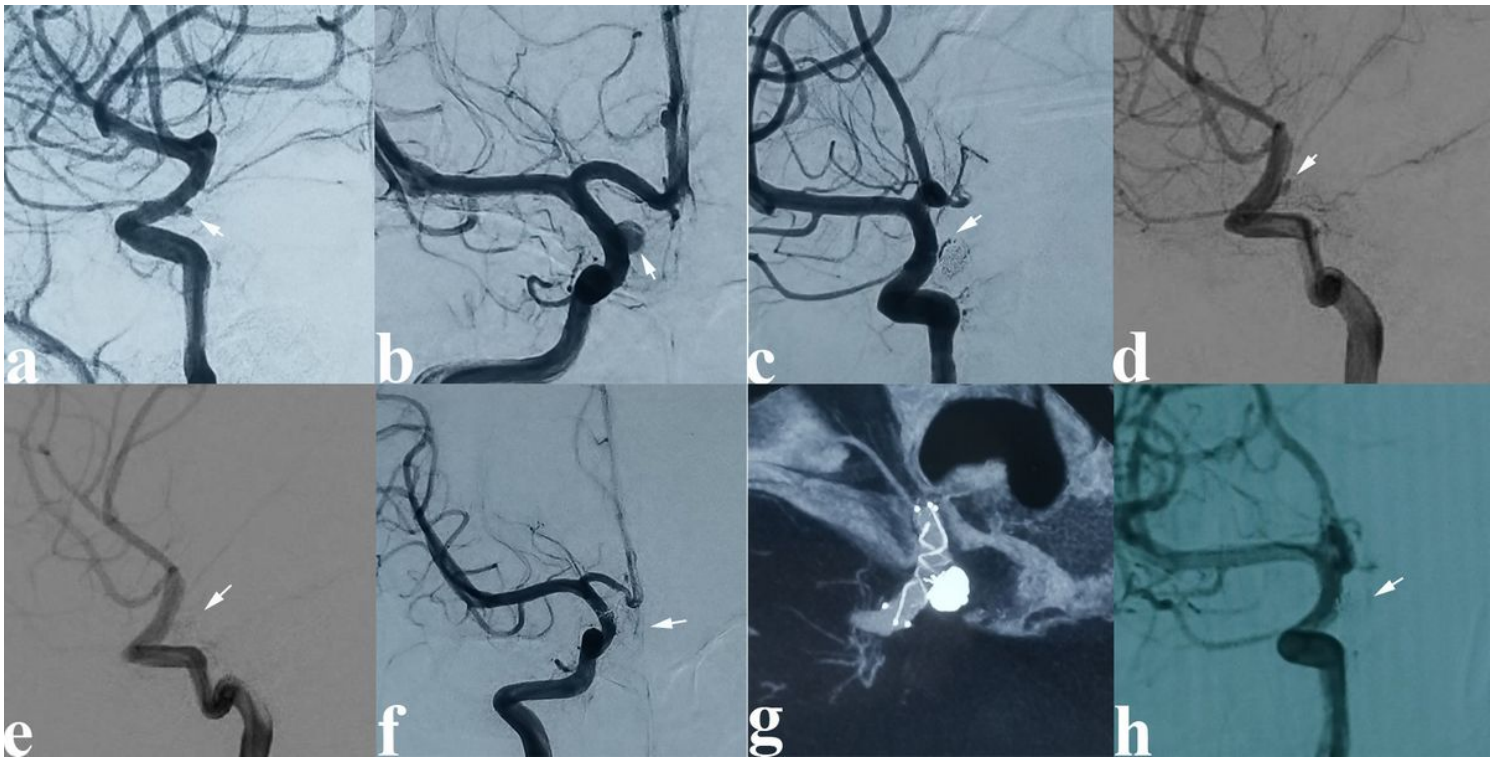

Figure 1

a-f: The patient presented epilepsy and coma after head trauma. DSA showed RTIA in right internal carotid artery(0.7×1.2mm)(a). After two weeks, the RTIA was enlarged to 3×3mm(b). Stent assisted-coiling was fulfilled with a small cavity in the inflow tract(c). One week later, the cavity was enlarged again(d). We carried out the electrocoagulation for 4min, which was repeated for another three times, then the cavity disappeared completely and immediately(e). DSA and VASO CT after three months showed no recurrence(f). DSA after 27 months showed no recurrence, either(g).

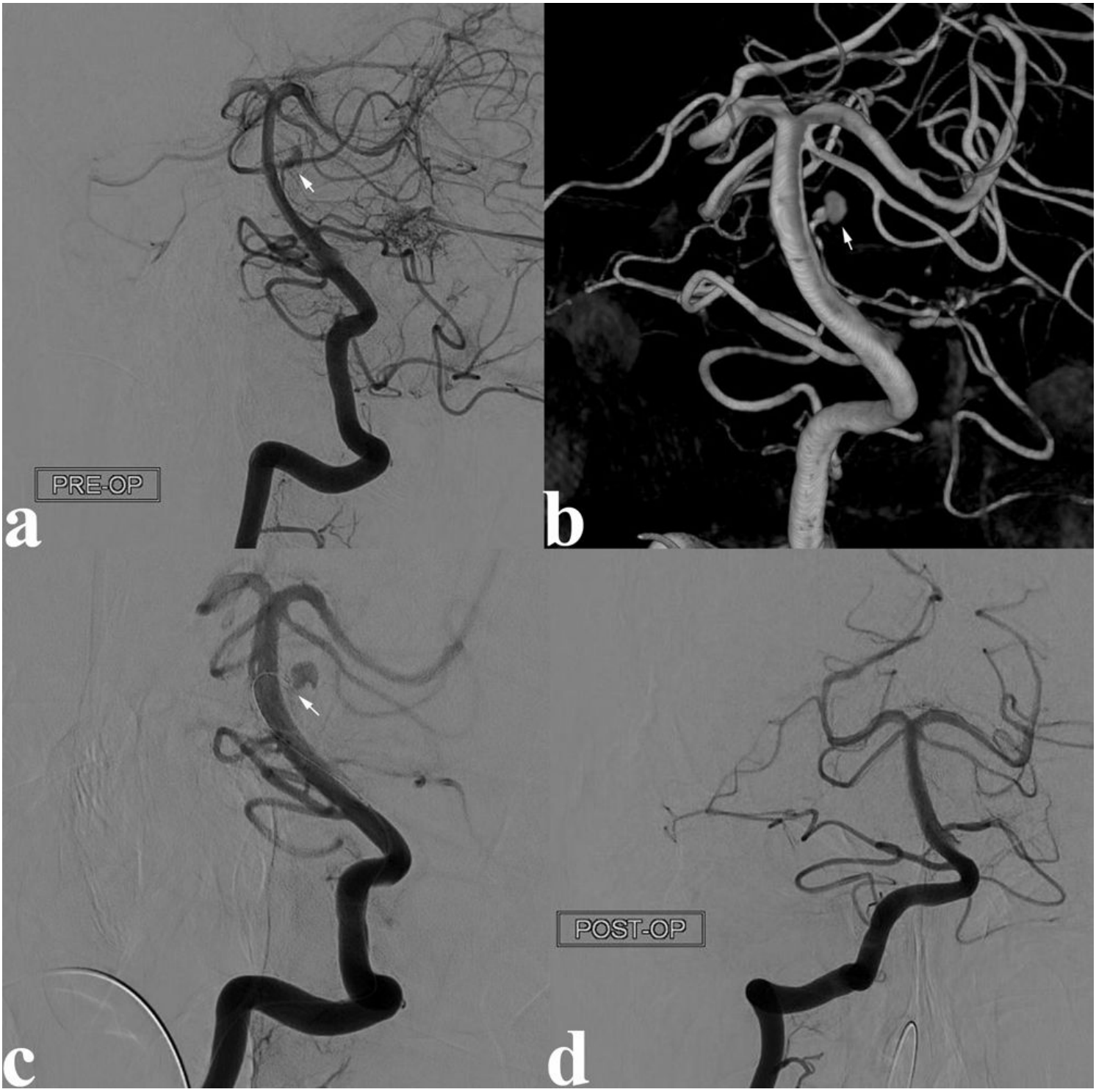

Figure 2

a-d: A 60 year-old male patient presented with a sudden severe headache. Pre-operated DSA showed RTIA was located in basal artery(a,b). After electrocoagulation for three times(c), the RTIA disappeared immediately(d).

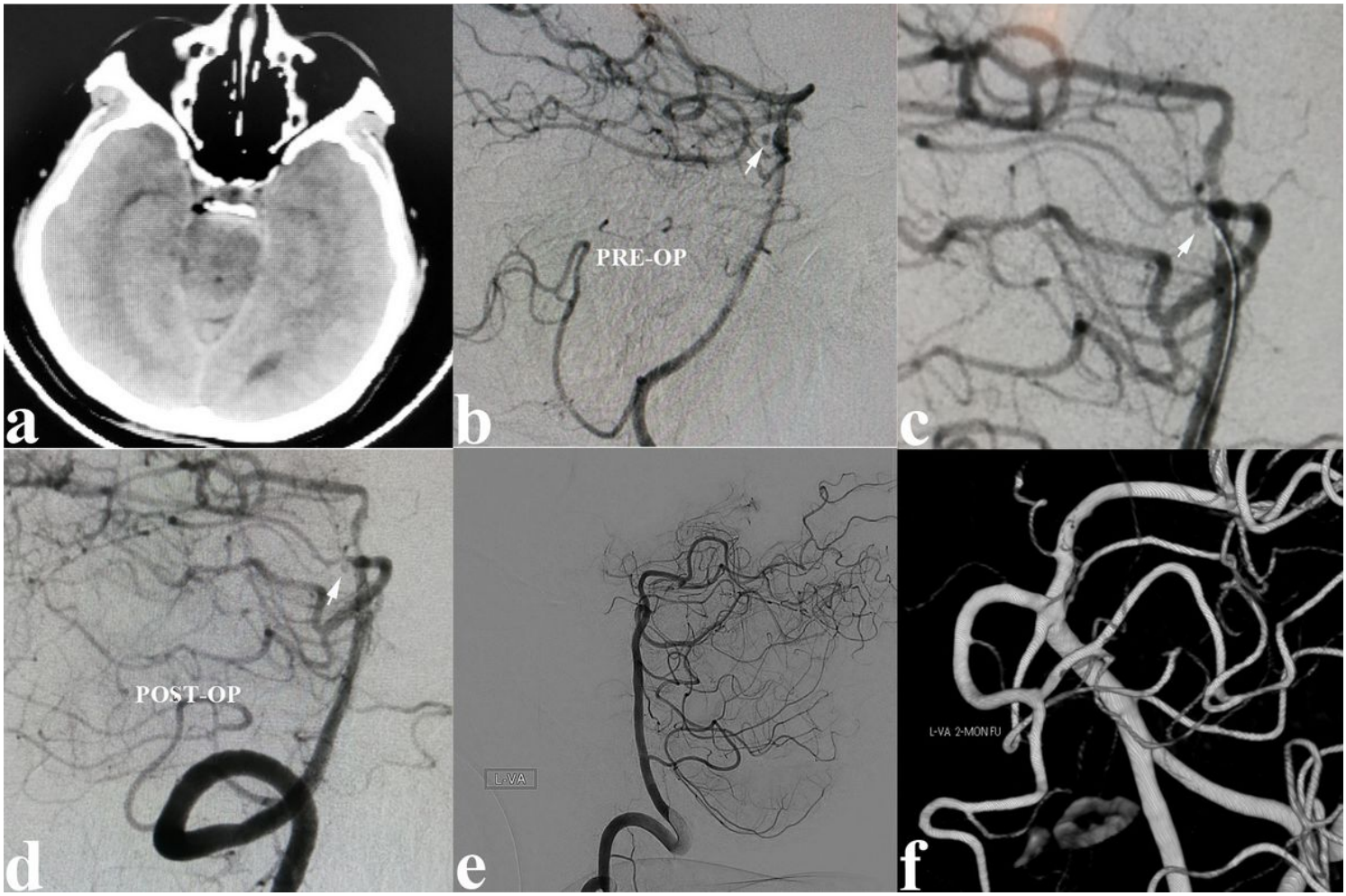

Figure 3

a-f: A 48-year-old patient presented with a severe sudden headache. CT scan (a) showed diffused subarachnoid hemorrhage. DSA of pre-operated performed a RTIA in basal artery(b), then we carried out electrocoagulation for three times only to find the forming of incomplete thrombi in the RTIA(d). Two months later, DSA showed RTIA had disappeared(e,f).