Clinical and CT Features of the COVID-19 Infection: Comparison among different four age groups

Wei Li
The Fifth Affiliated Hospital, Department of Radiology, Sun Yat-sen University https://orcid.org/0000-0003-0236-4214
Yijie Fang
Jianwei Liao
Wenjun Yu
Lin Yao
Huaqian Cui
Xiang Zeng
Shaolin Li (lishlin5@mail.sysu.edu.cn)
The Fifth Affiliated Hospital, Department of Radiology, Sun Yat-sen University https://orcid.org/0000-0003-1965-0217

Research Article

Keywords: Coronavirus; Pneumonia; COVID-19; Computer Tomography; Age Groups

Posted Date: May 21st, 2020

DOI: https://doi.org/10.21203/rs.3.rs-30392/v1

Version of Record: A version of this preprint was published at European Geriatric Medicine on July 13th, 2020. See the published version at https://doi.org/10.1007/s41999-020-00356-5.

Abstract

Purpose: To compare and analyze the clinical and CT features of coronavirus disease 2019 (COVID-19) among different four age groups.

Methods: 97 patients with chest CT examination and positive reverse transcriptase polymerase chain reaction test (RT-PCR) from January 17, 2019 to February 21, 2020 were reviewed. The first clinical symptoms of each patient were collected and their first chest CT images were observed by dividing them into 4 groups according to age: junior, young, middle-age, and senior.

Results: Comorbidities are more common in the senior group. Cluster onset is more common in junior group and senior group. Older patients have shown higher incidence with the highest clinical classification of severe or critical in these 4 groups. Senior patients have a higher incidence of large/multiple ground-glass opacity (GGO). Junior patients are mostly negative for chest CT or involve only one lobe of the lung. While in elderly patients, older patients have a higher incidence of involvement of 4 or 5 lung lobes. The frequency of lobe involvement also has significant differences in 4 different age groups.

Conclusion: The clinical and imaging features of patients in different age groups are significantly different. Understanding of these features correctly and making the correct diagnosis promptly is of great significance for the scanning, diagnosis and prevention of COVID-19.

Introduction

Since 31 December 2019, many cases of an “unknown viral pneumonia” have been reported and it was named the 2019 novel coronavirus (2019-nCoV) initially[1]. On February 12, 2020, the World Health Organization (WHO) announced that the official name of the disease caused by the virus is COVID-19[2]. As of April 9, 2020, a total of 1,353,361 cases of COVID-19 have been confirmed in more than 211 countries and regions. As the epidemic develops, the trend is gradually increasing[3]. The epidemic has developed into a global epidemic, and the diagnosis and treatment of the epidemic should be treated urgently[4]. As the number of new cases decreases and cured cases increases in China, a lot of working experience have been accumulated in this battle against the epidemic. Chest CT scan is one of the important methods for the diagnosis of pneumonia. The typical radiographic imaging of COVID-19 pneumonia is destruction of the lung parenchyma, including ground-glass opacities, consolidation, reticulation /interlobular septal thickening, irregular solid nodules and fibrous stripes[5-8]. However, previous reports are only a general retrospective description without specific age grouping. Our hospital is the only designated hospital for newly crowned patients in this city, and the treatment of patients was carried out early. By March 18, 2020, 99% of infected patients have been cured and discharged. 97 patients admitted in our hospital are classified according to different age groups, and their clinical symptoms and pulmonary CT imaging features were analyzed and summarized, in order to further improve the understanding and early diagnosis of the disease.

Materials And Methods

Patients

Our institutional review board approved this retrospective study. Informed consent was waived as the study involved no potential risk to patients. The work described has been carried out in accordance with The Code of Ethics of the World Medical Association (Declaration of Helsinki) for experiments. From January 17, 2019 to February 21, 2020, A total of 98 patients were confirmed. Their diagnosis criteria of COVID-19 infection was confirmed with a positive result to real-time fluorescence reverse transcriptase polymerase chain reaction (RT-PCR) detection of SARS-CoV-2 nucleic acid with nasopharyngeal or oropharyngeal swab specimens. Most of these patients have an epidemiological history or corresponding clinical manifestations. One patient was excluded because no CT scan was performed. A total of 97 infected patients were included in the study, of which 45 were male (46.4%) and 52 were female (53.6%). All patients were divided into 4 groups, and they are junior group (0-17 years, mean age, 5.0 years [SD, 5.2]), youth group (18-44 years, mean age, 33.7 years [SD, 6.5]), middle-age group (45-59 years, mean age, 54.7 years [SD, 4.0]), and senior group(≥60 years, mean age, 66.2 years [SD, 5.0]).

Image Acquisition

To avoid cross-infection, all patients were scanned on 3 machines according to clinical requirements. The machine models were PET-CT uMI780, uCT 760, and KAIPU CT precision 32. All patients underwent non-enhanced CT plain scans. The scanning conditions were: 120KV, automatic mAs, layer thickness 1.0cm (PET-CT uMI780, uCT 760), 1.1cm (KAIPU CT precision 32), layer spacing 1.0cm (PET-CT uMI780, uCT 760), 0.7cm (KAIPU CT precision 32).

Imaging Evaluation

Two chest radiologists with 10 and 7 years of experience independently reviewed the CT images while they were blinded to the names and clinical data of these patients. For each of the 97 patients, the initial chest CT images were evaluated for the following characteristics: patchy/punctate GGO, large/multiple GGO, consolidation, reticulation /interlobular septal thickening, irregular solid nodules, fibrous stripes and no related lesions. Patchy/punctate GGO is defined as a single ground glass lesion less than 5 cm in diameter of each lobe, and large/multiple GGO is defined as a single lesion larger than 5 cm in diameter or multiple lesions in each lobe. Regarding the inconsistent results, the two parties reached an agreement through consultation.

Statistical Analysis

All statistical analyses were performed by using SPSS statistical software (version 25, IBM). Categorical variables were described as frequency rates and percentages, and quantitative variables were described using mean (SD) or median (interquartile range, IQR) values. And the Fisher exact test were used for categorical variables with p-values corrected using Bonferroni correction. Quantitative variables were tested for normality using Shapiro-Wilk test. Quantitative variables were analyzed by one-way ANOVA

tests, and homogeneity of variance test was done before ANOVA test. Spearman Correlation Coefficient is used to determine the correlation between two bidirectionally ordered variables. P values < 0.05 were considered as statistically significant.

Results

Characteristics and clinical manifestations

The clinical classification of patients at different groups is shown in Table 1. Among them, the senior group had more comorbidities of hypertension, diabetes mellitus and heart disease($P \leq 0.05$). A total of 85% of patients have cluster onset, with the highest proportion of junior and senior groups (100%). There is a strong positive correlation between the different age groups and highest clinical classification. No significant differences of sex, symptoms and signs, temperature and clinical classification at admission were found among the four groups.

Chest CT findings

The first CT features of different age groups are shown in Table 2 which were taken at admission. The imaging finding of Large/Multiple GGO has a higher incidence in senior group. There is a strong positive correlation between the different age groups and numbers of lobes affected and the number of lesions affected increased with age. Junior group are mostly negative for chest CT or involve only one lobe of the lung. While in senior group, older patients have a higher incidence of involvement of 4 or 5 lung lobes. There were statistical differences between different age groups and frequency of lobe.

Involvement including right upper lobe, right middle lobe, right lower lobe, left upper lobe show significant differences between these 4 age groups. The incidence of bilateral disease is higher (17/24, 70.8%) in senior group. We found no significant differences in CT features of patchy/ punctate GGO, consolidation, reticulation /interlobular septal thickening, irregular solid, nodules, fibrous stripes and distribution among the four groups.

Discussion

Based on the clinical case data of our hospital, larger proportion of patients in the senior group had hypertension, diabetes mellitus and heart disease. It is suggested that elderly patients with multiple comorbidities are more likely to have impaired body function and weakened immune system and thus are more susceptible to the coronavirus. Signs and symptoms are not significantly different in different age groups. Patients of every age may appear fever, cough, expectoration, pharyngeal discomfort, myalgia, fatigue, dizziness, headache, chest tightness. But overall, patients are more likely to have fever, cough and expectoration at the time of onset[9]. So, the patients can be still helped to early screen by these characteristics. But it is worth noting that we found that some patients came for the first symptom with gastrointestinal symptoms, and there were still some patients who did not show symptoms at the time of

onset. Therefore, whether to use other inspection methods to help early screening is a question worth considering.

The first clinical classification of all patients at the time of admission was mostly ordinary, and there was no significant difference among different age groups. But there is a significant difference in the highest clinical classification of all patients. With the increase of age, the clinical classification of patients develops into severe /critical type. This suggests that older patients are more likely to get more severe clinical typing. For these elderly patients, clinicians need to pay special attention early.

In terms of CT features, patchy/punctate GGO is the most common imaging manifestation of coronavirus pneumonia[10]. But there is no obvious difference in this feature among the 4 groups. The only statistically significant one is GGO which is the only sigh appeared in junior group, and the older the age, the higher the proportion of GGO. 25.8% of these confirmed patients had no positive CT signs on admission. In addition, imaging features such as consolidation, reticulation /Interlobular septal thickening, Irregular solid nodules and fibrous stripes also appeared on the patient's CT, but they were not statistically significant. There is a strong correlation between different age groups and the numbers of lobes affected. Older patients have more lobes involved and they are linearly related. This may indicate that older people's lungs are more susceptible to viral infections[11].

In this study, the frequency of lobe involvement with the highest probability of disease were the left lower lobe, but there was no statistical difference. With the increase of age, the probability of occurrence in the right upper lobe, right middle lobe, right lower lobe, and left upper lobe increases. More than half of the patients have simultaneous onset of both lungs and the highest proportion is in the senior group, which is not seen in junior group.

A horizontal retrospective study of these 97 cases shows that typical clinical and CT findings can help early screening of suspicious patient cases of COVID-19. According to the current diagnostic standard "Diagnosis and Treatment of New Coronavirus Pneumonia" (trial version 7)[12], laboratory tests (such as RT-PCR detection, viral gene sequencing, serum new coronavirus-specific antibody detection, etc.) is the standard and formative assessment for the diagnosis of COVID-19 infection[13]. However, CT tests are essential when current laboratory tests are time consuming and fail to meet the needs of a growing number of infected people.

Declarations

Competing interests: The authors declare no competing interests.

References

1. Novel Coronavirus – China. In: Who.int Web site. Who.int Web site. https://www.who.int/csr/don/12-january-2020-novel-coronavirus-china/en/. Accessed April 12 2020.

2. Novel Coronavirus(2019-nCoV) Situation Report – 22. Who.int Web site. https://www.who.int/emergencies/diseases/novel-coronavirus-2019/situation-reports/. Accessed April 12 2020.
3. Coronavirus disease 2019 (COVID-19) Situation Report –82. Who.int Web site. https://www.who.int/emergencies/diseases/novel-coronavirus-2019/situation-reports/. Accessed April 12 2020.
4. WHO Director-General's opening remarks at the media briefing on COVID-19. Who.int Web site. https://www.who.int/dg/speeches/detail/. Accessed March 20 2020.
5. Wu J, Wu X, Zeng W, Guo D, Fang Z, Chen L et al. Chest CT Findings in Patients with Corona Virus Disease 2019 and its Relationship with Clinical Features. Invest Radiol. 2020. doi:10.1097/RLI.0000000000000670.
6. Bernheim A, Mei X, Huang M, Yang Y, Fayad ZA, Zhang N et al. Chest CT Findings in Coronavirus Disease-19 (COVID-19): Relationship to Duration of Infection. Radiology. 2020:200463. doi:10.1148/radiol.2020200463.
7. Xu X, Yu C, Qu J, Zhang L, Jiang S, Huang D et al. Imaging and clinical features of patients with 2019 novel coronavirus SARS-CoV-2. Eur J Nucl Med Mol Imaging. 2020. doi:10.1007/s00259-020-04735-9.
8. Zhao X, Liu B, Yu Y, Wang X, Du Y, Gu J et al. The characteristics and clinical value of chest CT images of novel coronavirus pneumonia. Clin Radiol. 2020;75(5):335-40. doi:10.1016/j.crad.2020.03.002.
9. Li K, Wu J, Wu F, Guo D, Chen L, Fang Z et al. The Clinical and Chest CT Features Associated with Severe and Critical COVID-19 Pneumonia. Invest Radiol. 2020. doi:10.1097/RLI.0000000000000672.
10. Liu KC, Xu P, Lv WF, Qiu XH, Yao JL, Gu JF et al. CT manifestations of coronavirus disease-2019: A retrospective analysis of 73 cases by disease severity. Eur J Radiol. 2020;126:108941. doi:10.1016/j.ejrad.2020.108941.
11. Shi H, Han X, Jiang N, Cao Y, Alwalid O, Gu J et al. Radiological findings from 81 patients with COVID-19 pneumonia in Wuhan, China: a descriptive study. Lancet Infect Dis. 2020. doi:10.1016/S1473-3099(20)30086-4.
12. Notice on Printing and Distributing the New Coronary Virus Pneumonia Diagnosis and Treatment Plan (Trial Version 7). nhc.gov.cn Web site. http://www.nhc.gov.cn/yzygj/new_index.shtml. Accessed March 19 2020.
13. Xie X, Zhong Z, Zhao W, Zheng C, Wang F, Liu J. Chest CT for Typical 2019-nCoV Pneumonia: Relationship to Negative RT-PCR Testing. Radiology. 2020:200343. doi:10.1148/radiol.2020200343.

Tables

Table 1 Basic clinical data of different age groups [n (%)]

	Total (n=97)	Junior group (n=6)	Youth group (n=44)	Middle age group (n=23)	Senior group (n=24)	P Value
	45.0(18.0)	5.0(5.2)	33.7(6.5)	54.7(4.0)	66.2(5.0)	
						0.095
	45(46.4)	5(83.3)	23(52.3)	7(30.4)	10(41.7)	
	52(53.6)	1(16.7)	21(47.7)	16(69.6)	14(58.3)	
	21(21.6)	0(0)	1(2.3)	5 (21.7)	15(62.5)	**p0.001**
	14(14.4)	0(0)	0(0)	4(17.4)	10(41.7)	**p0.001**
itus	5(5.2)	0(0)	0(0)	1(4.3)	4(16.7)	**p=0.024**
	4(4.1)	0(0)	0(0)	0(0)	4(16.7)	**p=0.014**
sis	2(2.1)	0(0)	0(0)	0(0)	2(8.3)	0.234
	3(3.1)	0(0)	1(2.3)	1(4.3)	1(4.2)	1.000
	83(85.6)	6(100)	33(75)	20(87.0)	24(100)	**p=0.022**
positive	67(69.1)	2(33.3)	28(63.6)	18(78.3)	19(79.2)	0.107
T-PCR positive	30(30.9)	4(66.7)	16(36.4)	5(21.7)	5(20.8)	0.107
ive	72(74.2)	4(66.7)	28(63.6)	19(82.6)	21(87.5)	0.150
T positive	7(7.2)	0(0)	4(9.1)	1(4.3)	2(8.3)	0.928
gative	18(18.6)	2(33.3)	12(27.3)	3(13.0)	1(4.2)	0.058
l Signs						
	12(12.4)	1(16.7)	6(13.6)	3(13.0)	2(8.3)	0.901
	55(56.7)	2(33.3)	26(59.1)	14(60.9)	13(54.2)	0.684
pectoration	43(44.3)	4(66.7)	19(43.2)	9(39.1)	11(45.8)	0.710
scomfort	13(13.4)	0(0)	9(20.5)	2(8.7)	2(8.3)	0.425
	6(6.2)	0(0)	3(6.8)	1(4.3)	2(8.3)	1.000
	8(8.2)	0(0)	4(9.1)	1(4.3)	3(12.5)	0.749
headache	7(7.2)	1(16.7)	3(6.8)	0(0)	3(12.5)	0.225
ss	4(4.1)	0(0)	2(4.5)	2(8.7)	0(0)	0.437
n/Diarrhea	6(6.2)	0(0)	3(6.8)	1(4.3)	2(8.3)	0.437
(°C)	37.7(0.9)	37.8(1.0)	37.8(0.8)	37.6(0.8)	37.9(1.0)	0.668
fication at admission						0.257
	10(10.3)	0(0)	7(15.9)	1(4.3)	2(8.3)	
	82(84.5)	6(100)	36(81.7)	22(95.7)	18(75)	
	4(4.1)	0(0)	1(2.3)	0(0)	3(12.5)	
	1(1.0)	0(0)	0(0)	0(0)	1(4.2)	
al classification						**P0.001**
	10(10.3)	0(0)	7(15.9)	1(4.3)	2(8.3)	
	65(67.0)	6(100)	32(72.7)	19(82.6)	8(33.3)	
	5(5.2)	0(0)	0(0)	0(0)	5(5.2)	
	17(17.5)	0(0)	5(11.4)	3(13.0)	9(37.5)	

Data are n (%), mean (SD), median (IQR).

Table 2. Initial CT Features of different age groups

ıeter	Total (n=97)	Junior group (n=6)	Youth group (n=44)	Middle age group (n=23)	Senior group (n=24)	P Value
ɜatures						
y/Punctate GGO	64(66.0)	4(66.7)	25(56.8)	17(73.9)	19(79.2)	0.180
/Multiple GGO	56(57.7)	0(0)	23(52.3)	15(65.2)	18(75.0)	**0.005**
ılidation	14(14.4)	0(0)	6(13.6)	2(8.7)	6(25.0)	0.377
ılation /Interlobular septal thickening	13(13.4)	0(0)	3(6.8)	4(17.4)	6(25.0)	0.135
ılar solid ɜs	6(6.2)	0(0)	3(6.8)	2(8.7)	1(4.2)	0.915
ıs stripes	8(8.2)	0(0)	3(6.8)	3(13.0)	2(8.3)	0.794
lated lesions	25(25.8)	2(33.3)	16(36.4)	4(17.4)	3(12.5)	0.107
ɜers of Lobes Affected						**0.001**
	27(27.8)	2(33.3)	16(36.4)	5(21.7)	3(12.5)	
	14(14.4)	4(66.7)	7(15.9)	2(8.7)	3(12.5)	
	17(17.5)	0(0)	11(25.0)	3(13.0)	3(12.5)	
	5(5.2)	0(0)	2(4.5)	2(8.7)	1(4.2)	
	16(16.5)	0(0)	3(6.8)	4(17.4)	9(37.5)	
	18(18.6)	0(0)	5(11.4)	7(30.4)	5(20.8)	
.ency of lobe ɜement						
upper lobe	33(34.0)	1(16.7)	9(20.5)	10(43.5)	13(54.2)	**0.020**
middle lobe	34(35.1)	0(0)	9(20.5)	11(47.8)	14(58.3)	**0.002**
lower lobe	45(46.4)	0(0)	18(40.9)	15(65.2)	12(50.0)	**0.024**
ɜpper lobe	41(42.3)	0(0)	14(31.8)	12(52.2)	15(62.5)	**0.009**
ɔwer lobe	59(60.8)	3(50.0)	21(47.7)	17(73.9)	18(75.0)	0.062
ral lung disease	52(53.6)	0(0)	20(45.5)	15(65.2)	17(70.8)	**0.005**
bution						
eural distribution	60(61.9)	3(50.0)	24(54.5)	16(69.6)	17(70.8)	0.433

Data are n (%), mean (SD), median (IQR).

Figures

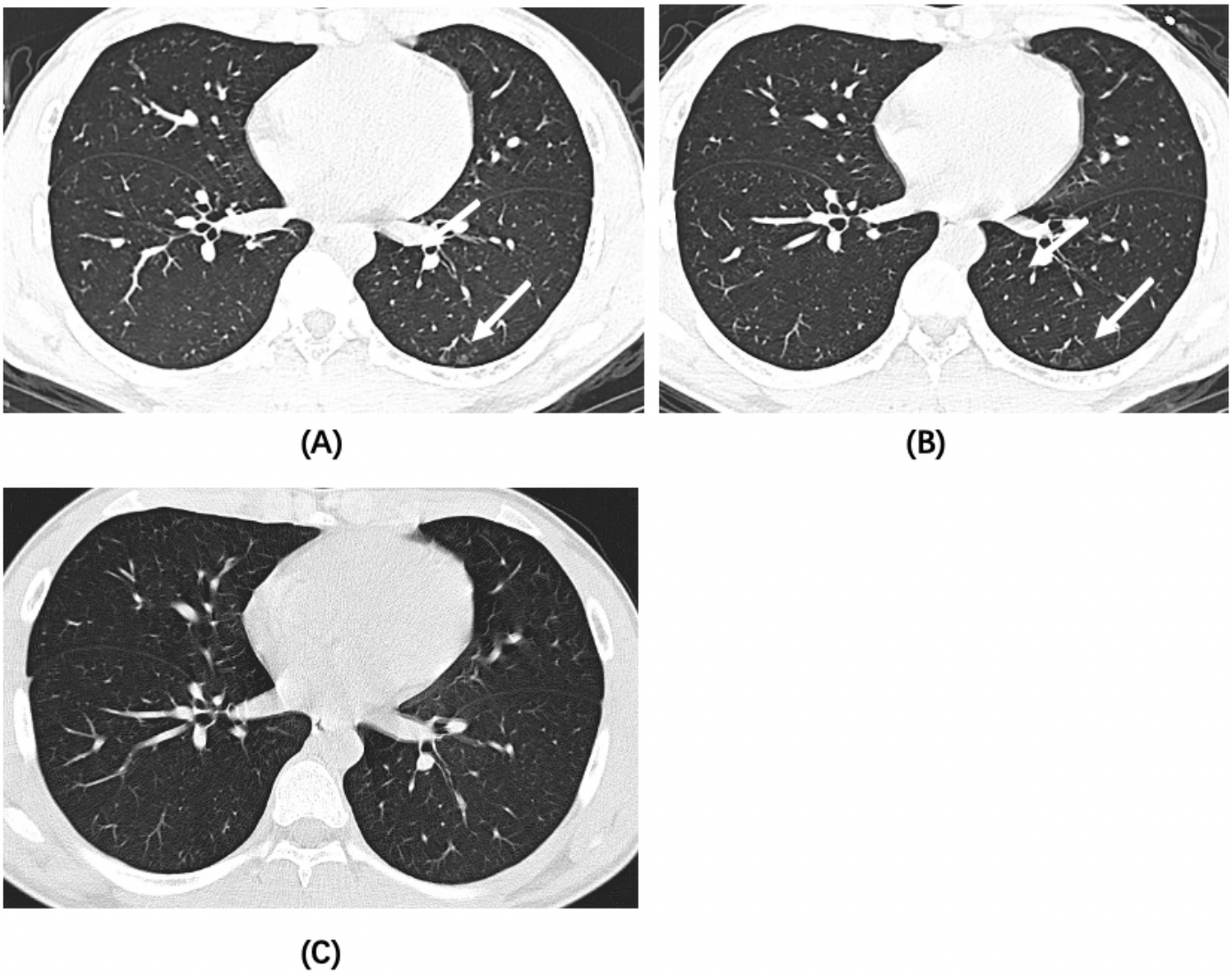

Figure 1

Axial non-enhanced chest CT in a boy age 15, with his mother confirmed. A. Chest CT at admission shows patchy GGO lesions in the left lower lobe subpleural(white arrow). B. Five days subsequently, the GGO starts to fade. C.31 days subsequently, appearances have normalised.

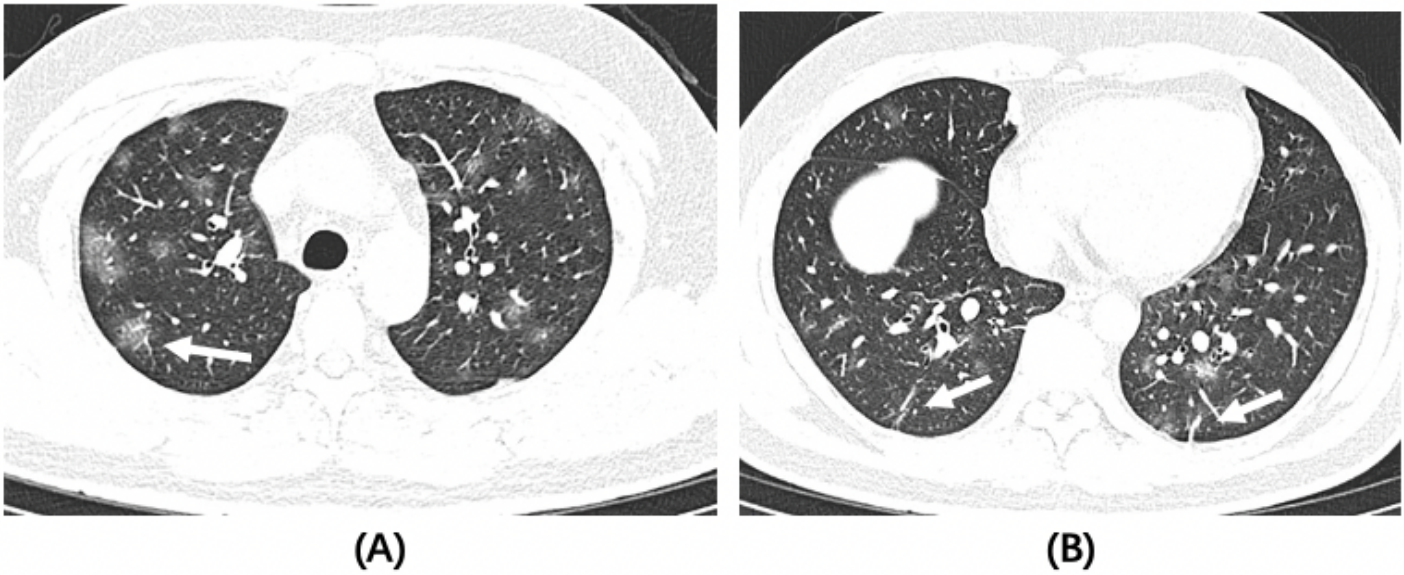

Figure 2

Axial non-enhanced chest CT in a 36-year-old male patient with fatigue, myalgia and fever. A.Chest CT at admission shows multiple GGO lesions in the bilateral lung.B. Fibrous stripes can be seen in the lower lobe of both lungs.

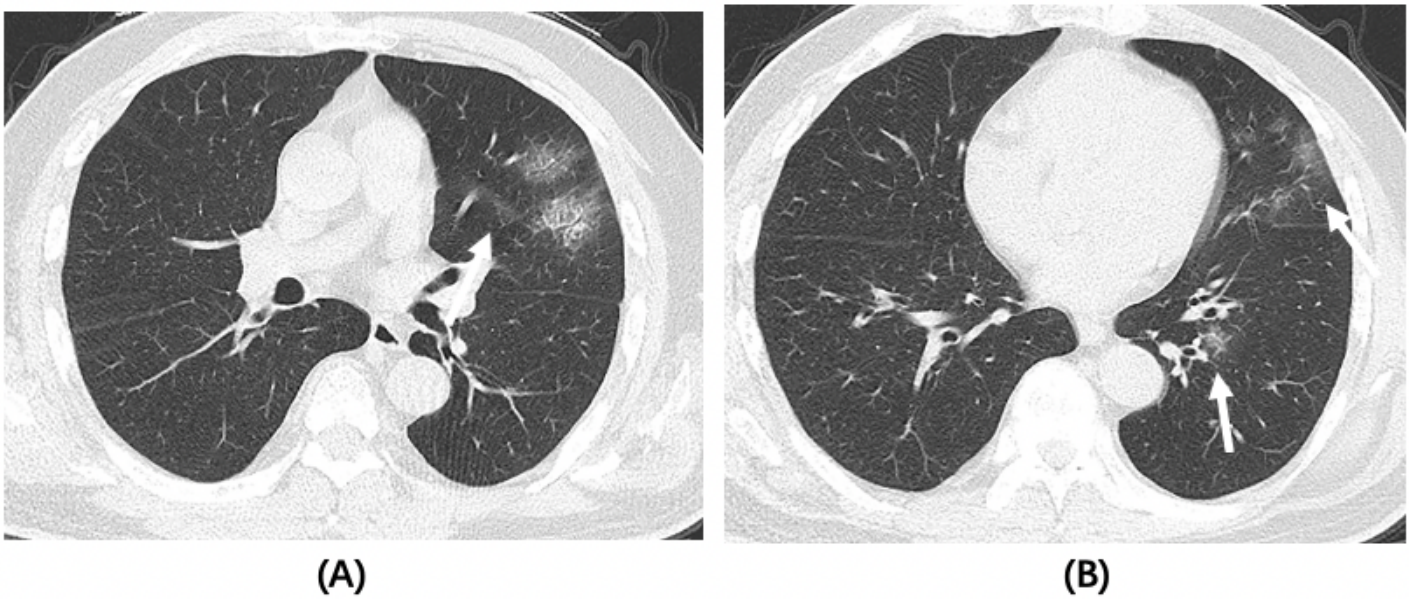

Figure 3

Axial non-enhanced chest CT in a 56-year-old male patient asymptomatic. A.Chest CT at admission shows Patchy GGO lesions in the left upper lobe.B. Some of the lesions are located under the pleura, some are distributed along the bronchi.

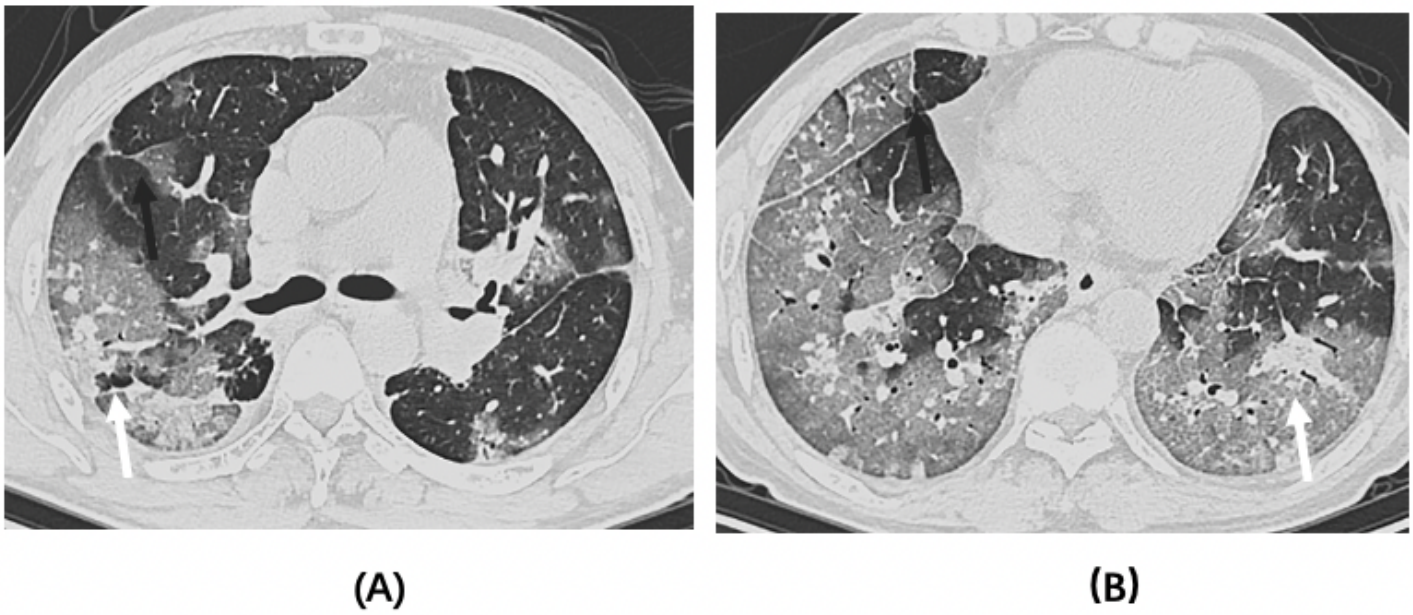

Figure 4

Axial non-enhanced chest CT in a 60-year-old male patient with maximum body temperature of 38℃. A.B. Chest CT at admission shows diffuse large/multiple GGO lesions in the bilateral lung lobes, which contains multiple consolidations (white arrow) and interlobular septal thickening(black arrow), Changing like “paving stones”.