The characteristics of overseas imported COVID-19 cases and the effectiveness of screening strategy in Beijing, China

Li Li
Capital Medical University Affiliated Beijing Ditan Hospital https://orcid.org/0000-0002-6666-3830
Cheng-Jie Ma
Capital Medical University Affiliated Beijing Ditan Hospital
Yu-Fei Chang
Capital Medical University Affiliated Beijing Ditan Hospital
Si-Yuan Yang
Capital Medical University Affiliated Beijing Ditan Hospital
Yun-Xia Tang
Capital Medical University Affiliated Beijing Ditan Hospital
Rong-Meng Jiang (13911900791@163.com)
Capital Medical University Affiliated Beijing Ditan Hospital

Case Study

Keywords: Characteristics, Screening, COVID-19, Imported cases

Posted Date: May 27th, 2020

DOI: https://doi.org/10.21203/rs.3.rs-30515/v1

Version of Record: A version of this preprint was published at BMC Infectious Diseases on January 17th, 2022. See the published version at https://doi.org/10.1186/s12879-021-06998-5.

Abstract

Background

While great success in the coronavirus disease 2019 (COVID-19) control has been achieved in China, imported cases have become a major challenge. This study aimed to describe the epidemiological and clinical characteristics of imported COVID-19 cases and to assess the effectiveness of screening strategy in Beijing, China.

Methods

This retrospective study included all imported COVID-19 cases from Beijing Ditan Hospital from 29 February to 20 March 2020, who were screened by both chest computed tomography (CT) and reverse-transcriptase-polymerase chain reaction (RT-PCR) at initial presentation. Demographic, clinical and laboratory data, in addition to chest CT imaging were were collected and analyzed.

Results

A total of 71 imported cases were finally diagnosed with laboratory-confirmed COVID-19. The cases were mainly acquired from Europe (63 cases, 88.73%). The main clinical manifestations were fever and cough, which accounted for 30 cases (42.25%) and 35 cases (49.30%), respectively. Only 4 cases (5.63%) had lymphocytopenia and 13 (18.31%) cases demonstrated elevated levels of C-reactive protein (CRP). All cases had normal serum levels of procalcitonin (PCT). 35 cases (49.30%) had abnormal CT findings at initial presentation, whereas 36 cases (50.70%) had a normal CT. Using RT-PCR, 59 cases (83.10%) were tested positive at initial presentation.

Conclusions

The number of overseas imported COVID-19 cases continues to rise in China. The combination of screening tools, particularly CT and RT-PCR, can detect imported COVID-19 cases efficiently.

Background

In December 2019, a cluster of patients with pneumonia of unknown cause was occurred in Wuhan, Hubei Province, China[1–5].The novel coronavirus, identified as the causative agent, is now formally named as severe acute respiratory syndrome coronavirus 2 (SARS-CoV-2) and the disease caused by this novel coronavirus is called coronavirus disease 2019 (COVID-19)[6, 7]. Due to the lack of immunity to SARS-CoV-2 virus in humans, as well as the efficient transmission between humans, this virus spread rapidly across the world. Concerning COVID-19, the World Health Organization (WHO) raised the threat to the CoV epidemic to the "very high" level on February 28, 2020[8].

Data provided by the WHO Health Emergency Dashboard (24 March 2020, 10:00AM CET) report 332930 confirmed cases of COVID-19 worldwide since the beginning of the epidemic [9]. Outside of China, the main endemic areas are Europe, Americas and Eastern Mediterranean Region. Due to global economic integration, large numbers of Chinese people travel to these endemic countries for trade, tourism, labour, study and other purposes. Subsequently, with the outbreak of COVID-19 abroad and the control of the epidemic in China, importation of COVID-19 from highly endemic areas into China is inevitable.

In recent days, there has been a rise in imported COVID-19 cases in Beijing. In order to address this new challenge, the rapid and accurate detection of imported cases is of great significance. In this study, we implemented border entry screening (BES) for overseas travellers and in-hospital screening for suspected cases. This provided us with a good opportunity to describe the characteristics of imported COVID-19 cases and to to assess the effectiveness of screening strategy in Beijing, China.

Methods

Study design and subjects

A retrospective analysis of 71 confirmed overseas COVID-19 cases (a history of travel from affected geographic areas within 14 days of symptom onset), who were transferred to Beijing Ditan Hospital from 29 February to 20 March 2020 was carried out. All COVID-19 cases were diagnosed according to the Seventh Revised Trial Version of the Novel Coronavirus Pneumonia Diagnosis and Treatment Guidance [10]. A laboratory COVID-19 case was defined as positive for SARS-CoV-2 nucleic acid of nasopharyngeal swab or/and sputum specimens by reverse transcription polymerase chain reaction (RT-PCR).

Screening process and data collection

Imported COVID-19 cases admitted to our hospital were detected using 2 detection routes in fever clinic (Figure 1):

1. Border entry screening: When an overseas flight arrived at Beijing international airport, travellers were required to complete body temperature monitoring and self-health declare during the customs check. Any traveller who was deemed to have symptoms of COVID-19 (including close contacts) was transferred to our hospital.
2. In-hospital screening: First, the travellers screened on arrival at airport would have been placed under respiratory isolation conditions. Then, in addition to medical history and laboratory tests, SARS-CoV-2 test and chest computed tomography (CT) were performed for further confirmation.

Data including demographic data (ie, gender, age, cluster, country from where the infection was acquired), clinical, laboratory findings and chest CT features at initial presentation were collected on each of the laboratory-confirmed cases. Laboratory results included complete blood count, C-reactive protein (CRP) and procalcitonin (PCT).

Statistical Analysis

We described the categorical variables as frequency rates and percentages (%), and continuous variables as mean and standard deviation (SD) or median and interquartile range (IQR) values, as appropriate. All statistical analyses were performed using SPSS (Statistical Package for the Social Sciences) version 22.0 software (SPSS Inc.).

Results

Demographic characteristics of overseas imported COVID-19 cases

From 29 February to 20 March 2020, 71 imported COVID-19 cases (2.79%) were identified from 2545 overseas travellers screened at emergency department of infectious diseases, Beijing Ditan Hospital, Capital Medical University. The demographic characteristics of the cases are described in Table 1. There were 27(38.03%) males and 44(61.97%) females. The median age of the cases was 24 years (IQR, 20-39; range, 6-55 years). A total of 11 clusters occurred, involving 39.44% of all COVID-19 cases. The cases were mainly acquired from Europe (63 cases, 88.73%). Of these, 22 (30.99%) cases were from Spain, followed by 17 (23.94%) cases from the United Kingdom and 16(22.54%) cases from Italy, respectively. The period from 29 February to 10 March 2020 was characterized by low numbers of imported cases. From 11 March onward, there was a gradual increase in the number of imported cases, of which the majority were 14 per day (Figure 2).

Clinical characteristics of overseas imported COVID-19 cases

The most common clinical manifestations at onset of illness were fever and cough, which accounted for 30 cases (42.25%) and 35 cases (49.30%), respectively. 15 (21.13%) cases had sore throat. In addition, 14 (19.72%) cases had fatigue, 9 (12.68%) cases had headache, 7 (9.86%) cases had myalgia or arthragia, 5(7.04%) cases had shortness of breath, 2(2.82%) cases had nausea or vomiting and 1(1.41%) cases had diarrhea. The median time from illness onset to hospital admission was 4.0 days (IQR, 2-7; range, 11 hours to 13 days).

According to laboratory findings at initial presentation, the white blood cell (WBC) count of 7 (9.90%) cases was lower than the normal range (4×10^9/L), and 4 cases (5.63%) had lymphocytopenia (the lymphocyte count was less than 1.0×10^9/L). 8(11.27%) cases had platelets higher than the normal range (300×10^9/L), and no case had lower platelets than the normal range (100×10^9/L). There were 13 (18.31%) cases with high CRP. There was a normal PCT value.

According to chest imaging findings at initial presentation, of 71 imported cases, 35 (49.30%) cases showed abnormal chest CT images, consisting 19 cases (26.76%) of bilateral pneumonia and 16 cases (22.54%) of unilateral pneumonia (Table 2),with typical findings of patchy ground-glass opacity(GGO) in lungs(Figure 3 A, B). There were 6(8.45%) cases of unilateral patchy consolidation and 5(7.04%) cases of

bilateral consolidation in lungs (Figure 3 C, D). 36(50.70%) cases had no abnormality in the parenchyma of both lungs.

During the diagnostic procedure, we found that 59 cases (83.10%) got a positive result in the first RT-PCR test at initial presentation. However, the remaining 12 cases(16.9%) were further confirmed after admitting to the isolation ward. 5 cases (7.04%) got a positive result in the second RT-PCR test. 7 cases (9.86%) didn't obtained positive results until 3-5 round of tests later (Figure 4).

The effectiveness of screening strategy

From 29 February to 20 March 2020, with the combination of screening tools, particularly CT and RT-PCR, 2.79% (71/2545) of entry screening cases were detected and isolated in time. However, those who were excluded from COVID-19 were tested for SARS-CoV-2 again after 14 days of isolation and all results were negative with telephone follow-up. At the same time, the local Centers for Disease Control and Prevention (CDC) had not reported any new confirmed cases in this population.

Discussion

In China, when there are no more new local cases reported, imported cases have become a major challenge. In this study, 71 overseas imported COVID-19 cases in Beijing were reported. Our results demonstrated the effectiveness of combined screening tools to detect overseas imported COVID-19 cases.

Focusing on the period from 29 February to 20 March 2020, there was a consistent increase in the number of imported COVID-19 cases from overseas in Beijing, China. Cases from various regions demonstrated import situation at different points in time, with strong correlations to the epidemic situation in case exporting countries. Therefore, more attention should be paid on returnees from the high-burden areas according to the dynamic development of outbreak of COVID-19 in different countries. The first imported case seen in Beijing was from Iran on 29 February 2020, corresponding to the severity of the COVID 19 outbreak occurred in Iran at the same time. However, over the course of the next few days, the case exporting regions diversified, and cases from around the world were identified. This demonstrated the global spread of the disease along with the development of the pandemic. This also suggests that dynamic epidemiological history is of paramount importance for alert and early detection of COVID-19 patients.

All imported cases were screened first at the customs via temperature monitoring and self-health declaration and then transferred to emergency department of infectious diseases in Beijing Ditan Hospital. In this study, the most common symptoms were fever and cough, similar to the cohorts reported in current available literatures[11–13]. Only 2 cases were asymptomatic, but SARS-CoV-2 nucleic acid were positive. Fever is less frequent in those infected with SARS-CoV-2 than those with SARS-CoV (99%) and MERS-CoV (98%)[14]. Furthermore, asymptomatic carriers are potential sources of SARS-CoV-2

transmission and cannot be ignored [15, 16]. As screening heavily on syndromic detection, a substantial proportion of asymptomatic cases may be missed.

Previous studies have shown that chest CT scan is of great significance to screen the suspected cases of COVID-19[17]. In the early stage, there were ground-glass opacification with or without consolidative abnormalities, especially showed with a peripheral distribution. In severe cases, lung consolidation may occur, but pleural effusion was rare [18]. In our study, nearly half of imported cases showed abnormal chest CT images, with GGO and consolidation. This was consistent with the study by Huang et al [19].Therefore, in clinical practice, when SARS-CoV-2 nucleic acid is negative or the result cannot be returned in time, chest CT images can be used as an important alert and help to quarantine the patient at the very first time. Notably, normal chest CT imaging was found in 36(50.70%) cases compared to 17% of a recently study by Pan et al [20]. Therefore, a normal result from the initial CT scan does not rule out COVID-19 completely. The imaging features of COVID-19 were diverse and depended on the stage of infection after the onset of symptoms. A retrospective analysis of chest CT in 121 patients with COVID-19 by Bernheim et al[21] showed more frequent normal CT findings (56%) in the early stages of the disease (0–2 days). In this regard, we suggest that follow-up CT scan should be performed with an interval of 3 days to show the pulmonary dynamic changes.

In this study, all cases received SARS-CoV-2 test at initial presentation. The sum of nucleic acid test prior to a positive diagnosis for each patient was analyzed. However, 7 cases didn’t obtained positive results until 3–5 rounds of testing later. These negatives could result from improper sampling techniques or low viral load in the area sampled [22, 23]. Therefore, for patients with high clinical suspicion, specimens should be continuously collected for multiple tests to avoid missed diagnosis.

There are several limitations to our study. First, due to the limited number of patients, our conclusions need to be further verified by large samples and multi-center data. Secondly, due to time constraints, those who were excluded from COVID-19 at initial presentation had not been followed up for longer periods of time. Therefore, continued attention needs to be paid to the report of local CDC on COVID-19 outbreaks for further verification.

Conclusions

Currently, SARS-CoV-2 continues to spread globlly. The epidemiologic study of imported cases showed that incoming travellers should not be overlooked as a source of imported infectious diseases. In order to accurately detect imported COVID-19 cases, the following aspects should be strengthened: (1) Strengthen surveillance of overseas COVID-19 outbreaks. Airport customs personnel and doctors in hosptial should update the epidemic situation abroad synchronously. (2) Strengthen the understanding of the clinical characteristics of the imported cases and use combined screening tools.

Abbreviations

COVID-19: Coronavirus disease 2019; SARS-CoV-2: Severe acute respiratory syndrome coronavirus 2; CT: Computed tomography; RT-PCR: Reverse-transcriptase-polymerase chain reaction; CRP: C-reactive protein; PCT: Procalcitonin; WHO: World Health Organization; BES, Border entry screening; SD: standard deviation; IQR: Interquartile range; WBC: White blood cell; GGO: Ground-glass opacity; CDC: Centers for Disease Control and Prevention

Declarations

Acknowledgement

We thank all cases included in this study. We are really grateful to all the health workers around the world. Their expertise is fundamental to stop SARS-CoV-2 from spreading further.

Authors' contributions

CJ M and RM J designed the study; LL, YF C, SY Y and YT T collected data; LL, CJ M and YF C performed data analyses; LL and CJ M drafted and revised the manuscript. All of the authors have read and approved the final manuscript.

Funding

This work was supported by National Science and Technology Major Project during the '13th Five-year' Plan Period (No.2017ZX10205502).

Availability of data and materials

Data of the study can be available upon request from Rong-Meng Jiang.

Ethics approval and consent to participate

The present study was approved by the Clinical Ethics Committees of Beijing Ditan Hospital, Capital Medical University (Record number 2020014-01). Signed informed consent was exempted due to the retrospective nature of the study. We confirmed that the identification information of all participants (including patient names, ID numbers, home addresses and telephone numbers) would not be included in recordings, written descriptions or publications.

Consent for publication

Not applicable

Competing interests

The authors declare that they have no competing interests.

Author details

[1]Clinical and Research Center of Infectious Diseases, Beijing Ditan Hospital, Capital Medical University, Beijing 100015, China

[2]Clinical Center for HIV/AIDS, Capital Medical University, Beijing 100015, China

References

1. Hui DS, I AE, Madani TA, Ntoumi F, Kock R, Dar O, et al. The continuing 2019-nCoV epidemic threat of novel coronaviruses to global health - The latest 2019 novel coronavirus outbreak in Wuhan, China. Int J Infect Dis. 2020;91:264-6. doi:10.1016/j.ijid.2020.01.009.
2. Lu H, Stratton CW, Tang YW. Outbreak of Pneumonia of Unknown Etiology in Wuhan China: the Mystery and the Miracle. J Med Virol. 2020;92(4):401-2.doi:10.1002/jmv.25678.
3. Paules CI, Marston HD, Fauci AS. Coronavirus Infections-More Than Just the Common Cold. JAMA. 2020. doi:10.1001/jama.2020.0757.
4. Wang C, Horby PW, Hayden FG, Gao GF. A novel coronavirus outbreak of global health concern. Lancet. 2020;395(10223):470-3. doi:10.1016/S0140-6736(20)30185-9.
5. Zhu N, Zhang D, Wang W, Li X, Yang B, Song J, et al. A Novel Coronavirus from Patients with Pneumonia in China, 2019. N Engl J Med. 2020;382(8):727-33. doi:10.1056/NEJMoa2001017.
6. Chen H, Guo J, Wang C, Luo F, Yu X, Zhang W, et al. Clinical characteristics and intrauterine vertical transmission potential of COVID-19 infection in nine pregnant women: a retrospective review of medical records. Lancet. 2020;395:809-15. doi:10.1016/S0140-6736(20)30360-3.
7. Lai CC, Shih TP, Ko WC, Tang HJ, Hsueh PR. Severe acute respiratory syndrome coronavirus 2 (SARS-CoV-2) and coronavirus disease-2019 (COVID-19): The epidemic and the challenges. Int J Antimicrob Agents. 2020;55:105924. doi:10.1016/j.ijantimicag.2020.105924.
8. World Health Organization. WHO Director-General's opening remarks at the media briefing on COVID-19 - 28 February 2020. Available at: https://www.who.int/dg/speeches/detail/who-director-general-s-opening-remarks-at-the-media-briefing-on-covid-19—28-february-2020.
9. World Health Organization. Coronavirus disease 2019 (COVID-19) Situation Report–63. Available at: https://www.who.int/docs/default-source/coronaviruse/situation-reports/20200323-sitrep-63-covid-19.pdf?sfvrsn=d97cb6dd_2.
10. National Health Commission of the People’s Republic of China website. Diagnosis and treatment of novel coronavirus pneumonia (trial version seventh). Available at: http://www.nhc.gov.cn/yzygj/s7652m/202003/a31191442e29474b98bfed5579d5af95.shtm.
11. Huang C, Wang Y, Li X, Ren L, Zhao J, Hu Y, et al. Clinical features of patients infected with 2019 novel coronavirus in Wuhan, China. Lancet. 2020;395:497-506. doi:10.1016/S0140-6736(20)30183-5.
12. Wang D, Hu B, Hu C, Zhu F, Liu X, Zhang J, et al. Clinical Characteristics of 138 Hospitalized Patients With 2019 Novel Coronavirus-Infected Pneumonia in Wuhan, China. JAMA. 2020;323(11):1061-9.

doi:10.1001/jama.2020.1585.

13. Xu XW, Wu XX, Jiang XG, Xu KJ, Ying LJ, Ma CL, et al. Clinical findings in a group of patients infected with the 2019 novel coronavirus (SARS-Cov-2) outside of Wuhan, China: retrospective case series. BMJ. 2020;368:m606. doi:10.1136/bmj.m606.
14. Zumla A, Hui DS, Perlman S. Middle East respiratory syndrome. Lancet. 2015;386:995-1007. doi:10.1016/S0140-6736(15)60454-8.
15. Rothe C, Schunk M, Sothmann P, Bretzel G, Froeschl G, Wallrauch C, et al. Transmission of 2019-nCoV Infection from an Asymptomatic Contact in Germany. N Engl J Med. 2020;382:970-1. doi:10.1056/NEJMc2001468.
16. Tuite AR, Fisman DN. Reporting, Epidemic Growth, and Reproduction Numbers for the 2019 Novel Coronavirus (2019-nCoV) Epidemic. Ann Intern Med. 2020;172(8):567-8. doi:10.7326/M20-0358.
17. Song F, Shi N, Shan F, Zhang Z, Shen J, Lu H, et al. Emerging 2019 Novel Coronavirus (2019-nCoV) Pneumonia. Radiology. 2020;295:210-7. doi:10.1148/radiol.2020200274.
18. Wu J, Liu J, Zhao X, Liu C, Wang W, Wang D, et al. Clinical Characteristics of Imported Cases of COVID-19 in Jiangsu Province: A Multicenter Descriptive Study. Clin Infect Dis. 2020. doi:10.1093/cid/ciaa199.
19. Chung M, Bernheim A, Mei X, Zhang N, Huang M, Zeng X, et al. CT Imaging Features of 2019 Novel Coronavirus (2019-nCoV). Radiology. 2020;295:202-7. doi:10.1148/radiol.2020200230.
20. Pan F, Ye T, Sun P, Gui S, Liang B, Li L, et al. Time Course of Lung Changes On Chest CT During Recovery From 2019 Novel Coronavirus (COVID-19) Pneumonia. Radiology. 2020;295(3):715-21. doi:10.1148/radiol.2020200370.
21. Bernheim A, Mei X, Huang M, Yang Y, Fayad ZA, Zhang N, et al. Chest CT Findings in Coronavirus Disease-19 (COVID-19): Relationship to Duration of Infection. Radiology. 2020;295(3):200463. doi:10.1148/radiol.2020200463.
22. Ai T, Yang Z, Hou H, Zhan C, Chen C, Lv W, et al. Correlation of Chest CT and RT-PCR Testing in Coronavirus Disease 2019 (COVID-19) in China: A Report of 1014 Cases. Radiology. 2020:200642. doi:10.1148/radiol.2020200642.
23. Winichakoon P, Chaiwarith R, Liwsrisakun C, Salee P, Goonna A, Limsukon A, et al. Negative Nasopharyngeal and Oropharyngeal Swab Does Not Rule Out COVID-19. J Clin Microbiol. 2020;58(5):e00297-20. doi:10.1128/JCM.00297-20.

Tables

Table 1. Demographic characteristics of the imported COVID-19 cases(N=71)

Variables	Cases
Gender	
Male	27(38.03%)
Female	44(61.97%)
Age (years)	
Median (IQR)	24(20-39)
≤19	12(16.90%)
20-29	33(46.48%)
30-39	10(14.08%)
40-49	12(16.90%)
≥50	4(5.63%)
Clusters	11(39.44%)
Infectious origin	
Spain	22(30.99%)
The United Kingdom	17(23.94%)
Italy	16(22.54%)
United States of America(USA)	5(7.04%)
Hungary	3(4.23%)
Austria	2(2.82%)
Brazil	1(1.41%)
Iran (Islamic Republic of)	2(2.82%)
France	1(1.41%)
Netherland	1(1.41%)
Luxembourg	1(1.41%)

Values are number (percentage) and median (IQR).IQR, interquartile range.

Table 2. Clinical characteristics of imported COVID-19 cases(N=71)

Variables	Cases
Duration from onset to admission (d), median (IQR)	4(2-7)*
Clinical on admission	
Fever	30（42.25%）
Cough	35（49.30%）
Sore throat	15（21.13%）
Fatigue	14（19.72%）
Headache	9（12.68%）
Myalgia or arthralgia	7（9.86%）
Nausea or vomiting	2（2.82%）
Shortness of breath	5（7.04%）
Diarrhea	1（1.41%）
No sign or symptom	2（2.82%）
Chest CT findings	
Bilateral pneumonia	19（26.76%）
Unilateral pneumonia	16（22.54%）
No abnormalities	36（50.70%）

Values are number (percentages) and median (IQR).CT, computed tomography. IQR, interquartile range.*Data of duration from onset to admission were available in 69 cases.

Table 3. Laboratory findings of imported COVID-19 cases(N=71)

Variables	Normal range	Cases		
		Median (IQR) or Mean (SD)	Increased No.	Decreased No.
Blood routine				
White blood cell count ($\times 10^9$/L)	4-10	5.67(4.76-7.08)	2(2.82%)	7(9.90%)
Lymphocyte count($\times 10^9$/L)	1-5	1.69±0.52	0(0.00%)	4(5.63%)
Platelet count count ($\times 10^9$/L)	100-300	236.00±56.37	8(11.27%)	0(0.00%)
Haemoglobin (g/L)	110-150（female） 120-160（male）	148.00±15.76	16(22.54%)	4(5.63%)
Infection-relation markers				
C-reactiveProtein(mg/L)	（0-5）	1.10(0.40-3.40)	13(18.31%)	0（0.00%）
Procalcitonin(ng/mL）	<0.05	-	0（0.00%）	0（0.00%）

Values are number (percentages) and median (IQR) or mean (SD). IQR, interquartile range; SD, standard deviation.

Figures

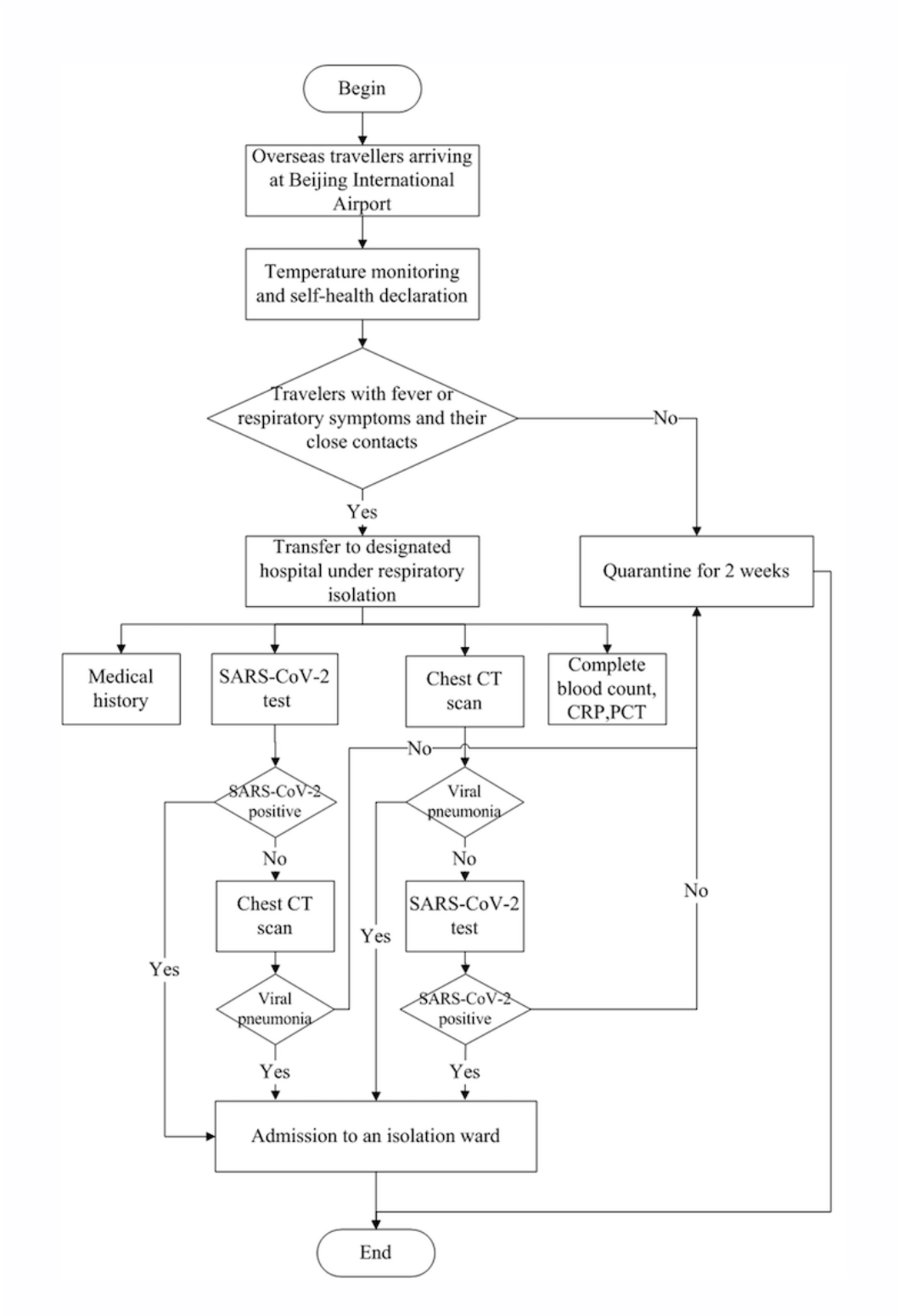

Figure 1

Flow chart of screening process for overseas imported COVID-19 cases in fever clinic. CT, computed tomography; CRP,C-reactive protein; PCT, procalcitonin; SARS-CoV-2, severe acute respiratory syndrome coronavirus 2.

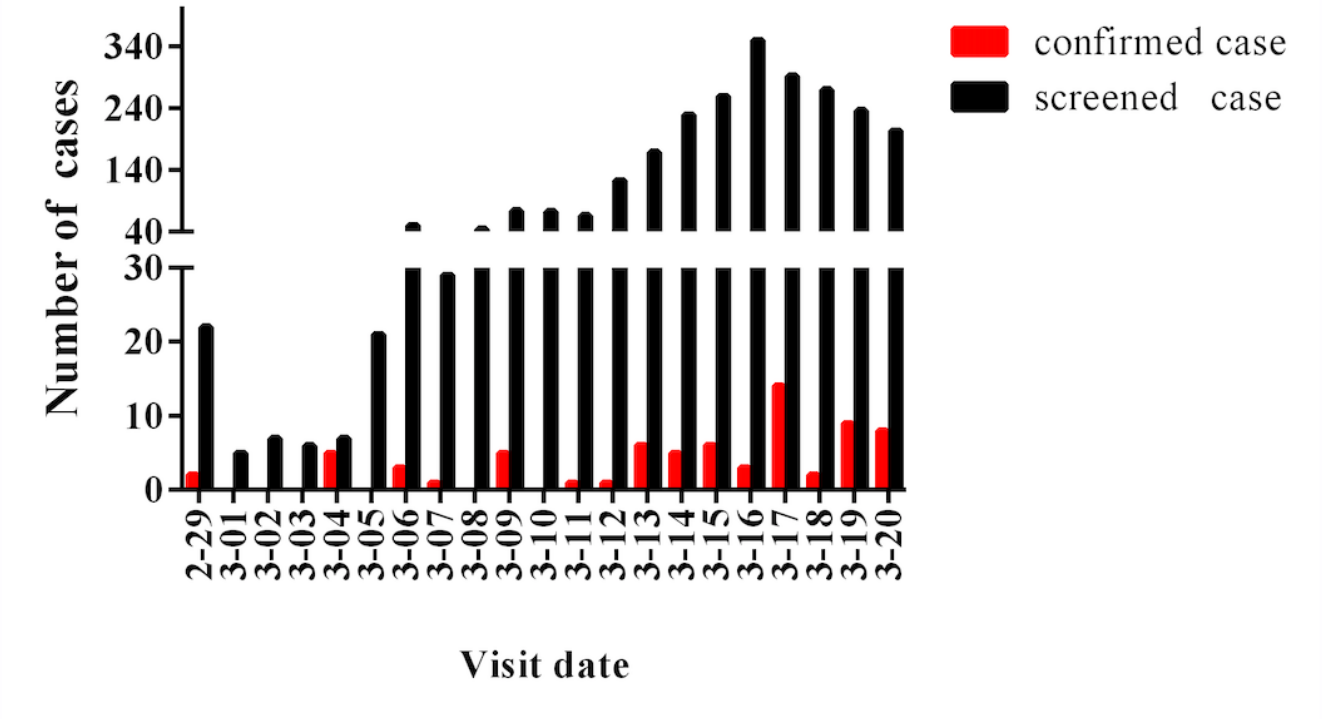

Figure 2

The daily screened and confirmed overseas imported cases in Beijing, China, from 29 February to 20 March 2020.

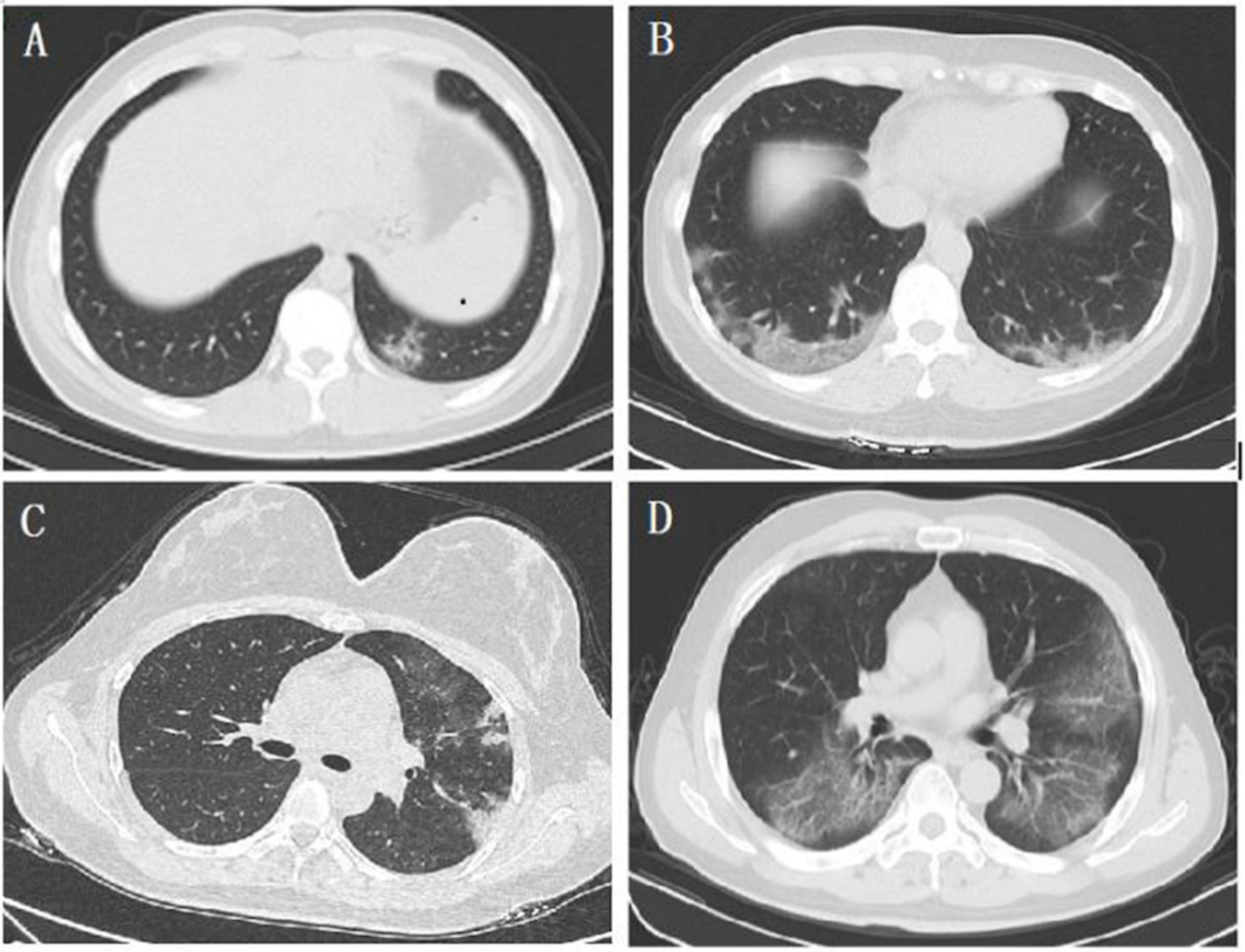

Figure 3

Chest CT images of COVID-19 cases (A)chest CT image from a 20-year-old man from The United Kingdom on illness days 5 showing that patchy ground-glass opacity (GGO)in subpleural area of left lower lobe. (B)chest CT image from a 37-year-old woman from America on illness days 10 showing that multiple patchy and spherical GGO in the lower lobe of bilateral lungs with interlobular septal thickening. (C)chest CT image from a 22-year-old woman from The United Kingdom on illness days 3 showing that multiple patchy consolidation and GGO in the left lung. (D)chest CT image from a 55-year-old man from Spain on illness days 10 showing that multiple patchy GGO and early consolidation in bilateral lungs .

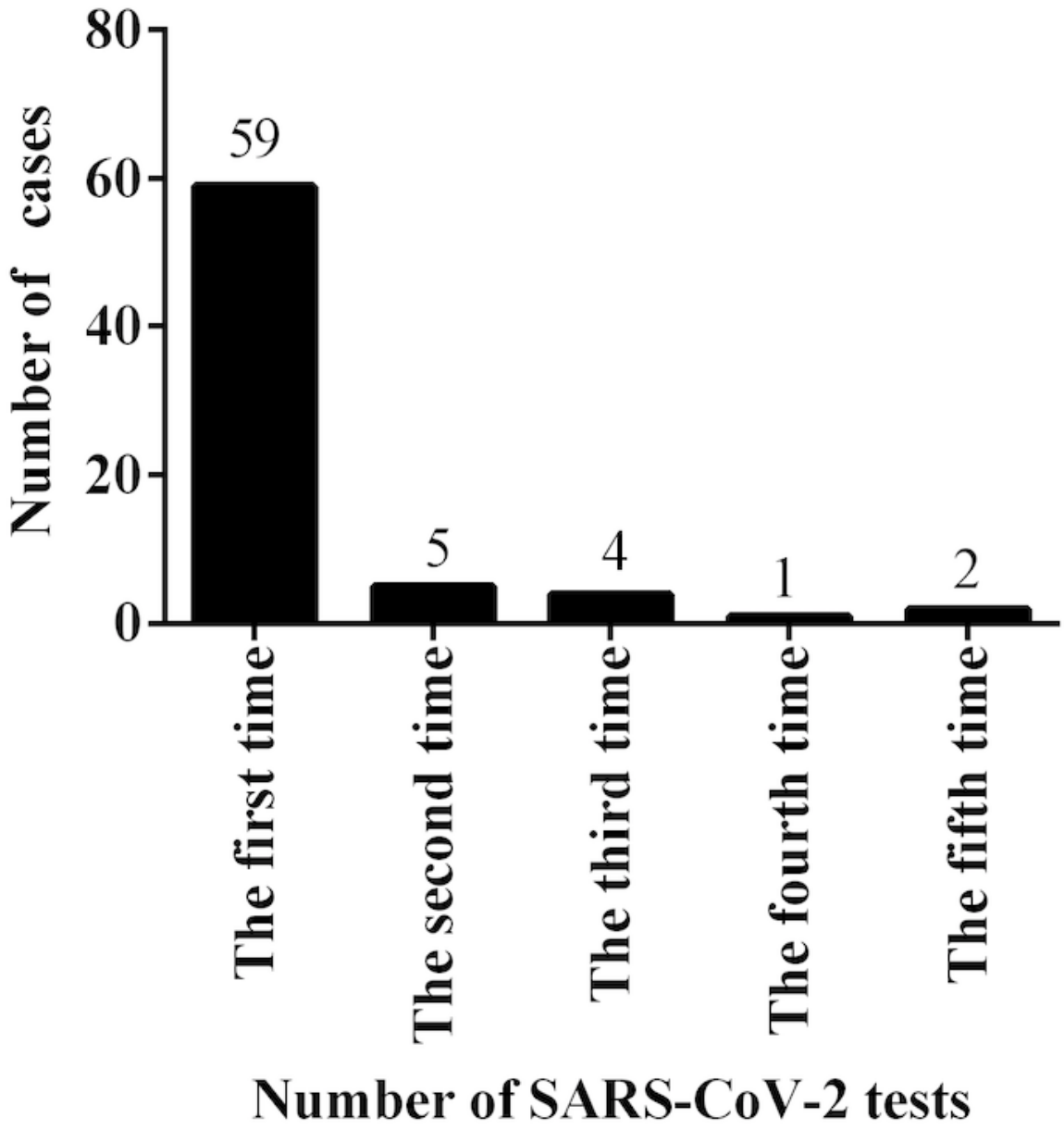

Figure 4

Number of SARS-CoV-2 tests to confirm COVID-19 in imported cases.