

Dichotomous Profile of Thoraco-lumbar Dislocation Fractures. Case Report and Review of the Literature

Israël Azabali Maoneo (✉ maoneo@yahoo.fr)

University of Kinshasa: Université de Kinshasa <https://orcid.org/0000-0003-1208-9033>

Antoine Kalubye Beltchika

University of Kinshasa Faculty of Sciences: Université de Kinshasa Faculté des Sciences

Dieu-Merci Kantenga Kabulo

University of Lubumbashi: Université de Lubumbashi

Pierre ili-apanda Mukuetala

University of Kinshasa: Université de Kinshasa

Glennie Eba Ntsambi

University of Kinshasa: Université de Kinshasa

Research Article

Keywords: Thoracolumbar fracture dislocation, Denis' three columns, Magerl classification

Posted Date: August 18th, 2023

DOI: <https://doi.org/10.21203/rs.3.rs-3054096/v2>

License:   This work is licensed under a Creative Commons Attribution 4.0 International License.

[Read Full License](#)

Abstract

Background. Dislocated thoracolumbar fractures are uncommon injuries following major trauma. However, the resulting spinal cord injuries do not always correspond to the radiological characteristics of osteo-discoligamentary injuries.

We report a case of thoraco-lumbar dislocated fracture of which radiological finding was in discrepancy with clinical aspect and postoperative evolution according to spinal cord injury.

Case presentation.

A 32-year-old congolese, female, admitted in Neurosurgery Department of the University Hospital of Kinshasa for low back pain and functional impotence of lower limbs and urinary

retention following a road traffic accident three weeks prior. The physical examination was normal. We found a painful swelling at level of T12-L2 spinous processes and Wagner's grade IV gluteal pressure sores. Neurologically, the sensation was preserved on both limbs, motor strength on lower limbs was graded 3/5 globally. She had urinary retention. We made a diagnosis of an incomplete spinal cord injury (ASIA C) secondary to a thoraco-lumbar spinal trauma. CT-Scan showed a fracture of the vertebral body and pedicles of L2 with retrolisthesis of L1/L2 grade IV (Magerl B.3.3). She underwent posterior spinal decompression followed by spinal stabilisation with pedicle screws. The gluteal ulcers were debrided and sutured during the same surgery. Postoperatively, the pressure ulcers healed and the patient recovered full motor and urinary sphincter functions after several sessions of physiotherapy months.

Conclusion. This case report demonstrates the possibility of discordance between radiological images of dislocated thoracolumbar fractures and spinal cord injury clinical.

Introduction

Thoracolumbar injuries are very common compared to other spinal segments [1]. More than 90% of spinal injuries are located at the thoracolumbar region (T11-L2) [2]. This transition zone between the rigid dorsal column and the mobile lumbar column constitutes a point of weakness exposed to various traumas. Fracture dislocations are rare lesions whose production requires a high-energy trauma leading to the rupture of three spinal columns [3]. The rupture of all three columns by a major trauma leads to instability of the spine, likely to cause a dislocation (Denis type III injury) with a very high risk of spinal cord or nerve root injury [4]. In the majority of cases, high-grade thoracolumbar dislocation fractures are manifested by complete neurological deficit [3]. Cases with incomplete or no neurological deficit are rare. We report a case of a grade IV traumatic thoracolumbar fracture dislocation with incomplete neurological deficit treated in our Department in order to discuss the discrepancy between the radiological finding and the clinical and therapeutic aspects.

Case Report

We report a 32-year-old female patient, referred from a peripheral hospital on 3rd February 2021 to the Neurosurgery Department of the University Teaching Hospital of Kinshasa for low back pain, functional impotence of the pelvic limbs and urinary retention following a road traffic accident three weeks prior. Her past medical and surgical history was unremarkable.

On examination, she was stable and coherent, pink and vital signs were within normal limits. In the dorsolumbar region, there was swelling in regard to L1-L2. Palpation revealed moderate tenderness. In the gluteal region, there was an oval wound in the upper-internal quadrant of the right buttock, about 8/6 cm in diameter, covered with a whitish crust. And on the superior-internal quadrant, an oval wound, 12/10 mm in diameter, covered with a blackish crust. In the genital area, the urinary catheter connected to the collecting bag was in place with clear urine.

Neurologically, Glasgow coma Scale was 15/15. The pupils were equal and reactive to light. She had paraparesia with global power of 3/5. Sensation was preserved on both lower limbs. She was classified as ASIA C. The anal sphincter was slightly tonic and bulbocavernosus reflexe was present.

Thoraco lumbar CT scan showed fracture with bony fragments of the L1 vertebral body along the right inferior articular process with a Meyerding grade 3 retrolisthesis of L1 on L2 corresponding to Magerl B.3.3. Displaced fractures of the left transverse process of L1, two transverse processes and pedicles of L2 and the right transverse process of L3 were also noted on these CT scans. Finally, the CT scan showed the loss of lumbar lordosis (Fig. 1A, B, C).

The results of the biological examinations performed were within the normal range. In view of the above, we made a diagnosis of incomplete spinal cord injury secondary to fracture dislocation of L1/L2, ASIA C, Meyerding grade IV and Wagner stage II sacral pressure sores. Spinal decompression surgery followed by spinal stabilisation was indicated. Eleven weeks later, the patient underwent spinal stabilisation and spinal decompression laminectomy via the posterior approach. Stabilisation was performed using two parallel rods attached to 8 pedicle screws, 4 on each side, placed at 4 levels (D12, L1, L2 and L3) under fluoroscopy. This stabilisation was preceded by contraction of two dislocated spinal ends (Fig. 2). During the same procedure, the gluteal ulcers were debrided and sutured in two layers, first with number 2/0 vicryl and then with number 0 monofilament nylon.

Postoperatively the patient could regain power and could stand up at one week, followed by walking with a walking frame at three weeks and normal walking at two months after several sessions of rehabilitation and physiotherapy (Fig. 3). She also recovered the vesico-sphincter function.

Discussion

Thoracolumbar dislocation fractures are uncommon. Mostly young people between 15 and 35 years of age are affected as a result of road accidents or falls from height [5]. Because of the high degree of violence required to produce dislocated fractures, they are often associated with major neurological deficits, such as complete paraplegia [3, 6].

The reported case is a dislocation fracture of the thoracolumbar hinge (L1-L2) in a 32-year-old female patient following a traffic accident. Clinically, the patient presented with paraparesia and urinary retention (ASIA C). Radiologically, it is a grade IV dislocation fracture, Magerl type B.3.3. The radio-clinical dichotomy is explained by the fact that such a type of lesion should normally manifest itself as a complete paraplegia (ASIA A) and not an incomplete neurological deficit. Several authors have reported cases similar to ours, even complete fracture dislocations, Meyerding grade V, without neurological deficit. They have tried to explain this radio-clinical discrepancy by the possibility of spontaneous decompression caused by the separation of the anterior column from the middle column following the fracture of the pedicles during the trauma. This would enlarge the spinal canal and preserve the cord from traumatic injury [5, 6, 7]. In our case, the pedicles were ruptured, which could justify this incomplete neurological deficit.

Conclusion

This case demonstrates the possibility of discordance between radiological images of thoracolumbar dislocation fractures, spinal cord injury, clinic and postoperative neurological recovery.

Limit of study

MRI was not performed. It was not available during that period ; But the surgery findings revealed a slight damage to the spinal cord and nerve roots.

Declarations

Funding. The authors do not have a financial relationship with any organization that sponsored the research.

Conflict of Interest. The authors declare that they have no conflict of interest.

Authors' contributions

IM followed the case, collated the figures, wrote the manuscript and sought consent from the patient.

PM was the senior physician overseeing the case.

DK corrected the manuscript English version.

AB supervised the work.

GN was the principle operator and the supervisor of the article redaction.

All the authors read and approved the final manuscript

References

1. Curfs I, Schotanus M, Van Hemert WLW, Heijmans M, De Bie RA, Van Rhijn LW, et al. Reliability and clinical usefulness of current classifications in traumatic thoracolumbar fractures: A systematic review of literature. *Int J Spine Surg.* 2020;14(6):956–69.
2. Su Q, Zhang Y, Liao S, Yan M, Zhu K, Yan S, et al. 3D Computed Tomography Mapping of Thoracolumbar Vertebrae Fractures. *Med Sci Monit.* 2019;25:2802–10.
3. Kanna RM, Raja DC, Shetty AP, Rajasekaran S. Thoraco-lumbar dislocations without spinal cord injury. Classification and principles of management. *Global Spine J.* 2021;11(1):63–70.
4. Denis F. The three column spine and its significance in the classification of acute thoracolumbar spinal injuries. *Spine.* 1983;8(8):817–31.
5. Rahimizadeh A, Asgari N, Rahimizadeh A. Complete thoracolumbar fracture-dislocation with intact neurologic function: Explanation of a novel cord saving mechanism. *J Spinal Cord Med.* 2018;41(3):367–76.
6. Vaccaro AR, Zeiller SC, Hulbert RJ, Anderson PA, Harris M, Hedlund R, et al. The thoracolumbar injury severity score: a proposed treatment algorithm. *J Spinal Disord Tech.* 2005;18(3):209–15.
7. Zeng J, Gong Q, Liu H, Rong X, Ding C. Complete fracture-dislocation of the thoracolumbar spine without neurological deficit. A case report and review of the literature. *Med (Baltim).* 2018;97(9):0050

Figures

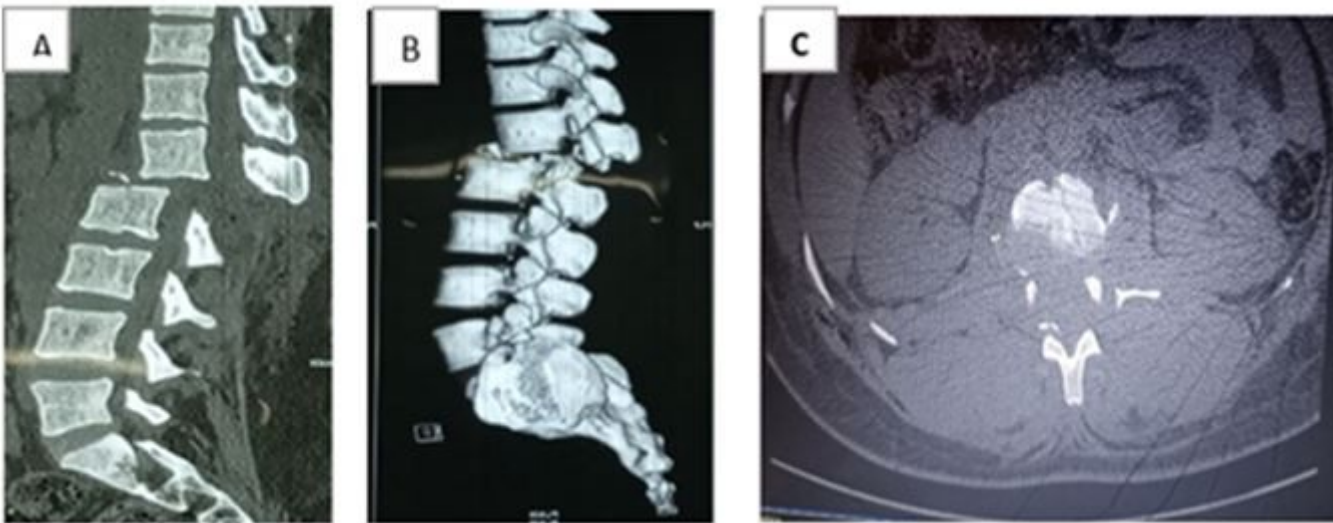


Figure 1

Preoperative CT images showing retrolisthesis on sagittal slices (A-B) and fracture of the pedicles and transverse processes of L2 on an axial slice (C).

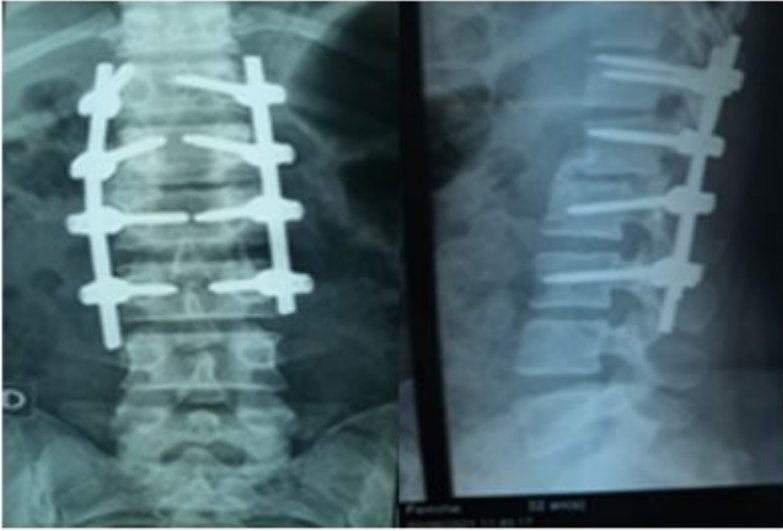


Figure 2

Postoperative images showing reduction and stabilisation with pedicle screws.



Figure 3

Patient regained power, standing station and walking.