Metallic Stent Placement Versus Catheter Drainage for Malignant Bilioenteric Anastomotic Stricture

Wei-zhong Zhou
The First Affiliated Hospital of Nanjing Medical University
Jun-zheng Wu
The First Affiliated Hospital of Nanjing Medical University
Sheng Liu
The First Affiliated Hospital of Nanjing Medical University
Wei Wan
The First Affiliated Hospital of Nanjing Medical University
Chun-gao Zhou
The First Affiliated Hospital of Nanjing Medical University
Hai-Bin Shi (Shihb@njmu.edu.cn)
The First Affiliated Hospital of Nanjing Medical University

Research article

Keywords: Self-expandable metallic stent, Catheter Drainage, Malignant Bilioenteric Anastomotic Stricture, Stent/Catheter malfunction

Posted Date: June 3rd, 2020

DOI: https://doi.org/10.21203/rs.3.rs-30594/v1

Version of Record: A version of this preprint was published at Japanese Journal of Radiology on November 29th, 2021. See the published version at https://doi.org/10.1007/s11604-021-01222-5.

Abstract

Background

Currently, the percutaneous approach is the mainstream of treatment for malignant bilioenteric anastomotic stricture (BAS). However, there is no consensus on the optimal bile drainage method since previous studies on malignant BAS related jaundice are very limited. The purpose of the study is to compare self-expandable metallic stent placement with catheter drainage for malignant bilioenteric anastomotic stricture in terms of efficacy and safety.

Materials and Methods

This study included 54 patients with malignant bilioenteric anastomotic stricture treated from March 2016 to February 2020. Twenty-seven patients underwent insertion of self-expandable metallic stent (Stent group); the remaining twenty-seven patients underwent internal-external catheter drainage (Catheter group). Technical success was defined as successful placement of stent or drainage catheter in the appropriate position; clinical success was defined as a 20% reduction in serum bilirubin within 1 week after the procedure, compared with baseline. Complications, duration to stent/catheter malfunction, and overall survival were evaluated.

Results

Technical success was achieved in all patients in both groups. In the Stent group, 21 patients received one stent and the other 6 patients required two stents. Clinical success rates were similar between the groups (Stent group, 92.6% [25/27]; Control group, 88.9% [24/27]). There were no major complications. The median duration to stent/catheter malfunction was significantly longer in the Stent group (130 days) than in the Control group (82 days; P = 0.010). The median overall survival was also significantly longer in the Stent group (187 days) than in the Catheter group (118 days; P = 0.038).

Conclusion

Self-expandable metallic stent placement may be better than internal-external catheter drainage for malignant bilioenteric anastomotic stricture in terms of the duration before stent/catheter malfunction and patient survival.

Background

Malignant bilioenteric anastomotic stricture (BAS) is an uncommon condition caused by tumor recurrence at the anastomotic site after surgery [1, 2]. Published articles on BAS are few due to its low incidence and late development following surgery [3, 4]. According to a recent study of 420 patients who

underwent bilioenteric anastomosis due to benign or malignant tumors, only 0.8% of patients were diagnosed with malignant BAS [2]. Malignant BAS could lead to obstructive jaundice. To relieve jaundice, endoscopic intervention is usually technically challenging because of surgically altered gastrointestinal anatomy [5]. Thus, the percutaneous approach is regarded as the mainstream of treatment for this condition [6, 7].

However, since previous studies on malignant BAS related jaundice are very limited, there is no consensus on the optimal bile drainage method via the percutaneous approach. Whether metallic stents can be routinely used in this kind of patient is still in controversy, as it raises the concern that a stent being placed across the stricture may cause high rates of cholangitis and stent migration [8–10]. Thus, percutaneous transhepatic catheter drainage is conventionally performed for these patients. However, the catheter drainage has several disadvantages such as bile loss, catheter dislodgement, lowering the quality of life, and so on [11–13]. Therefore, further investigation to compare these two techniques is warranted.

The purpose of this study was to compare self-expandable metallic stent (SEMS) placement with internal-external catheter drainage for malignant BAS in terms of efficacy and safety.

Materials And Methods

Patients

The study was approved by our institutional review board. The data of 66 patients with malignant bilioenteric anastomotic strictures who underwent internal-external catheter drainage or SEMS placement in our department between March 2016 to February 2020 were retrospectively reviewed. Inclusion criteria were: (i) diagnosis of malignant BAS on the basis of imaging (contrast-enhanced CT or magnetic resonance imaging) and laboratory findings; (ii) surgically unresectable disease; (iii) no previous biliary drainage prior to admission; (iv) with a regular follow-up. Twelve patients were excluded: seven were lost to follow up and five had received external drainage before stent placement at another hospital. Of the remaining 54 patients who met inclusion criteria, 27 underwent internal-external catheter drainage (Catheter group) and 27 received stent implantation (Stent group).

Procedure

Before the procedure, intravenous sedation with oxycodone and midazolam was used to alleviate pain during the procedure.

Stent placement group

Under fluoroscopic guidance, the intrahepatic bile duct was punctured using a 22-G Chiba needle (Cook, Bloomington, IN), followed by insertion of a Neff percutaneous access set (Cook, Bloomington, IN). The

outer cannula of the Neff set was kept for cholangiography to assess the severity of the anastomotic stricture. A 0.035-inch guidewire was then inserted and the outer cannula of the Neff set was exchanged with a 5-F Headhunter or Cobra catheter to pass through the stricture into the intestine. After measurement of the length of the stricture, a 6-F sheath was advanced over the guidewire to the intrahepatic bile duct. A bare SEMS was inserted through the sheath and delivered in the center of the stricture. Both ends of the stent should be at least 1.5 to 2 cm longer than the stricture. After stent placement, repeat cholangiography was performed to verify the stent patency. Finally, the puncture approach was occluded with gelfoam pledgets through the sheath (Fig. 1).

Catheter drainage group

The puncture technique used in the Catheter group was similar to that described in the Stent group. As the extrahepatic bile duct was short after the anastomosis, an external drainage catheter was cut with additional side holes to function as an internal-external drainage catheter for the convenience of the patients. After the stricture was crossed, the 8.5-F or 10-F drainage catheter (COOK) was advanced over the 0.035-inch guidewire and into the bile ducts. The pigtail tip was located in the intestine and the cutting holes were placed above the stricture. Cholangiography was repeated to ensure the adequate location of the catheter. Then, the catheter was then fastened at the skin surface with stitches (Fig. 2).

Assessment and follow-up

Technical success was defined as successful placement of stent or drainage catheter in the appropriate position, with good drainage of the bile. Clinical success was defined as a decrease of serum bilirubin level by at least 20% compared with the baseline within 1 week after the procedure. All complications were divided into major or minor based on the reporting standards of the Society of Interventional Radiology [14]. Major complications were defined as those requiring major therapy, an unplanned increase in the level of care, or prolonged hospitalization (> 48 h), and those causing permanent adverse sequelae or death. Other complications were considered to be minor.

All patients were regularly followed up through June 2019 or until patient death. The follow-up visits consisted of outpatient and telephone interviews. Telephone interviews were performed at 2 weeks and then every 3 months after the treatment. Outpatient interviews were performed 1 month after stent or catheter implantation. During the follow-up period, the patient was encouraged to receive stent revision or catheter exchange if obstructive jaundice recurred (confirmed by elevation of bilirubin level and dilatation of bile ducts on CT).

The duration of stent/catheter malfunction was measured from the time of initial stent/catheter placement to recurrence of jaundice, the last follow-up, or patient death without evidence of jaundice. If a patient ceased without recurrent jaundice, the stent/catheter patency period was considered to be the same as the duration of survival. Survival was defined as the time interval between the initial stent/catheter placement and death from any cause or last follow-up.

Statistical analysis

The paired t-test was used for testing within-subject comparisons and the independent t-test for testing differences between groups. A chi-squared test or Fisher's exact test was used to compare categorical variables, depending on the scale level. Survival curves were calculated with the Kaplan–Meier method and compared with a log-rank test. A two-tailed P-value lower than 0.05 was considered statistically significant. All analyses were performed with SPSS version 15.0 software (SPSS, Chicago, Illinois, USA).

Results

The 54 patients consisted of 30 men and 24 women, with a mean age of 60.8 years (range 19–82 years). The primary causes of anastomotic strictures were cholangiocarcinoma (n = 35), pancreatic carcinoma (n = 9), gallbladder carcinoma (n = 4), and gastric cancer (n = 6). The detailed baseline characteristics of the two groups are listed in Table 1 and there was no significant difference between the two groups (All P > 0.05).

Table 1
Patients' characteristics of the two groups

	Catheter	Stent	*P* Value
Pt. No.	27	27	
Age (Year)	60.6 ± 12.4	61.0 ± 11.6	0.92
Gender (M/F)			0.27
Male	17 (63.0)	13(48.1)	
Female	10(37.0)	14(51.9)	
Obstruction causes			0.40
Cholangiocarcinoma	16(59.3)	19(70.4)	
Pancreatic cancer	6(22.2)	3(11.1)	
Gallbladder cancer	3(11.1)	1(3.7)	
Gastrointestinal cancer	2(7.4)	4(14.8)	
ECOG			0.36
1	18(66.7)	21(77.8)	
2	9(33.3)	6(22.2)	
CA19-9 > 1000	8(29.6)	8(29.6)	1
Further Chemotherapy	7(25.9)	11(40.7)	0.25
Note-Values in parentheses are per-centages. ECOG = Eastern Cooperative Oncology Group; CA19-9 = cancer antigen 19 – 9			

Technical success

Technical success was achieved in all patients in both groups. In the Stent group, 21 patients received one stent, and the other 6 patients required two stents placed using the side-by-side technique because of isolated strictures. Two types of uncovered SEMS with a diameter of 8 mm and lengths from 40 to 80 mm were used in this study (E-Luminexx [Bard Peripheral Vascular, Tempe, AZ] and Zilver [Cook, Bloomington, IN]). The stents with a size of 8*60 mm were the most commonly used. In the Catheter group, 8.5F drainage catheters were used in 20 patients and 10F drainage catheters in the remaining 7 patients.

Clinical success

The clinical success rate was similar between the two groups (Stent group, 92.6% [25/27]; Control group, 88.9% [24/27]). The bilirubin level in both groups decreased significantly after the procedures except five patients with severe infection and poor general conditions (ECOG = 2) prior to the procedures. Table 2 lists the liver function parameters including total bilirubin, direct bilirubin, alanine aminotransferase, and aspartate aminotransferase of the two groups before and after the procedures.

Table 2
Liver function before and 1 week after the procedures in the two groups

	Catheter	**Stent**	***P* Value**
ALT (U/L)			
Before	89.5 ± 91.2	90.8 ± 67.9	0.95
After	40.3 ± 23.7	45.6 ± 31.5	0.48
P Value	0.00	0.00	
AST (U/L)			
Before	97.9 ± 79.7	96.9 ± 58.8	0.96
After	52.9 ± 38.1	49.1 ± 31.8	0.69
P Value	0.00	0.00	
TBIL (μmol/L)			
Before	183.1 ± 146.5	179.6 ± 116.2	0.93
After	111.7 ± 85.5	103.0 ± 89.9	0.72
P Value	0.00	0.00	
DBIL (μmol/L)			
Before	129.0 ± 102.5	132.1 ± 87.3	0.90
After	77.1 ± 61.8	71.1 ± 59.6	0.72
P Value	0.00	0.00	
Note-ALT = alanine aminotransferase; AST = aspartate aminotransferase; TBIL = total bilirubin; DBIL = direct bilirubin.			

Complications

No major complications occurred in both groups. Minor complications were observed no significant difference between two groups (Table 3). Six patients developed cholangitis (four in the Stent group and two in the Catheter group) after the procedures, which were resolved with antibiotics. One patient in the

Stent group developed pancreatitis with amylase > 500 U/L after stent placement. After two days of fasting, intravenous nutritional support, anti-inflammatory and other treatments, his amylase dropped to normal and he complained of no discomfort. Although some patients developed right abdominal pain or nausea, all were mild and responded to symptomatic treatment.

Table 3
Complications of the two groups

	Catheter	Stent	*P* Value
Major complication	0	0	1
Minor complications	7 (18.4)	9 (33.3)	0.24
Cholangitis	2 (7.9)	4 (29.6)	0.04
Pancreatitis	1 (5.3)	0	1
Abdominal pain	7 (2.6)	6( )	1
Nausea	5	4	
Note-Values in parentheses are percentages.			

Follow-up time, stent patency, and survival

Patients were followed up for 1–12 months (mean 5 months) in the Stent group and 1–10 months (mean 4 months) in the Catheter group. Eleven patients in the Stent group and seven patient in the Catheter group underwent further chemotherapy after the relief of jaundice. The median duration before the stent/catheter malfunction was 130 days in the Stent group and 82 days in the Catheter group (P = 0.010, Fig. 4). A total of 16 patients had the stent/catheter malfunction: six patients in the Stent group and were treated with external drainage (Fig. 3); ten patients in the Catheter group underwent catheter drainage due to catheter malfunction (dislodgement and/or occlusion). Through the follow-up, only six patients in the Stent group and three patients in the Catheter group were alive. The causes of death in the Stent group included disease progression (n = 8), liver failure (n = 5), multiple organ failure (n = 5), infection (n = 2), and alimentary tract hemorrhage (n = 1). In the Catheter group, causes of death included disease progression (n = 7), liver failure (n = 4), multiple organ failure (n = 5), infection (n = 6), and alimentary tract hemorrhage (n = 2). The median overall survival in the Stent group was significantly longer (187 days) than that in the Catheter group (118 days, P = 0.038; Fig. 5).

Discussion

In this study, we compared the clinical outcomes of patients with malignant BAS who received stent insertion versus those who received internal-external drainage. The results showed that median duration

before stent/catheter malfunction and median overall survival were significantly longer in the Stent group than in the Catheter group.

Traditionally, stent placement is better than catheter drainage for patients with malignant obstructive jaundice who are unsuitable for surgery, as it almost does not affect the patient's quality of life [15, 16]. However, for malignant BAS, the condition is different since the anatomy changes after surgery. The stricture is usually very short. Stent migration and cholangitis due to intestinal fluid reflux are the two main concerns after stent placement [8–10].

In this study, the incidences of cholangitis after the procedures were similar between the two groups, which mean stent insertion did not increase the incidence of cholangitis. Furthermore, infection was found to be more frequent as the cause of death in the Catheter group. This may be resulted from ex vitro infection tracking along the drainage catheter [17, 18].

With regard to stent migration, as the data were retrospectively collected and follow-up abdominal CT was not regularly performed in the stent group to check the stent position, it is impossible to obtain the exact stent migration rate. However, the stent was assumed to be in position and patent if the patient had no recurrence of jaundice. And for those patients in the Stent group with recurrent jaundice, CT and fluoroscopy were performed and stent migration was not found. These facts may prove that stent migration should not be an important concern when the stent is placed across the anastomotic stricture.

In terms of the duration before stent/catheter malfunction and patient survival, the Stent group was significantly better than the Catheter group. Compared with the stent being placed inside, the internal-external catheter has several disadvantages. First, the internal-external catheter could easily be malfunction by the debris in the bile or dislodgement due to improper catheter care [19]. Second, the internal-external drainage could cause fluid and electrolyte loss leading to metabolic imbalance [20, 21]. Third, as part of the drainage catheter is exposed externally and its caliber is small, which is easy to cause biliary infection [22]. Thus, these may be the reasons for the longer stent patency and overall survival in the Stent group.

This study has several limitations. Firstly, because this is a retrospective study and thus had no randomization, there could be bias in patient selection. Most of the procedures in the Catheter group were performed early in the study period and most in the Stent group were performed later in the study period. Secondly, this study included a small number of patients; a randomized prospective study with a large number of patients is warranted to prove our results in the future.

In conclusion, the preliminary results of this study demonstrated that self-expandable metallic stent placement is better than internal-external drainage catheter insertion for malignant bilioenteric anastomotic strictures in terms of the duration before stent/catheter malfunction and patient survival.

Abbreviations

Bilioenteric anastomotic stricture (BAS)

Self-expandable metallic stent (SEMS)

Eastern Cooperative Oncology Group (ECOG)

Declarations

Ethics approval and consent to participate

All procedures performed in this study were in accordance with the ethical standards of ethical committee of the First Affiliated Hospital of Nanjing Medical University and with the 1964 Helsinki declaration and its later amendments. Written informed consent was obtained from individual or guardian participants included in the study.

Consent for publication

The patients gave written consent for their personal or clinical details along with any identifying images to be published in this study.

Availability of data and materials

The datasets used and analysed during the current study are available from the corresponding author on reasonable request.

Competing interests

The authors declare that they have no competing interests.

Funding

This study was not supported by any funding.

Authors' contributions

WZ. Z and HB. S conceived of and designed the study; JZ. W, S. L, and W. W acquired and analyzed data. WZ. Z and JZ. W wrote the first draft. S. L, W. W, and CG. Z revised the manuscript for important intellectual content critically. All authors made substantial contributions towards drafting the manuscript,

reviewing the final manuscript for intellectual content, and authorizing the submission. All of the authors read and approved the final manuscript.

Acknowledgements:

Not applicable.

References

1. Kadaba RS, Bowers KA, Khorsandi S, Hutchins RR, Abraham AT, Sarker SJ, et al. Complications of biliary-enteric anastomoses. Ann R Coll Surg Engl. 2017;99(3):210–5.
2. Zhu JQ, Li XL, Kou JT, Dong HM, Liu HY, Bai C, et al. Bilioenteric anastomotic stricture in patients with benign and malignant tumors: prevalence, risk factors and treatment. Hepatobiliary Pancreat Dis Int. 2017;16(4):412–7.
3. House MG, Cameron JL, Schulick RD, Campbell KA, Sauter PK, Coleman J, et al. Incidence and outcome of biliary strictures after pancreaticoduodenectomy. Ann Surg. 2006;243(5):571-6; discussion 6–8.
4. Malgras B, Duron S, Gaujoux S, Dokmak S, Aussilhou B, Rebours V, et al. Early biliary complications following pancreaticoduodenectomy: prevalence and risk factors. HPB (Oxford). 2016;18(4):367–74.
5. Saleem A, Baron TH, Gostout CJ, Topazian MD, Levy MJ, Petersen BT, et al. Endoscopic retrograde cholangiopancreatography using a single-balloon enteroscope in patients with altered Roux-en-Y anatomy. Endoscopy. 2010;42(8):656–60.
6. Mita A, Hashikura Y, Masuda Y, Ohno Y, Urata K, Nakazawa Y, et al. Nonsurgical policy for treatment of bilioenteric anastomotic stricture after living donor liver transplantation. Transpl Int. 2008;21(4):320–7.
7. Duconseil P, Turrini O, Ewald J, Berdah SV, Moutardier V, Delpero JR. Biliary complications after pancreaticoduodenectomy: skinny bile ducts are surgeons' enemies. World J Surg. 2014;38(11):2946–51.
8. Okamoto T, Fujioka S, Yanagisawa S, Yanaga K, Kakutani H, Tajiri H, et al. Placement of a metallic stent across the main duodenal papilla may predispose to cholangitis. Gastrointest Endosc. 2006;63(6):792–6.
9. Jang S, Stevens T, Parsi M, Lopez R, Zuccaro G, Dumot J, et al. Association of covered metallic stents with cholecystitis and stent migration in malignant biliary stricture. Gastrointest Endosc. 2018;87(4):1061–70.
10. Horaguchi J, Fujita N, Noda Y, Kobayashi G, Ito K, Koshita S, et al. Metallic stent deployment in endosonography-guided biliary drainage: long-term follow-up results in patients with bilio-enteric anastomosis. Dig Endosc. 2012;24(6):457–61.

11. Beissert M, Wittenberg G, Sandstede J, Beer M, Tschammler A, Burghardt W, et al. Metallic stents and plastic endoprostheses in percutaneous treatment of biliary obstruction. Z Gastroenterol. 2002;40(7):503–10.
12. Doctor N, Dick R, Rai R, Dafnios N, Salamat A, Whiteway H, et al. Results of percutaneous plastic stents for malignant distal biliary obstruction following failed endoscopic stent insertion and comparison with current literature on expandable metallic stents. Eur J Gastroenterol Hepatol. 1999;11(7):775–80.
13. Kuhn JP, Busemann A, Lerch MM, Heidecke CD, Hosten N, Puls R. Percutaneous biliary drainage in patients with nondilated intrahepatic bile ducts compared with patients with dilated intrahepatic bile ducts. AJR Am J Roentgenol. 2010;195(4):851–7.
14. Sacks D, McClenny TE, Cardella JF, Lewis CA. Society of Interventional Radiology clinical practice guidelines. J Vasc Interv Radiol. 2003;14(9 Pt 2):199–202.
15. Guo YX, Li YH, Chen Y, Chen PY, Luo PF, Li Y, et al. Percutaneous transhepatic metal versus plastic biliary stent in treating malignant biliary obstruction: a multiple center investigation. Hepatobiliary Pancreat Dis Int. 2003;2(4):594–7.
16. Perdue DG, Freeman ML, DiSario JA, Nelson DB, Fennerty MB, Lee JG, et al. Plastic versus self-expanding metallic stents for malignant hilar biliary obstruction: a prospective multicenter observational cohort study. J Clin Gastroenterol. 2008;42(9):1040–6.
17. Xu C, Lv PH, Huang XE, Sun L, Wang SX, Wang FA. Internal-external percutaneous transhepatic biliary drainage for patients with malignant obstructive jaundice. Asian Pac J Cancer Prev. 2014;15(21):9391–4.
18. Szabo S, Mendelson MH, Mitty HA, Bruckner HW, Hirschman SZ. Infections associated with transhepatic biliary drainage devices. Am J Med. 1987;82(5):921–6.
19. Nomura T, Shirai Y, Hatakeyama K. Bacteribilia and cholangitis after percutaneous transhepatic biliary drainage for malignant biliary obstruction. Dig Dis Sci. 1999;44(3):542–6.
20. Furey AT. Hyponatremia after choledochostomy and T tube drainage. Am J Surg. 1966;112(6):850–5.
21. Kichloo A, Zain EA, Khan MZ, Wani F, Singh J. Severe Persistent Hyponatremia: A Rare Presentation of Biliary Fluid Loss. J Investig Med High Impact Case Rep. 2019;7:2324709619869379.
22. Chandrashekhara SH, Gamanagatti S, Singh A, Bhatnagar S. Current Status of Percutaneous Transhepatic Biliary Drainage in Palliation of Malignant Obstructive Jaundice: A Review. Indian J Palliat Care. 2016;22(4):378–87.

Figures

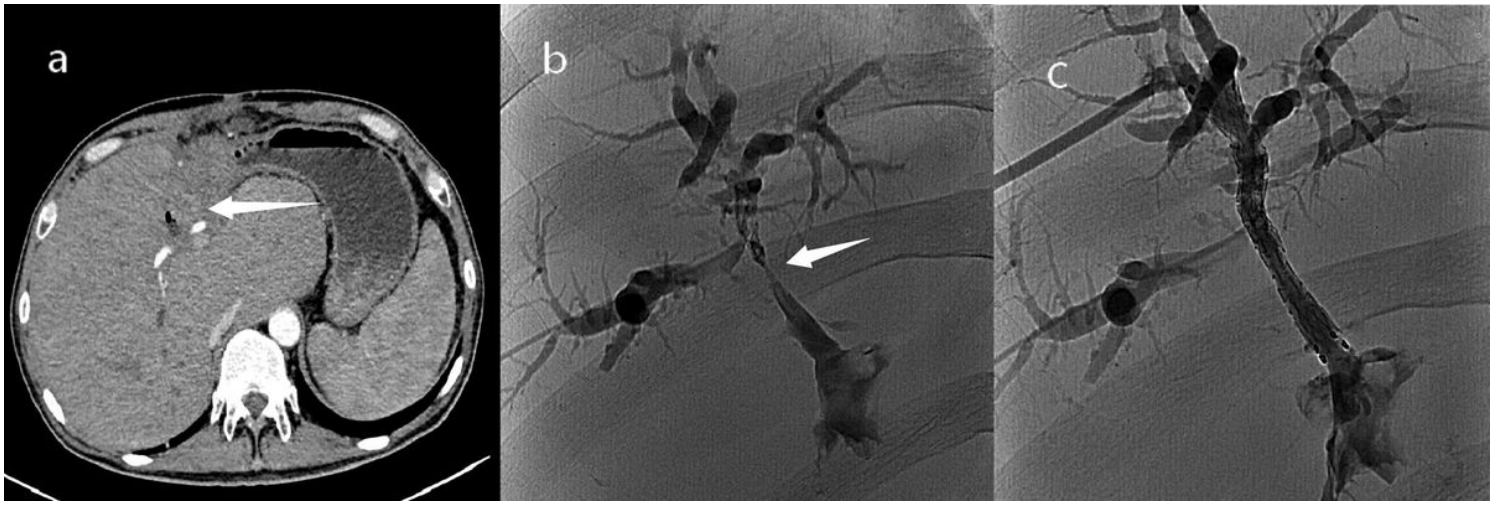

Figure 1

A 68-year-old man had malignant bilioenteric anastomotic stricture seven months after undergoing radical section for hilar cholangiocarcinoma. (a) Wall thickening and arterial phase enhancement of bilioenteric anastomotic showing tumor recurrence (white arrow). (b) Fluoroscopic image showing bilioenteric anastomotic stricture (white arrow). (c) A bare SEMS (diameter 8 mm, length 6 cm) was placed in the center of the stricturethe and cholangiography showed that the stent was patent.

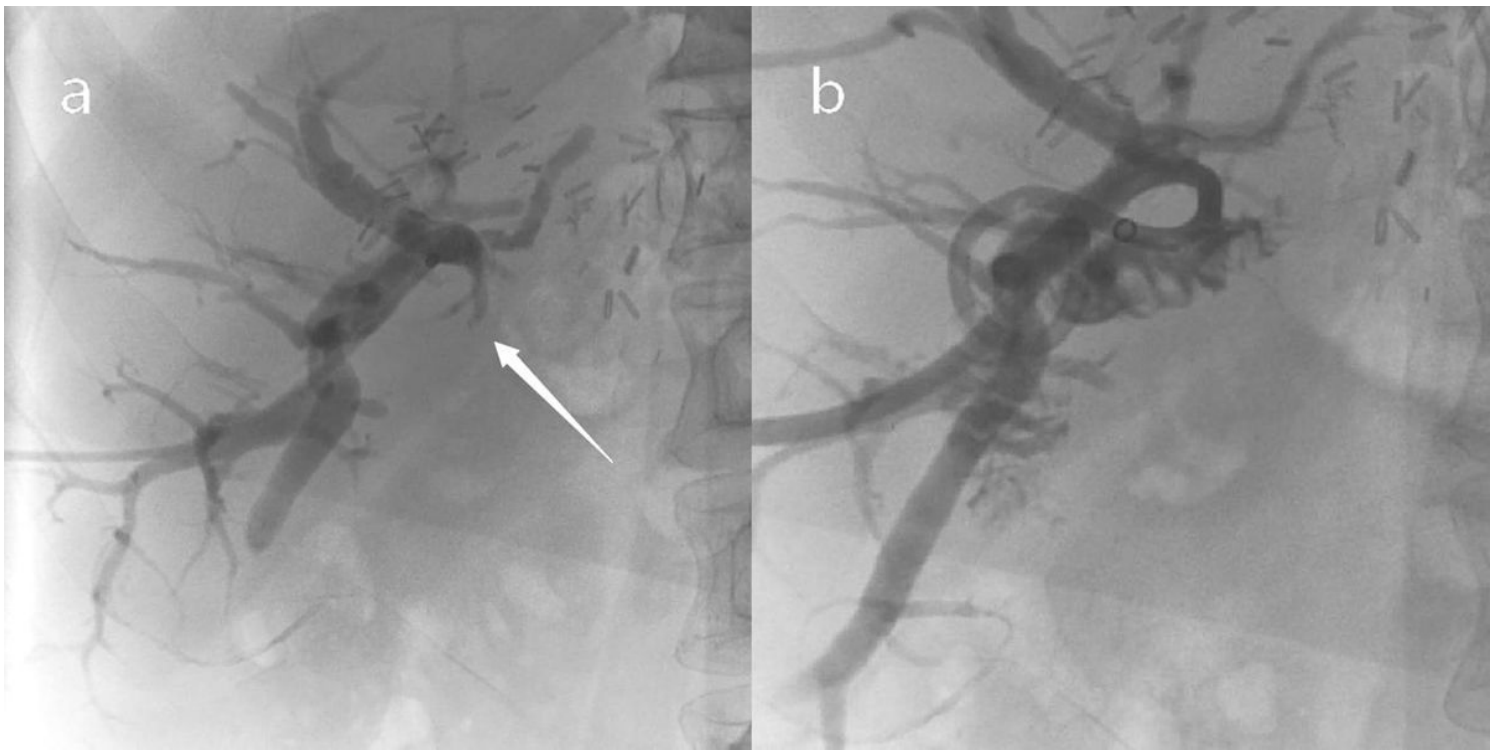

Figure 2

A 65-year-old man had malignant bilioenteric anastomotic stricture six years after undergoing left hepatectomy and hepatectomy for cholangiocarcinoma. (a) Fluoroscopic image showing bilioenteric anastomotic stricture (white arrow). (b) A 8.5-F percutaneous transhepatic biliary drainage catheter with additional side holes was deployed for internal and external drainage.

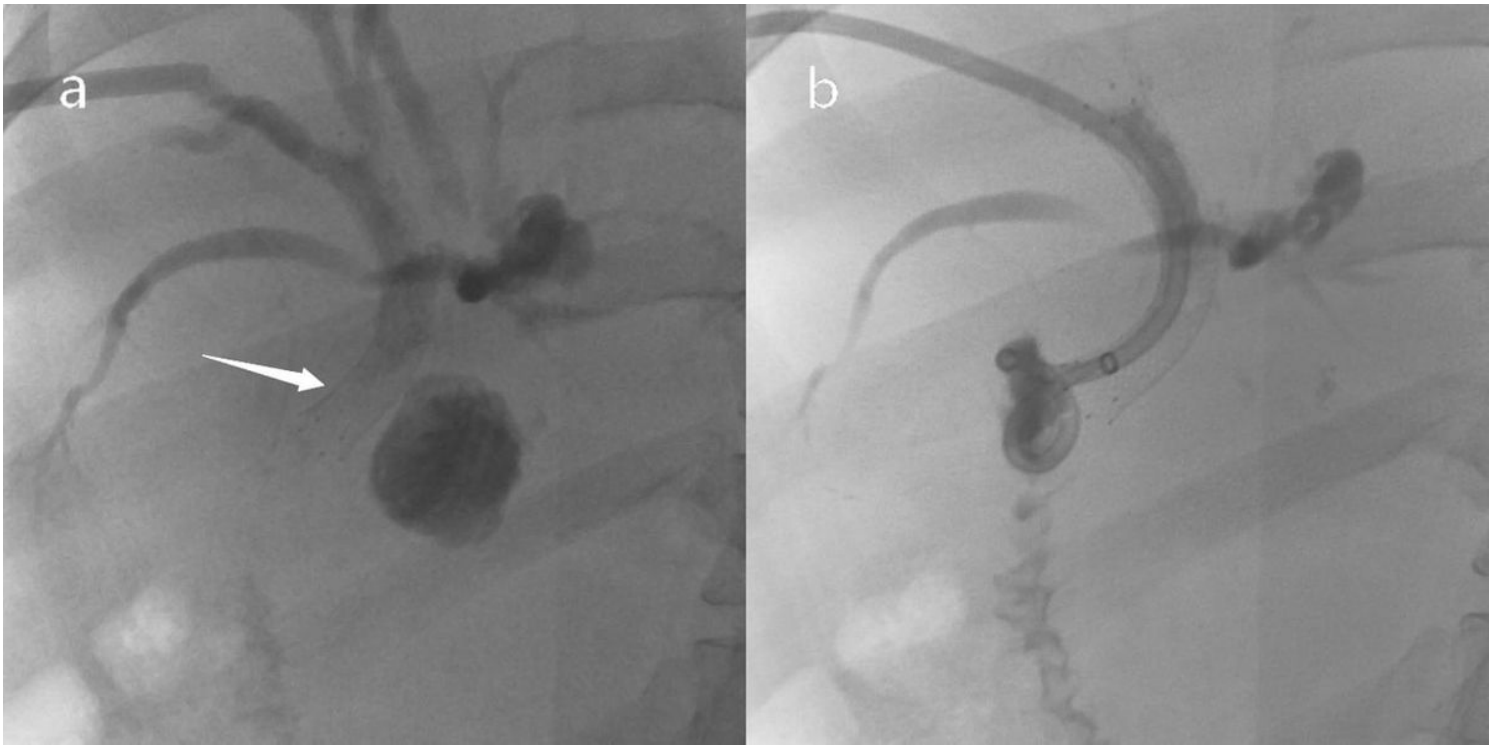

Figure 3

A 62-year-old woman readmitted with jaundice 134 days after SEMS placement. (a) Cholangiography showing obstruction of the lower part of the stent (white arrow). (b) A 8.5-F drainage catheter was placed through the obstruction segment for drainage.

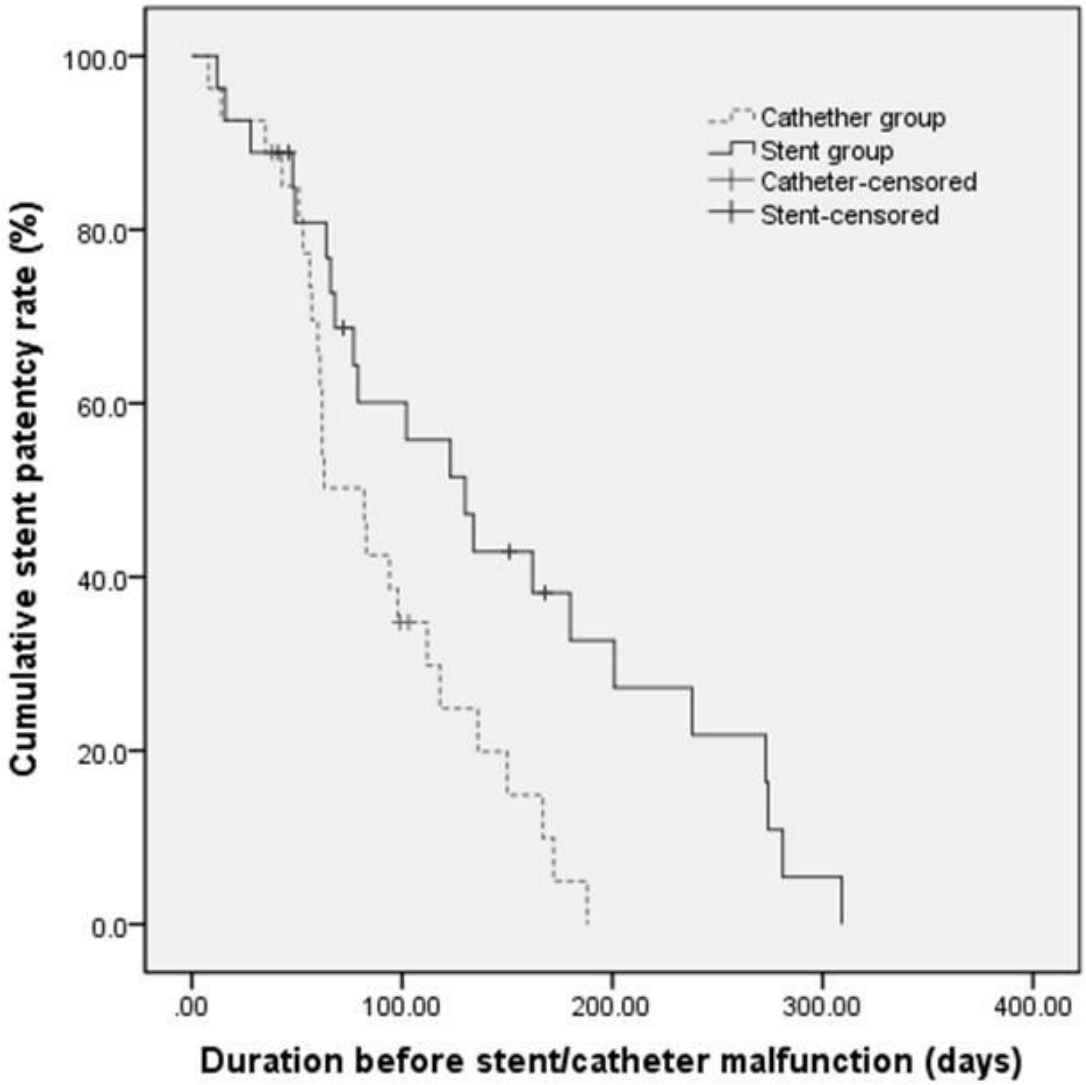

Figure 4

Kaplan–Meier estimation of duration before stent/catheter malfunction. Duration before stent/catheter malfunction in the Stent group was significantly longer than that in the Catheter group (P=0.010).

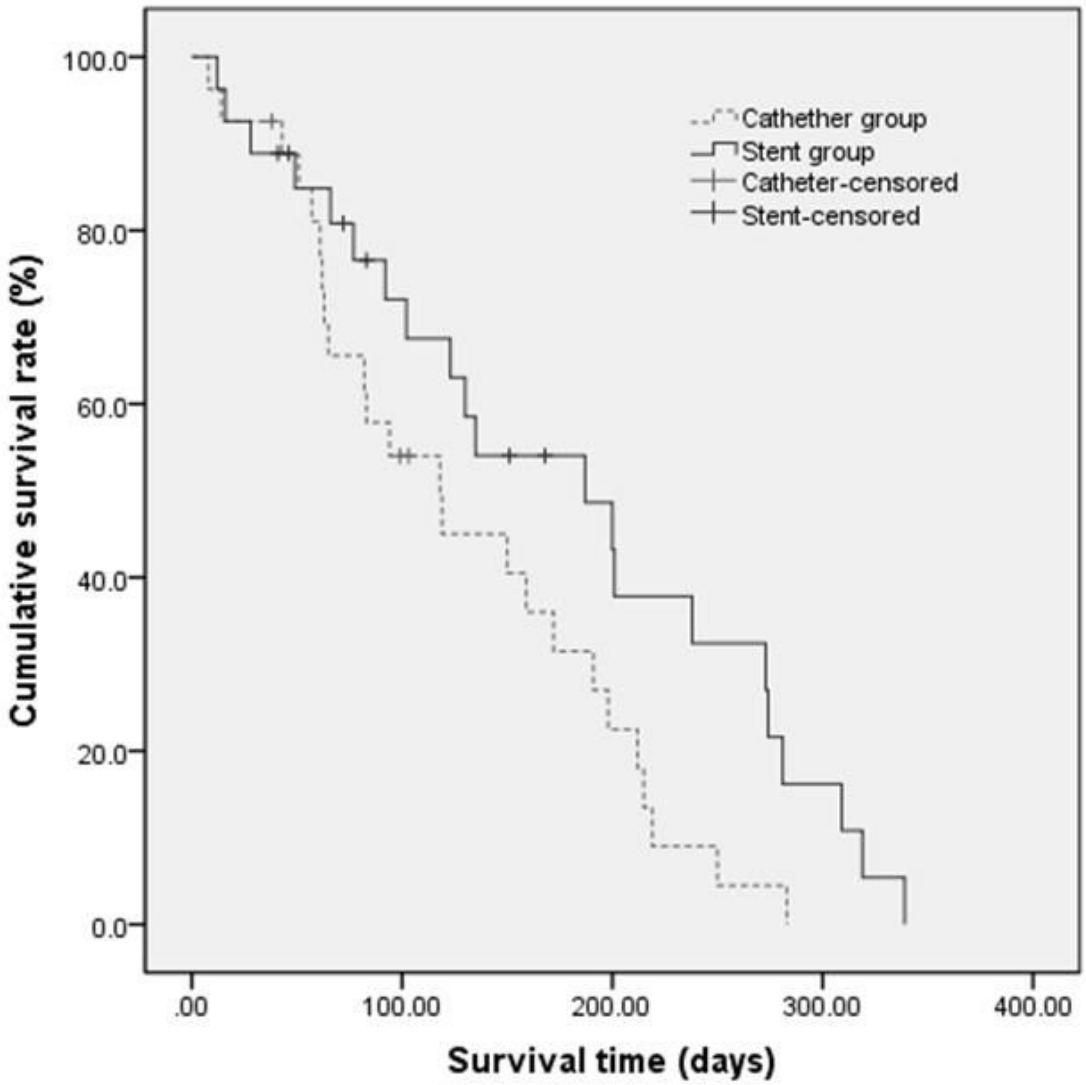

Figure 5

Kaplan–Meier estimation of patient survival. Survival time in the Stent group was longer than that in the Catheter group (P=0.038).