Surgical Ciliated Cyst Secondary to Orthognathic Surgery: Report of three cases and review of the literature

Díez-Montiel, Alberto, MD (diezmontiel@gmail.com)
Department of Oral and Maxillofacial Surgery Gregorio Marañon General University Hospital, Madrid, Spain https://orcid.org/0000-0003-1014-9426

Santos Armentia, Eloísa, MD, PhD
Department of Radiodiagnosis Hospital Povisa, Vigo, Spain

Antunez-Conde, Raul, MD
Department of Oral and Maxillofacial Surgery Gregorio Marañon General University Hospital, Madrid, Spain

Navarro-Cuéllar, Carlos, MD, PhD
Department of Oral and Maxillofacial Surgery Gregorio Marañon General University Hospital, Madrid, Spain

Tousidonis, Manuel, MD, PhD
Department of Oral and Maxillofacial Surgery Gregorio Marañon General University Hospital, Madrid, Spain

Salmeron, Jose Ignacio MD
Department of Oral and Maxillofacial Surgery Gregorio Marañon General University Hospital, Madrid, Spain

Antón-Badiola, Iosu María MD, PhD
Department of Pathology Hospital Povisa, Vigo, Spain

Castro Soares, José, MD
Department of Oral and Maxillofacial Surgery Hospital Povisa, Vigo, Spain

Bonsfills, Nuria, MD, PhD
ICIRE Institute for Reconstructive and Esthetic Surgery, Madrid, Spain

Case Report

Keywords: Surgical ciliated cyst, Nonodontogenic Cysts, Orthognathic Surgery, Paranasal Sinus, Maxillary Diseases, Delayed Complication

Posted Date: March 9th, 2021

DOI: https://doi.org/10.21203/rs.3.rs-307578/v1

Abstract

Background: Surgical ciliated cysts (SCC) of the maxilla appear as a delayed complication after surgery in the maxillary sinus, midface osteotomies, traumatic tooth extraction, and maxillary fractures. They are defined as a lytic lesion with entrapment of the pseudostratified columnar epithelium.

Report of three cases: We present three patients in which after orthognathic surgery a slowly enlarging asymptomatic swelling mass was developed. On CT, all the cases presented lytic expansive lesions in the alveolar ridge. In the three cases, lesions were completely excised, and upon histological examination, ciliated pseudostratified columnar epithelium with goblet cells was found so they were diagnosed as SCC.

An exhaustive review of the medical literature was conducted. The PubMed database was searched for PubMed Central (PMC). 44 references were found, reporting 1555 cases: 11 series and 33 case reports, being the largest series from the Asian countries. The mean age was 46.5 years, and more frequently described in male patients. The most frequent form of presentation was as unilateral unilocular cysts in the posterior maxilla. They were described most frequently after a Caldwell-Luc approach. The average latency time was of 19.9 years.

Conclusion: SCC is a rare complication after orthognathic surgery, but large series have been published, so maybe it could be interesting to include these cysts in the next Edition of the World Health Organization Classification of the Head and Neck Tumors: Odontogenic and Maxillofacial Bone Tumors, making clear the difference between SCC and mucoceles to avoid future confusions.

Introduction

Surgical ciliated cysts (SCC) were first described by Kubo et al. In 1927 [1] as a maxillary cyst secondary to a chronic maxillary sinusitis surgery. These cysts have also been termed as postoperative maxillary cysts and as postoperative paranasal cysts [2]. The clinical presentation may be variable, with some patients showing poorly defined pain, a painless mass, or even completely asymptomatic patients. They can be unilateral or bilateral and have been described as unilocular or multilocular lytic lesions. No side predominance has been found. The latency from the causal previous surgery to the appearance of the cyst ranges from months to several decades, making sometimes the diagnosis difficult.

Most of the reports and scientific papers come from the Asian literature and most often from Japan [3–5], but in the last years, many authors all over the world have described this entity. However, there are important differences about the size of the series (larger series coming from Asia and shorter ones from Occidental countries) and about the given details of the cases (scarce in Asian papers and thorough in Occidental reports. This difference may come from the exact definition and/or classification of SCC, so a deeper study is needed.

The aim of this paper is to review the existing literature and report the experience of our centers with this entity.

Case Report

In the last 7 years, there have been three cases of SCC in our hospital. An overview of the characteristics of our series is shown in Table 1.

Case 1

A 31-year-old female with severe skeletal class III malocclusion underwent orthognathic surgery. A Le Fort I maxillary osteotomy with horizontal advancement of 10 mm and a 5 mm vertical augmentation combined with autogenous iliac bone graft was performed in 2007 (Figure 1). One year later, in 2008, 8 implants were placed in the upper maxilla, and in 2009 two implants were explanted on the left side, and cranial vault bone graft was placed and fixed with screws.

Five years later, in 2013, she developed a slow-growing progressive swelling on the left posterior maxillary region of two months of evolution.

A dual-Energy CT after intravenous contrast administration was performed (Figure 1). On the right maxilla, a newly unilocular lytic expansive lesion was found, with marked thinning of the cortical bone. On the left posterior maxilla alveolar region, a smaller lytic expansive lesion could also be detected. On the iodine map, no enhancement was proved inside the lesions. Neither periosteal reaction nor cortical disruption was present. The surrounding tissues and the underlying dental pieces had a standard appearance.

With the radiological diagnosis of SCC, the patient underwent surgery, whereby the cyst of the right upper maxilla was completely enucleated and filled with lyophilized bone.

The lytic lesion of the left upper maxillary was conservatively treated with careful observation during follow-up.

Histopathological examination of the surgical specimen showed ciliated pseudostratified columnar epithelium with goblet cells and with an underlying capsular fibrous tissue partially hyalinised (Figure 1). These findings were compatible with SCC.

The patient remained asymptomatic for 6 years, but in 2019 she appeared with pain and swelling on the left upper maxilla, with signs and symptoms of maxillary infection. CT scan revealed that the pre-existing lytic lesion in the left side had increased substantially in size; consequently, a new surgical procedure was required; the cyst was enucleated and filled with lyophilized bone (images not shown).

Upon microscopic investigation, a cystic structure with a ciliated respiratory epithelium was again observed. Based on the pathological findings and location of the lesion, the diagnosis of SCC was once more made.

The patient remains asymptomatic at present.

Case 2:

A 14-year-old female patient with severe skeletal class III malocclusion underwent orthognathic surgery in 1995. No images are available for this surgery.

In 2015, when she was 34-year-old, she presented with facial pain focused on tooth 17, where a fistula discharging purulent material was evident on the physical examination. The panoramic radiograph depicted a lytic well-defined lesion on the tuberosity, on the posterior region of the right maxilla (images not shown).

CT scan after intravenous contrast administration (Figure 2) revealed postsurgical changes after LeFort type I and on the right upper maxilla, a lytic unilocular lesion with well-defined walls, and no enhancement inside the lesions was identified. The radiological diagnosis of SCC was performed. The 17 was removed and a cystectomy was conducted. The histological analysis showed an edematous vascularized stroma, with the proliferation of fibroblasts without atypia and slight and patchy inflammatory cellularity, in which spaces were lined by a columnar stratified respiratory epithelium (ciliated respiratory epithelial), containing scarce mucous and ciliated cells without dysplasia was found, compatible with SCC.

The patient evolved favorably and is currently asymptomatic.

Case 3

34-year-old man, with class III dental malocclusion and crossbite (with around 1 cm of midline deviation) consulted in the Maxillofacial Surgery Department in 2011. In 2016, Surgically Assisted Rapid Palatal Expansion (SARPE) was performed, and a pre-fabricated Hyrax appliance was used. Subsequently, after orthodontic preparation, he underwent orthognathic surgery, whereby a Le Fort I type I osteotomy of the upper maxilla was performed, with advancement and decrease of vertical dimension, fixed with mini-plates (figure 3).

The patient remained asymptomatic for two years, but in 2018 he presented slight discomfort on the right maxilla with some episodes of sinusitis.

A CT was performed, revealing a new unilocular lytic lesion at the right upper maxilla, under the floor of the maxillary sinus, most likely corresponding to SCC.

The patient was scheduled for surgery, in which the surgical hardware was removed and the cyst was enucleated and filled with demineralized lyophilized bone matrix.

The histological analysis showed a cystic cavity lined exclusively by respiratory epithelial tissue, containing scarce mucous and ciliated cells. The cyst wall contained chronic inflammatory infiltrate and the cystic content contained a varied amount of inflammatory cells represented by neutrophils.

The patient has had no symptoms up till now.

Review Of The Literature

In order to carry out a systematic review, the Prisma protocol was approached. The questions that have been answered in this study are: (a) what are specifically surgical ciliated cysts?, (b) how often do they appear?, (c) is there a race predominance? A search was carried out among articles in electronic databases of Pubmed, Embase, Cochrane Library, Scopus, and Google Scholar. The search strategy was based on Mesh vocabulary and the combination of these words was done with logical operators, “AND” and “OR” in search phrases, including the keywords “postoperative maxillary cyst”, “secondary mucocele”, “surgical ciliated cyst”, “respiratory epithelium lined cyst”, “postoperative mucocele”, and “ectopic ciliated cyst”, with no date filter. No language filter was used, and therefore papers in English, Japanese, German, Portuguese, and Polish, among others, were reviewed. First, the articles were screened based on title, abstract, and objective of the study, and their texts were retrieved. Then the whole text was analyzed and investigated and finally, 61 articles were selected.

Data collected from the papers were: country, age, location of the cyst, etiologic previous surgery, latency from the previous surgery to the appearance of the cyst, and recurrence.

Results Of The Literature

A total of 61 articles describing surgical ciliated cysts were found, describing 1857 patients. Of these articles, 44 were case reports (including 47 patients) and 17 series (with 1810 patients), in both single-center and multi-center studies (Table 2). Papers were from 19 different countries, being Japan the country where most of the cases were registered (1779 cases described in 18 articles). The United Kingdom (with 28 patients in 6 papers) and the USA (with 16 cases in 12 papers) were the followings by frequency. The rest of the countries published a short local series or case reports.

The mean age of the patients was 45.9 years old (range age: 17 - 80). When gender was specified, 926 were males (49.9%) and 745 females (40.1%).

The location of the cysts was analyzed per side and affected part of the maxilla. 160 patients were reported to have a unilateral cyst, 25 patients presented bilateral cyst, and 7 patients had a midline cyst. Unfortunately, the specific affected side was not described in larger series, so no there are no available data from the rest of the cases. The affected part of the maxilla was described in 437 patients; among these, the most referred affected part was the maxillary sinus and the posterior and lateral part of the maxilla (Table 3). 1420 records did not show the exact location in the maxilla or any location at all.

The previous surgery was specified only in 96 cases, being the Caldwell-Luc procedure the most common one, comprising 58.3% of the cases. In all the other cases, the initial surgery was described as “antral surgery” (in the largest series, the Japanese one from Nishioka et al[6]), “undescribed” (in the second largest series, the one by Kimizuka et al[7]), “maxillary radical surgery”, or “maxillary surgical intervention”. Of these patients, only 20 cases developed the SCC specifically after orthognathic surgery, 16 cases after a LeFort I osteotomy (alone or combined with other procedures) [3–5,8–13], 3 cases after a bimaxillary orthognathic surgery [14,15], and 1 patient after a LeFort II naso-maxillary advancement (Henderson-Jackson technique) [11]

The average time of latency for SCC after the first surgery was 20.1 years (range: 0.5 – 60.0 years). Only 3 papers described relapses (a British case from the paper of Sugar et al[11], one of the cases of Kimizuka et al[7], and 3 cases from the series of Higuchi et al[16]), describing no recurrence of 32 cases in 24 papers (mostly in case reports), but the remaining 34 papers did not mention anything about relapsing.

Discussion

In this paper, three patients with surgical ciliated cysts (two female and one male) have been described. The ciliated cysts appeared after a 2, 5, 12, and 20 years period, respectively, after orthognathic surgery. In one case, there was a small cyst in the contralateral maxilla that was considered initially to be observed, but it increased significantly its size after 6 years, so 4 SCC have been included in our series in 7 years.

Our series is a short one, with four SCC in three patients. Given that the usual way to communicate cases in the occidental area is one of the single case reports, we think our series will help in increasing the database of SCC and maybe clarifying some of the previous concerns.

The mean age of our three patients was about 10 years lower than the described in the literature. The location of the cysts was the posterior maxilla in all cases, tie in with the reported cases all over the world. Most of the SCC described in the literature were unilocular, but also, much less commonly, multilocular, with no differences in the evolution of both types; we presented two unilocular cysts and one bilobulated.

The previous surgery was a LeFort I procedure previous in all the cases, as described in other SCC in the literature [3–5,8–13], where it is not clear why there are so few cases associated with orthognathic surgery.

The term “postoperative maxillary cyst” or “SCC” refers to a delayed complication arising years after surgery involving the maxillary sinus. They are most commonly associated with a history of surgery for maxillary sinusitis, particularly Caldwell–Luc procedure, but may also result from gunshot injuries, fractures of the malar–maxillary complex, midface osteotomies and after orthognathic surgery and traumatic tooth extraction in the mandible [12,15,17–23]. A comprehensive patient medical record is of particular importance in guiding towards the final diagnosis, as it played a significant role in the diagnosis of the three cases here presented.

It is commonly found in the literature that the first author that described the surgical ciliated cyst was Kubo in 1927 [1]. He described a frequent cyst in the Japanese population, that represented as much as 20% of all the oral cysts, being uncommon in occidental areas [1,24]. After that first publication, we have found 60 articles referring to surgical ciliated cysts.

Cystic lesions found in the maxillary sinuses can be pseudocysts (with no epithelium in their walls) or real cysts (with a lining epithelium). Among the last ones, mucoceles, odontogenic cysts, bone cysts, fissural cysts, postsurgical maxillary cysts, and other non-odontogenic cysts are included. Pseudocysts do not show a wall of the epithelium, but a cavity filled with an inflammatory exudate, surrounded by a dense compact layer of connective tissue under the sinus mucosa, originating from the accumulation of that inflammatory exudate of the bone and pushing the periosteum and the sinus epithelium into the sinus cavity. Mucoceles, otherwise, show a lining of respiratory epithelium (pseudostratified ciliated epithelium with goblet cells) and can be classified as primary (retention mucous cysts without a known etiology) and secondary (originate from a known cause, like a chronic obstruction of the ostium of the sinus, an inflammation of the mucosa, previous surgeries on the sinus or close to it, chronic infections…) [9,24–26].

Surgical ciliated cyst can be considered a secondary mucocele. Simply, the difference between SCC and a secondary mucocele should be based on the growing pattern: mucoceles grow from the inside of the sinus in a centrifugal way, expanding the walls of the maxillary sinus; on the other hand, surgical ciliated cysts grow inside the trabecular bone, and from there they expand centrifugally. Since the epithelium of both lesions is respiratory, that is to say, a pseudostratified ciliated cylindrical epithelium, lesions where the real origin cannot be determined except for the surgical episode can be found [9,27–30].

Different hypotheses for the pathogenesis of SCC have been stated: **(1)** residual mucosa trapped in the bone during the surgical procedure [1,3,4,6,9,15,24,31–33]; **(2)** retention of blood or sinus tissue fluid that forms a closed space without communication with the outside [1,8,31,34–36]; **(3)** a racial predisposition to secondary mucoceles after chronic sinusitis surgery [6,32,37]; **(4)** implantation of sinus mucosa in a different location [2,5,8,15,25]; **(5)** early closure of the ostium for the natural drainage before the complete mucosalization of the sinus, with regeneration of granulation tissue [3,9,11,32,38–43]; **(6)** trauma, being the SCC secondary to accidental traumatisms or surgery (especially to the Caldwell-Luc procedure) [6,43]; **(7)** inflammation, being the SCC secondary to a continuous inflammatory process in a scarcely ventilated space, due to the occlusion of the drainage ostium

[6,32]; and **(8)** metaplasia from irritation, changing the original stratified epithelium of the nasal mucosa to respiratory epithelium [39,41]. **(9)** **P**luripotentiality of odontogenic epithelium in a cystic lesion with odontogenic origin with the presence of respiratory epithelium [5,12,15,25,37,44]. In our opinion, this last theory would be extremely rare, since the aggressions on a specialized epithelium like the respiratory one induce metaplastic changes towards a more resistant that provides protection (as the squamous epithelium); the inverse situation, that is, from a protective epithelium towards a specialized one like the respiratory epithelium, is an extraordinary scenario.

A wrong interpretation of the histologic findings should also be considered. For instance, if an odontogenic cyst grows enough to protrude over the maxillary sinus mucosa, and in the resection surgery the cyst is obtained in several parts, the pathoanatomic study can mislead the respiratory mucosa of the sinus with the wall of the cyst, thus classifying the lesion as a SCC. The finding of respiratory epithelium in a cyst does not make it a surgical ciliated cyst even if the patient could have received previous surgery.

Japanese literature offers a very high incidence of SCC. There are some reasons for these comparatively high figures: (1) a publication bias, where the reported cysts were not real SCC, and it could be considered if they were expansive mucoceles [27–30,33,40]. (2); differences when performing a Caldwell-Luc procedure, but we consider it less probable since the procedure is a worldwide standard one [32,33]; (3) a different pattern of the facial bone structure of the Japanese population compared with the Occidental one [6,37]; (4) a different bacterial flora colonizing the paranasal sinuses in the Japanese population [6,11,37,45]; (5) the more common surgical treatment of the chronic sinusitis during the II World War when antibiotics were scarce, although this finding would not support the persistent high figures in the past decades until today [10,11,31]. That is why we hypothesize that the real difference in the incidence of SCC should not be so striking between Asian and Occidental countries; a possible mistake in the interpretation of the histologic findings, as previously referred, or a classification bias, should be rethought.

Regarding treatment, symptomatic SCC has a surgical indication. Some different techniques have been proposed: simple cystectomy, cystectomy, and antrostomy, marsupialization… being all of them effective. The recurrence rate is extremely low.

The surgical ciliated cyst in the maxillary territory, although it is an entity described in the scientific literature, is neither included nor classified in the “4th Edition of the World Health Organization Classification of the Head and Neck Tumors: Odontogenic and Maxillofacial Bone Tumors” [25,26,46,47]. Since there are more than 1850 cases reported in the literature and 61 papers, maybe it could be interesting to include these cysts in the next edition, with a new definitive classification of the cysts that would not lead to confusion, making clear the difference between SCC and mucoceles to avoid future confusions.

Declarations

Compliance with Ethical Standards

The authors declare that they have no conflict of interest.

This is an observational study. The hospital Research Ethics Committee has confirmed that no ethical approval is required.

The authors affirm that human research participants provided informed consent for publication of the images in Figures 1, 2, and 3. The participants have consented to the submission of the case report to the journal.

The authors confirm that this study is not developed in response to an invitation from the Journal.

References

1. Kubo I. A buccal cyst occurred after a radical operation of the maxillary sinus in Japanese. Z F Otol Tokyo. 1927;3:896–7.
2. Yamamoto S, Maeda K, Kouchi I, Hirai Y, Taniike N, Imai Y, et al. Surgical ciliated cyst following maxillary sinus floor augmentation: A case report. J Oral Implantol [Internet]. Allen Press Inc.; 2017 [cited 2020 Jul 21];43:360–4. Available from: https://pubmed.ncbi.nlm.nih.gov/28841394/
3. Golaszewski J, Muñoz R, Barazarte D, Perez L. Surgical ciliated cyst after maxillary orthognathic surgery: a literature review and case report [Internet]. Oral Maxillofac. Surg. Springer Verlag; 2019 [cited 2020 Jul 2]. p. 281–4. Available from: https://pubmed.ncbi.nlm.nih.gov/31093791/
4. Hayhurst DL, Moenning JE, Summerlin DJ, Bussard DA. Surgical ciliated cyst: A delayed complication in a case of maxillary orthognathic surgery. J Oral Maxillofac Surg [Internet]. J Oral Maxillofac Surg; 1993 [cited 2020 Jul 2];51:705–8. Available from: https://pubmed.ncbi.nlm.nih.gov/8492215/
5. Bourgeois SL, Nelson BL. Surgical ciliated cyst of the mandible secondary to simultaneous Le Fort I osteotomy and genioplasty: Report of case and review of the literature. Oral Surgery, Oral Med Oral Pathol Oral Radiol Endodontology [Internet]. Mosby Inc.; 2005 [cited 2020 Jul 21];100:36–9. Available from: https://pubmed.ncbi.nlm.nih.gov/15953915/
6. Nishioka M, Pittella F, Hamagaki M, Okada N, Takagi M. Prevalence of Postoperative Maxillary Cyst Significantly Higher in Japan. Oral Med Pathol [Internet]. The Japanese Society for Oral Pathology; 2005 [cited 2020 Jul 21];10:9–13. Available from: http://joi.jlc.jst.go.jp/JST.JSTAGE/omp/10.9?from=CrossRef
7. Kimizuka S, ECHIGO S, Ilzuka Y, Matsuda K, YAMAGUCHI T, IIZUKA Y, et al. Clinicopathological study of postoperative maxillary cysts. JAPANESE J ORAL Maxillofac Surg. 1995;41:699–704.

8. Coviello V, Zareh Dehkhargani S, Patini R, Cicconetti A. Surgical ciliated cyst 12 years after Le Fort I maxillary advancement osteotomy: a case report and review of the literature. Oral Surg [Internet]. Blackwell Publishing Ltd; 2017 [cited 2020 Jul 21];10:165–70. Available from: http://doi.wiley.com/10.1111/ors.12246
9. Amin M, Witherow H, Lee R, Blenkinsopp P. Surgical ciliated cyst after maxillary orthognathic surgery: Report of a case. J Oral Maxillofac Surg. W.B. Saunders; 2003;61:138–41.
10. Shakib K, McCarthy E, Walker DM, Newman L. Post operative maxillary cyst: Report of an unusual presentation. Br J Oral Maxillofac Surg [Internet]. Br J Oral Maxillofac Surg; 2009 [cited 2020 Jul 2];47:419–21. Available from: https://pubmed.ncbi.nlm.nih.gov/18995936/
11. Sugar AW, Walker DM, Bounds GA. Surgical ciliated (postoperative maxillary) cysts following mid-face osteotomies. Br J Oral Maxillofac Surg [Internet]. Br J Oral Maxillofac Surg; 1990 [cited 2020 Jul 2];28:264–7. Available from: https://pubmed.ncbi.nlm.nih.gov/2207046/
12. Seifi S, Sohanian S, Khakbaz O, Abesi F, Aliakbarpour F, Rayani A. Ectopic Ciliated Cyst in the Mandible Secondary to Genioplasty and Lefort after Two Years: A Case Report and Literature Review [Internet]. Iran. J. Otorhinolaryngol. Mashhad University of Medical Sciences; 2016. Available from: /pmc/articles/PMC5045706/?report=abstract
13. Thio D, De S, Phelps PD, Bath AP. Maxillary sinus mucocele presenting as a late complication of a maxillary advancement procedure. J Laryngol Otol [Internet]. J Laryngol Otol; 2003 [cited 2020 Jul 21];117:402–3. Available from: https://pubmed.ncbi.nlm.nih.gov/12803793/
14. Lee JH, Huh KH, Yi WJ, Heo MS, Lee SS, Choi SC. Bilateral postoperative maxillary cysts after orthognathic surgery: A case report. Imaging Sci Dent [Internet]. Korean Academy of Oral and Maxillofacial Radiology; 2014 [cited 2020 Jul 2];44:321–4. Available from: /pmc/articles/PMC4245475/?report=abstract
15. Koutlas IG, Gillum RB, Harris MW, Brown BA. Surgical (implantation) cyst of the mandible with ciliated respiratory epithelial lining: A case report. J Oral Maxillofac Surg [Internet]. W.B. Saunders; 2002 [cited 2020 Jul 21];60:324–5. Available from: https://pubmed.ncbi.nlm.nih.gov/11887151/
16. Higuchi Y, Nakamura H, Kondo H, Takahashi S, Kawasaki M. Clinical study of post-operative maxillary cysts. Nihon Bika Gakkai Kaishi (Japanese J Rhinol. 2000;39:345–51.
17. Anastassov GE, Lee H. Respiratory mucocele formation after augmentation genioplasty with nasal osteocartilaginous graft. J Oral Maxillofac Surg. United States; 1999;57:1263–5.
18. Cai M, Shen G, Lu X, Wang X. Two mandibular surgical ciliated cysts after Le Fort I osteotomy and genioplasty. Br J Oral Maxillofac Surg. Scotland; 2015;53:1040–2.
19. Imholte M, Schwartz HC. Respiratory implantation cyst of the mandible after chin augmentation: report of case. Otolaryngol Head Neck Surg. England; 2001;124:586–7.
20. Kelly JP, Malik S, Stucki-McCormick SU. Tender swelling of the chin 40 years after genioplasty. J Oral Maxillofac Surg. United States; 2000;58:203–6.
21. Lazar F, zur Hausen A, Mischkowski R, Zöller JE. Atypical cyst formation following chin augmentation using a nasal osteocartilaginous graft. J Craniomaxillofac Surg. Scotland; 2006;34:107–12.
22. Nastri AL, Hookey SR. Respiratory epithelium in a mandibular cyst after grafting of autogenous bone. Int J Oral Maxillofac Surg. Denmark; 1994;23:372–3.
23. Li C-C, Feinerman DM, MacCarthy KD, Woo S-B. Rare mandibular surgical ciliated cysts: report of two new cases. J Oral Maxillofac Surg. United States; 2014;72:1736–43.
24. Bulut AŞ, Şehlaver C, Perçin AK. Postoperative Maxillary Cyst: A Case Report. Patholog Res Int [Internet]. Hindawi Limited; 2010 [cited 2020 Jul 21];2010. Available from: /pmc/articles/PMC2989648/?report=abstract
25. Yamamoto H, Takagi M. Clinicopathologic study of the postoperative maxillary cyst. Oral Surgery, Oral Med Oral Pathol [Internet]. Oral Surg Oral Med Oral Pathol; 1986 [cited 2020 Jul 21];62:544–8. Available from: https://pubmed.ncbi.nlm.nih.gov/3466125/
26. Wright JM, Vered M. Update from the 4th Edition of the World Health Organization Classification of Head and Neck Tumours: Odontogenic and Maxillofacial Bone Tumors. Head Neck Pathol. 2017;11:68–77.
27. Chindasombatjaroen J, Uchiyama Y, Kakimoto N, Murakami S, Furukawa S, Kishino M. Postoperative maxillary cysts: Magnetic resonance imaging compared with computerized tomography. Oral Surgery, Oral Med Oral Pathol Oral Radiol Endodontology [Internet]. Oral Surg Oral Med Oral Pathol Oral Radiol Endod; 2009 [cited 2020 Jul 21];107. Available from: https://pubmed.ncbi.nlm.nih.gov/19426905/
28. Gardner DG. Pseudocysts and retention cysts of the maxillary sinus. Oral Surgery, Oral Med Oral Pathol. Mosby; 1984;58:561–7.
29. Lockhart R, Ceccaldi J, Bertrand JC. Postoperative maxillary cyst following sinus bone graft: report of a case. undefined. 2000;
30. Durr ML, Goldberg AN. Endoscopic partial medial maxillectomy with mucosal flap for maxillary sinus mucoceles. Am J Otolaryngol. United States; 2014;35:115–9.
31. Fernandes KS, Gallottini MHC, Felix VB, Santos PSS, Nunes FD. Surgical ciliated cyst of the maxilla after maxillary sinus surgery: a case report. Oral Surg [Internet]. Blackwell Publishing Ltd; 2013 [cited 2020 Jul 21];6:n/a-n/a. Available from: http://doi.wiley.com/10.1111/ors.12039
32. Leung YY, Wong WY, Cheung LK. Surgical ciliated cysts may mimic radicular cysts or residual cysts of maxilla: Report of 3 cases. J Oral Maxillofac Surg. 2012;70.
33. Niederquell B-M, Brennan PA, Dau M, Moergel M, Frerich B, Kämmerer PW. Bilateral Postoperative Cyst after Maxillary Sinus Surgery: Report of a Case and Systematic Review of the Literature. Case Rep Dent [Internet]. Hindawi Limited; 2016 [cited 2020 Jul 21];2016. Available from:

/pmc/articles/PMC4958477/?report=abstract

34. Rajkumar, Sharma S, Anuradha G, Lakshmi P. Surgical ciliated cyst of maxilla - report of a case. J Oral Maxillofac Pathol [Internet]. Medknow Publications; 2003 [cited 2020 Jul 21];7:8. Available from: http://www.jomfp.in/article.asp?issn=0973-029X;year=2003;volume=7;issue=1;spage=8;epage=10;aulast=Rajkumar
35. Marano R, Santos SE, Sawazaki R, de Moraes M. Um raro caso de cisto cirúrgico ciliado após 5 anos de extração dentária. Rev Port Estomatol Med Dent e Cir Maxilofac. 2012;53:246–51.
36. Lim D, Ngeow WC. Surgical ciliated cyst of the maxilla: A rare pathology of the maxillary sinus. Arch. Orofac. Sci. J. Sch. Dent. Sci. USM Arch Orofac Sci. 2017.
37. Hasegawa M, Kuroishikawa Y. Protrusion of Postoperative Maxillary Sinus Mucocele into the Orbit: Case Reports. Ear, Nose Throat J [Internet]. SAGE PublicationsSage CA: Los Angeles, CA; 1993 [cited 2020 Jul 21];72:752–4. Available from: http://journals.sagepub.com/doi/10.1177/014556139307201114
38. Mohri M, Nishio M, Mohri J, Shimazu K, Akane K, Asai R. Problems relating to postoperative maxillary cyst. Nippon Jibiinkoka Gakkai Kaiho [Internet]. The Oto-Rhino-Laryngological Society of Japan, Inc.; 1977 [cited 2020 Jul 21];80:326–33. Available from: http://joi.jlc.jst.go.jp/JST.Journalarchive/jibiinkoka1947/80.326?from=CrossRef
39. Maruyama M, Onodera K, Ooya K. A histopathological and lectin-histochemical study of the lining epithelium in postoperative maxillary cysts. Oral Dis [Internet]. Oral Dis; 2002 [cited 2020 Jul 21];8:241–8. Available from: https://pubmed.ncbi.nlm.nih.gov/12363108/
40. Basu MK, Rout PGJ, Rippin JW, Smith AJ. The post-operative maxillary cyst. Experience with 23 cases. Int J Oral Maxillofac Surg [Internet]. Int J Oral Maxillofac Surg; 1988 [cited 2020 Jul 21];17:282–4. Available from: https://pubmed.ncbi.nlm.nih.gov/3143772/
41. Martinelli-Kläy CP, Chatelain S, Salvado F, Lombardi T. Respiratory Epithelium Lined Cyst of the Maxilla: Differential Diagnosis. Case Rep Pathol [Internet]. 2017/09/28. Hindawi; 2017;2017:6249649. Available from: https://pubmed.ncbi.nlm.nih.gov/29093979
42. Kaneshiro S, Nakajima T, Yoshikawa Y, Iwasaki H, Tokiwa N. The postoperative maxillary cyst: report of 71 cases. J Oral Surg. United States; 1981;39:191–8.
43. Kishimoto HH, Saitoh H, Santoh E, HARADA T, OKA M, YOSHIMURA Y. A clinical study of postoperative maxillary cyst. JAPANESE J ORAL Maxillofac Surg. 1990;36:547–52.
44. Cano J, Campo J, Alobera MA, Baca R, Angel Alobera M, Baca R. Surgical ciliated cyst of the maxilla. Clinical case. Med Oral Patol Oral Cir Bucal [Internet]. Med Oral Patol Oral Cir Bucal; 2009 [cited 2020 Jul 2];14. Available from: http://www.medicinaoral.com/medoralfree01/v14i7/medoralv14i7p361.pdf
45. Pakravan A, Nafarzadeh S. Report of a case of surgical ciliated cyst in the left maxillary sinus. J Contemp Med Sci. Naba'a Al-Hayat Foundation for Medical Sciences and Health Care; 2017;3:234–6.
46. Menditti D, Laino L, Di Domenico M, Troiano G, Guglielmotti M, Sava S, et al. Cysts and pseudocysts of the oral cavity: Revision of the literature and a new proposed classification [Internet]. In Vivo (Brooklyn). International Institute of Anticancer Research; 2018 [cited 2020 Jul 2]. p. 999–1007. Available from: https://pubmed.ncbi.nlm.nih.gov/30150421/
47. El-Naggar AK. WHO classification of head and neck tumours. 4th ed. Lyon: International Agency for Research on Cancer; 2017.
48. Kaltreider SA, Dortzbach RK. Destructive Cysts of the Maxillary Sinus Affecting the Orbit. Arch Ophthalmol [Internet]. Arch Ophthalmol; 1988 [cited 2020 Jul 21];106:1398–402. Available from: https://pubmed.ncbi.nlm.nih.gov/3178550/
49. Pe MB, Sano K, Kitamura A, Inokuchi T. Computed tomography in the evaluation of postoperative maxillary cysts. J Oral Maxillofac Surg [Internet]. J Oral Maxillofac Surg; 1990 [cited 2020 Jul 21];48:679–84. Available from: https://pubmed.ncbi.nlm.nih.gov/2358943/
50. Isoda H, Takehara Y, Masui T, Seki A, Takahashi M, Kaneko M. Mri of postoperative maxillary cysts. J Comput Assist Tomogr [Internet]. J Comput Assist Tomogr; 1993 [cited 2020 Jul 21];17:572–5. Available from: https://pubmed.ncbi.nlm.nih.gov/8331228/
51. Weber R, Keerl R, Draf W. Endonasale endoskopische chirurgie kieferhohlen-mukozelen nach Caldwell-Luc-Operation. Laryngorhinootologie [Internet]. Laryngorhinootologie; 2000 [cited 2020 Jul 21];79:532–5. Available from: https://pubmed.ncbi.nlm.nih.gov/11050980/
52. Lekkas C, Smets L, Van Hoeken F. Cyst arising in a free bone graft. Eur J Plast Surg. 2001;24:195–6.
53. Bartnik W, Bartnik-Krystalska A. [Postoperative maxillary cyst]. Otolaryngol Pol = Polish Otolaryngol. Poland; 2004;58:641–3.
54. Ohba T, Yang RC, Chen CY, Uneoka M. Postoperative maxillary cysts in panoramic radiography. Dentomaxillofac Radiol [Internet]. 1978 [cited 2020 Jul 21];7:109–12. Available from: https://pubmed.ncbi.nlm.nih.gov/291558/
55. Kim JJ, Freire M, Yoon JH, Kim HK. Postoperative maxillary sinus mucocoele: risk factors for restenosis after surgery and preventive effects of mytomycin-C - PubMed. J Craniofac Surg [Internet]. J Craniofac Surg; 2013 [cited 2020 Jul 21];24:e521–3. Available from: https://pubmed.ncbi.nlm.nih.gov/24036833/
56. Moe JS, Magliocca KR, Steed MB. Early maxillary surgical ciliated cyst after Le Fort I untreated for 20 years. Oral Surg [Internet]. John Wiley & Sons, Ltd; 2013;6:224–8. Available from: https://doi.org/10.1111/ors.12038
57. An J, Zhang Y. Surgical ciliated cyst of the medial canthal region after the management of a midfacial fracture: A case report. J Craniofac Surg [Internet]. Lippincott Williams and Wilkins; 2014 [cited 2020 Jul 21];25:701–2. Available from: https://pubmed.ncbi.nlm.nih.gov/24621729/
58. Gowthamnath HV, Jesija JS, Gopal KS. Ciliated cyst of the maxilla following trauma: An unusual case report. Int J Med Dent Case Reports. Incessant Nature Science Publishers Pvt Ltd.; 2014;1:1–3.

59. Clarós P, Clarós A, Sarr M, Cardesa A. [Post operative Caldwell-Luc procedure maxillary cyst: Report of a case]. Rev Laryngol Otol Rhinol (Bord). France; 2014;135:45–7.
60. Koo Min Chee CA, Brierley DJ, Hunter KD, Pace C, McKechnie AJ. Surgical ciliated cyst of the maxilla following maxillary osteotomy: a case report. Oral Surg [Internet]. John Wiley & Sons, Ltd; 2014;7:39–41. Available from: https://doi.org/10.1111/ors.12041
61. Gonzalez LD, Guzman J. Bilateral Postoperative Maxillary Cyst: A Case Report. J Clin Case Reports. OMICS Publishing Group; 2017;07.
62. Han Y-S. Postoperative Maxillary Cyst Developing After Sinus Augmentation for Dental Implants. Implant Dent [Internet]. Ovid Technologies (Wolters Kluwer Health); 2018 [cited 2020 Jul 21];1. Available from: https://pubmed.ncbi.nlm.nih.gov/29557797/
63. Yoshikawa Y, Nakajima T, Kaneshiro S, Sakaguchi M. Effective treatment of the postoperative maxillary cyst by marsupialization. J Oral Maxillofac Surg [Internet]. J Oral Maxillofac Surg; 1982 [cited 2020 Jul 21];40:487–91. Available from: https://pubmed.ncbi.nlm.nih.gov/6953207/
64. Tanio S, Tamura T, Kasuya H, Kawasaki M, Taniguchi N, Otsuki K, et al. Surgical ciliated cyst developing after Le Fort I osteotomy: Case report and review of the literature. J Oral Maxillofac Surgery, Med Pathol [Internet]. 2019;31:410–4. Available from: http://www.sciencedirect.com/science/article/pii/S2212555819300092
65. Siwach P, Joy T, Gaikwad S, Meshram V. Postoperative maxillary cyst. Indian J. Dent. Res. Off. Publ. Indian Soc. Dent. Res. India; 2020. p. 157–9.
66. Theofilou N-E, Lombardi T, Scolozzi P. Maxillary surgical ciliated cysts following advancement Le Fort I osteotomy with concomitant autogenous bone grafting: a simple coincidence or a cause-effect relationship? J Stomatol Oral Maxillofac Surg [Internet]. 2020; Available from: http://www.sciencedirect.com/science/article/pii/S2468785520302342
67. Maeda Y, Osaki T, Yoneda K, Hirota J. Clinico-pathologic studies on post-operative maxillary cysts. Int J Oral Maxillofac Surg. Denmark; 1987;16:682–7.

Tables

le 1. Specific data of our series

Our series	Year	Country	n	Filiation		Location (side)		Location in maxilla	Previous surgery	Time after surgery (mean time after surgery (years)	Relapse
				Sex (n F)	Age	Left	Right				
Case 1 (1)	2013	Spain	3 patients (4 cysts)	1	36		1	Posterior and lateral maxilla	Le Fort I osteotomy	5	No
Case 1 (2)	2019				42	1		Posterior maxilla	Le Fort I osteotomy	12	No
Case 2	2015			1	34		1	Posterior maxilla	Le Fort I osteotomy	20	No
Case 3	2016			1	34		1	Posterior and lateral maxilla	Le Fort I osteotomy	2	No
Mean values (when applied)					34,6					9.75	

Table 2. Description of the papers

Authors	Year	Country	n	Filiation			Location (side)					Location in maxilla	Previous surgery	Time after surgery (mean time after surgery (years) (m = mean value; i = interval; when known)	Relapse
				Sex (n F)	Sex (n M)	Age / mean age (*)	Left	Right	Bilat	Midline	Unknown				
Ohba et al.[19]	1980	Japan	2	2		49,5 (*)	2					Maxillary sinus (1), posterior maxilla (1)	Maxillary radical surgery	29,5 (m)	Undescribed
Kaneshiro et al[54]	1981	Japan	71								71	Right and left maxillary sinus	Maxillary radical surgery	10-30 (i)	Undescribed
Yoshikawa et al. [42]	1982	Japan	7	4	3	46,4 (*)	1	0	1		5	Premaxila, lateral maxilla, posterior maxilla (1), posterior maxilla (2), lateral maxilla (1), maxilla (3)	Caldwell-Luc surgery (7)	14-30 (i)	No
Yamamoto et al. [63]	1986	Japan	60	30	30	39,1 (*)	23	37				Posterior and lateral maxilla	Maxillary radical surgery	18,3 (m)	Undescribed
Maeda et al[67]	1987	Japan	56								56	Right and left maxillary sinus	Antral surgery	20	Undescribed
Basu et al.[67]	1988	United Kindom	21	12	9	43,7 (*)					21	Maxilla	Caldwell-Luc surgery	20 (m)	Undescribed
Miller et al.[40]	1988	USA	1		1	21		1				Right lateral maxilla	Endodontic tooth	4	No
Kaltreider et al[15].	1988	USA	1		1	56		1				Right lateral and posterior maxilla, right orbita	Gunshot	30	Undescribed
Sugar et al.[48]	1990	United Kindom	3	1	2	36,7 (*)	3					Infraorbitary rim (1), medial canthal region (1), posterior and lateral maxilla (1)	Le Fort III (cranio-synosotosis) (1), Le Fort II naso-maxillary advancement (1), Le Fort I osteotomy (1)	4	1
Pe et al.[11]	1990	Japan	22	6	16	48,4 (*)	6	3	13			Maxillary sinus (22)	Maxillary surgical intervention (22)	25,1 (m)	Undescribed
Kishimoto et al[49]	1990	Japan	46	14	32	35	21	25				Right and left maxillary sinus	Maxillary radical surgery	20	Undescribed
Hayhurst et al.[43]	1993	USA	1		1	20					1	Hard palatal	Le Fort I osteotomy	5	No
Hasegawa et al.[4]	1993	Japan	2	1	1	55,5 (*)	2					Maxillary sinus and left orbit (2)	Caldwell-Luc surgery (2)	37	Undescribed
Isoda et al.[37]	1993	Japan	24	9	15	47,4 (*)					24	Maxilla	Maxillary surgical intervention	26 (m)	Undescribed
Nastri et al[50]	1994	Australia	1	1		33				1		Symphyseal and parasymphyseal mandible	Rhinoplasty and genioplasty	15	No
Kimizuka et al.[22]	1995	Japan	229	114	115	45,2 (*)					229	Undescribed	Undescribed	Undescribed	1
Anastassov et al[7]	1999	USA	1		1	53				1		Symphyseal and parasymphyseal mandible	Rhinoplasty and genioplasty	39	No
Lockhart et al. [17]	2000	France	1	1		41		1				Right posterior maxilla	Maxillary sinus floor augmentation	0,5	No
Weber et al. [29]	2000	Germany	3	1	2	52,3 (*)					3	Undescribed	Caldwell-luc surgery (3)	16,3 (m)	Undescribed
Kelly et al[51]	2000	USA	1		1	56				1		Symphyseal mandible	Rhinoplasty and genioplasty	40	No
Higuchi et al[20]	2000	Japan	110	52		49,5					110	Right and left maxillary sinus	Antral surgery	27,5	Yes (3 cases)
Lekkas et al.[16]	2001	The Netherlands	1		1	19					1	Premaxilla	Bone grafting for alveolar cleft	8	Undescribed
Imholte et al[52]	2001	USA	1		1	59				1		Symphyseal mandible	Septorhinoplasty and augmentation genioplasty	40	No
Koutlas et al. [15]	2002	USA	1	1		34	1					Left angle and ramus mandible	Bimaxillar orthognathic surgery	13	No
Amin et al.[9]	2003	United	1		1	32	1					Left posterior	Le Fort I	15	No

		Kindom										and lateral maxilla	osteotomy		
Rajkumar et al. [34]	2003	India	1	1		27	1					Left posterior maxilla	Tooth extraction	5	No
Thio et al.[13]	2003	United Kindom	1	1		31	1					Left maxillary sinus	Le Fort I osteotomy	15	No
Bartnik et al.[53]	2004	Poland	1								1	Posterior maxilla (side?)	Caldwell-Luc surgery	26	Undescribed
Bourgeois et al.[5]	2005	USA	1	1		27					1	Premaxilla	Le Fort I osteotomy	4	No
Nishioka et al.[6]	2005	Japan	1141	471	670	48,5 (*)					1141	Undescribed	Antral surgery	23,3 (m)	Undescribed
Lazar et al[21]	2006	Germany	1		1	24				1		Symphyseal and parasymphyseal mandible	Rhinoplasty and genioplasty	16	No
Shakib et al.[10]	2009	United Kindom (African)	1	1		35				1		Midline of the anterior hard palate	Le Fort I osteotomy	7	No
Cano et al. [44]	2009	Spain	1	1		56		1				Right lateral maxilla	Caldwell-Luc surgery	3	No
Chindaombatjaroen et al. [27]	2009	Japan	7	4	3	62,1 (*)	1	2	4			Maxillary sinus (7)	Caldwell-luc surgery (7)	15-60 (i)	Undescribed
Bulut et al.[24]	2010	Turkey	1	1		54	1					Left maxillary sinus	Caldwell-Luc surgery	8	Undescribed
Leung et al.[32]	2012	China	3	2	1	40,7 (*)	2	1				Posterior maxila (2), lateral maxila (1)	Caldwell-Luc surgery (3)	2-27 (i)	No
Marano et al.[35]	2012	Brazil	1	1		37	1					Left lateral and posterior maxilla	Tooth extraction	5	No
Fernandes et al [31]	2013	Brazil	1		1	63		1				Right posterior maxilla	Caldwell-Luc surgery	15	No
Kim et al.[55]	2013	Korea	1		1	60		1				Right lateral and posterior maxilla	Maxillary sinus floor augmentation	11	No
Moe et al[56]	2013	USA	1		1	22		1				Right maxillary sinus	Le Fort I osteotomy	2	No
An et al[57]	2014	China	1		1	42		1				Right medial canthal region	Midfacial fracture surgery	10	No
Lee et al.[14]	2014	Korea	1	1		42			1			Left and right lateral maxilla	Bimaxillar orthognathic surgery	21	No
Gowthamnath et al. [58]	2014	India	1		1	17		1				Premaxila and right lateral maxilla	Facial trauma	2	Undescribed
Clarós et al[59]	2014	Spain	1	1		56		1				Right posterior maxilla	Caldwell-luc surgery	10	No
Koo Min Chee et al[60]	2014	United Kindom	1		1	42		1				Right maxillary sinus	Bimaxillary osteotomy	20	No
Li et al[23]	2014	USA	2		2	57 (*)		1		1		Symphyseal mandible and right ascending ramus	Le Fort I osteotomy /rhinoplasty and genioplasty	18-56 (i)	No
Durr et al[30]	2014	USA	4	3	1	52,0 (*)	1	2	1			Right and left maxillary sinus	Caldwell-Luc surgery	10-50(I)	No
Cai et al[18]	2015	China	1		1	21		1				Parasymphyseal mandible	Le Fort I osteotomy and genioplasty	2	No
Seifi et al.[12]	2016	Iran	1	1		37					1	Symphyseal and parasymphyseal mandible	Le Fort I osteotomy and genioplasty	2	Undescribed
Niederquell et al. [33]	2016	Germany	1	1		68		1				Right maxillary sinus	Caldwell-Luc surgery	55	Undescribed
Coviello et al.[8]	2017	Italy	1		1	53					1	Premaxilla	Lefort I osteotomy	12	No
Martinelli-Kläy et al.[41]	2017	Switzerland	1		1	35		1				Right posterior maxilla	No trauma, no surgery		Undescribed
Pakravan et al[45].	2017	Iran	1		1	49	1					Left lateral maxilla	Caldwell-Luc surgery	30	No
Gonzalez et al.[61]	2017	USA	1		1	56			2			Right and left maxillary sinus	Le Fort II and right mandibular body fractures	22	No
Yamamoto et al.[2]	2017	Japan	1	1		64	1					Left lateral maxilla	Maxillary sinus floor augmentation	9	No
Lim et al. [36]	2017	Malaysia	1		1	43		1				Right lateral and posterior maxilla	Caldwell-Luc surgery	30	No
Han et al. [62]	2018	Korea	1		1	63	1					Left lateral and posterior maxilla	Maxillary sinus floor augmentation	5	No

Golaszewski et al. [3]	2019	Venezuela	1	1		22	1					Premaxila, right lateral maxilla	Le Fort I osteotomy	5	No
Tanio et al[64]	2019	Japan	1		1	25		1				Right maxillary sinus	Le Fort I osteotomy	5	No
Siwach et al[65]	2020	India	1	1		65			1			Right maxillary sinus	Caldwell-Luc surgery	30	Undescribed
Theofilou et al[66]	2020	Switzerland	3	2	1	39,3 (*)		1	2			Right and left maxillary sinus	Le Fort I osteotomy	3-13 (i)	No

Table 3. Location of the cyst

Location of the cyst	n
UNDESCRIBED LOCATION	1748
No location described	1372
Unspecified location within the maxilla	48
Maxillary sinus	328
DESCRIBED LOCATION	109
Posterior and lateral maxilla	66
Posterior maxilla	11
Mandible	11
Lateral maxilla	7
Premaxilla	5
Hard palatal	2
Maxillary sinus and orbit	2
Medial canthal region	2
Infraorbitary rim	1
Posterior and lateral maxilla, orbita	1
Premaxila and lateral maxilla	1

le 4. Surgical previous procedures

Surgical previous procedures	n
GENERAL / UNDEFINED PROCEDURES	1761
Undescribed	229
Maxillary radical surgery	179
Maxillary surgical intervention	46
Antral surgery	1307
SPECIFIC PROCEDURES	96
A. Orthognathic procedures	20
Le Fort I osteotomy (OS)	13
Le Fort I osteotomy and genioplasty (OS)	3
Bimaxillar orthognathic surgery (OS)	3
Le Fort II naso-maxillary advancement (Henderson-Jackson technique) and mandible osteotomy (OS)	1
B. Non-orthognathic procedures	76
Caldwell-Luc surgery	56
Rhinoplasty and genioplasty	6
Maxillary sinus floor augmentation	4
Tooth extraction	2
Bone grafting for alveolar cleft	1
Endodontic tooth	1
Facial trauma	1
Gunshot	1
Le Fort II and right mandibular body fractures	1
Le Fort III (cranio-synostosis)	1
Midfacial fracture surgery	1
No trauma, no surgery	1

Figures

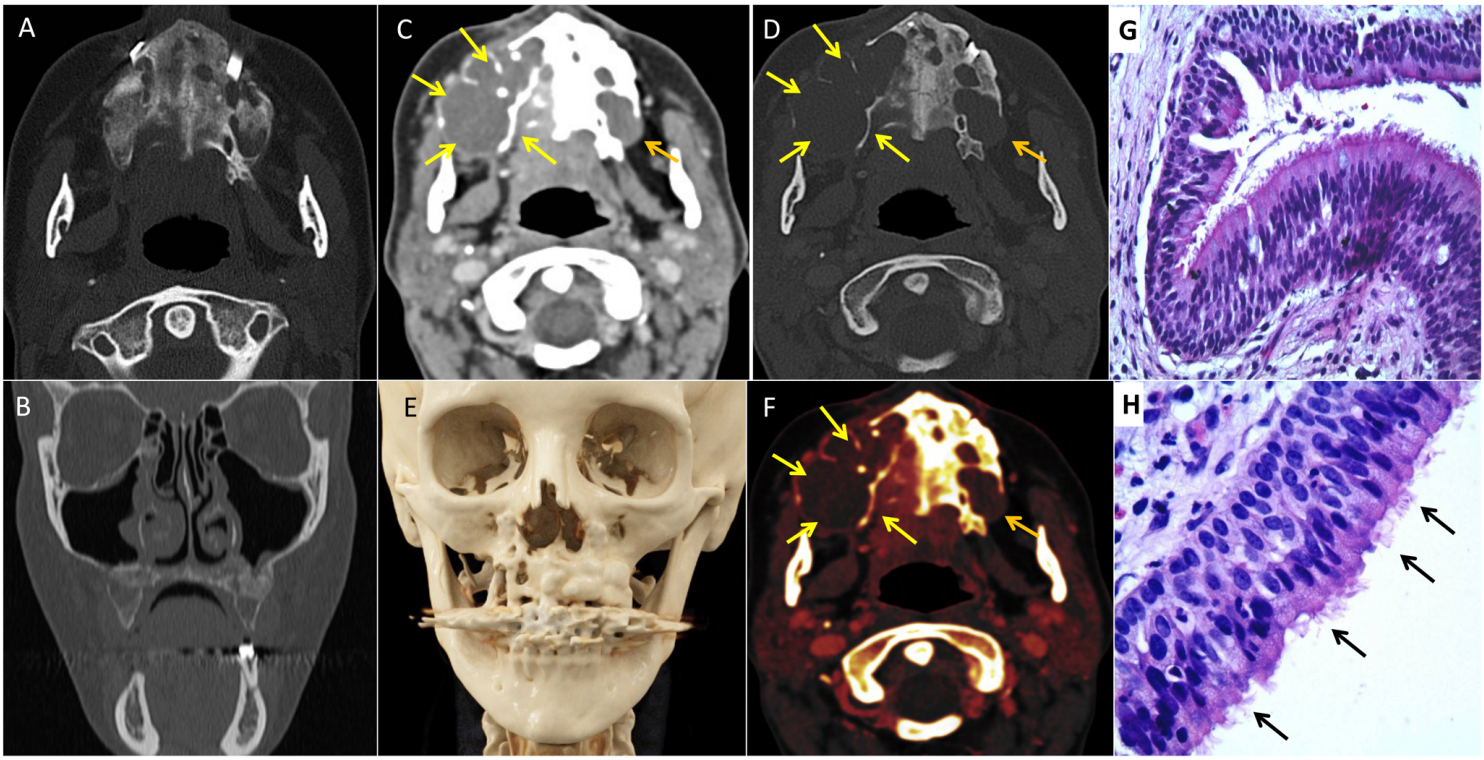

Figure 1

Images of patient 1. CT showing postsurgical changes after Le Fort type I with bone graft in the axial (A) and coronal (B) plane. 6 years later new onset bilateral lytic expansive lesions may be seen, larger on the right maxilla (yellow arrows) and smaller on the left (orange arrow) in the soft-tissue window (C) and the bone window (D) of the axial CT. 3D reconstruction (E) and Dual-energy iodine map (F) showing no enhancement inside the lytic lesions. Histological examination, HE x 20 (G) and x 63 (H), showing a cyst wall composed of fibrous connective tissue invaded by variable degree of inflammatory cell infiltrate, and lined by pseudostratified ciliated columnar epithelium. The black arrows point the cilia of the respiratory epithelium.

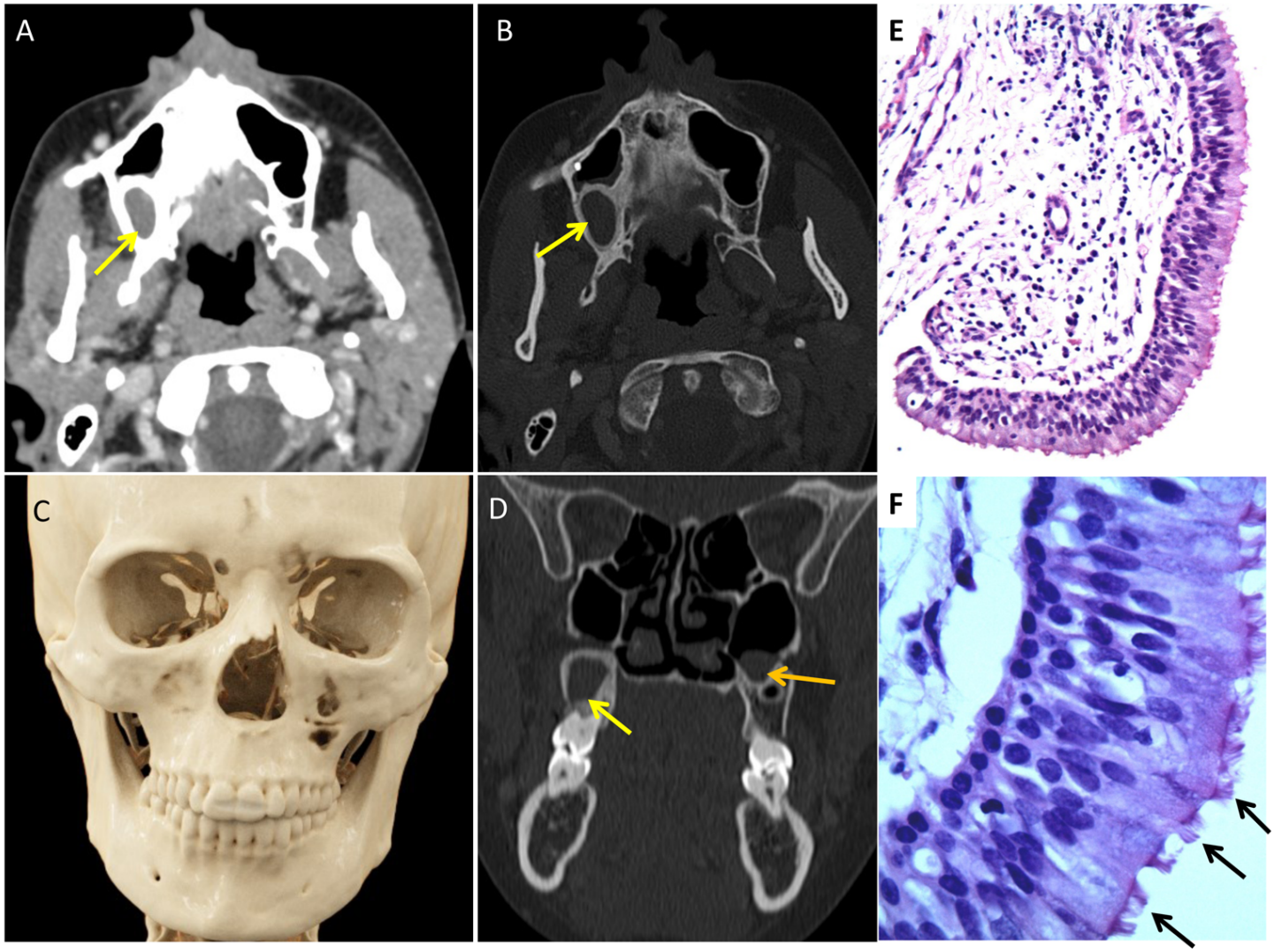

Figure 2

Images from patient 2. A. Soft-tissue and B. bone window CT in the axial plane, showing on the right side a lytic discreetly expansive lesion (yellow arrow). C. 3D reconstruction and D. Coronal plane: on the left upper maxilla a lack of continuity (orange arrow) in the surgical site after Le Fort type I is observed, and on the right maxilla new lytic discreetly expansive lesion (yellow arrow) is seen. Histopathology releaved a cyst wall with fibrous connective tissue with an inflammatory cell infiltrate, and lined by pseudostratified ciliated columnar epithelium (black arrows) (HE, E. x10, and F. x 40).

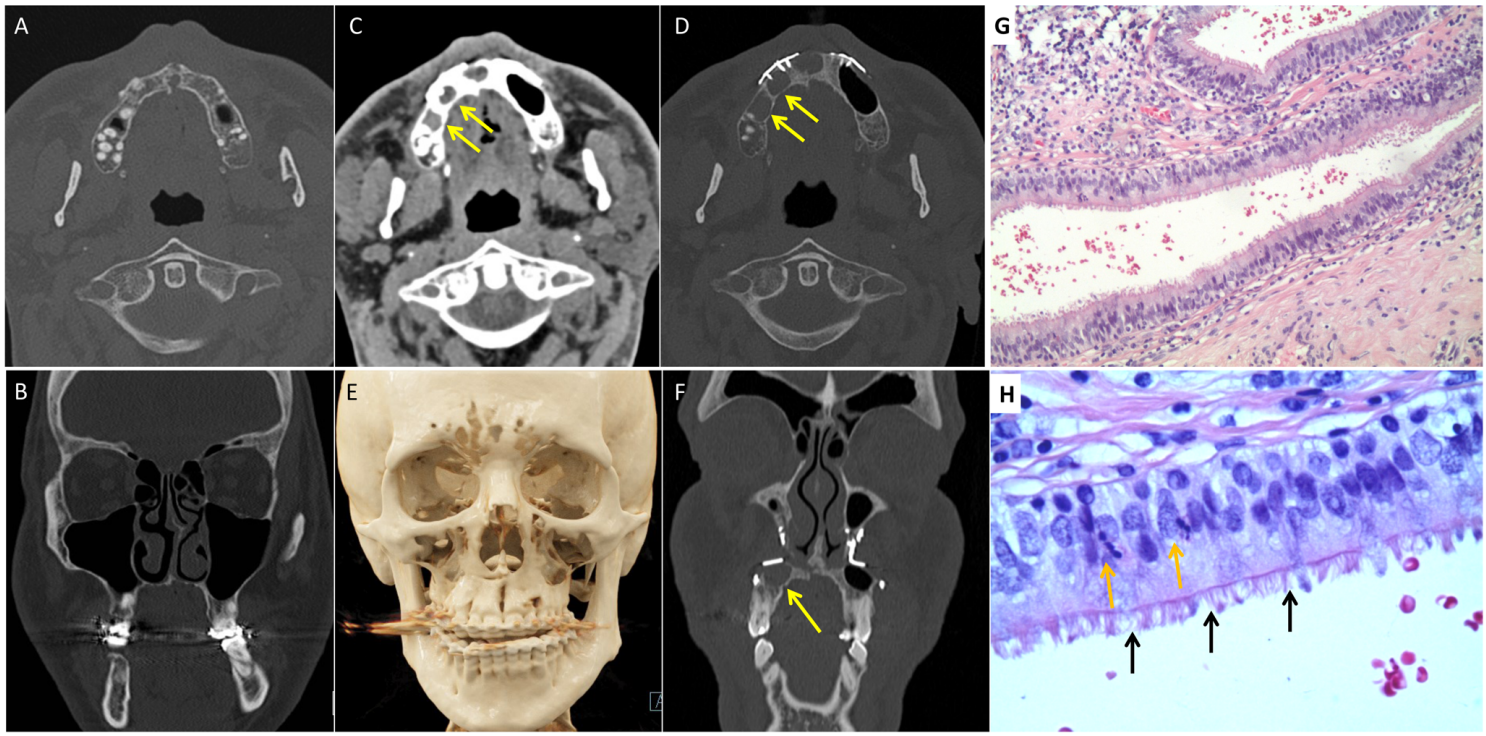

Figure 3

Images from patient 3. A. and B. Postsurgical CT after LeFort type I, where the alveolar ridge was normal. C. Soft-tissue and D. bone window CT in the axial plane performed two years later. A newly lytic lesion (yellow arrows) in the left upper maxilla is seen. E. 3D reconstruction and F. bone window CT in the coronal plane, where the yellow arrow points the lytic lesion which was not present at B. Histopathology showing a cyst wall composed of fibrous connective tissue extensively hyalinized with an inflammatory cell infiltrate, and lined by pseudostratified ciliated columnar epithelium (black arrows) with polymorphonuclear neutrophils (orange arrows). HE, G. x20, and H. x 40).