Evaluation of the Anterior Chamber Angle by Anterior Segment Optical Coherence Tomography After Implantable Phakic Contact Lens Implantation in Myopic Eyes.

Mohamed Salah El-Din Mahmoud (drmsalah1982@yahoo.com)
Faculty of Medicine, Minia University https://orcid.org/0000-0003-4537-2177

Asmaa Anwar Mohamed
Faculty of Medicine, Minia University

Hosny Ahmed Zein
Faculty of Medicine, Minia University

Research Article

Keywords: anterior chamber (AC) angle, Anterior Segment Optical Coherence Tomography (AS-OCT), Implantable Phakic Contact Lens (IPCL)

Posted Date: March 23rd, 2021

DOI: https://doi.org/10.21203/rs.3.rs-308166/v1

Version of Record: A version of this preprint was published at International Ophthalmology on March 4th, 2022. See the published version at https://doi.org/10.1007/s10792-022-02244-2.

Abstract

Purpose: To evaluate the changes in the angle of the AC and lens vault after IPCL implantation by AS-OCT in myopic patients.

Methods: A prospective observational study involving 30 myopic eyes which were implanted with IPCL with AS-OCT was used for evaluation of the anterior chamber angle parameters as anterior chamber angle (ACA), angle opening distance (AOD) and, trabecular iris space area (TISA) and lens vault at 1,3 and 6 months postoperatively.

Results: There were high significant changes between the preoperative values of ACA, AOD and, TISA and first follow-up after 1 month postoperatively with no significant changes between second and third follow-up after 3 and 6 months postoperatively. Regarding the vault, there were stable vault values with no significant changes after 6 months follow-up.

Conclusion: IPCL is a safe method of correction of myopia with stable AC angle narrowing which was monitored by the safe noncontact tool, AS-OCT.

Introduction

The phakic posterior chamber intraocular lenses (pIOLs) are used for correction of refractive errors in patients unsuitable for LASIK as with high degrees of errors of refraction with thin corneal thickness with the advantages of better contrast sensitivity and lower induction of postoperative aberrations. But have some disadvantages as potential trauma to intraocular structures and infections [1, 2].

The most commonly used pIOLs in the market are the Visian implantable Collamer lens (ICL-Staar Surgical AG, Nidau, Switzerland) and the Implantable Phakic Contact Lens (IPCL-Care group Sight Solutions, India). But the price of the ICL is about 2.5 times the IPCL which is an economic burden on the developing countries [3, 4].

The IPCL is a posterior chamber IOL designed to be implanted in the ciliary sulcus, it is foldable and injectable through a 2.8 mm corneal incision. V2.0 is the available design which has a central hole of 350 um with no need for peripheral iridectomy (PI) while the old design V1 needs PI [5].

Optical coherence tomography (OCT) was used at first to image the retina, but it was rapidly adapted to image the anterior segment and cornea (AS-OCT) [6].

Our study aims to evaluate the anterior chamber iridocorneal angle parameters and lens vault before and after IPCL implantation by AS-OCT.

Materials And Methods

A prospective, longitudinal, observational, pilot study was done in Minia University hospital from April 2019 to December 2020 on 30 myopic eyes after obtaining consent from all the participants in the study with approval of the ethical committee of faculty of medicine of Minia University. The included patients had aged more than 18 years with a degree of myopia of more than – 8 diopters (D) with astigmatism less than – 2 D with stable refraction over the past year, Anterior chamber depth (ACD) more than or equal 3 mm, corneal endothelium count more than 2500 cells/mm2 with intraocular pressure (IOP) less than 21 mmHg. Patients with ACD less than 3 mm, keratoconus, glaucoma, corneal or retinal disease and low endothelial cells count less than 2500 cells/mm2 were excluded from the study. Also, patients with diabetes mellitus (DM) and autoimmune diseases were excluded.

Preoperative evaluation

Complete ophthalmological examination including examination of the anterior segment of the eye with the slit-lamp (Sun Kingdom, China). Uncorrected (UCDVA) and best-corrected visual acuity (BCDVA) was assessed by the LogMAR chart. Tonometry with Goldmann applanation tonometer (Keeler, UK). Refraction with Nidek® auto refractometer and with retinoscopy. Endothelial cell count by specular microscopy (NIDEK, CEM-530, JAPAN), corneal topography (Oculus Pentacam, Oculus Co., Irvine, California, United States).

For calculation of the power and size of the IPCL, spherical and cylindrical errors, keratometric readings, pachymetry, ACD and, white to white diameter (WTW) were needed.

The IPCL surgery

V2.0 design was used with no need for PI. Done by the same surgeon under general anesthesia (GA), preoperatively, pupillary dilatation was done by tropicamide 1 % and phenylephrine hydrochloride 2.5%. Loading of the IPCL was done before opening the eye, the IPCL was implanted via a 2.8 mm clear temporal corneal incision after injection of viscoelastic. After implantation, the footplates were tucked under the iris. Injection of intracameral miotic then wash of viscoelastic. Finally wound hydration was done.

Postoperative treatment consisted of topical antibiotic as topical moxifloxacin and topical anti-inflammatory as prednisolone acetate 1 % in tapering doses. Topical antiglaucoma eye drops as beta-blockers were used in some cases.

AS-OCT technique:

Using RTVue XR 100 Avanti spectral domain-OCT device, version 2015 (Optovue, Inc., Fremont, California) ™.

AS-OCT was performed in dim illumination after introduction of the patient data with selection of the examination type (the enhanced anterior segment single protocol) from the machine software. The video image was centered on the limbus in the 4 quadrants (nasal, temporal, superior, inferior) and the scan head was moved towards the patient until the anterior chamber angle view became focused, the patient

was asked to look into the imaging aperture and look at the center of the blue star-shaped target and not at the moving light then images were captured by pressing the joystick or checkmark button. Firstly, the scleral spur identification, which was established as the point of change in the aqueous corneoscleral interface which appears as the sclera's inward protrusion. 3 measurements were taken from each image:

1- Anterior chamber angle (ACA) (TIA750): The trabecular-iris angle estimated at 750 µm from the scleral spur with the apex in the iris recess and the angle arms passing through a point on the trabecular meshwork and the point on the iris perpendicularly opposite.

2- Angle opening distance at 750 µm (AOD750): 750 µm from the scleral spur, the distance between the posterior corneal surface and the anterior iris surface on a line perpendicular to the trabecular meshwork.

3-Trabecular-iris space area at 750 µm (TISA): A trapezoid surface area with the following boundaries: anterior, the opening angle 750 µm away from the scleral spur; posterior, the line traced from the scleral spur perpendicular to the iris plane of the inner scleral wall; superior, the inner corneoscleral wall; and inferior, the surface of the iris.

- The vault was also manually measured by drawing a line from the middle of the IPCL's back surface and the crystalline lens's anterior surface.

Statistical analysis:

SPSS statistics software (version 20 for Windows; SPSS Inc., Chicago, IL) was used for data analysis. Number (N) and percentage (%) were used for qualitative data and mean and standard deviation (SD) were used for quantitative data. For comparison of dependent quantitative data, the dependent (paired) sample t- test was used. Probability (p) was considered significant if $p < 0.05$.

Results

-Demographic data:

30 myopic eyes were implanted with IPCL with a range of age from 22 to 32 years (16 male and 14 female).

-**Visual outcome**:

The preoperative UCDVA was 0.04 ± 0.01 which improved to 0.34 ± 0.09 after 6 months follow-up. The BCDVA was 0.36 ± 0.09 which improved to 0.32 ± 0.07 after 6 months follow-up, the refractive errors were represented in table (1).

Table (1): Visual outcome:

Variable	Preoperative	First follow-up (1 month)	Second follow-up (3 months)	Third follow-up(6 months)	P-value
UCDVA	0.04 ± 0.01	0.31 ± 0.08	0.35 ± 0.11	0.34 ± 0.09	P1:<0.001 P2: :<0.001 P3: :<0.001 P4:0.003 P5:0.010 P6:0.161
Sphere	-12.5 ± 2.8	-0.70 ± 0.24	-00.53 ± 0.08	-0.50 ± 0.14	P1: <0.001 P2: <0.001 P3: <0.001 P4:0.001 P5:0.008 P6:0.425
Cylinder	-0.82 ± 0.54	-0.48 ± 0.20	-0.44 ± 0.19	-0.51 ± 0.23	P1:0.016 P2:0.004 P3:0.015 P4:0.381 P5:0.537 P6:0.275
BCDVA	0.36 ± 0.09	0.33 ± 0.08	0.34 ± 0.09	0.32 ± 0.07	P1:0.048 P2:0.236 P3:0.058 P4:0.653 P5:0.442 P6: <0.001

-IOP:

IOP increased significantly in the First follow-up (1 month) and returned to a value near the preoperative value in the second and third follow-up. Table (2)

Table (2): IOP

	Preoperative	First follow-up (1month)	Second follow-up (3 months)	Third follow-up(6 months)	
IOP	13.47 ± 1.27	18.40 ± 1.22	15.2 ± 1.71	13.33 ± 1.76	P1: <0.001
					P2: <0.001
					P3:0.696
					P4: <0.001
					P5: <0.001
					P6: <0.001

P1: pre vs first P2: pre vs second

P3: pre vs third P4: first vs second

P5: first vs third P6: second vs third

- AC angle parameters:

1-ACA:

The preoperative values for superior (ACAS), inferior(ACAI), nasal (ACAN)and temporal(ACAT) quadrants were 43 ± 1.28, 47.6 ± 3.92, 45.6 ± 1.38 and 48.0 ± 2.11 respectively and decreased to 23.3 ± 3.3, 29.5 ± 5.09, 30.8 ± 3.7 and 30.1 ± 5.3 after 1 month which was statistically significant with no significance after 3 and 6 months. Table (3).

Table (3): ACA

Variable	Preoperative	First follow- up (1 month)	Second follow-up (3 month)	Third follow-up(6 months)	p-value
ACAS	43 ± 1.28	23.3 ± 3.3	23.4 ± 2.9	23.1 ± 3.5	P1: :<0.001 P2: :<0.001 P3: :<0.001 P4:0.671 P5:0.438 P6:0.326
ACAI	47.6 ± 3.92	29.5 ± 5.09	29.6 ± 2.4	29.2 ± 2.7	P1: :<0.001 P2: :<0.001 P3: :<0.001 P4:0.890 P5:0.781 P6:0.062
ACAN	45.6 ± 1.38	30.8 ± 3.7	29.4 ± 4.1	28.7 ± 3.9	P1: :<0.001 P2: :<0.001 P3: :<0.001 P4: :0.071 P5: :0.058 P6:0.066
ACAT	48.0 ± 2.11	30.1 ± 5.3	30.7 ± 4.1	28.7 ± 3.9	P1: :<0.001 P2: :<0.001 P3: :<0.001 P4:0.070 P5:0.537 P6:0.120

P1: pre vs first P2: pre vs second

P3: pre vs third P4: first vs second

P5: first vs third P6: second vs third

2- AOD:

The preoperative values for superior (AODS), inferior (AODI), nasal (AODN) and temporal (AODT) quadrants were 748.2 ± 41.7, 866.7 ± 48.2, 834.4 ± 23.9 and 837.7 ± 37.2 respectively and decreased to 378.6 ± 56.3, 487.2 ± 82.9, 484.4 ± 75.9 and 467.9 ± 80.4 after 1 month which was statistically significant with no significance after 3 and 6 months. Table (4)

Table (4): AOD

Variable	Preoperative	First follow up	Second follow up	Third follow-up(6 months)	p-value
AODS	748.2 ± 41.7	378.6 ± 56.3	374.5 ± 57.1	372.3 ± 64.9	P1: :<0.001 P2: :<0.001 P3: :<0.001 P4: :0.072 P5:0.067 P6:0.323
AODI	866.7 ± 48.2	487.2 ± 82.9	516.3 ± 46.6	509.8 ± 47.8	P1: :<0.001 P2: :<0.001 P3: :<0.001 P4:0.061 P5:0.054 P6:0.062
AODN	834.4 ± 23.9	484.4 ± 75.9	470 ± 77.8	468.5 ± 78.0	P1: :<0.001 P2: :<0.001 P3: :<0.001 P4:0.077 P5:0.121 P6:0.090
AODT	837.7 ± 37.2	467.9 ± 80.4	484.1 ± 59.4	477.7 ± 62.2	P1: :<0.001 P2: :<0.001 P3: :<0.001 P4:0.065 P5:0.175 P6:0.081

P1: pre vs first P2: pre vs second

P3: pre vs third P4: first vs second

P5: first vs third P6: second vs third

3- TISA:

The preoperative values for superior(TISAS), inferior(TISAI), nasal (TISAN) and temporal (TISAT) quadrants were 0.39 ± 0.04, 0.41 ± 0.04, 0.36 ± 0.01 and 0.37 ± 0.03 respectively and decreased to 0.16 ± 0.03, 0.22 ± 0.04, 0.23 ± 0.06 and 0.21 ± 0.06 after 1 month which was statistically significant with no significance after 3 and 6 months. Table (5)

Table (5): TISA

Variable	Preoperative	First follow- up (1 month)	Second follow-up(3 months)	Third follow-up(6 months)	p-value
TISAS	0.39 ± 0.04	0.16 ± 0.03	0.16 ± 0.03	0.16 ± 0.03	P1: :<0.001 P2: :<0.001 P3: :<0.001 P4:0.935 P5:0.388 P6:0.057
TISAI	0.41 ± 0.04	0.22 ± 0.04	0.23 ± 0.03	0.23 ± 0.03	P1: :<0.001 P2: :<0.001 P3: :<0.001 P4:0.056 P5:0.123 P6:0.066
TISAN	0.36 ± 0.01	0.23 ± 0.06	0.22 ± 0.06	0.22 ± 0.06	P1: :<0.001 P2: :<0.001 P3: :<0.001 P4: :0.070 P5:0.089 P6:0.695
TISAT	0.37 ± 0.03	0.21 ± 0.06	0.21 ± 0.06	0.21 ± 0.06	P1: :<0.001 P2: :<0.001 P3: :<0.001 P4: :0.073 P5: :0.059 P6:0.067

P1: pre vs first P2: pre vs second

P3: pre vs third P4: first vs second

P5: first vs third P6: second vs third

-The Vault:

The vault was 495.7 ± 68.5 um in the First follow-up (1 month) and decreased to 487 ± 66.9 after 6 months follow-up with small change in the values. Table (6) and figure (1)

Table (6): The vault:

Variable	First follow- up (1 month)	Second follow-up(3 months)	Third follow-up(6 months)	p-value
Vault	495.7 ± 68.5	489.9 ± 67.7	487 ± 66.9	P1: 0.079 P2: 0.058 P3: 0.066

P1: first vs second

P2: first vs third

P3: second vs third

Discussion

PIOLs are widely used for correction of some cases of refractive errors which are unsuitable for LASIK, The Visian implantable Collamer lens (ICL - Staar Surgical AG, Nidau, Switzerland) and Implantable Phakic Contact Lens (IPCL- Caregroup Sight Solutions, India) are the most commonly used posterior chamber pIOLS. The safety and efficacy of ICL have been demonstrated for a long time but the economic burden limits its use in some areas as developing countries [7, 8, 9].

IPCL is a good cheap alternative for the correction of errors of refractions up to -30 D while ICL up to -18 D, the initial design of IPCL was V1 which needs PI while V2.0 design has a central hole with no need for PI with reduced risk of pigment dispersion, decreased risk of pupillary block glaucoma with decreased incidence of cataract formation due to maintained aqueous current between the anterior capsule of lens and posterior surface of IPCL [5].

The most common postoperative complications of pIOLs are cataract and glaucoma [10]. So accurate IPCL size is very important which needs a proper preoperative accurate assessment of ACD, and WTW [5] .Many studies have shown that it is possible to accurately calculate the ICL size to ensure the optimum postoperative vault height (distance between ICL and crystalline lens) [11, 12]. To prevent postoperative cataracts and glaucoma, the ideal size is very critical to detect the vault and angle of the AC.

After reviewing the literature, no previous studies on the AC angle changes after IPCL by AS-OCT and this is the first study on this subject.

Angle evaluation is very important in follow-up of patients with IPCL, there are many investigations used for this evaluation as Pentacam, AS-OCT and ultrasound biomicroscopy (UBM). Our study showed that ACA, AOD and, TISA decreased significantly after 1 month of IPCL implantation and remained stable during the 6 months follow-up with no significant changes between 1, 3 and, 6 months postoperatively, this indicated significant AC angle narrowing in the first month postoperatively when compared to preoperative values and AC angle remained stable during the 6 months follow-up with no significant changes between 1, 3 and, 6 months follow-up.

The vault was measured manually as the distance between the posterior surface of the IPCL and anterior surface of the crystalline lens. Evaluation of the vault is very important as a lower vault has a major risk of cataract development and high vault is a major risk for glaucoma. 250 um to 750 um was considered as a safe vault value and the lens must be explanted when the vault close to 1000 µm [13]. In our study, the vault was 495.7 ± 68.5 in the First follow-up (1 month) and remained at similar values after 3 and 6 months and this agreed with similar studies as **Sachdev G and Ramamurthy D 2019** but they implanted IPCL V0.1 and **Bianchi GR 2019** who implanted V2.0 design [5, 14] .

IOP monitoring showed a slight increase one month postoperatively which may be caused by retained viscoelastic, postoperative inflammation and topical steroid and returned to values near the preoperative values after that. This agreed on other studies on IPCL as **Bianchi GR et al 2019** and **Bianchi GR et al 2019**[14, 15]. AS-OCT was used for angle evaluation with ICL as **Singh R et al 2020** who implanted ICL in 32 eyes with 3 months follow-up and resulted in stable angle narrowing in the follow-up period and **Gargallo-Martinez, B et al 2020** who studded vault of ICL by OCT [16, 17].

A study was done by **Wan T et al 2019** on 82 phakic myopic eyes implanted with Visian ICL and 3 instruments were used, AS-OCT, Pentacam and UBM for assessment of ACD and central vault for 3 months and showed that the measurements of AS-OCT were high while Pentacam measurements were lower than UBM[18]

Our research has some limitations, such as the limited follow-up time, the small sample size and the absence of angle assessment by other tools such as UBM and Pentacam.

Conclusion

IPCL V2.0 is a safe approach for correction of refractive errors with no need for PI provided that lens size is so accurate and AS-OCT is a safe non-contact method for AC angle and vault evaluation after IPCL implantation.

Declarations

Funding

The authors did not receive support from any organization for the submitted work.

Conflicts of Interest / Competing Interests

The authors have no funding or conflicts of interest to disclose

Availability of data and material:

Available

Ethics declarations

Conflict of interest

The authors declare that they have no conflict of interest.

Ethical standard

The study was conducted in accordance to the Declaration of the Helsinki.

Ethical approval

Approval obtained from the Clinical and Research Ethics Committee of faculty of medicine of Minia University with approval ID was 635-6/2020

Informed consent

Informed consent was obtained from all individual participants included in the study.

The authors affirm that human research participants provided informed consent for publication of the figures of AS-OCT of their eyes.

References

1. **Coskunseven E, Kavadarli I, Sahin O, Kayhan B, Pallikaris I (2017).** Refractive outcomes of 20 eyes undergoing ICL implantation for correction of hyperopic astigmatism. J Refract Surg. 33(9):604–609.
2. **Nakamura T, Isogai N, Kojima T, Yoshida Y, Sugiyama Y (2019).** Posterior chamber phakic intraocular lens implantation for the correction of myopia and astigmatism: a retrospective 10 year follow-up study. Am J Ophthalmol ;206:1–10.
3. **Sachdev GS, Singh S, Ramamurthy S, Rajpal N, Dandapani R (2019)** Comparative analysis of clinical outcomes between two types of posterior chamber phakic intraocular lenses for correction of myopia and myopic astigmatism. Indian J Ophthalmol; 67:1061–65.
4. **Vasavada V, Srivastava S, Vasavada SA, Sudhalkar A, Vasavada AR, Vasavada VA (2018).** Safety and efficacy of a new phakic posterior chamber IOL for correction of myopia: 3 years of follow-up. J Refract Surg.;34: 817–23.

5. **Sachdev G, Ramamurthy D (2019)**. Long–term safety of posterior chamber implantable phakic contact lens for the correction of myopia. Clin Ophthalmol;13:137–142.
6. **Grewal DS, Tanna AP (2013)**. Diagnosis of glaucoma and detection of glaucoma progression using spectral domain optical coherence tomography. *Curr Opin Ophthalmol*; 24: 150–161.
7. **Singh R, Vanathi M, Kishore A, Tandon R, Singh D (2020).** An anterior segment optical coherence tomography study of the anterior chamber angle after implantable collamer lens-V4c implantation in Asian Indian Eyes. Indian J Ophthalmol;68:1418-23
8. **Kamiya K, Shimizu K, Igarashi A, Hikita F, Komatsu M (2009).** Four-year follow-up of posterior chamber phakic intraocularlens implantation for moderate to high myopia. Arch Ophthalmol;127:845-50.
9. **Packer M (2018).** The Implantable Collamer Lens with a central port: Review of the literature. Clin Ophthalmol;12:2427-38.
10. **Fernandes P, González-Méijome JM, Madrid-Costa D, Ferrer-Blasco T, Jorge J, Montés-Micó R (2011).** Implantable collamer posterior chamber intra-ocular lenses: a review of potential complications. J Refract Surg.;27(10):765–776
11. **Nakamura T, Isogai N, Kojima T, Yoshida Y, Sugiyama Y (2018).** Implantable Collamer lens sizing method based on swept-source anterior segment optical coherence tomography. Am J Ophthalmol;187 : 99–107.
12. **Igarashi A, Shimizu K, Kato S, Kamiya K (2019).** Predictability of the vault after posterior chamber phakic intraocular lens implantation using anterior segment optical coherence tomography. J Cataract Refract Surg; 45: 1099–1104.
13. **Perez-Cambrodi RJ, Pinero DP, Ferrer-Blasco T, Cervino A, Brautaset R (2013).** The posterior chamber phakic refractive lens (PRL): a review. Eye (Lond).;27(1):14–21
14. **Bianchi GR (2019)** Initial Results From a New Model of Posterior Chamber Implantable Phakic Contact Lens: IPCL V2.0. Med Hypothesis Discov Innov Ophthalmol ;8(2):57-63.
15. **Bianchi GR (2020).** Presbyopia management with diffractive phakic posterior chamber IOL.Cesk Slov Oftalmol. Winter;76(5):211-219.
16. **Singh R, Vanathi M, Kishore A, Tandon R, Singh D (2020).** An anterior segment optical coherence tomography study of the anterior chamber angle after implantable collamer lens-V4c implantation in Asian Indian Eyes. Indian J Ophthalmol;68:1418-23
17. **Gargallo-Martinez, B., Garcia-Medina, J.J., Rubio-Velazquez, E. et al. (2020)** Vault changes after cyclopentolate instillation in eyes with posterior chamber phakic intraocular lens. Sci Rep; 10, 9646.
18. **Wan, T., Yin, H., Yang, Y. et al (2019)** Comparative study of anterior segment measurements using 3 different instruments in myopic patients after ICL implantation. BMC Ophthalmol;19, 182.

Figures

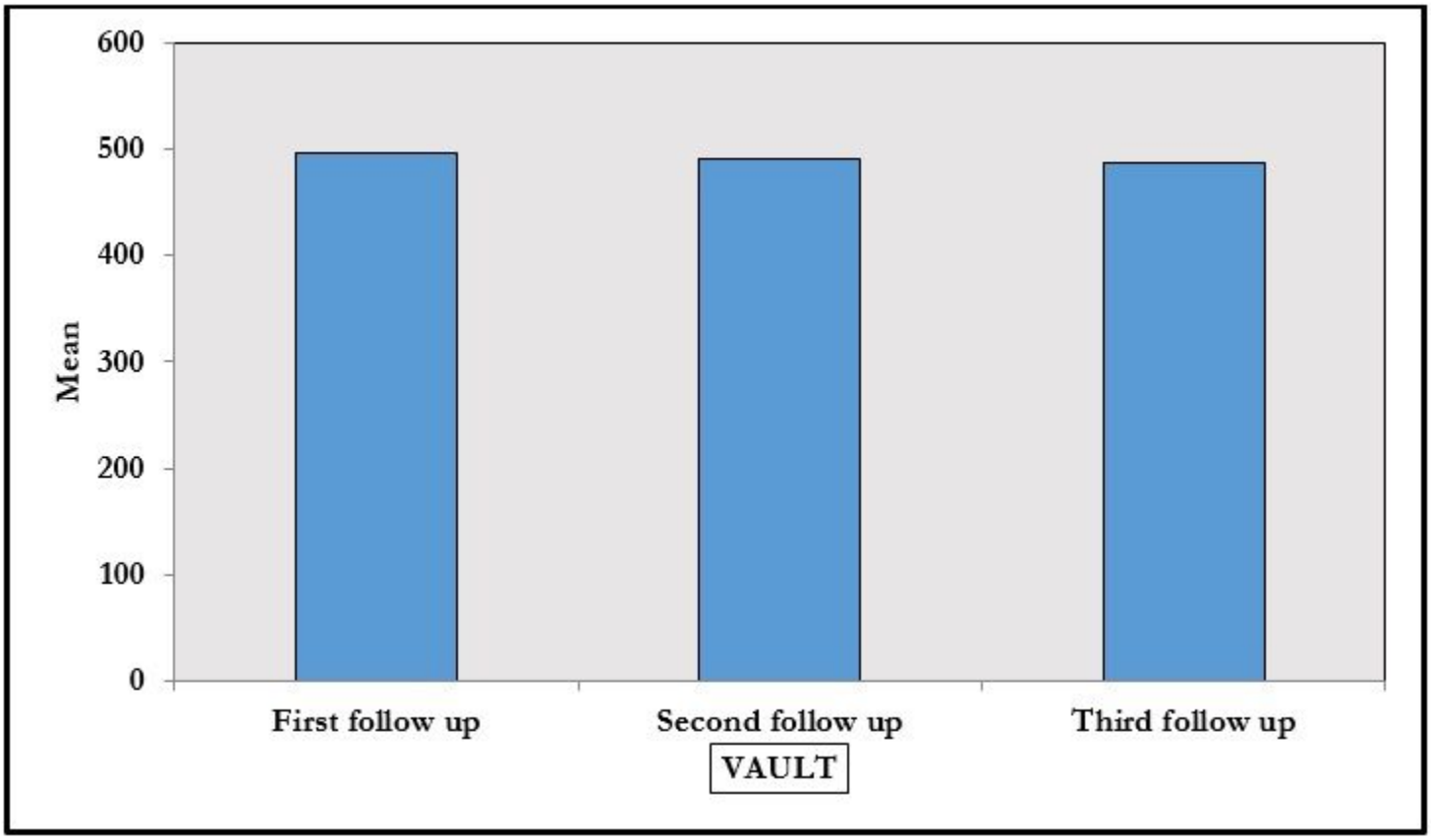

Figure 1

The vault changes during the follow-up period with stable vault values.

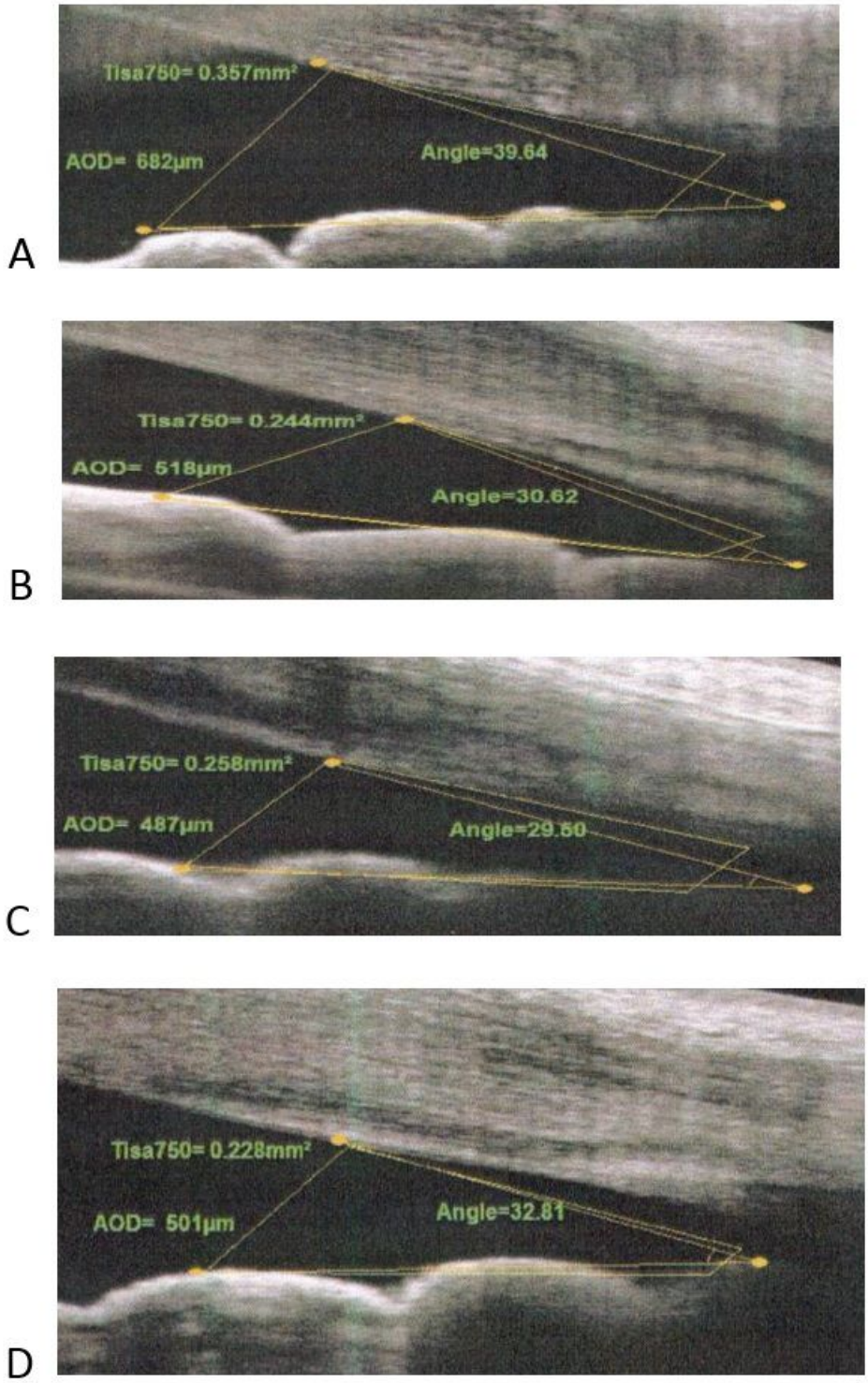

Figure 2

AS-OCT image of the AC angle showing the ACA, AOD and TISA. (A): preoperatively, (B): After 1 month, (C): After 3 months and (D): After 6 months.