# Balloon tamponade sequentially combined with TIPS for refractory acute variceal bleeding: efficacy, safety and procedure techniques

**Chongtu Yang**
Wuhan Union Hospital
**Jiacheng Liu**
Wuhan Union Hospital
**Chen Zhou**
Wuhan Union Hospital
**Jingqiang Ma**
Wuhan Union Hospital
**Songlin Song**
Wuhan Union Hospital
**Kun Qian**
Wuhan Union Hospital
**Bin Xiong** ( herr_xiong@126.com )
Wuhan Union Hospital https://orcid.org/0000-0002-7795-7041

---

**Research article**

**Keywords:** Hypertension, portal, Portosystemic shunt, transjugular intrahepatic, Esophageal and Gastric Varices, Hemorrhage, Embolization, Therapeutic

**Posted Date:** June 9th, 2020

**DOI:** https://doi.org/10.21203/rs.3.rs-31067/v1



---

**Version of Record:** A version of this preprint was published at Chinese Journal of Academic Radiology on March 11th, 2021. See the published version at https://doi.org/10.1007/s42058-021-00062-6.

## Abstract

# Background

This study aimed to evaluate the efficacy and safety of a therapeutic strategy, balloon tamponade (BT) sequentially combined with transjugular intrahepatic portosystemic shunt (TIPS), in cirrhotic patients with refractory acute variceal bleeding (AVB), and to introduce technique points of performing TIPS under BT.

# Methods

Fifteen consecutive patients with refractory AVB who had been treated with balloon tamponade sequentially combined with TIPS between February 2017 and November 2019 were retrospectively analyzed. We evaluated the technical success rate, efficacy and procedure-related complications, and compared pre- and post-TIPS portal pressure gradient (PPG). Variceal rebleeding, overt hepatic encephalopathy (OHE), TIPS patency was assessed periodically and survival at 6 weeks and 1 year were recorded during follow-up.

# Results

The procedure was successfully performed in all patients. Balloon was deflated during TIPS procedure in seven patients, after TIPS in three and before TIPS in five. Mean PPG decreased from 27.7 ± 4.3 mmHg to 10.7 ± 2.8 mmHg ($P < 0.001$). No TIPS- and balloon-related complications were observed. Two patients died during a median follow-up of 12 months (range 1–34 months). The 6-week and 1-year survival rate was 100% and 76% respectively. The incidence of OHE was 21% (3/14). The probability of remaining free of recurrent bleeding was 100%, and the probability of maintaining TIPS patency was 100%.

# Conclusions

Balloon tamponade sequentially combined with TIPS should be considered an effective and safe strategy for patients with refractory AVB (especially bleeding from esophageal varices). This strategy could increase bleeding control rate and reduce the incidence of procedure-related complications and rebleeding.


## Background

Acute bleeding from gastroesophageal varices, which is widely defined as the bleeding occurred within the first 5 days after admission, is a common medical emergency and causes a mortality of 12%-20%[1–3]. In addition, failure to control bleeding initially or early rebleeding is associated with a higher mortality[3–5]. Therefore, the primary goal is to control bleeding promptly and effectively. Combination of

blood volume resuscitation, prophylactic antibiotics, administration of vasoactive drugs and endoscopic therapy is the recommended standard treatment for AVB[1, 2, 6]. However, there are still 10%-20% of patients presenting failure to this treatment and requiring further therapy, which are called “refractory acute variceal bleeding”[2, 6, 7].

TIPS using expanded polytetrafluoroethylene (ePTFE)-covered stents has been proven highly effective in patients refractory to standard treatment[3, 5, 8]. However, considering that most medical centers cannot offer TIPS readily since it is a complicated and highly specialized procedure, and TIPS may not be feasible in patients with massive and uncontrollable bleeding, balloon tamponade is widely used as a “bridge therapy” to TIPS[2, 6, 8]. Sengstaken-Blakemore (SB) tube is the most commonly used device for BT which can provide a bleeding control rate of 90% by compressing bleeding veins directly[9–11]. But its use is accompanied by a series of severe complications such as aspiration pneumonia, necrosis of esophageal mucosal, and even worse, esophageal perforation. These complications will increase as the use prolongs[4, 12, 13]. Besides, about half of patients will rebleed after balloon deflation[4]. Therefore, BT is used only as a temporary treatment for refractory or massive AVB until TIPS is feasible[2, 3, 8].

SB tube has been used for nearly 70 years, but the data on combined therapy using SB tube and TIPS were limited. In order to control hemorrhage more effectively and to reduce procedure-related complications, we used the strategy of balloon tamponade sequentially combined with TIPS treatment, that was to control bleeding by SB tube at first for patients failed standard therapy or patients with massive bleeding that endoscopic therapy was not available, then performing TIPS as a definitive therapy to prevent rebleeding as soon as hemodynamic stabilization was achieved. Here, we aimed to evaluate the efficacy and safety of this strategy for refractory AVB, and introduce technical points of performing TIPS under BT.

# Methods

### Study design

The present observational, single-center study was conducted at Wuhan Union Hospital (an academic center which can provide emergency TIPS 24h a day). The study protocol was complied with the principles of the Declaration of Helsinki and was approved by the institutional ethics committee. Written informed consent was waived due to the retrospective nature of the study. The Strengthening the Reporting of Observational Studies in Epidemiology (STROBE) were applied for the study design[14].

### Participants

Between February 2017 and November 2019, all patients admitted for acute variceal bleeding and treated with balloon tamponade sequentially combined with TIPS at our center were screened retrospectively. Inclusion criteria were: (1) liver cirrhosis that has been diagnosed through typical images or biopsy; (2) the presence of gastroesophageal variceal bleeding related to portal hypertension; (3) pharmacological therapy (vasoactive drugs + prophylactic antibiotics) has been initially performed; (4) no history of BT

treatment. The strategy was indicated to control bleeding when: (1) active bleeding episodes were not controlled by medical and endoscopic therapy; (2) massive bleeding making visualization of the bleeding vessels impossible or causing marked hemodynamic instability despite rapid blood resuscitation, which made endoscopic therapy not feasible; (3) severe rebleeding was not controlled by two attempts at endoscopic hemostasis. All patients were managed according to the Baveno Ⅵ recommendations.

Acute variceal bleeding was suspected when patients had clinical presentations (including hematemesis and melena), and was confirmed by diagnostic endoscopy based on an observation of one of the following: (a) acute bleeding from a varix; (b) a “white nipple” or clots overlying a varix; (c) varices without other potential source of bleeding[6]. Failure to control bleeding and rebleeding was defined on the basis of the Baveno criteria[2,15]. Hepatic encephalopathy was subdivided into five grades according to current guidelines, and only grade Ⅱ-Ⅳ(overt HE) was considered for the study[16].

## Procedure

### *Sengstaken-Blakemore tube*

The SB tube placement was performed by professional physicians as previously described[9-11,17]. The gastric balloon was inflated with 150-200mL of air after inserting into the stomach, and pulled up to the gastroesophageal junction and fixed under slight traction. The esophageal balloon was inflated with 60-100mL of air according to patient’s tolerance, and should be deflated every 8-12h. Close attention was paid to patients after balloon insertion.

### *Transjugular intrahepatic portosystemic shunt*

TIPS procedure was conducted by at least two experienced interventional radiologists working together. The catheterization of the right or middle hepatic vein was performed through the right internal jugular vein with a transjugular liver access set (RUPS-100; Cook Inc.). Then the TIPS needle was used to puncture the right or left portal vein under fluoroscopic guidance. Once access was successfully achieved, a hydrophilic guidewire (Terumo, Tokyo, Japan) was advanced gradually to the main portal vein, splenic vein, or superior mesenteric vein, then balloon can be deflated so that contrast medium can be observed in the varices under portal venography. Selective embolization of varices was performed with coils and/or cyanoacrylate. Afterwards, a 6-8mm balloon was used to dilate the tract and a bare metal stent (Bard E-LUMINEXX, Vascular Stent, Karlsruhe, Germany) combined with an 8-mm expanded PTFE-covered stent (Fluency; Bard Inc.) was deployed between the hepatic vein and the portal vein. PPG was measured before and after the shunt established(Fig.1). After the operation, patients were hospitalized to receive further treatment, including liver protection, anticoagulation therapy and strategy to prevent against HE.

## Follow-up protocol

Follow-up was scheduled for all patients at 1,3,6,12 and 24 months after TIPS procedure, and was done by outpatient visit supplemented by telephone contact. Protocol of the follow-up included: (1) laboratory

examination used to detect liver and kidney function; (2) abdominal ultrasound or CT scans used to evaluate TIPS patency, ascites and portal thrombosis; (3) recurrence of variceal bleeding, OHE, TIPS- and balloon-related complications and survival at 6 weeks and 1 year were recorded. Patients were followed until death, liver transplantation, a maximum of 2 years of follow-up or until the end of this study (November 2019), and data were censored at the end of follow-up.

### Statistical analysis

Quantitative variables were expressed by means ± standard deviation or median (range), and qualitative variables were expressed by number (percentage). Pre- and post-TIPS PPG and laboratory parameters were analyzed by a paired sample t test. A P value of less than 0.05 was considered statistically significant. Statistical analyses were processed using SPSS (version 25.0).

## Results

### Study population

Fifteen consecutive patients who met the inclusion criteria were enrolled in this study with an age of 54±9 years (range 43-75 years). Preoperative Child-Pugh classifications were A in 1 patient (7%), B in 10 patients (72%) and C in 3 patients (21%), and Patient 13 was too emergent to receive serological test. The mean MELD score and MELD-Na score before TIPS was 12.6±3.8 and 15.0±5.9 respectively. Seven patients were classified as esophageal varices (EV) while the other eight patients were gastroesophageal varices (GOV1). Table 1 demonstrates the baseline characteristics of the study population.

### Treatments

TIPS was performed successfully in all fifteen patients with a success rate of 100%, and it was conducted within 24h from admission in seven patients (47%). Balloon was deflated during TIPS procedure in seven patients (47%), after TIPS in three patients (20%) and before TIPS in five patients (33%). Among the patients whose balloon was deflated before TIPS procedure, two of them rebled after deflation and underwent a second BT attempt until TIPS was performed. Seven patients underwent variceal embolization (47%). Pre-TIPS PPG was 27.7±4.3mmHg and post-TIPS PPG decreased to 10.7±2.8mmHg. Mean post-TIPS PPG was significantly lower than pre-TIPS PPG (P<0.001). All patients had mild to massive ascites before TIPS but ascites was diagnosed only in three patients. No major TIPS-related complications (e.g. intraperitoneal hemorrhage, infection) and balloon-related complications (e.g. necrosis of mucosal, esophageal perforation) were observed. Table 2 demonstrates the main laboratory parameters, Child-Pugh scores, MELD and MELD-Na scores before TIPS and 3 days after TIPS.

### Rebleeding, OHE and shunt dysfunction

During a median follow-up of 12 months (range 1-34 months), Patient 6 was lost after discharge, while other patients have complete follow-up records. Variceal rebleeding was not observed in all patients during follow-up. Post-TIPS OHE was observed in three patients (patient 4,5,9) and was successfully

managed in patient 4 and 9 with conservative treatment, which had not recurred until the end of follow-up. Patient 5 experienced recurrent OHE precipitated by high-protein diets and recovered after medical treatment including lactulose and L-ornithine L-aspartate (LOLA). TIPS patency was maintained in all patients without developing shunt dysfunction.

### Survival

Two patients died during follow-up. Patient 2 died of massive arterial gastrointestinal hemorrhage secondary to a gall bladder lithotripsy 8 months after TIPS placement, patient 5 died of ventricular fibrillation 10 months after TIPS placement. The survival rate of 6 weeks and 1 year was 100% and 76% respectively. Table 3 demonstrates the results of treatment and details of follow-up.

## Discussion

Management of acute variceal bleeding with standard treatment is effective in most patients. However, treatment of refractory AVB still remains a challenge. According to Baveno Ⅵ conference, e-PTFE covered TIPS must be considered in patients presenting failure to control bleeding despite combined medical and endoscopic therapy, and balloon tamponade should be used temporarily until TIPS can be performed[2]. Thus, balloon tamponade sequentially combined with TIPS is a feasible strategy theoretically. However, there are few data in the literature on the safety and efficacy of this therapeutic strategy. Escorsell et al.[4] have performed TIPS as a definitive treatment to prevent rebleeding after BT in part of their patients, but nearly half of their patients received TIPS as a rescue therapy when BT failed. Also, their research mainly focused on the comparison between esophageal stent versus BT and did not report this strategy in detail.

Our research was intentionally designed to evaluate the strategy of balloon tamponade sequentially combined with TIPS. The success rate of TIPS procedure reached to 100% without developing procedure-related complications, and all patients remained free of recurrent bleeding during follow-up. These results were relatively better than previous studies [5, 18, 19]. This improvement may be attributed to the following reasons. Firstly, compared with performing TIPS only, BT can control gastroesophageal variceal bleeding rapidly and effectively, which allows to correct hemodynamic instability or other concomitant diseases so that patients are in better conditions to receive TIPS. Previous researches have demonstrated that for high-risk patients, failure of initial treatment will lead to further deterioration in liver function, which is the predictor of poor outcomes, and may also preclude the use of TIPS[5, 18–20]. Therefore, this strategy may improve technical success rate and decrease the risk of poor prognosis because of the stable conditions for TIPS placement provided by BT. Secondly, compared with using BT to control hemorrhage only, this strategy can shorten the compression time due to the early use of TIPS, which in turn reduces the incidence of balloon-related complications. Meanwhile, the long-term hemostasis effect of TIPS is superior to BT and even endoscopic therapy [5, 21, 22], so the incidence of rebleeding was lower than that of using balloon only. In a study involving patients with AVB who received BT for 24 h, complications occurred in 30% of patients[11]. Similarly, another study involving patients treated with BT for 48 h, the incidence of complications was 33% and the rebleeding rate was 58%[23]. In our study,

except Patient 11 who received BT for a total of 65 h had vomiting occasionally, other patients with an average compression time of 15 h (range:4.5–43 h), which was lower than that of aforementioned studies, did not develop balloon-related complications. Thus, it indicates that balloon tamponade sequentially combined with emergency TIPS can reduce the incidence of variceal rebleeding and balloon-related complications.

Balloon was deflated during TIPS procedure in seven patients in this study. Different from standard TIPS procedure, balloon was deflated once access to the portal vein was achieved, then we performed portal venography to determine whether to embolize varices depending on their numbers and sizes under DSA and the severity of portal hypertension. Afterwards, a standard TIPS procedure was performed. This modified TIPS procedure has two advantages. Firstly, once the portal vein is accessed, embolization can be conducted promptly even if bleeding restarts after balloon deflation, which in turn increases the safety of TIPS procedure and has a better hemostasis effect than deflating balloon before TIPS. Secondly, the compression time can be further shortened on the basis of deflating balloon after finishing TIPS and a lower risk of complications may be achieved. Thus, our findings suggest that balloon deflation during TIPS is superior to balloon deflation before and after TIPS. It should be pointed out that balloon must be deflated before portography, otherwise contrast medium may not be observed in the varices (Fig. 2).

Hepatic encephalopathy is one of the most severe complications after TIPS placement, which is related to the severity of liver insufficiency and shunt diameter[16, 24, 25]. OHE is the decompensated phase of HE and the 1-year cumulative incidence after TIPS ranges from 10–50% [16, 26]. Our incidence of OHE after TIPS was 21%, which was similar to previous researches[16, 26]. According to current guidelines, no definitive prophylactic therapy is recommended to prevent against post-TIPS HE[16]. Therefore, controlling precipitating factors of HE and treating episodes of OHE actively is of vital importance. 3 patients had a total of 7 episodes of OHE in our study, which were mainly precipitated by high-protein diet. This case highlights the importance of education about strict protein nutrition intake for patients (especially for patients with poor compliance) receiving TIPS placement. Shunt dysfunction was defined as the portocaval gradient ≥ 12 mmHg or a stent lumen stenosis ≥ 50%[27] after TIPS placement. No patients experienced shunt dysfunction during follow-up and the rate of maintaining shunt patency was better than that in previous studies[27, 28].

Although several randomized controlled trials (RCTs) and meta-analysis have been performed, there are no universally accepted standards to date for the evaluation of survival after TIPS treatment. In our study, the 6-week survival rate was significantly higher than the strategy of inserting balloon only or performing rescue TIPS only (100% vs 57% and 64%, respectively)[13, 29, 30]. Meanwhile, the 1-year survival rate was improved compared with performing rescue TIPS only (76% vs 58%)[29], and both two deaths were neither caused by operation nor by portal hypertension-related complications. Hence, BT sequentially combined with TIPS demonstrated a beneficial effect on survival compared with using BT or rescue TIPS only, and this effect might be attribute to better control of factors leading to death, including failure to control bleeding, recurrent rebleeding and severe procedure-related complications. However, no firm conclusions can be drawn because of the small number of patients receiving this strategy.

Recent researches report a self-expandable esophageal metal stent might be an alternative to BT in managing refractory AVB because of its higher effectiveness and less adverse events[4, 13]. However, esophageal stent has some drawbacks such as a greater cost and sophisticated procedure of deployment and retrieval, and mortality still remains high despite combining with definitive treatment to prevent rebleeding (non-selective beta-blockers + EVL)[4]. In addition, a higher bleeding control rate and fewer complications was achieved by combining BT and TIPS in our study. Since esophageal stent can be maintained for over a week, it may have a higher value in medical centers which could not provide emergency TIPS. But for centers that are able to provide TIPS readily, we favor use of balloon tamponade combined with TIPS for refractory AVB.

This study has some limitations that should be considered. Firstly, the hemostatic effect of SB tube on esophageal varices is better than on gastric varices (Linton-Nachlas tube or endoscopic therapy with tissue adhesive is preferred)[17], and the type of varices were mainly EV and GOV Ⅱ in our research. Thus, whether our strategy equally benefits GOV Ⅱ and IGV patients has not been confirmed. Secondly, two cases rebled after balloon deflation among the patients deflating balloon before TIPS procedure, and received a second BT until TIPS was conducted. Thereby we believe the strategy of deflating balloon during TIPS may prevent failure to control bleeding and achieve better results in these cases. Finally, our research had a small number of study populations and a relatively short follow-up period, and was conducted as a retrospective study. Therefore, further researches, especially RCTs including a larger study group and a longer follow-up period are needed.

# Conclusions

The present study has confirmed the feasibility, safety and efficacy of balloon tamponade sequentially combined with TIPS for refractory AVB. This strategy should be considered in patients with AVB (especially from esophageal varices) refractory to medical and endoscopic therapy or patients with massive bleeding that endoscopic therapy may not be feasible. Combining the advantage of short-term hemostasis by balloon tamponade and long-term hemostasis by TIPS procedure can effectively increase bleeding control rate as well as reduce the incidence of procedure-related complications and rebleeding.

# Abbreviations

AVB = acute variceal bleeding, BT = balloon tamponade, DSA = digital subtraction angiography, ePTFE = expanded polytetrafluoroethylene, EV = esophageal varices, GOV = gastroesophageal varices, MELD = Model for end-stage liver disease, OHE = overt hepatic encephalopathy, PPG = portal pressure gradient, SB = Sengstaken-Blakemore, TIPS = transjugular intrahepatic portosystemic shunt

# Declarations

### Ethics approval and consent to participate

The study protocol was complied with the principles of the Declaration of Helsinki and was approved by the institutional review board of the Union Hospital, Tongji Medical college, Huazhong University of Science and Technology. Consent to participate was waived due to the retrospective nature of the study.

## Consent for publication

Not applicable

## Availability of data and materials

The datasets used and analyzed during the current study are available from the corresponding author on reasonable request.

## Competing interests

The authors of this manuscript declare no relationships with any companies, whose products or services may be related to the subject matter of the article.

## Funding

This study has received funding by National Natural Science Foundation of China (81873917). The funder had no role in study design, data collection and analysis, decision to publish, or preparation of the manuscript.

## Authors' contributions

CT and JC designed the whole study. BX supervised the whole project. CT and CZ performed data analysis. SL and KQ supervised patient diagnosis and treatment. CT drafted the manuscript. JC and JQ revised the manuscript. All authors critically reviewed the article and approved the final manuscript.

## Acknowledgements

Not applicable

# References


1. (2018) EASL Clinical Practice Guidelines for the management of patients with decompensated cirrhosis. J Hepatol 69:406–460.
2. de Franchis R, Baveno VIF. Expanding consensus in portal hypertension: Report of the Baveno VI Consensus Workshop: Stratifying risk and individualizing care for portal hypertension. J Hepatol. 2015;63:743–52.
3. Hernandez-Gea V, Berbel C, Baiges A, Garcia-Pagan JC. Acute variceal bleeding: risk stratification and management (including TIPS). Hepatol Int. 2018;12:81–90.
4. Escorsell A, Pavel O, Cardenas A, et al. Esophageal balloon tamponade versus esophageal stent in controlling acute refractory variceal bleeding: A multicenter randomized, controlled trial. Hepatology. 2016;63:1957–67.
5. Garcia-Pagan JC, Caca K, Bureau C, et al. Early use of TIPS in patients with cirrhosis and variceal bleeding. N Engl J Med. 2010;362:2370–9.
6. Garcia-Tsao G, Sanyal AJ, Grace ND, Carey W, Practice Guidelines Committee of the American Association for the Study of Liver D, Practice Parameters Committee of the American College of G. Prevention and management of gastroesophageal varices and variceal hemorrhage in cirrhosis. Hepatology. 2007;46:922–38.
7. D'Amico M, Berzigotti A, Garcia-Pagan JC. Refractory acute variceal bleeding: what to do next? Clin Liver Dis. 2010;14:297–305.
8. Dworzynski K, Pollit V, Kelsey A, Higgins B, Palmer K, Guideline Development G. Management of acute upper gastrointestinal bleeding: summary of NICE guidance. BMJ. 2012;344:e3412.
9. Mitchell K, Silk DB, Williams R. Prospective comparison of two Sengstaken tubes in the management of patients with variceal haemorrhage. Gut. 1980;21:570–3.
10. Paquet KJ, Feussner H. Endoscopic sclerosis and esophageal balloon tamponade in acute hemorrhage from esophagogastric varices: a prospective controlled randomized trial. Hepatology. 1985;5:580–3.
11. Teres J, Planas R, Panes J, et al. Vasopressin/nitroglycerin infusion vs. esophageal tamponade in the treatment of acute variceal bleeding: a randomized controlled trial. Hepatology. 1990;11:964–8.
12. Nadler J, Stankovic N, Uber A, et al. Outcomes in variceal hemorrhage following the use of a balloon tamponade device. Am J Emerg Med. 2017;35:1500–2.
13. Rodrigues SG, Cardenas A, Escorsell A, Bosch J. Balloon Tamponade and Esophageal Stenting for Esophageal Variceal Bleeding in Cirrhosis: A Systematic Review and Meta-analysis. Semin Liver Dis. 2019;39:178–94.
14. von Elm E, Altman DG, Egger M, Pocock SJ, Gotzsche PC, Vandenbroucke JP. The Strengthening the Reporting of Observational Studies in Epidemiology (STROBE) statement: guidelines for reporting observational studies. PLoS Med. 2007;4:e296.

15. de Franchis R. Evolving consensus in portal hypertension. Report of the Baveno IV consensus workshop on methodology of diagnosis and therapy in portal hypertension. J Hepatol. 2005;43:167–76.
16. (2014) Hepatic encephalopathy in chronic liver disease: 2014 practice guideline by the European Association for the Study of the Liver and the American Association for the Study of Liver Diseases. J Hepatol 61:642–659.
17. Teres J, Cecilia A, Bordas JM, Rimola A, Bru C, Rodes J. Esophageal tamponade for bleeding varices. Controlled trial between the Sengstaken-Blakemore tube and the Linton-Nachlas tube. Gastroenterology. 1978;75:566–9.
18. Azoulay D, Castaing D, Majno P, et al. Salvage transjugular intrahepatic portosystemic shunt for uncontrolled variceal bleeding in patients with decompensated cirrhosis. J Hepatol. 2001;35:590–7.
19. Garcia-Pagan JC, Di Pascoli M, Caca K, et al. Use of early-TIPS for high-risk variceal bleeding: results of a post-RCT surveillance study. J Hepatol. 2013;58:45–50.
20. Liu J, Shi Q, Xiao S, et al. Using transjugular intrahepatic portosystemic shunt as the first-line therapy in secondary prophylaxis of variceal hemorrhage. J Gastroenterol Hepatol. 2019. 10.1111/jgh.14761.
21. Monescillo A, Martinez-Lagares F, Ruiz-del-Arbol L, et al. Influence of portal hypertension and its early decompression by TIPS placement on the outcome of variceal bleeding. Hepatology. 2004;40:793–801.
22. Halabi SA, Sawas T, Sadat B, et al. Early TIPS versus endoscopic therapy for secondary prophylaxis after management of acute esophageal variceal bleeding in cirrhotic patients: a meta-analysis of randomized controlled trials. J Gastroenterol Hepatol. 2016;31:1519–26.
23. Avgerinos A, Klonis C, Rekoumis G, Gouma P, Papadimitriou N, Raptis S. A prospective randomized trial comparing somatostatin, balloon tamponade and the combination of both methods in the management of acute variceal haemorrhage. J Hepatol. 1991;13:78–83.
24. Bajaj JS, Schubert CM, Heuman DM, et al. Persistence of cognitive impairment after resolution of overt hepatic encephalopathy. Gastroenterology. 2010;138:2332–40.
25. Bettinger D, Schultheiss M, Boettler T, Muljono M, Thimme R, Rossle M. Procedural and shunt-related complications and mortality of the transjugular intrahepatic portosystemic shunt (TIPSS). Aliment Pharmacol Ther. 2016;44:1051–61.
26. Nolte W, Wiltfang J, Schindler C, et al. Portosystemic hepatic encephalopathy after transjugular intrahepatic portosystemic shunt in patients with cirrhosis: clinical, laboratory, psychometric, and electroencephalographic investigations. Hepatology. 1998;28:1215–25.
27. Perarnau JM, Le Gouge A, Nicolas C, et al. Covered vs. uncovered stents for transjugular intrahepatic portosystemic shunt: a randomized controlled trial. J Hepatol. 2014;60:962–8.
28. Bureau C, Garcia Pagan JC, Layrargues GP, et al. Patency of stents covered with polytetrafluoroethylene in patients treated by transjugular intrahepatic portosystemic shunts: long-term results of a randomized multicentre study. Liver Int. 2007;27:742–7.

29. Maimone S, Saffioti F, Filomia R, et al. Predictors of Re-bleeding and Mortality Among Patients with Refractory Variceal Bleeding Undergoing Salvage Transjugular Intrahepatic Portosystemic Shunt (TIPS). Dig Dis Sci. 2019;64:1335–45.
30. Choi JY, Jo YW, Lee SS, et al. Outcomes of patients treated with Sengstaken-Blakemore tube for uncontrolled variceal hemorrhage. Korean J Intern Med. 2018;33:696–704.

# Tables

**Table 1. Clinical characteristics of the study population.**

| No. | Age^ | Clinical symptoms and signs | | Etiology of cirrhosis | Type of varices | Child-Pugh score** | MELD score# | MELD-Na score† |
|---|---|---|---|---|---|---|---|---|
| | | GI bleeding | Ascites* | | | | | |
| 1 | 65-70 | + | 2 | schistosomiasis | GOV1 | 8 | 14 | 14 |
| 2 | 70-75 | + | 1 | schistosomiasis | EV | 8 | 8 | 8 |
| 3 | 40-45 | + | 1 | HEV | GOV1 | 6 | 10 | 10 |
| 4 | 50-55 | + | 1 | HBV | EV | 7 | 9 | 9 |
| 5 | 45-50 | + | 3 | HBV | GOV1 | 10 | 21 | 18.8 |
| 6 | 45-50 | + | 1 | HBV | EV | 12 | 21 | 23 |
| 7 | 55-60 | + | 3 | HBV | EV | 9 | 14 | 14 |
| 8 | 45-50 | + | 3 | AIH | EV | 8 | 8 | 15.8 |
| 9 | 50-55 | + | 1 | HBV | GOV1 | 8 | 15 | 19.7 |
| 10 | 55-60 | + | 1 | HBV | GOV1 | 8 | 12 | 13 |
| 11 | 45-50 | + | 3 | HBV | GOV1 | 9 | 9 | 9 |
| 12 | 60-65 | + | 1 | HBV | EV | 11 | 16 | 16 |
| 13 | 45-50 | + | 1 | HBV | GOV1 | NA | NA | NA |
| 14 | 55-60 | + | 2 | schistosomiasis | EV | 7 | 13 | 13 |
| 15 | 55-60 | + | 3 | HCV | GOV1 | 9 | 11 | 30.8 |

^ Specific ages were classified into age range to anonymize identifiable information.

* Ascites score was defined on the basis of CT images (0=none, 1=mild, 2=moderate, 3=massive)

** According to the Child-Pugh classification, class A (5-6 points) indicates the least severe liver disease, class B (7-9 points) indicates the moderately severe liver disease and class C (10-15 points) the most severe liver disease.

#/† The MELD score/MELD-Na score ranges from 6-40 points and a higher score indicates more severe liver disease.

Abbreviations: No. number, NA not applicable, GI gastrointestinal, HBV hepatitis B virus, HCV hepatitis C virus, HEV hepatitis E virus, AIH autoimmune hepatitis, EV esophageal varices, GOV-Ⅱ gastroesophageal varices-Ⅱ, MELD model for end-stage liver disease

**Table 2. Laboratory parameters before and 3 days after TIPS procedure.**

| Parameters | | Before TIPS | After TIPS | P value |
|---|---|---|---|---|
| Hemoglobin (g/L) | | 85.2±12.5 | 82.4±13.6 | 0.49 |
| Platelet count (´$10^9$/L) | | 92.1±40.1 | 104±59.8 | 0.48 |
| Prothrombin time (s) | | 19.6±3.7 | 18.9±4.9 | 0.80 |
| International normalized ration | | 1.7±0.4 | 1.6±0.5 | 0.82 |
| Bilirubin (mg/dL) | | 30.3±15.7 | 30.9±17.7 | 0.89 |
| Albumin (g/L) | | 25.3±4.9 | 26.1±3.9 | 0.6 |
| Creatinine (mg/dL) | | 63.7±22.1 | 64.5±18.7 | 0.78 |
| Blood Urea Nitrogen (mmol/L) | | 8.9±4.8 | 8.0±4.9 | 0.35 |
| Sodium (mmol/L) | | 136.2±6.2 | 138.7±6.4 | 0.058 |
| Child-Pugh score | | 9.0±1.4 | 8.2±1.6 | 0.12 |
| Child-Pugh class | | | | |
| A | 1 | | | 2 |
| B | 10 | | | 12 |
| C | 3 | | | 1 |
| MELD score | | 12.6±3.8 | 13.7±3.7 | 0.82 |
| MELD-Na score | | 15.0±5.9 | 15.8±6.1 | 0.51 |

**Table 3. Results of treatment and details of follow-up.**

| No. | Compression time (h) | Complications | | Pre-/Post PPG(mmHg) | Variceal rebleeding | Shunt patency | OHE | Survival |
|---|---|---|---|---|---|---|---|---|
| | | TIPS-related | BT-related | | | | | |
| 1 | 11 | - | - | 40/14 | - | + | - | + |
| 2 | 10 | - | - | 39/13 | - | + | - | - |
| 3 | NA | - | - | 49/20 | - | + | - | + |
| 4 | 43 | - | - | 31/10 | - | + | + | + |
| 5 | 37 | - | - | 39/14 | - | + | + | - |
| 6 | NA | - | - | 26/8 | NA | NA | NA | NA |
| 7 | NA | - | - | 40/20 | - | + | - | + |
| 8 | 15 | - | - | 34/14 | - | + | - | + |
| 9 | 16 | - | - | 34/14 | - | + | + | + |
| 10 | 11 | - | - | 37/13 | - | + | - | + |
| 11 | 65 | - | - | 31/12 | - | + | - | + |
| 12 | 6 | - | - | 43/20 | - | + | - | + |
| 13 | 4.5 | - | - | 37/16 | - | + | - | + |
| 14 | 6 | - | - | 40/20 | - | + | - | + |
| 15 | 7 | - | - | 44/11 | - | + | - | + |

Abbreviations: No. number, NA not applicable, OHE overt hepatic encephalopathy, PPG portal pressure gradient

# Figures

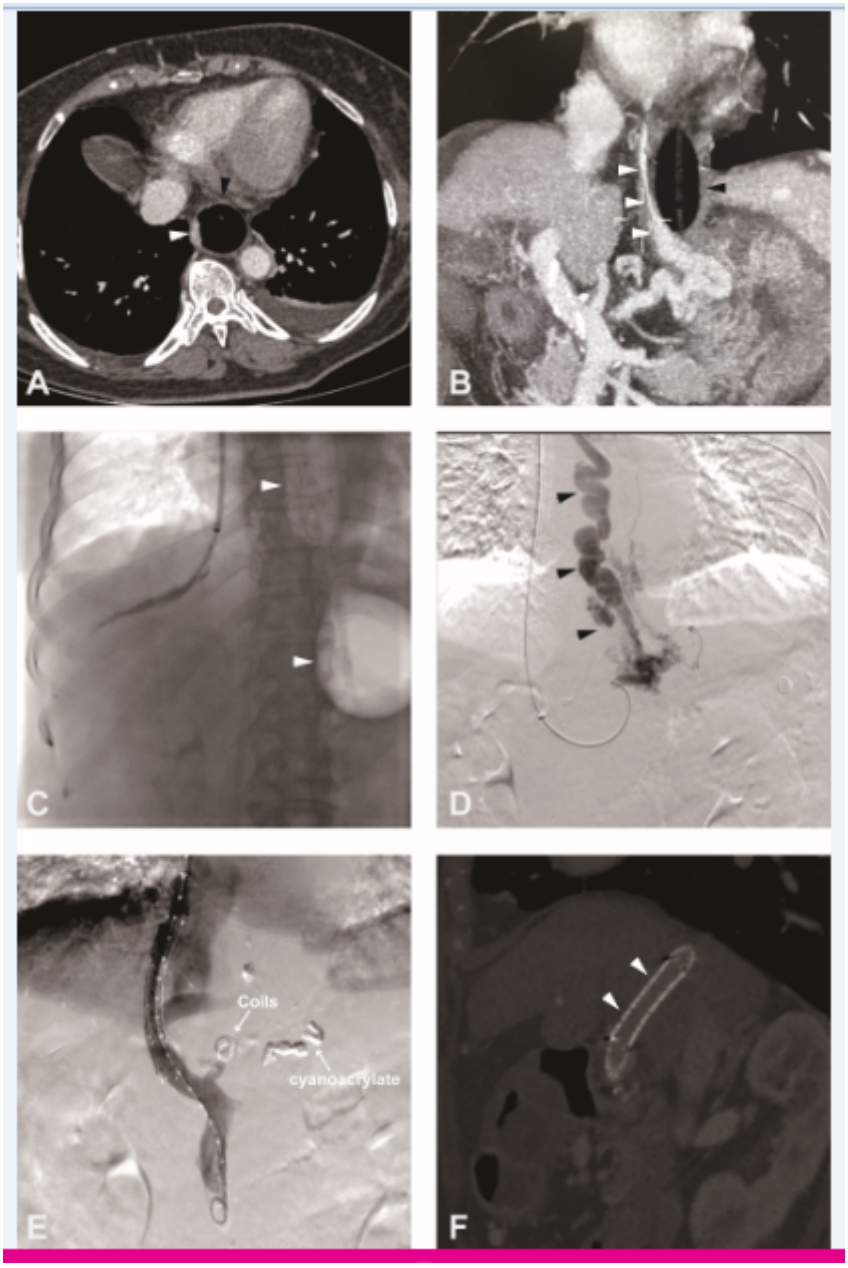


**Figure 1**

Images from a patient with Child-Pugh class B and refractory AVB. (A) and (B) Enhanced CT scans before TIPS showed the esophageal varices (white arrow) compressed by balloon (black arrow). (C) The esophageal and gastric lumen of SB tube (white arrow) under fluoroscopy. (D) After successfully puncturing to the portal vein, deflated the balloon and conducted portal venography, which showed the gastro-esophageal varices (black arrow) clearly. (E) Appropriate flow from MPV through the shunt to HV was displayed under portal venography and varices were not seen after embolization with coils and cyanoacrylate. (F) 3 months after TIPS insertion, stent patency was maintained (white arrow).

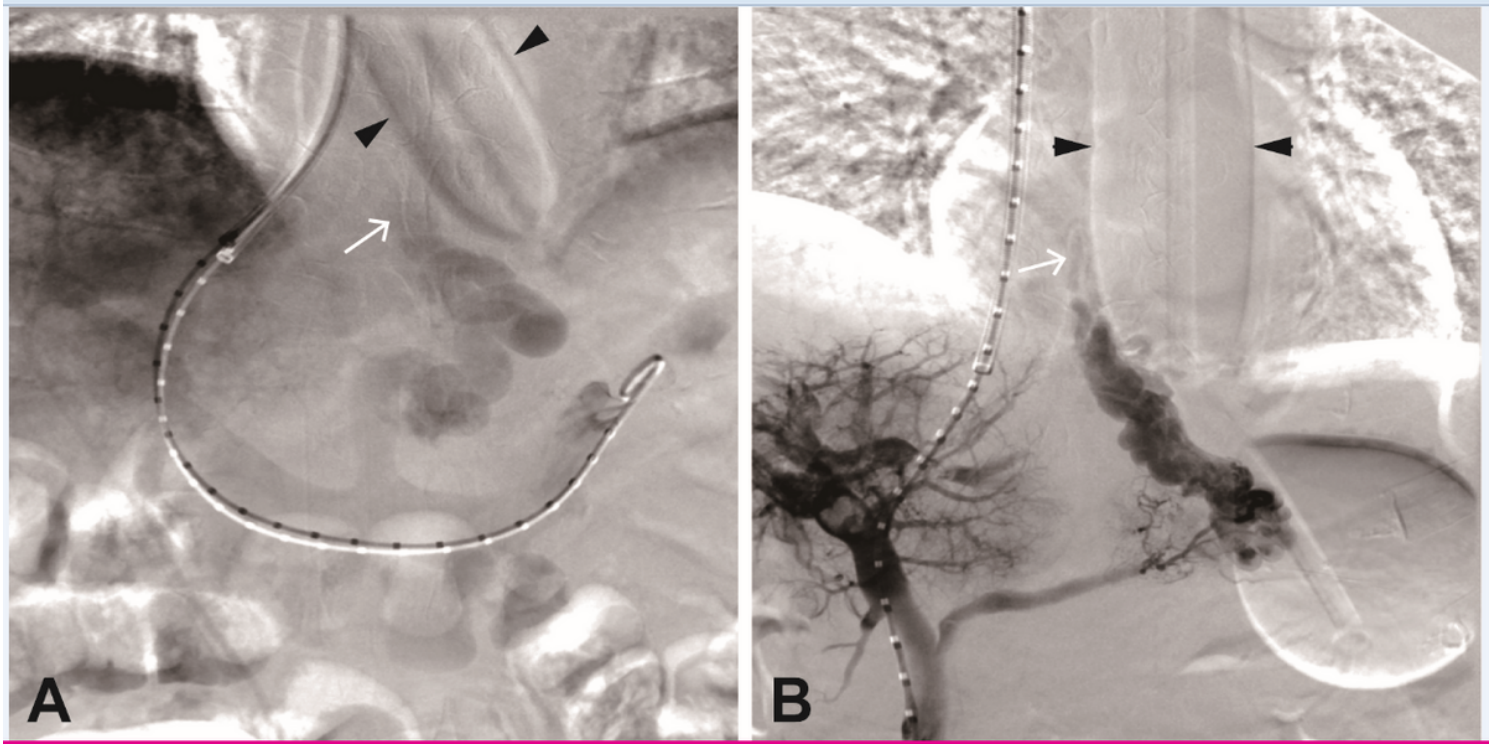


**Figure 2**

Two cases in which portography was performed before balloon deflation. Esophageal varices were compressed by esophageal lumen (black arrow) so that contrast medium could not entering into the varices (white arrow).