Semiprone Position for Posterior Approaches to Acetabular fractures Allows Intuitive Radiographic Acquisition and Versatility for Surgical Hip Dislocation: A Technical Note and Preliminary Report

Chia-Che Lee
National Taiwan University Hospital https://orcid.org/0000-0002-1616-0178
I-Hsin Chen
National Taiwan University Hospital
Tzu-Hao Tseng
National Taiwan University Hospital
Shau-Huai Fu
National Taiwan University Hospital Yun Lin Branch
Ting-Ming Wang
National Taiwan University Hospital
Wei-Hsin Lin (oweihsin@gmail.com)

Technical advance

Keywords: decubitus positioning, prone positioning, patient positions methods, posterior approaches, acetabulum fractures

Posted Date: June 1st, 2020

DOI: https://doi.org/10.21203/rs.3.rs-31107/v1

Abstract

Background

Although the pros and cons of prone and decubitus positioning methods, for posterior approaches to acetabular fractures, have been widely discussed, it remains inconclusive whether a particular patient position is superior to the other. Here we present our preliminary experience with placing the patient in the semiprone position for posterior approaches to the acetabulum as a potentially advantageous alternative.

Methods

Technical notes were provided as well as the preoperative, intraoperative and postoperative images of the demonstrative cases. From July 2018 to April 2020, eight selected patients with complex acetabular fractures were surgically treated through posterior approaches in semiprone position. Patient demographics, fracture pattern, poor prognostic factors and associated conditions were recorded. The quality of fracture reduction was assessed by Modified Matta's criteria. The operative hip's function was evaluated by the Modified Merle d'Aubigné-Postel score if follow-up was more than 3 months.

Result:

The Median age of our cohort was 48.55 years (24.3–70.6). The median body mass index was 23.90 kg/m^2 (17.6–26.4). Satisfactory reduction was achieved in 6 of the 8 patients. Intraoperative radiographs obtained by the standard vertical and horizontal projection of the C-arm machine resembled the classic Judet views. Trochanteric flip osteotomy and surgical hip dislocation were feasible. One hip was converted to total hip replacement 5 months after primary fracture surgery due to femoral head osteonecrosis.

Conclusion:

The preliminary radiographic and reduction quality of our cohort were comparable to those reported in the literature. The advantages of semiprone position include intuitive intraoperative radiographic acquisition, making gravity as a aid for reduction and feasibility of surgical hip dislocation. Long-term follow-up and further case-controlled or randomized controlled studies are necessary to uphold its value.

Background

Surgical treatment for certain types of acetabular fractures warrants posterior approaches, such as Kocher-Langenbeck approach or modified Gibson approach [1, 2]. There are pros and cons for each positioning method [3]. For lateral position, most surgeons are familiar with it and surgical hip dislocation is readily applicable. Reduction against gravity and maintenance of the reduction quality are the issues since gravity tends to cause medialization of the medial acetabular wall, or the quadrilateral plate [3, 4]. For prone position, gravity may act as an aid, instead of an obstacle, for reduction. But hip manipulation

is relatively limited and surgical hip dislocation may not be feasible. It remains inconclusive whether a particular patient position is superior to the other. The choice of the patient positioning method depends mainly on the surgeon's decision.

A well-trained technician is paramount for good intraoperative radiographic acquisition in both traditional positioning method., especially when Judet views are required. The advantage of intuitive radiographic acquisition on semiprone position was first noted by our orthopedic oncology team during surgeries involving the pelvis or acetabulum. Selected cases were put in semiprone position to facility the excision and reconstruction surgery. The intraoperative radiographs acquired from standard vertical and horizontal projections were similar to the classic Judet views [5]. We started to apply this positioning method to selected acetabular fractures from July 2018. Here we share our preliminary experiences of semiprone position as an alternative for posterior approaches, showing potential advantages.

Method

Techniques:

A. For Kocher-Langenbeck or modified Gibson approach, with or without trochanteric flip osteotomy

1. The patient is put semiprone on position bolsters or chest rolls on radiolucent table (figure 1a-c). If position changing during surgery is expected or potentially possible, a space must be left between the posterior posts and the body (figure 1b). Sterile preparation and draping must include the whole ipsilateral leg.

2. During surgery, the lower leg of the injured limb may rest on another sterile bolster and a supporting mayo stand to keep the hip in extension and knee in flexion in order to protect the sciatic nerve.

3. Here we take a case of associated posterior column and posterior wall fracture, patient number 6 in table 1, for example. The wall fragment extended supero-anteriorly (Figure 2a-d). Modified Gibson approach with trochanteric flip osteotomy was done for fracture site exposure.

4. Vertical projection of the radiation beam from C-arm machine (figure 3a) will produce iliac oblique view of Jude on the image intensifier. Figure 3b and 3c show the radiographs acquired intraoperatively during reduction process of posterior column.

5. Horizontal projection of the radiation beam will produce obturator view of Judet (figure 4a). Reduction process of the posterior wall is shown in figure 4b and 4c.

6. The final construct is shown in figure 5a-d.

B. For surgical hip dislocation

1. During positioning, a space should be left between the lower back and the posterior posts (Fig. 1b) to allow position switching between lateral decubitus and semiprone position. It should be checked before disinfection and must be interchangeable smoothly.

2. If hip reduction via surgical hip dislocation approach is planned to be done first, as in the situation of irreducible femoral head fracture-dislocation or incarcerated fragments in the hip joint, the patient is put in semiprone position first during preparation.

3. After surgical field disinfection, the posterior aspect from the back to the buttock was draped aseptically. A non-scrubbed-in assistant help to push the upper trunk and shoulder backward in cooperation with the anesthesiology team, while the scrubbed-in change the patient position to lateral decubitus. The scrubbed-in must then exchange gloves. Disinfection was applied again to previously nonsterile part and the whole surgical field. Then we continue to finish the draping. Doing it in the opposite manner, decubitus position first, is also possible and may be applied according to the surgical planning.

4. After dealing with intraarticular conditions via surgical hip dislocation, we may change the patient position to semiprone position to treat the acetabular fracture.

5. Here we show case number 7, a case of femoral head fracture and associated T-shaped acetabular fracture with irreducible hip dislocation in closed manner, for example (Fig. 6). After disinfection and draping as described, surgical hip dislocation was done first in lateral decubitus position to reduce the hip and treat the femoral head fracture. The femoral head bone loss was inevitable due to multiple comminuted non-fixable fracture fragments. We managed to reduce the fracture and shape the femoral head as spherical as possible. After completion of femoral head fixation, we change the patient position to be semiprone by pushing the back, again, in cooperation with the anesthesiology team. The T-shaped acetabular fracture was then reduced and fixed.

Table 1. Patient Characteristics and Outcome

	Age (years) & Sex	Fracture Patterns	Approach	Reduction Quality (Matta's)	Functional outcome (Modified Merle d'Aubign'e-Postel)	Associated Factors & Conditions
1	33.6 M	Both Column	AIP + LW; KL	Anatomical	Excellent	Posterior wall
2	48.6 F	ACPHT	AIP + LW; KL	Inadequate	Fair	OI; MQLP; anterior/posterior wall, transtectal comminution
3	70.2 M	Posterior wall	KL	Imperfect	Good (THR due to ONFH after 5 months)	Marginal impaction; age; hip dislocation; SEPWF
4	62.5 F	ACPHT	AIP + LW; KL	Anatomical	Good	Anterior/Posterior wall; femoral head chondral injury, MQLP, age
5	27.8 M	Posterior wall	G + TFO	Anatomical	N/A (brain injury and bedridden status)	Hip dislocation, SEPWF
6	70.6 M	Posterior column + posterior wall	G + TFO	Anatomical	Excellent	Femoral head chondral injury, MQLP, age
7	24.3 M	T-shaped	G + SHD	Anatomical	N/A (short follow-up)	Femoral head fracture-dislocation, MQLP
8	48.5 M	Transverse	G + LW	Inadequate	N/A (short follow-up)	Transtectal comminution, MQLP

The abbreviations in alphabetic order: ACPHT: anterior column posterior hemitransverse; AIP: anterior intrapelvic approach; G: modified Gibson approach; KL: Kocher-Langenbeck; LW: lateral window; MQLP: medialization of quadrilateral plate; OI: osteogenesis imperfecta; ONFH: Osteonecrosis of the femoral head; SEPWF: superiorly extended posterior wall fragment; SHD: surgical hip dislocation; TFO: trochanteric flip osteotomy;;

Facility, Patient Demographics and Preliminary Outcome Measures:

Our facility is a "Medical Center" under our health care system, as a tertiary referral hospital, certificated by Ministry of Health and Welfare, Taiwan. This retrospective study was approved by the institutional review board, named National Taiwan University Hospital (NTUH) Research Ethics Committee (REC).

Majority of the acetabular fractures warranting posterior approaches were treated by standard decubitus or prone position in our institute and the branches. From July 2018 to April 2020, posterior approaches were done in semiprone position in 8 selected patients with acetabular fractures. The fracture patterns warranted specific attentions. The characteristics of these fractures included medially displaced quadrilateral plate, femoral head fracture-dislocation, marginal impaction, posterior wall fracture extending superoanteriorly, hip dislocation and fracture comminution. Median age was 48.55 years old (24.3 – 70.6). Median BMI was 23.9 kg/ m^2 (17.6 – 26.4). C.C. Lee participating in major parts of the

surgeries of all 8 patients, in cooperation with T.H. Tseng or S.H. Fu. The patient demographics and characteristics are listed in Table 1. Matta's criteriae were applied with modification to evaluate the standard postoperative plain films for evaluation of reduction quality [6]. That is, residual gap ≤ 1 mm for anatomical reduction, 1-3 mm for imperfect reduction and > 3mm for inadequate reduction on standard AP and the Judet views [7, 8]. Poor prognostic factors, associated conditions and hip survival were recorded [7]. Modified Merle d'Aubigné-Postel score during the last follow-up was also recorded if it was more than 3 months [9].

Preliminary Results

Good intraoperative Judet views could be acquired by simple vertical and horizontal projections as demonstrated. Five out of eight patients had anatomical reduction (< 1 mm). One had imperfect (1-3mm). Two had inadequate reduction, that is, gap or step-off > 3mm according to Matta's criteria. Six of the eight cases achieved "satisfactory reduction", including the anatomical and the imperfect reduction [6, 7]. The result regarding fracture reduction is comparable to the reported literatures[7]. Three of the eight patients were treated with anterior intrapelvic approach first, which determined the major part of fracture reduction. Subsequently we put the patients in semiprone position to address the significant posterior wall fragments. Anatomical reduction was achieved in two. The other was inadequate, mainly due to the special condition of high bone mass osteogenesis imperfect and mélange of troublesome fracture patterns as listed in table 1.

Patient number 2 had intraoperative anatomical reduction, including the reduced and grafted marginal impaction by direct vision and intraoperative images. But the postoperative plain films showed suspicious re-collapsed marginal impaction, about 2 mm step-off, confirmed by follow-up computed tomography (CT). Later the patient had ipsilateral femoral head osteonecrosis and received total hip replacement 5 months after the primary fracture surgery. Patient number 5 was bedridden due to brain injury caused by the motor-vehicle accident. The follow-up for Patient number 7 and 8 was shorter than 3 months. After patient number 3, 7 and 8 were excluded, good-to-excellent outcome was achieved in 4 of 5 hips, and in 3 of 4 survived hips.

Discussion

The fracture personalities of these selected patients were knotty, while the reduction quality in our small cohort was still comparable to the reported literatures[4, 6, 7]. For surgical treatment of acetabular fractures, the quality of reduction is directly related to the outcome [7]. For certain acetabular fractures, gravity acts to medialize the medial wall of the acetabulum in decubitus position, which may cause problems during reduction [4]. If at the same time surgical hip dislocation is favored, surgeons would face a dilemma. The semiprone positioning method offers some benefits of prone position and provides the versatility for surgical hip dislocation.

There are three scenarios that we will consider putting the patient in semiprone position. First, when posterior wall fracture extends superiorly with hip subluxation, gravity will keep the femoral head anterior in the acetabular socket. Gibson approach or trochanteric flip osteotomy may be done with uncompromised anterior access. Second, when a markedly medialized quadrilateral plate warrants posterior approach for reduction, gravity will not be so much an obstacle as in decubitus position. Again, anterior access is preserved for insertion anterior column screw or interfragmentary screws. Surgical hip dislocation may also be performed if intraarticular inspection is necessary [1]. Third, when there are intraarticular acetabular fragments or Pipkin IV fractures, surgical hip dislocation in combination with Kocher-Langenbeck or Gibson approach may be done to treat both intraarticular conditions and the acetabular fracture.

Good intraoperative radiograph acquisition may further help the surgeons strive to get anatomical or satisfactory reduction. Experienced technicians or assistants are helpful in getting the Judet views when patients are put in prone or lateral position. When patients are put in semiprone position, it become intuitive to acquire intraoperative Judet views as demonstrated.

Postoperative computed tomography (CT) may be more accurate in evaluating the quality of reduction than traditional radiographs, and is associated with hip survivorship [10–12]. Verbeek et al. identified residual gap of 5 mm and step-off of 1 mm as critical cut-off, measured at the high weight bearing dome on computed tomographic images [11]. The clinical utility of postoperative CT is not yet determined and its routine use has not been justified [8, 10]. However, we do observe an increase in frequency of ordering postoperative CT in our daily practice and in the reported literatures [7, 8, 10, 12]. Only small portion of the patient will be treated differently by routine postoperative CT. Careful selection may add its value [13].

This is a small numbered retrospective study without long-term outcome. But we consider semiprone positioning method potentially advantageous and worth spreading. Long-term follow-up, as in all outcome studies for acetabular fracture surgery, is necessary. Further large scale, case-controlled or randomized controlled studies may be necessary to prove its value.

Conclusions

Semiprone position may be a viable alternative positioning method for posterior approaches to acetabular fractures. It is advantageous for intuitive intraoperative radiographic acquisition, preservation of anterior access, making gravity as an aid for fracture reduction and being versatile for surgical hip dislocation. Further studies are necessary to uphold its value.

Declarations

Ethics approval and consent to participate

The study was approved by National Taiwan University Hospital Research Ethics Committee. The study has been conducted under the Declaration of Helsinki.

Consent for Publication

Written informed consents were acquired prior to publication.

Competing Interests

The authors declare no competing interests.

Funding

Not applicable

Contributions:

Technique concept and execution: C.C. Lee, W.H. Lin, T.H. Tseng; Participation and planning for Surgery: C.C. Lee, T.H. Tseng, W.H. Lin, S.H. Fu; Data collection and evaluation: C.C. Lee, I.H. Chen, T.H. Tseng; Preparation of 3D printed model and the schematic diagram: I.H. Chen, C.C. Lee, W.H. Lin; Literature Review: C.C. Lee, S.H. Fu; Study supervision: S.H. Fu, T.M. Wang

Acknowledgement

Special thanks to **Chang, Chih-Hao, MD, PHD**, for providing the equipment and the techniques to make the 3D-printed pelvic fracture model.

Availability of data and materials

The data that support the findings of this study are available from National Taiwan University Hospital but restrictions apply to the availability of these data, which were used under license for the current study, and so are not publicly available. Data are however available from the authors upon reasonable request and with permission of National Taiwan University Hospital.

Author Information

Chia-Che Lee[1] MD, jackamades@gmail.com

Corresponding Author: Wei-Hsin Lin[1] MD,

I-Hsin Chen[1] MD**,**

Tzu-Hao Tseng[1] MD,

Shau-Huai Fu[1,2] MD,

Ting-Ming Wang[1,3] MD, PhD

Affiliations (symbolled as the upper mark after the author name)

1. **Department of Orthopedic Surgery, National Taiwan University Hospital, Taipei, Taiwan**
2. **Department of Orthopedic Surgery, National Taiwan University Hospital, Yunlin Branch, Yunlin County, Taiwan**
3. **Department of Orthopedic Surgery, College of Medicine, National Taiwan University, Taipei, Taiwan**

References

1. Siebenrock KA, Keel MJB, Tannast M, Bastian JD. Surgical Hip Dislocation for Exposure of the Posterior Column. JBJS essential surgical techniques. 2019;9(1):e2.
2. Moed BR. The modified gibson posterior surgical approach to the acetabulum. J Orthop Trauma. 2010;24(5):315–22.
3. Negrin LL, Benson CD, Seligson D. Prone or lateral? Use of the Kocher-Langenbeck approach to treat acetabular fractures. The Journal of trauma. 2010;69(1):137–41.
4. Collinge C, Archdeacon M, Sagi HC. Quality of radiographic reduction and perioperative complications for transverse acetabular fractures treated by the Kocher-Langenbeck approach: prone versus lateral position. J Orthop Trauma. 2011;25(9):538–42.
5. Monks J, Yeoman L. Judet's views of the acetabulum: a demonstration of their importance. Radiography today. 1989;55(628):18–21.
6. Matta JM. Fractures of the acetabulum: accuracy of reduction and clinical results in patients managed operatively within three weeks after the injury. The Journal of bone joint surgery American volume. 1996;78(11):1632–45.
7. Ziran N, Soles GLS, Matta JM. Outcomes after surgical treatment of acetabular fractures: a review. Patient safety in surgery. 2019;13:16.
8. DeCoster TA. **CT After ORIF of Acetabular Fractures Detects Residual Displacement Not Seen on Radiography and Correlates with Osteoarthritis Risk and THA**: **Commentary on an article by Diederik** O. Verbeek, **MD**, **et al**.: "**Postoperative CT Is Superior for Acetabular Fracture Reduction Assessment and Reliably Predicts Hip Survivorship**". *JBJS* 2017, **99**(20):1.
9. Ovre S, Sandvik L, Madsen JE, Roise O. Comparison of distribution, agreement and correlation between the original and modified Merle d'Aubigne-Postel Score and the Harris Hip Score after acetabular fracture treatment: moderate agreement, high ceiling effect and excellent correlation in 450 patients. Acta Orthop. 2005;76(6):796–802.

10. Verbeek DO, van der List JP, Villa JC, Wellman DS, Helfet DL: **Postoperative CT Is Superior for Acetabular Fracture Reduction Assessment and Reliably Predicts Hip Survivorship**. *JBJS* 2017, **99**(20):1745–1752.
11. Verbeek DO, van der List JP, Tissue CM, Helfet DL. Predictors for Long-Term Hip Survivorship Following Acetabular Fracture Surgery: Importance of Gap Compared with Step Displacement. JBJS. 2018;100(11):922–9.
12. Archdeacon MT, Dailey SK. Efficacy of Routine Postoperative CT Scan After Open Reduction and Internal Fixation of the Acetabulum. J Orthop Trauma. 2015;29(8):354–8.
13. Elnahal WA, Ward AJ, Acharya MR, Chesser TJS. Does Routine Postoperative Computerized Tomography After Acetabular Fracture Fixation Affect Management? J Orthop Trauma. 2019;33:43–8.

Figures

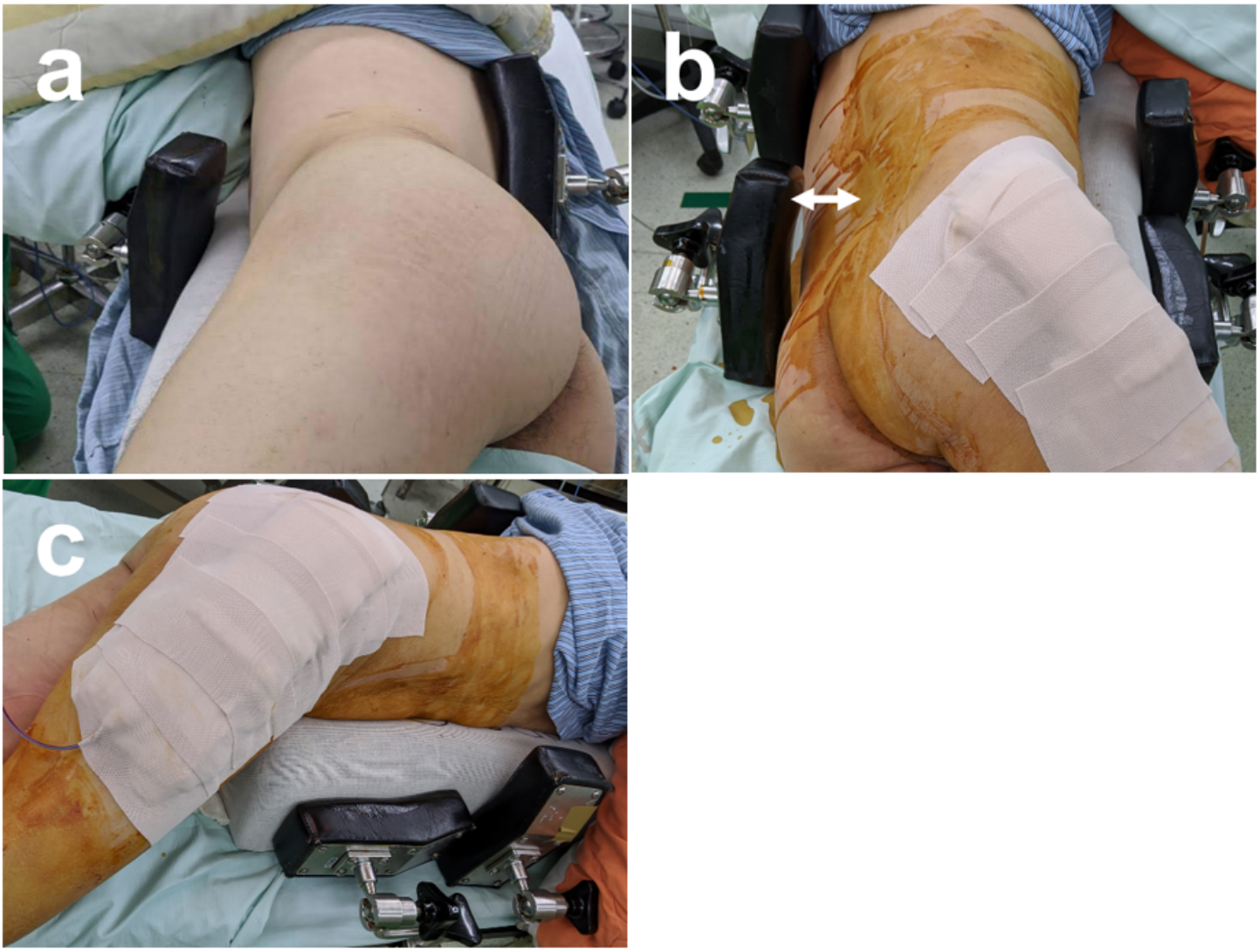

Figure 1

The Semiprone Position Fig. 1a: The posterior post left no place for position changing in this figure. It may be applied when the surgical plan rwarrants only semiprone position. Fig. 1b: There is space left between posterior posts and the lower back (double headed arrow) to allow position change. Fig. 1c: The position bolster should be firmly supported by the anterior posts to avoid slippage.

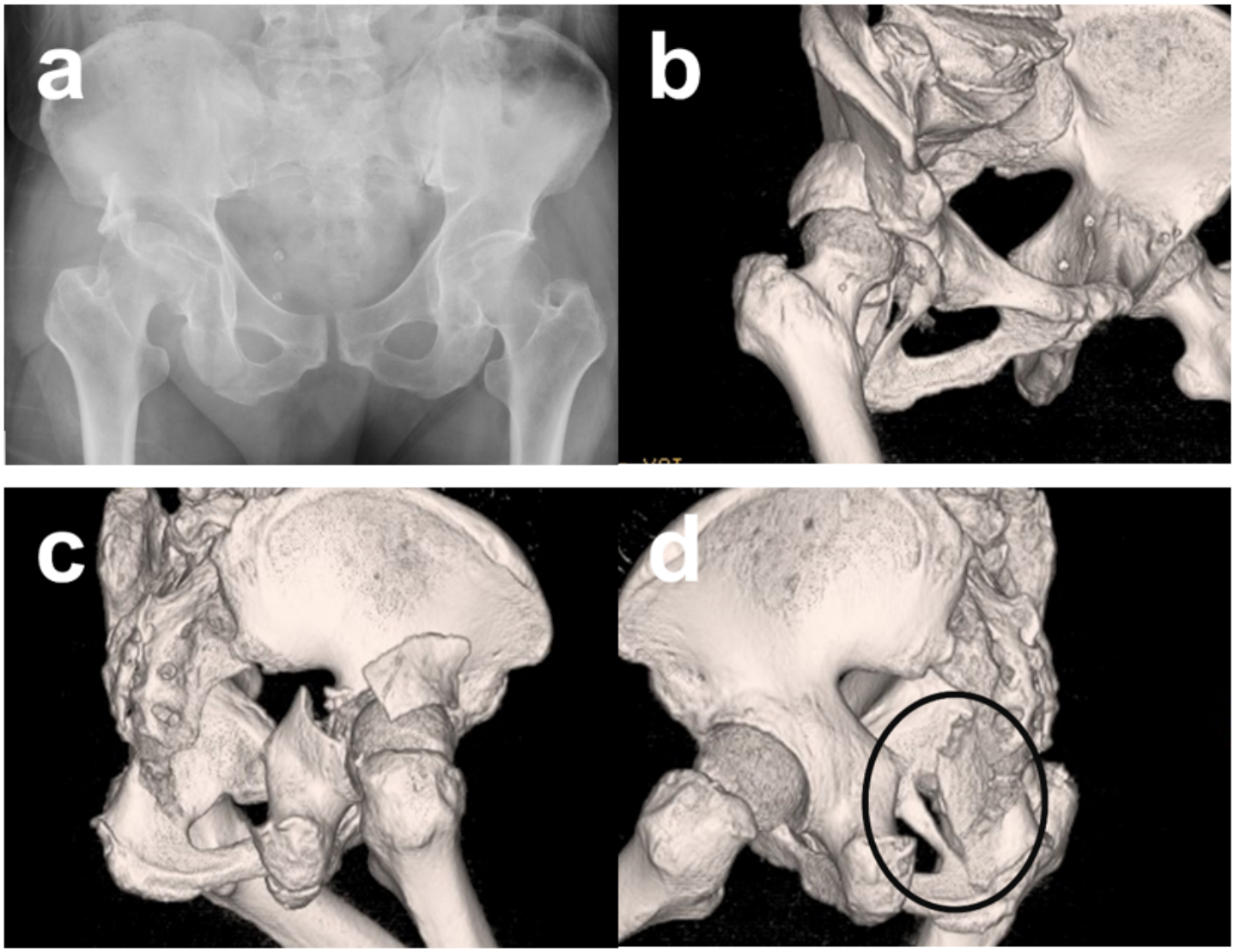

Figure 2

Preoperative Images: posterior column and posterior wall fracture Fig. 2a: Plain film, AP view of the pelvis Fig. 2b-d: Three-dimension reconstruction of computed tomographic studies, shows posterior column and posterior wall fracture extending superoanteriorly, with hip dislocation and posteromedially displaced quadrilateral plate (black circle).

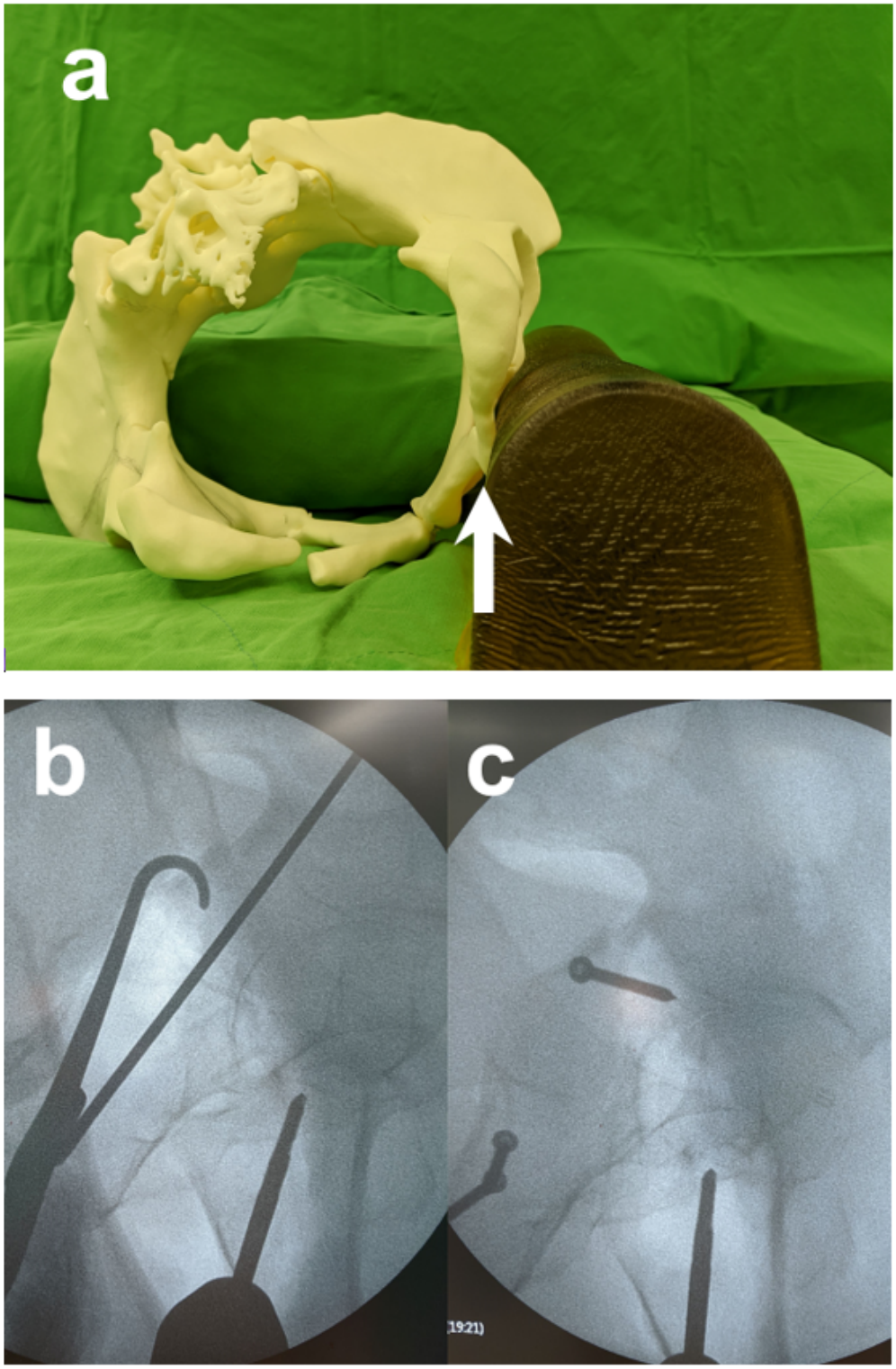

Figure 3

Intraoperative Iliac Oblique View Fig. 3a: We used a 3D-printed pelvic fracture model for demonstration of semiprone position. The white arrow represents the vertical projection of radiation beams from C-arm machine, centered on the acetabulum. Fig. 3b & c: The intraoperative images acquired on image intensifier resemble iliac oblique views of Judet. The images show the process of reduction and

preliminary fixation with lag screws and a position screw. Besides direct vision and finger palpation, the reduction quality of posterior column can be further evaluated by these images.

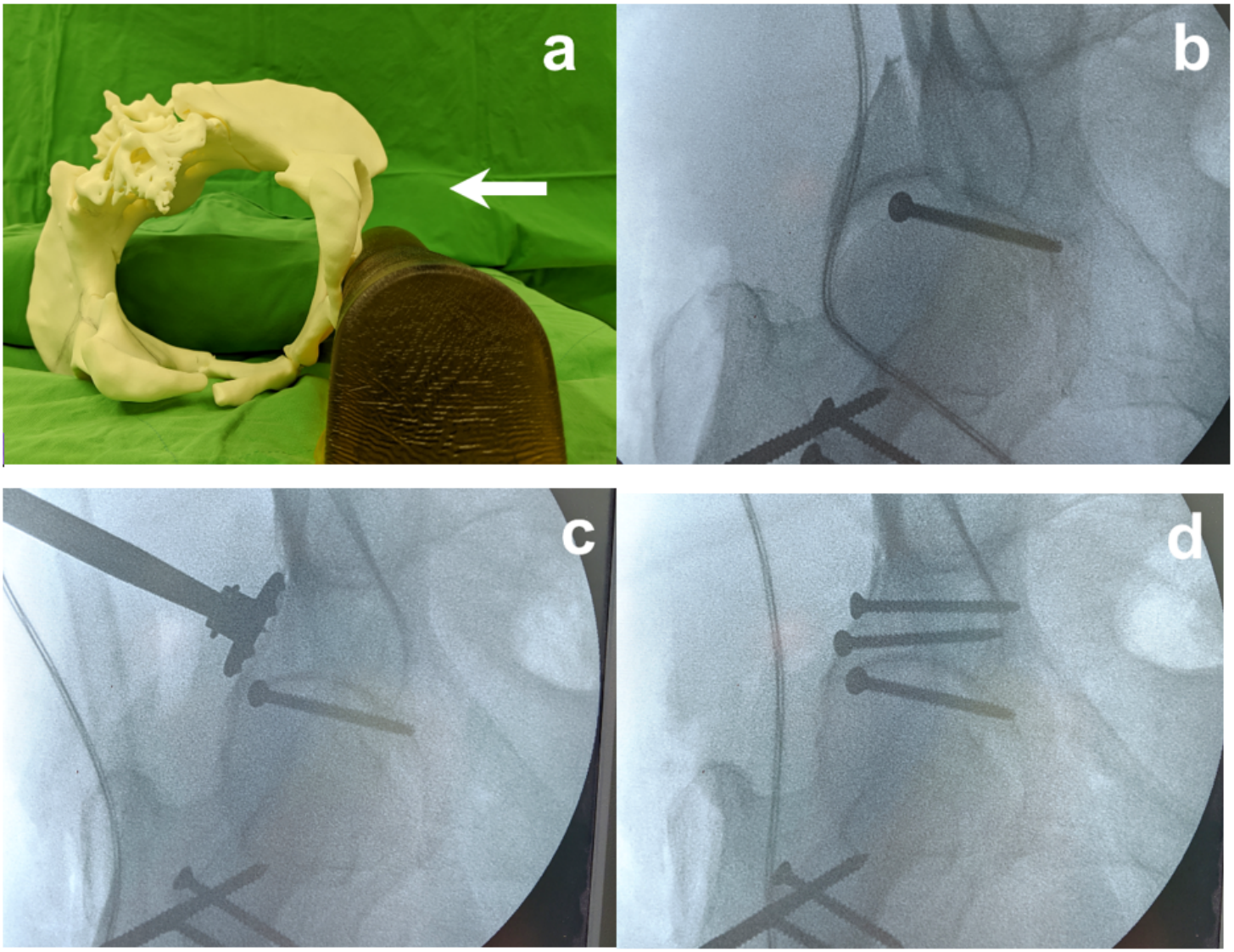

Figure 4

Intraoperative Obturator Oblique View Fig. 4a: The white arrow represents the horizontal projection of radiation beams from C-arm machine, centered on the acetabulum. Fig. 4b-d: The reduction process was recorded by the intraoperative images, resembling obturator oblique views of Judet. The posterior wall fragment was reduced and the reduction was maintained by ball spike pusher with a disc. Preliminary fixation was done via a lag screws and a position screw. Two neutralizing plates were then applied in standard manner.

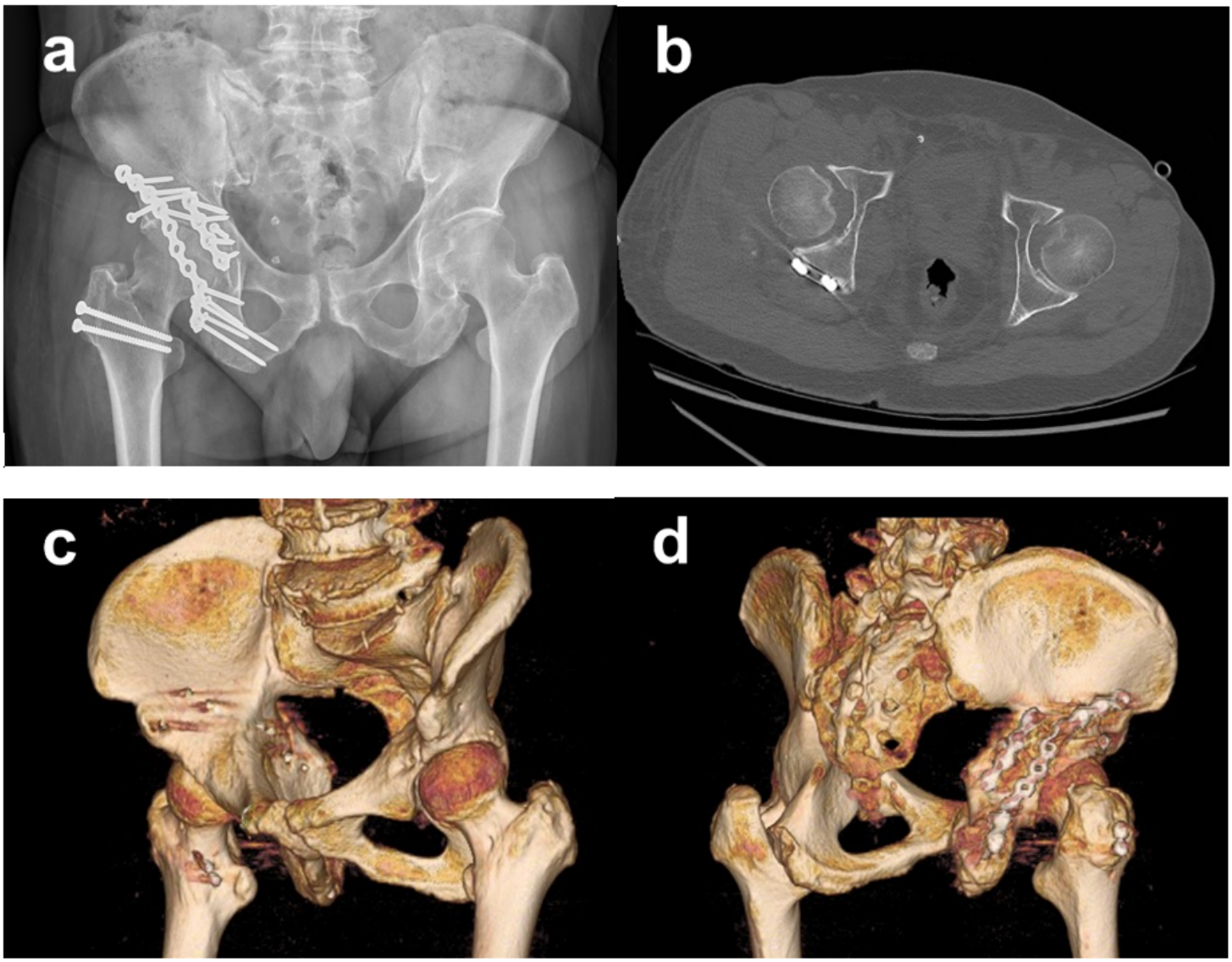

Figure 5

The Postoperative Images Fig. 5a: Plain film, AP view of pelvis Fig. 5b: Axial computed tomography (CT) showed anatomical reduction. Fig. 5c & d: The 3D reconstruction of computed tomographic studies shows the fracture reduction and the final construct.

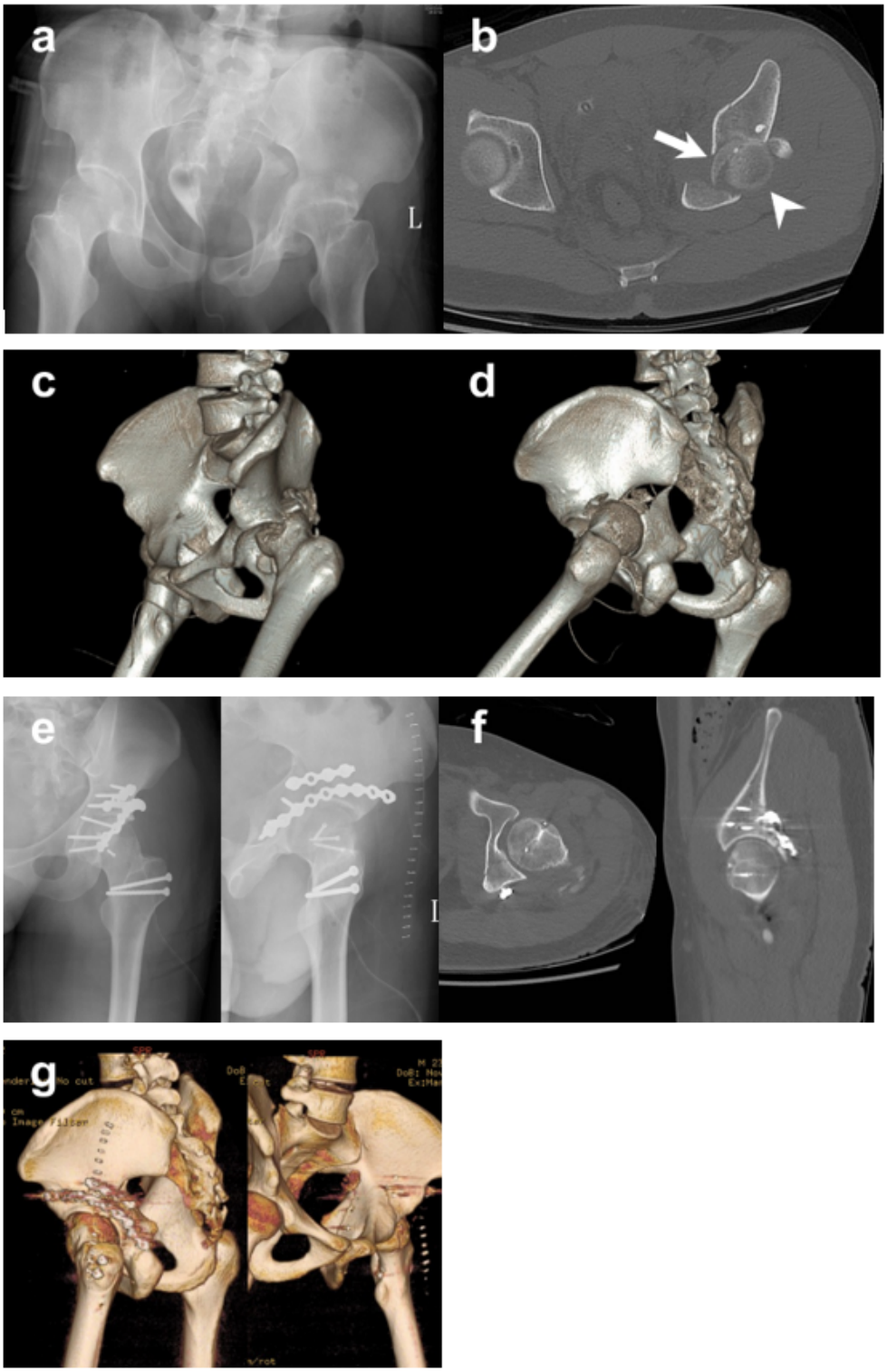

Figure 6

A case of Pipkin IV and T-shaped acetabular fracture Fig. 6a: Preoperative AP view of pelvis Fig. 6b: Preoperative axial cut of CT: The white arrow points out the incarcerated femoral head fragment, while the arrow head shows the remaining femoral head. Fig. 6c & d: Preoperative 3D reconstruction of the CT images show Pipkin IV femoral head fracture-dislocation. Fig. 6e: Postoperative obturator oblique view and iliac oblique view of Judet Fig. 6f: CT images show simultaneously the reduction of acetabulum and

the femoral head. Partial loss of sphericity of the femoral head was noted. The acetabulum, including the posterior wall fragment, was well reduced. Fig. 6g: 3D reconstructed CT image show the reduced T-shaped acetabular fracture and the whole fixation construct.