A Modified Prone Position Using A Body-Shape Plaster Bed and Skull Traction for Posterior Cervical Spine Surgeries

Zhiyu Ding
Central South University Third Xiangya Hospital https://orcid.org/0000-0002-3238-7428
Yuezhan Li
Central South University Third Xiangya Hospital
Weiguo Wang
Central South University Third Xiangya Hospital
Jianlong Wang
Central South University Third Xiangya Hospital
Deyang Cai
Xiangya Basic Medical College of Central South University
Ruping Zheng
Xiangya Basic Medical College of Central South University
Haiyang Yu
Xiangya Basic Medical College of Central South University
Shijie Chen
Central South University Third Xiangya Hospital
Jinglei Miao
Central South University Third Xiangya Hospital
Jinsong Li (Jinsongli@csu.edu.cn)
https://orcid.org/0000-0001-7649-0817

Research article

Keywords: Modified prone position, Cervical spine surgery, Body-shape plaster bed, Skull traction, Posterior approach

Posted Date: June 2nd, 2020

DOI: https://doi.org/10.21203/rs.3.rs-31312/v1

Abstract

Background

A modified prone cervical spine surgical position using a body-shape plaster bed with skull traction (BSPST) was compared with the traditional prone surgical position with horseshoe headrests.

Methods

Forty-seven patients undergoing posterior cervical spine surgery for cervical spine fracture were retrospectively classified into two groups, BSPST group (n = 24) and traditional group (n = 23) and underwent posterior instrumented fusion with or without decompression. Multiple indicators were used to evaluate the advantages of the BSPST compared with the traditional position.

Results

All the operations went smoothly. The mean recovery rate was 56.30% in the BSPST group and 48.55% in the traditional group, with no significant difference. Intraoperative blood loss and total incidence of complications were significantly less in the BSPST group than in the traditional group. In addition, the BSPST position provided greater comfort level for the operators and allowed convenient intraoperative radiography.

Conclusions

This is the first study to describe a combined body-shape plaster bed and skull traction as a modified cervical spine prone surgical position that is simple, safe and stable, adjustable during surgery, reproducible and economical for posterior cervical spine fracture surgery and potentially other cervical and upper dorsal spine surgeries in the prone position. Additionally, this position provides surgeons a comfortable surgical field and can be easily achieved in most orthopedic operation rooms.

Background

The prone position is widely used for posterior cervical and dorsal spine surgeries around the world[1]. To date, the traditional posterior approach to surgical stabilization of the head and the cervical spine is usually achieved by the horseshoe headrest[2]. This system, however, has many shortcomings, such as being unavailable and unstable for position adjustment during surgery. Additionally, inappropriate pressure from the horseshoe headrest over the eyeballs and facial skin may cause damage to patients, especially during long-duration cervical spine surgery in the prone position[3–5].

According to our experience, a good patient surgical position is essential for smooth surgery and should be safe, stable, adjustable during surgery to reduce postoperative complications. The authors present a modification of the prone surgical position for posterior cervical spine surgeries using a cervical tong for skull traction and a body-shape plaster bed for fixing the patients' body. We named this modified prone surgical position the "body-shape plaster bed with skull traction" (BSPST). This modified system using a body-shape plaster bed avoids localized pressure associated with the horseshoe headrest as well as allows free access to anesthetists for better endotracheal tube management. Additionally, the body-shape plaster bed and skull traction support reliable stable fixation at any time during surgery and can also be available for intraoperative position adjustment and radiography.

Based on our previous experiences in posterior cervical and dorsal spine surgeries, we used the BSPST position for 24 patients with unstable cervical spines, i.e., traumatic cervical cord injury caused by cervical spine fracture, undergoing surgical treatment in the prone position. There have been no previous reports of the combination of a body-shape plaster bed and cervical tong used in cervical spine surgery. To evaluate the effectiveness and safety of the BSPST position in posterior cervical spine surgeries, comparisons in perioperative events including positioning time, surgical time, intraoperative blood loss, complications, neurological improvement, and comfort of surgeons between cases using the BSPST position and traditional prone surgical position were performed.

Methods

Patient population

A total of 205 patients who underwent prone position cervical spine surgery from June 2018 to February 2020 in our institute were included and retrospectively reviewed. After excluding cases with degenerative cervical syndrome (n = 62), degenerative cervical spinal stenosis (n = 20), ossification of the cervical spine yellow ligament (n = 9), ossification of the cervical spine posterior longitudinal ligament (n = 33), intraspinal occupying lesion of the cervical spine (n = 26), and other cervical spine diseases (n = 7), a total of 47 patients with cervical spine fracture were included and divided into a BSPST group (using the BSPST position, n = 24) and a traditional position group (using horseshoe headrest position, n = 23). None of the included patients had other diseases related to the cervical spine fracture, and coagulation function test results were normal for every patient. All patients received regular outpatient visits or telephone follow-up, and the final follow-up was defined as the 3-month postoperative follow-up. Informed consent was obtained from all individual participants included in the study.

The modified BSPST position

All surgeries were performed by a senior surgeon with the same standard. The patients were placed in the supine position after general anesthesia on a surgical transfer trolley, and after the body-shape plaster bed was buckled onto the patient's head and chest (*see Additional file 1*), the whole body and the body-shape plaster bed were turned over together and placed in the prone position; then, an anesthesia tube was attached and surgical drape or bandage was used to bind the patient, body-shape plaster bed and

operation table together to ensure stability (*see Additional file 2*). The skull traction was assembled in the appropriate direction and placed on a conventional operating table (here an Alphastar bed, MAQUET GmbH & Co. KG, Sweden) as shown in Figs. 1 and 2. Subsequently, surgeons and assistants can adjust the posture of the cervical spine and head by putting a soft cotton pad between the patient's shoulder and body-shape plaster bed before surgery. The body-shape plaster bed and traction system together provide stability of the patient during adjustment of the operating table and can provide enough space for intraoperative anesthesia tube management (Fig. 3 *and Additional files 2, 3*). Additionally, this system allows intraoperative adjustment of the traction direction and weight by the traction system. At the end of the surgery, the patient was turned supine, and the tong were removed (*see Additional file 4*). The pin sites were dressed with band-aids.

Data statistics and clinical assessments

All the patients underwent radiologic examinations, including computed tomography (CT) and magnetic resonance imaging (MRI) of cervical spine before surgery. The modified Japanese Orthopedic Association (JOA) scores were used to assess neurological function, and the neurological recovery rate was calculated as = (final JOA - preoperative JOA) / (11 - preoperative JOA) × 100%. The neurological recovery rate of 75–100% was designated as excellent; 50–74%, good; 25–49%, fair; and less than 25%, poor. According to our experience in cervical spine surgeries and cervical spine anatomy, we described an assessment of intraoperative surgeon comfort. The angle between the C7 spinous process-external occipital protuberance line and horizontal line (C7SP-EOP angle) was categorized into four levels from −5° to 15° (Fig. 4). Level 4 was defined as the most comfortable position for surgeons with a C7SP-EOP angle between 10°-15° while Level 1 was defined as a difficult process to finish the surgery for surgeons with a C7SP-EOP angle between − 5°-0°. Intraoperative blood loss, operation time and positioning time (the time required after induction of anesthesia until positioning the patient prone on the operating table), perioperative complications, C7SP-EOP angle and possibility for intraoperative radiography were recorded and compared between the two groups.

Statistical analysis

All the data were analyzed by PASW Statistics 18.0 (SPSS Inc., Chicago, IL, USA). Intragroup or intergroup comparisons were performed by independent samples t-test or Pearson's $\chi 2$ test. *P* values less than 0.01 were defined as statistically significant.

Results

The differences in general preoperative information between the two groups were not significant, as shown in *Table 1*. A total of 169 segments (traditional position group, n = 84; BSPST group, n = 85) were involved. The distribution of the surgical levels was not significantly different between the two groups (p = 0.885).

As shown in Table 2, intraoperative blood loss in the BSPST group was significantly less than that in the traditional position group ($p = 0.003$). Although the mean JOA scores in the BSPST group and traditional position group significantly increased at the final follow-up, differences in the preoperative JOA score, final JOA score, neurological recovery rate were not significant. There were six patients in the traditional position group, but no patients in the BSPST group, who experienced facial skin necrosis ($p = 0.007$), and these patients completely recovered after a consultation in the department of dermatology with regular dressing changes for one week. Only two cases in the traditional position group received conjunctival and corneal abrasions but recovered without treatment within several days ($p = 0.140$). Leakage of cerebrospinal fluid occurred with one patient in the traditional position group but no patient in the BSPST group, and this patient experienced incision healing without infection ($p = 0.302$). Both groups had one patient with C5 palsy after the operation that healed on its own ($p = 0.976$). The traditional position group had one patient with wound infection ($p = 0.302$), and this patient was completely healed after regular dressing changes and the use of intravenous antibiotics within one postoperative week. There was only one patient with a cervical tong pin site complication in the BSPST position group ($p = 0.322$). The patient was bleeding under galea aponeurotica because of the use of low molecular weight heparin in the intensive care unit, and the blood was gradually absorbed after stop using low molecular weight heparin. The total incidence of perioperative complications in the BSPST group was significantly less than that in the traditional position group ($p = 0.004$).

Table 1
General preoperative information in two groups

	Traditional position (n = 23)	**BSPST position (n = 24)**	***p* value**
Age (year)	52.09 ± 12.76	52.67 ± 15.89	0.891
Gander (M\F)	21\2	20\4	0.413
Diabetes (n)	3	5	0.478
Hypertension (n)	4	4	0.947
BMI	23.22 ± 4.30	23.30 ± 4.05	0.949
Surgery levels of cervical spine of patients			0.885
2 levels	3	5	
3 levels	8	6	
4 levels	7	9	
5 levels	4	3	
6 levels	1	1	
Comparisons in outcomes and complications between two groups			

Table 2

Comparisons in outcomes and complications between two groups

	Traditional position (n = 23)	**BSPST position (n = 24)**	***p* value**
Operation time (hour)	4.400 ± 1.752	3.755 ± 1.136	0.144
Positioning time (min)	15.960 ± 6.832	16.250 ± 6.835	0.184
Intraoperative blood loss (ml)	439.1 ± 369.0	177.5 ± 105.2	**0.003***
JOA score			
Before surgery	7.913 ± 5.017	7.875 ± 4.675	0.979
1 month after surgery	9.736 ± 5.268	11.040 ± 4.506	0.366
3 months follow-up	11.090 ± 5.468	12.460 ± 4.520	0.353
Neurological recovery rate (%)	48.550 ± 35.770	56.300 ± 34.690	0.454
Grading of neurological recovery rate (n)			0.176
Excellent	7	9	
Good	2	7	
Fair	7	3	
Poor	7	5	
Complication, number of patients			
Face skin necrosis	6	0	**0.007#**
Conjunctival and corneal abrasions	2	0	0.140
POVL	0	0	——
Injury to spinal cord (Leakage of CSF)	1	0	0.302
C5 palsy	1	1	0.976
Wound infection	1	0	0.302
Cervical tong pin sites complications	0	1	0.322

JOA, Japanese Orthopedic Association.

* Statistically different from the intraoperative blood loss ($p < 0.01$).

Statistically different from the face skin necrosis cases ($p < 0.01$).

§ Statistically different from the total incidence of complications ($p < 0.01$).

Difficult access to anesthesia tubes	0	0	——
Total incidence of complications (%)	47.8	8.3	**0.004§**
JOA, Japanese Orthopedic Association.			
* Statistically different from the intraoperative blood loss ($p < 0.01$).			
# Statistically different from the face skin necrosis cases ($p < 0.01$).			
§ Statistically different from the total incidence of complications ($p < 0.01$).			

There were 20 patients in the BSPST group, but only one patient was assessed at level 4 or level 3 in the evaluation system for the degree of comfort of the surgeon during the operation as shown in *Table 3* ($p < 0.01$). The BSPST position allowed both anterior-posterior and lateral intraoperative radiography, while the traditional position did not allow ($p < 0.01$).

Table 3: C7SP-EOP angle (comfort level for surgeons) and Intro-op radiography

	Traditional position (n = 23)	**BSPST position (n = 24)**	**p value**
Comfort level for surgeons			0*
Level 4	0	15	
Level 3	1	5	
Level 2	10	4	
Level 1	12	0	
Intro-op radiography			
A-p (unable\able)	23\0	0\24	0#
Lateral (unable\able)	0\23	0\24	——
* Statistically different from the comfort level of surgeons (p < 0.01).			
# Statistically different from the anterior-posterior intro-operation radiography (p < 0.01).			

Discussion

According to lots of researches, many complications have been reported due to the disadvantages of the traditional posterior approach position, such as postoperative visual loss (POVL), skin necrosis, venous air embolism, etc[3, 6]. These complications may have serious consequences to the patients, but researchers have only sporadically attempted to modify the traditional prone surgical position.

Improper pressure over the eyeballs and facial skin for long time is a common cause of visual loss and skin necrosis. Several studies have discussed postoperative vision loss due to prone position[3]. They conclude that the inappropriate pressure from the horseshoe headrest led to direct pressure over the eyeball, which may cause intraocular pressure and visual loss[7, 8]. In addition, there have been many documented cases of facial pressure sores and ischemic orbital compartment relate to prone position and horseshoe headrest[3]. It has been reported that the long-term localized pressure on the face in the prone position is on average below 30 mmHg but can be higher than 50 mmHg in certain areas, such as the chin and forehead above the supraorbital ridge, which may cause facial edema and pressure sores[9–11].

According to our experience, surgeons may need intraoperative readjustment of patients' position for a better surgical field. The traditional prone position has no fixation of the patients' head, body and operating table, so it is impossible to ensure the stability of patients when adjusting the operating table and traction direction during the operation, which may lead to respiratory passage compression and asphyxia. Additionally, Kadam AB et al.[2] proposed a modified prone position for posterior cervical spine surgeries using cervical tong for traction and two lateral brace attachments on an operating table, which can avoid localized pressure over the eyeballs and face skin associated with horseshoe headrest. However, this modified prone position has an inability to intraoperatively readjust the position and tilt the table beyond 30° to either side.

Immobilization by a cervical collar to protect the patient from secondary damage is a standard procedure in cervical spine trauma patients[12, 13]. However, more studies have pointed out that applying a cervical collar in general will cause immense three-dimensional movement, and extrication collars can result in abnormal movement within the upper cervical spine in the presence of a severe injury[14–16]. We believe that an absolute restriction of the cervical spine cannot be only achieved by the cervical collar during preoperative positioning and may cause secondary dislocation in those with spinal cord injury, especially in the presence of a dissociative injury[17].

The BSPST position has more advantages in protecting facial skin and eyes from skin necrosis and ocular complications with the use of protective macromolecular material. The body-shape plaster bed can decrease the vertical direct pressure by distributing pressure equally across the facial skin, and the round head holder has no direct contact with patients' eyes. In our analysis of the traditional and BSPST positions, we identified ten patients (47.8%) with postoperative complications in the traditional position group and three patients (8.3%) with postoperative complications in the BSPST group ($p = 0.004$). This result showed that the incidence of postoperative complications was relatively high when cervical spine surgery incorporated a traditional prone surgical position compared with the BSPST prone surgical position.

As for the adjustment of the surgical position, the BSPST position can maintain a stable position even when the table exceeds 35° to either side. Additionally, the traction direction can be intraoperatively adjusted to expose of the operation fields for obese and short-neck patients. This method also allows

patients to be stably positioned in the reverse Trendelenburg's position (*see Additional file 3*), which can reduce venous congestion and bleeding as well as reduce orbital pressure to diminish the occurrence of postoperative vision loss[6, 18]. It was obvious in our research that only one patient in the traditional position group but 20 patients in the BSPST group provided surgeon comfort levels of 1 and 2 ($p < 0.01$), and intraoperative blood loss in the BSPST position group was significantly less than that in the traditional position group ($p = 0.003$). These results indicated that the BSPST position may provide the surgeons with a more comfortable surgical position and reduce intraoperative blood loss.

To maintain safety during the preoperative positioning, the surgeon and assistants can create a situation in which the patient and body-shape plaster bed stay together so that the patients' head, whole cervical spine and body can turn around at the same time by using the body-shape plaster bed. The BSPST position also facilitated easy access to the anesthesia tube, which could be removed from either side below the body-shape plaster bed (Figs. 1, 2 *and Additional file 2*).

Intraoperative radiography is necessary for spine surgery, especially cervical spine surgery, and it can help surgeons to conform surgical segments and guide as well as conform pedicle screw placement[19]. However, anterior-posterior interoperative radiography is unavailable in traditional position because of the material of the headrest, which may create difficulties to the surgeons (Figs. 2 and 5). The BSPST position system is X-ray penetrable, easy to assemble and inexpensive, and can be acceptable for patients in many hospitals in developing countries compared with other innovations of prone position for cervical spine surgeries[20–22].

The positioning time was 16.250 ± 6.835 min in the BSPST group and 15.960 ± 6.832 min in the traditional group, which were not significantly different ($p = 0.144$). Although cervical tong application may appear to require additional time, it is a relatively quick procedure, and the time consumed is well compensated by the reduced time required to reduce skin necrosis and ocular complications. In addition, the BSPST position can be used in not only cervical spine fracture surgeries but also other posterior cervical spine surgeries.

All techniques have downsides, and there are still several limitations of this study and the BSPST position. First, retrospective results from a single center should be prospectively verified by multicenter and randomized controlled studies. Second, the patient sample was relatively small, and the follow-up was relatively short in this study. Besides, this position is not available for advanced deformity patients and has some disadvantages directly related to the prone position. In addition, the measurement of the C7SP-EOP angle may show significant deviations in obese patients due to thick fat tissue around the neck and back. Finally, further studies are required to conclusively establish the efficacy and safety of the BSPST position to put it into use and improve upon it.

Conclusion

This is the first study to describe a combined body-shape plaster bed and skull traction as a modified prone surgical position that has characteristics of simple construction, safe and stable, adjustable during

surgery, reproducible and economical for posterior cervical spine fracture surgery and potentially other cervical and upper dorsal spine surgeries in the prone position. Additionally, this position can be easily achieved in most operating rooms and provides a comfortable surgical field for surgeons. However, further studies are required to conclusively establish the efficacy and safety of this modified method.

Abbreviations

BSPST
Body-shape plaster bed with skull traction

Declarations

Ethics approval and consent to participate

All procedures performed in studies involving human participants were in accordance with the ethical standards of the institutional and national research committee (The IRB of the Third Xiangya Hospital, Central South University. Reference number: No. 2019-S036) and with the 1964 Helsinki declaration and its later amendments or comparable ethical standards.

Consent for publication

Not applicable.

Availability of data and materials

To preserve the privacy of the patients, their clinical data will not be shared; data can be available from authors upon request.

Competing interests

The authors declare that they have no competing interests.

Funding

This study was partially supported by National Natural Science Foundation of China (Grant Nos. 81502331, 81772866), The National Key Research and Development Program of China(Grant Nos. 2016YFC1201800), The New Xiangya Talent Project of the Third Xiangya Hospital of Central South University (JY201510), Natural Science Foundation of Hunan Province (Grant Nos. 2016JJ3176, 2018JJ2602, 2018JJ2617), Fundamental Research Funds for the Central Universities of Central South University (Grant Nos. 1053320192461). The study supporters played no role in the study design,

collection, analysis and interpretation of data; in the writing of the manuscript; and in the decision to submit the manuscript for publication.

Authors' contributions

All authors contributed to the study conception and design. Material preparation was performed by Zhiyu Ding, Jinglei Miao, Jianlong Wang and Weiguo Wang, data collection and analysis were performed by Yuezhan Li, Haiyang Yu, Shijie Chen and Deyang Cai. The first draft of the manuscript was written by Zhiyu Ding, Ruping Zheng and Jinsong Li and all authors commented on previous versions of the manuscript. All authors read and approved the final manuscript.

Acknowledgements

We thank Dr. Qingming Peng, Dr. Haoming Feng and Dr. Dongbiao Liu who help to make the simulated videos as the additional files, and Dr. Song Wu for his expertise in spine surgery.

References

1. Schonauer C, Bocchetti A, Barbagallo G, Albanese V, Moraci A. Positioning on surgical table. Eur Spine J. 2004;13(Suppl 1):50.
2. Kadam AB, Jaipuria AS, Rathod AK. Modified prone position using lateral brace attachments for cervico-dorsal spine surgeries. Eur Spine J. 2013;22(7):1474–9.
3. Kwee MM, Ho Y-H, Rozen WM. The prone position during surgery and its complications: a systematic review and evidence-based guidelines. International surgery. 2015;100(2):292–303.
4. Jain V, Bithal P, Rath G. Pressure sore on malar prominences by horseshoe headrest in prone position. Anaesthesia intensive care. 2007;35(2):304–6.
5. Bekar A, Türeyen K, Aksoy K. Unilateral blindness due to patient positioning during cervical syringomyelia surgery: unilateral blindness after prone position. J Neurosurg Anesthesiol. 1996;8(3):227–9.
6. Stambough JL, Dolan D, Werner R, Godfrey E. Ophthalmologic complications associated with prone positioning in spine surgery. JAAOS-Journal of the American Academy of Orthopaedic Surgeons. 2007;15(3):156–65.
7. Slocum H, O'neal K, Allen C. Neurovascular complications from malposition on the operating table. Surg Gynecol Obstet. 1948;86(6):729–34.
8. Kasodekar V, Chen J. Monocular blindness: a complication of intraoperative positioning in posterior cervical spine surgery. Singapore medical journal. 2006;47(7):631–3.
9. Leibovitch I, Casson R, Laforest C, Selva D. Ischemic orbital compartment syndrome as a complication of spinal surgery in the prone position. Ophthalmology. 2006;113(1):105–8.

10. Atwater BI, Wahrenbrock E, Benumof JL, Mazzei WJ. Pressure on the face while in the prone position: proneview™ versus prone positioner™. J Clin Anesth. 2004;16(2):111–6.
11. Shamshery C, Haldar R, Srivastava A, Kaushal A, Srivastava S, Singh PKJJoCJ, et al. An unusual cause of unilateral facial injuries caused by horseshoe headrest during prone positional craniovertebral junction surgery. 2016;7(1):62–4.
12. Subcommittee A, Tchorz KM, Group IAW. Advanced trauma life support (ATLS®): the ninth edition. The journal of trauma acute care surgery. 2013;74(5):1363.
13. Walters BC, Hadley MN, Hurlbert RJ, Aarabi B, Dhall SS, Gelb DE, et al. Guidelines for the management of acute cervical spine and spinal cord injuries: 2013 update. 2013;60(CN_suppl_1):82–91.
14. Ben-Galim P, Dreiangel N, Mattox KL, Reitman CA, Kalantar SB, Hipp JA. Extrication collars can result in abnormal separation between vertebrae in the presence of a dissociative injury. Journal of Trauma Acute Care Surgery. 2010;69(2):447–50.
15. Liao S, Schneider NR, Hüttlin P, Grützner PA, Weilbacher F, Matschke S, et al. Motion and dural sac compression in the upper cervical spine during the application of a cervical collar in case of unstable craniocervical junction—A study in two new cadaveric trauma models. PloS one. 2018;13(4):e0195215.
16. Prasarn ML, Conrad B, Del Rossi G, Horodyski M, Rechtine GR. Motion generated in the unstable cervical spine during the application and removal of cervical immobilization collars. Journal of Trauma Acute Care Surgery. 2012;72(6):1609–13.
17. Horodyski M, DiPaola CP, Conrad BP, Rechtine IIGR. Cervical collars are insufficient for immobilizing an unstable cervical spine injury. J Emerg Med. 2011;41(5):513–9.
18. Carey TW, Shaw KA, Weber ML, DeVine JG. Effect of the degree of reverse Trendelenburg position on intraocular pressure during prone spine surgery: a randomized controlled trial. The Spine Journal. 2014;14(9):2118–26.
19. Abumi K, Shono Y, Ito M, Taneichi H, Kotani Y, Kaneda K. Complications of pedicle screw fixation in reconstructive surgery of the cervical spine. Spine. 2000;25(8):962–9.
20. Moon AS, Cignetti CA, Isbell JA, Weng C, Manoharan SRR. Traumatic hyperextension-distraction injuries of the thoracolumbar spine: a technical note on surgical positioning. European Spine Journal. 2019:1–8.
21. Kolb B, Large J, Watson S, Smurthwaite G. An innovative prone positioning system for advanced deformity and frailty in complex spine surgery. Journal of Neurosurgery: Spine. 2019;1(aop):1–6.
22. Gupta N. A modification of the Mayfield horseshoe headrest allowing pin fixation and cranial immobilization in infants and young children. Operative Neurosurgery. 2006;58(suppl_1):ONS. -E181-ONS-E..

Additional Files

Additional file. 1 The model was placed in the supine position after “general anesthesia” on a surgical transfer trolley, and the body-shape plaster bed was buckled onto the model's head and chest (This is an illustrative video, and not the actual patient)

Additional file. 2 The model’s whole body and the body-shape plaster bed were turned over together by surgeon and assistants and placed in the prone position; then, an anesthesia tube was attached. The head, whole cervical spine and body can turn around at the same time with the use of body-shape plaster bed (This is an illustrative video, and not the actual patient)

Additional file. 3 The body-shape plaster bed and skull traction support reliable stable fixation at any time during surgery, even in reverse Trendelenburg position (This is an illustrative video, and not the actual patient). The C7SP-EOP angle is 11.3° in the BSPST position during the surgery which provide a most comfortable position for surgeons (Practical surgery).

Additional file. 4 At the end of the surgery, the model and the body-shape plaster bed were turned supine, the tong and body-shape plaster bed were removed (This is an illustrative video, and not the actual patient).

Figures

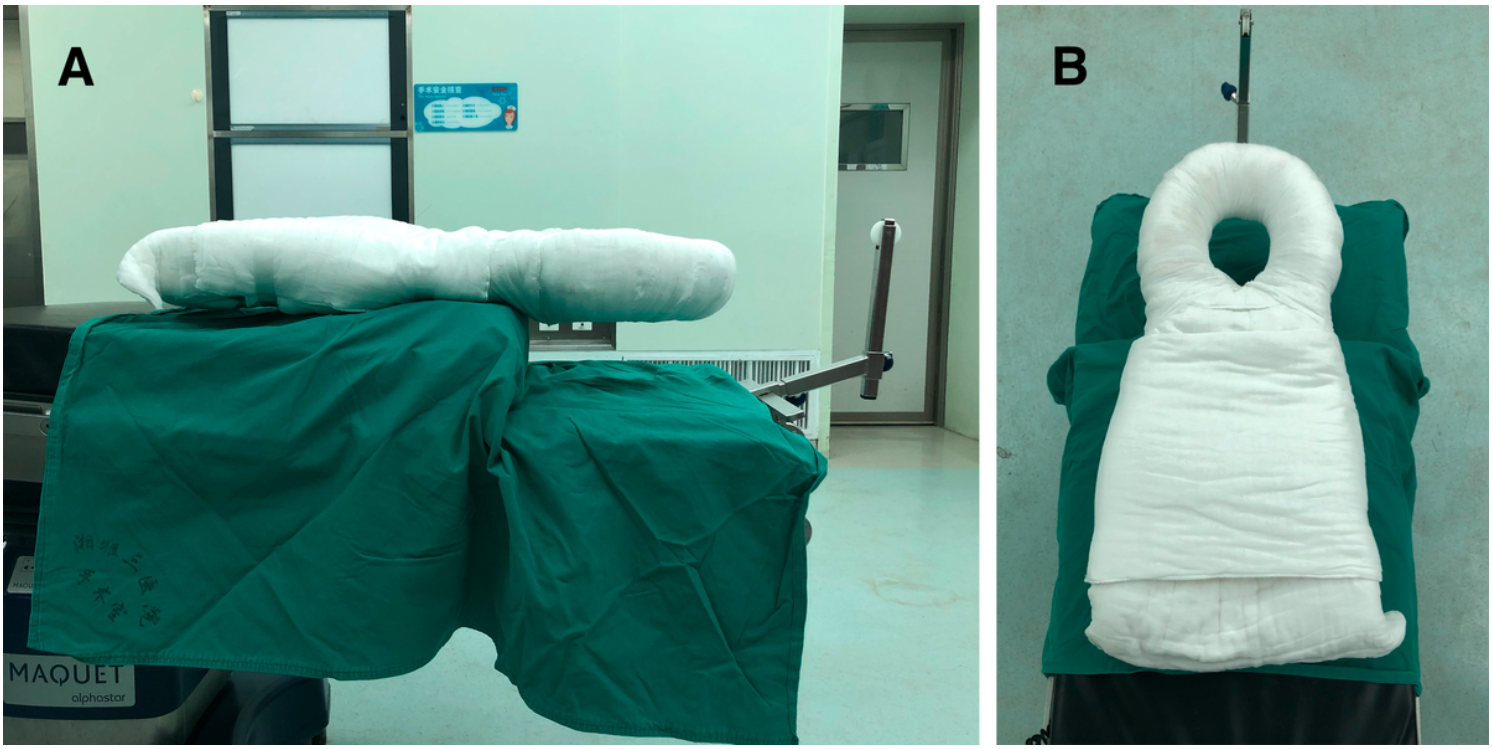

Figure 1

The assembly of traction system set on a conventional operating table and the body-shape plaster bed as seen from different positions. a The BSPST position system can provide enough space for managing anesthesia tube blow the body-shape plaster bed

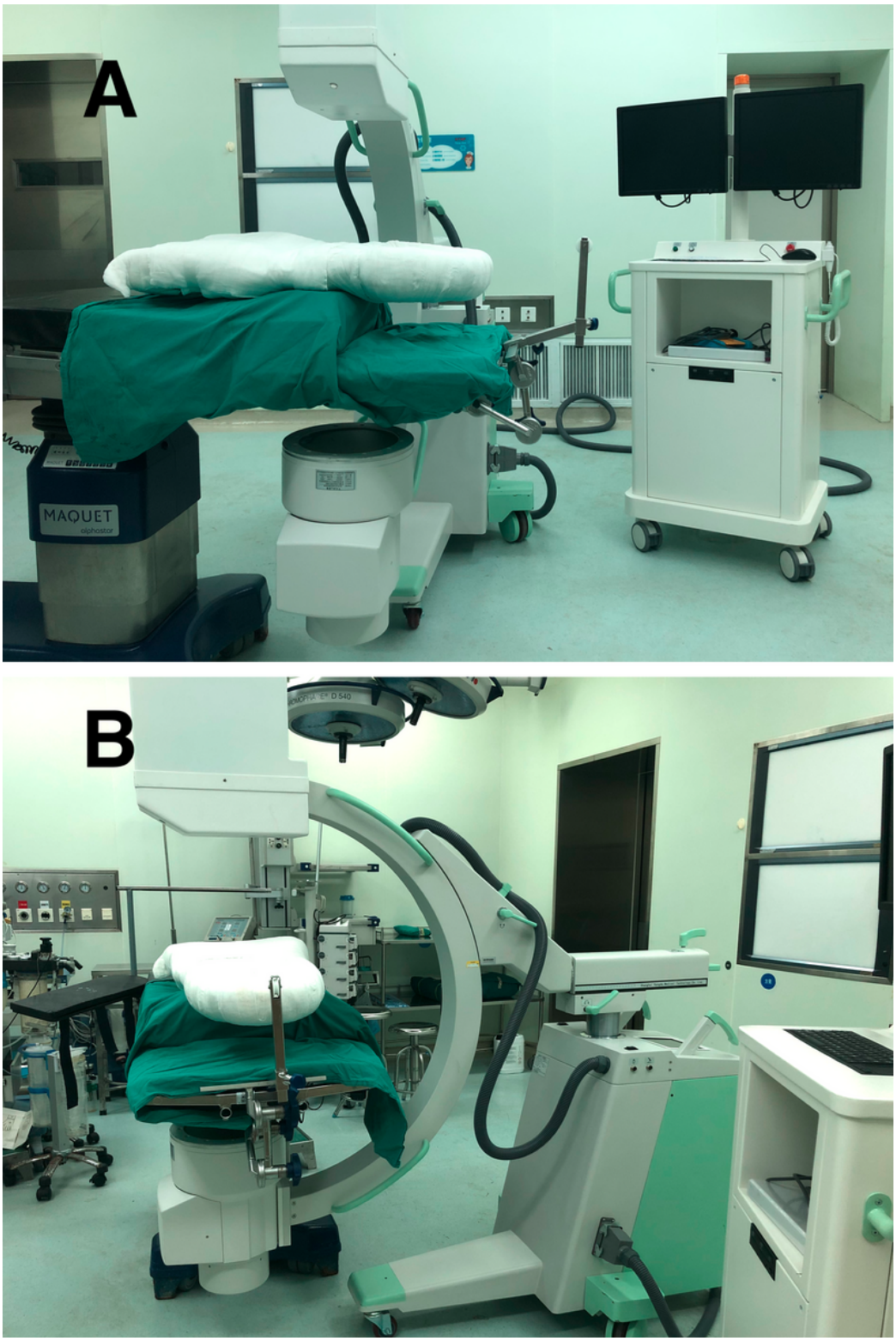

Figure 2

The BSPST system and C-arm digital radiography machine from different positions which can make anterior-posterior interoperative radiography available

Figure 3

The patients undergoing surgical treatment in the prone position. The patient in traditional position with horseshoe headrest (a and c) and in BSPST position with cervical tong for skull traction and body-shape plaster bed for fixation (b and d) as seen from vertical and horizontal angle. The BSPST position can provide enough space for managing anesthesia tube and reliable intraoperative steadiness with the usage of body-shape plaster bed and skull traction

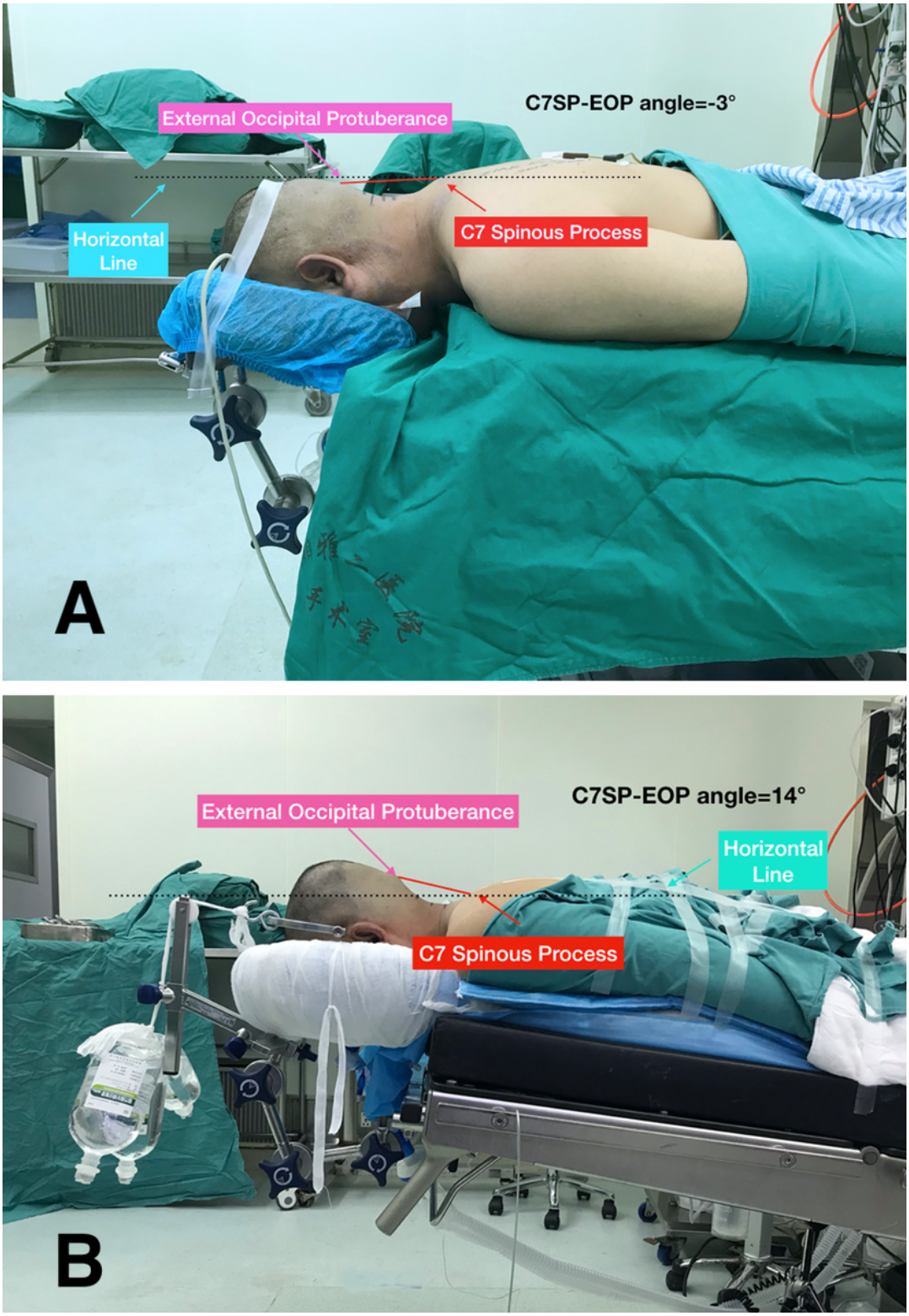

Figure 4

The angle between the C7 spinous process-external occipital protuberance line and horizontal line (C7SP-EOP angle) was define as a system to evaluate the degree of surgeon comfort during the operation. The traditional position is assessed at level 1 (a) while the BSPST position at level 4 (b)

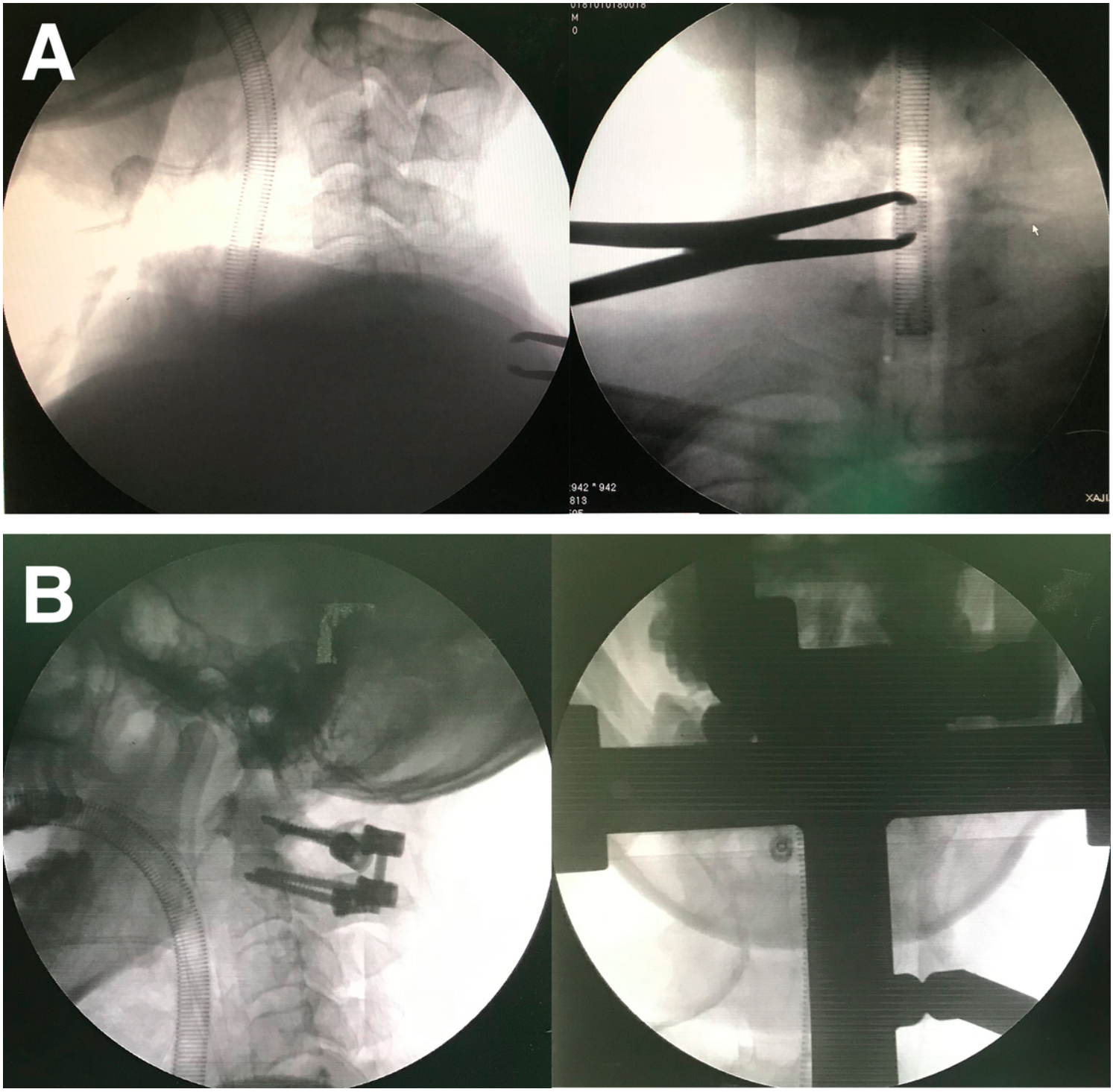

Figure 5

Anterior-posterior intro-operation radiography is available in BSPST position benefit from X-ray penetrable characteristics of plaster (a)

Supplementary Files

This is a list of supplementary files associated with this preprint. Click to download.

- Additionalfile1.mp4
- Additionalfile2.mp4
- Additionalfile3.mp4
- Additionalfile4.mp4