Combined subcostal and posterior transversus abdominis plane block for postoperative pain relief after abdominoplasty

Haytham El Sayed (dr_hytham_anesthesia@yahoo.com)
Al Kindi Specialised Hospital https://orcid.org/0000-0002-1479-6930

A Shaheed Fadhul
SMC

Mohamed Al Falalki
SMC

M Nasr Awad
Al Kindi Specilaised Hospital, Bahrain

Research article

Keywords: Abdominoplasty, pain relief, Abdominal Wall Block

Posted Date: July 23rd, 2020

DOI: https://doi.org/10.21203/rs.3.rs-31398/v2

Version of Record: A version of this preprint was published on December 31st, 2020. See the published version at https://doi.org/10.26715/jbms.32_2020_4_4.

Abstract

Background: Abdominoplasty is a common aesthetic surgery. Adequate pain management during the postoperative period is of great importance. Previous studies have failed to achieve safe and reliable effective analgesic techniques beyond the recovery room. This research aims to investigate the outcome of the abdominoplasty operation for the patients' received transversus abdominis plan block in comparison with the non-blocked patients.

Methods: 58 patients, undergoing elective abdominoplasty, received general anesthesia. Patients were randomly assigned to two equal groups of 29 patients each. Combined subcostal and posterior transversus abdominis plane block group and non-blocked group. For both groups, the standard postoperative analgesic regimen consisted of IV Paracetamol 1 g every 6 hours. Values of visual analog scale values were recorded postoperatively, once the patient had a visual analog scale ≥ 4, IV opioids administered and visual analog scale recorded every 30 min till pain improved. The primary outcome was opioids consumption in the first 72 hours postoperatively, the secondary outcome was the value of visual analog scale at rest and movement (or with knee flexion) in the first 72 hours postoperatively, time to first ambulation, time to first incentive spirometer 900 ml/min were recorded and also the incidence of postoperatively mechanical ventilatory support (CPAP) requirements.

Results: Morphine consumption in the first 72 hours was 6.97±1.97 in the non-blocked group and 4.38±2.04 in the blocked group ($p < 0.05$). Pethidine consumption in the first 72 hours was 208.62±85.64 in the non-blocked group and 20.69±25.06 in the blocked group ($p < 0.05$). VAS was lower in the blocked group during the first 72 hours were ($p < 0.05$). Time to first ambulation was 12.41±5.04 hours in the non-blocked group and 4.62±1.08 hours in the blocked group ($p < 0.05$), time to first incentive spirometer 900 ml/min was 11.45±5.05 hours in the non-blocked group and 4.27±1.09 hours in the blocked group ($p < 0.05$).

Conclusion: Combined subcostal and posterior transversus abdominis plane block is a promising regional anesthetic technique for postoperative pain relief in abdominoplasty surgery, it offers a longer postoperative analgesic effect duration and fewer analgesic requirements with less postoperative complications.

Background

Abdominoplasty is considered one of the most common aesthetic surgery. It is estimated that more than 800,000 people undergo this operation each year, making it the sixth most common cosmetic procedure all over the world [1].

Abdominoplasty is generally elective procedures undergone by healthy patients whose expectations can be ruined by a subsequent complication [2]. Complications of abdominoplasty vary in severity and in the impact they have on the aesthetic outcomes, postoperative pain is the main cause of both late patients ambulation and respiratory complication, respiratory insufficiency or distress complications may develop

secondary to the plication of the rectus abdominis sheath or due to excessive tension, which can be more complicated due to the respiratory depressant effect by opioids analgesics used [3]. Systemic complications are the most feared due to their severity. Combining this surgery with other intra-abdominal operations increases the risk of developing deep venous thrombosis [4]. Reports of a fat embolism following an abdominoplasty are scarce [5].

Improving the postoperative period by reducing pain development leads to earlier ambulation, shortening the hospital stays, reduced hospital costs, and increase patient satisfaction.

Recently systemic acting pain killers have been more effective but also, they have their limitations especially opioids which associated with dose-related side effects including nausea, vomiting, drowsiness and respiratory complications. The usage of multimodal analgesia technique is preferred to take advantage of additive or synergistic analgesics activity while minimizing adverse events with larger doses of single analgesic, the nerve block is considered the cornerstone of multimodal analgesia technique for postoperative pain control as it carries numerous advantages with fewer side effects.

We hypothesis that Abdominal Wall Nerve Blocks give the patients an efficient sensory block to cover the postoperative pain caused by abdominoplasty surgery, which allows the patients to start ambulation early postoperatively, the early regaining of consciousness and avoidance of respiratory or nausea caused by opioids.

Therefore this research is designed to investigate the outcome of the abdominoplasty operation for the patients received combined subcostal and posterior TAP block in comparison with the non-blocked patients. The primary outcome was morphine and pethidine consumption in the first 72 hours postoperatively, the secondary outcome was the value of visual analog scale in the first 72 hours postoperatively, time to first ambulation, time to first incentive spirometer 900 ml/min were recorded and also the incidence of postoperatively mechanical ventilatory support (CPAP) requirements.

Methods

In adherence to CONSORT guidelines, this prospective, randomized study was conducted, after obtaining Hospital Ethics Committee approval and informed written consent was taken for every patient, the study was carried out according to the principles of the Declaration of Helsinki guidelines seventh revision (2013). We studied prospectively 58 patients, undergoing elective abdominoplasty surgery from 2017 to 2020 at Al Kindi Specialised Hospital, Bahrain.

Inclusion criteria were patients undergoing elective abdominoplasty surgery with rectus sheath plication and ASA (I-II) patients. Exclusion criteria were patient’s refusal, patients with a history of known hypersensitivity to local anesthesia and psychiatric disorders, or use of psychiatric medications.

Patients were randomly assigned using computer-generated numbers using random allocation software QuickCals (GraphPad Software Inc., La Jolla, CA, USA) into two equal groups of 29 patients each.

Transversus abdominis plane block (TAPB) group and non-blocked group.

Preoperatively, the patients were educated to the use of the incentive spirometer and visual analog scale (VAS) to monitor their pain postoperatively (where 0 represented no pain, and 10 meant the worst possible pain).

The anesthesia management of all patients was the same. On arrival at the operating theatre, the patients were monitored by electrocardiography, non-invasive blood pressure, and pulse oximetry. Intravenous infusion of warm ringer's lactate solution was initiated. All patients received general anesthesia; midazolam 0.03 to 0.05 mg/kg was given intravenously. After adequate pre-oxygenation, anesthesia was induced by IV fentanyl 1 to 2 µg/kg, propofol 1.5 to 2mg/kg, and cisatracurium 0.15 to 0.2 mg/kg. Tracheal intubation was done and ventilator settings were adjusted to maintain the end-tidal carbon dioxide tension at 30 to 35 mm Hg.

Anesthesia was maintained using 1.2 MAC isoflurane, oxygen–nitrous oxide mixture, and IV cisatracurium incremental doses. Incremental doses of morphine 0.01 to 0.03 mg/kg were given intraoperatively with an interval of 30 min between each dose.

A standard abdominoplasty technique was performed for all patients including rectus sheath plication with or without liposuction. The procedure starts with liposuction, if indicated, by infiltrating the subcutaneous abdominal layer with normal saline mixed with adrenaline, followed by suctioning most of the fat layer using a 2-4 mm cannula through small skin incisions.

Proceeding with abdominoplasty; initially the umbilicus is separated from the abdominal wall through a circular incision & dissecting along the umbilicus stalk. Then, an incision is made horizontally at the pubic hair boundary to approximately 3–4 cm caudal to the anterior superior iliac spine on both sides. The flap is dissected cranially along the superficial fascia, in a lateral direction as far as the xiphoid process and the costal arch. While ensuring immediate hemostasis at all times.

To achieve a good result for the tightening of the abdominal wall, plication of the rectus sheath is routinely carried out by doubling the fascia longitudinally. The first layer, by using an interrupted mattress sutures, while the second layer, which forms sort of a mesh layer, by using a continuous loop suture. The flap is then pulled down, & the excess skin/fat layer is excised. The wound is closed in three layers. Finally, the new umbilicus site is created.

By the end of the surgery, for the blocked group after wound closure and keeping dressing, a bilateral subcostal and bilateral posterior TAPB has done to provide a sensory block for the anterior abdominal wall dermatomes from T6 to L1. Ultrasound-guided block using a high-frequency linear probe 7-15 MHZ, a 22 G needle for injection, and an isobaric bupivacaine 0.25% dosage 2mg/kg as local analgesia with additive dexamethasone 0.1 to 0.2 mg/kg to increase the duration of LA. For the subcostal TAPB the transversus abdominis muscle identified starting beneath rectus abdominis muscle, the target is to visualize the fascial plane between the internal oblique and transversus abdominis muscle where LA has

injected 10 ml on each side. While for the posterior TAPB the three layers of abdominal wall muscles (external and internal oblique as well as the transversus abdominis muscles) were visualized, the target is the fascial plane between the internal oblique and the transversus abdominis muscles where LA was injected 15 to 20 ml on each side.

Using the ultrasound gives the chance of performing the block under the complete clear vision of the needle tip, and also for observing the LA spread which allows us to avoid structures injury (intestine/vascular) and to give the less amount of LA to achieve the wanted effect without the risk of dose-related toxicity.

After finishing the block, isoflurane was discontinued, Neuromuscular blockade was antagonized with 0.025 to 0.05 mg/kg neostigmine and 0.01 to 0.02 mg/kg atropine, and then extubation was done for all patients

In PACU, where patient observed and monitored for 1 hour. ECG, NIBP, pulse oximetry, respiratory rate, and respiratory effort were monitored and VAS was assessed. All patients have received IV morphine of 0.01 to 0.03 mg/kg when VAS ≥ 4, patients with respiratory difficulty non-invasive mechanical ventilation (CPAP) was applied.

In the ward all patients' data were recorded for 72 hours postoperatively. Including the opioids consumption, pain assessed at rest and during movement (or with knee flexion) using VAS in 1 hour (H1), 3 hours (H3), 6 hours (H6), 12 hours (H12), 24 hours (H24), 36 hours (H36), 48 hours (H48), 60 hours (H60) and 72 hours (H72) postoperatively. Also time to the first ambulation and the time to first incentive spirometer when the patient was able to reach 900 ml/min.

For all patients analgesic regimen consisted of IV Paracetamol 1 g every 6 hours, values of VAS were recorded postoperatively, once the patient had a VAS ≥ 4 pethidine 50 mg IV was administered and VAS was recorded every 30 min until the pain improved with an interval of 3 to 4 hours between each pethidine dose.

Data entry and analyses were performed using the SPSS statistical package, version 27 (SPSS, Inc., Chicago, IL, USA). The data were examined for normal distribution using Shapiro-Wilk's test. For parametric data, a t-test was used for mean ± SD, while nonparametric data Wilcoxon Signed Ranks Test was applied for median or frequency. Assuming an α error of 0.05, β error of 0.1, and power of study 90%, the statistically significant level was set a p-value ≤ 0.05, post-hoc power test SPSS was performed also using G power 3.1.9.7 to determine the sample size. All calculated P-values were two-tailed.

Results

The demographic data in table (1) shows that there was no significant difference between both groups regarding the age, BMI, gender, and ASA group. Where the p-value for all are 0.540, 0.416, 1 and 0.285 respectively which are> 0.05

The opioids consumption data in table (2) show that there was a significant difference for the consumption of morphine and pethidine postoperatively. Where the p-value of both morphine and pethidine used are < 0.0001 for both which < 0.05

The VAS data in table (3) shows that there was a significant difference between both groups. Where the p-value of total VAS in (H1, H3, H6, H12, H24, H36, H48, H60, H72) are < 0.0001 for all which are < 0.05

The time to first ambulation postoperatively data in table (4), shows that there was a significant difference between both groups. Where the p-value is < 0.0001 which is < 0.05

The time to first incentive spirometer when the patient was able to reach 900 ml/min postoperatively data in table (5) shows that there was a significant difference between both groups. Where the p-value is < 0.0001 which is < 0.05

The incidence of postoperatively mechanical ventilatory support (CPAP) requirements data in table (6) shows that there was a significant difference between both groups. Where the p-value is 0.001 which is < 0.05

Discussion

Abdominoplasty is a common aesthetic procedure. It aims to improve the abdominal wall contour by the removal of the redundant skin and fat from the abdominal region, including rectus sheath plication and umbilicus transposition. The procedure can be combined with liposuction for further improvement of contour [6]. Patients undergoing such type of surgery usually suffer from preoperative emotional stress and anxiety due to expected postoperative pain. Pain following abdominal surgeries has two components: somatosensory pain originating from the cutaneous, subcutaneous, and muscular layers of the incision site and visceroperitoneal inflammatory pain of viscera and deeper peritoneal layers [7].

Abdominoplasty is an extraperitoneal surgical procedure devoid of the visceroperitoneal pain component. Besides the extensive incision, most of the pain is initially related to the fascial plication of the abdominal wall [8]. Hence, adequate pain management during the postoperative period is of great importance. Previous studies on postoperative pain management after abdominoplasty have failed to achieve effective analgesia beyond the recovery room. So many investigators have been searching for a safe and reliable analgesic technique [9].

This study showed the effectiveness of the TAPB assisted technique for pain control after abdominoplasty. The TAP block was used as a method of analgesia in most varieties of abdominal surgeries [10]. The TAPB has been administrated to provide an early postoperative analgesic effect and so reduce the analgesic requirements. The transversus abdominis plane block (TAPB) is a regional anesthetic technique that targets the injection of the local anesthetic (LA) in the neurovascular plane between the transversus abdominis muscle and the internal oblique muscle [11].

There are various techniques to perform a TAP block (subcostal, lateral, and posterior) each one provides different dermatomes coverage, the exact technique should be selected according to the surgical incision and technique undergoing. The subcostal TAP covers from T6 to T9 dermatomes and is usually suitable for upper abdominal surgeries. Lateral TAP block gives coverage from T10 to T12 dermatomes while the posterior TAP approach covers from T9 to T12, L1, and is shown to provide longer analgesia duration with some visceral analgesic effect [12].

The usage of ultrasound-guided TAP block is not devoid of its challenges, especially in obese patients with the redundant abdominal wall and thick fat folds. Difficult patient positioning, unsuccessful identification of the anatomic landmarks, and lack of suitable equipment require more experience and multiple attempts could be made before achieving a successful block. Additional obstacles could be due to the postoperative tissue edema, the presence of drains, and wound dressing [13,14].

The postoperative opioids consumption in this study; morphine and pethidine consumption were significantly lower in the TAPB group in comparison to the non-blocked group, where our results show that for morphine 4.38±2.04 to 6.97±1.97 and pethidine 20.69±25.06 to 208.62±85.64 respectively.

Our results were in agreement with the results of Araco et al, 2010[15]. who found that it reduces the stress response and facilitates earlier rehabilitation and recovery, also the results of Abo-Zeid MA,2018 who noticed that the direct bilateral TAPB offered a longer postoperative analgesia duration and lesser morphine consumption when compared with rectus sheath block (RSB) and subcutaneous infiltration (SCI)[16].

Abd El-Hamid AM, Afifi EE (2016), concluded that patients with TAP block had lower pain scores and less total postoperative morphine requirements compared with local anesthetic wound infiltration after open inguinal hernia repair [17]. Feng [18] also described a combination of intercostal, pararectus, iliohypogastric, and ilioinguinal nerve blocks for abdominoplasty, her work showed substantial improvements in pain scores and a reduction in narcotic use.

Hebbard P. 2008, described a modification of subcostal TAP block (oblique subcostal TAP block). The purpose of covering the anterior abdominal wall dermatomes from T6 to T12 and L1 performing one needle prick only using a longer needle to inject local anesthesia in the TAP plane from the subcostal region to iliac crest. But it’s difficult to perform, therefore it has not gained popularity. The difficulty is to reach the lower dermatomes and to provide good coverage for the lower abdominal wall[19].

On the other side, Azawietal (2016) found that local anesthetic wound infiltration was superior to the TAP block concerning postoperative analgesia after laparoscopic nephrectomy [20]. J. Kessler, also found that TAP block did not improve postoperative quality of recovery (QoR-40) for patients undergoing total laparoscopic hysterectomy [21]. In contrast, the use of TAP block in patients undergoing more minor gynecological laparoscopic surgery led to faster readiness for discharge and was associated with a better quality of recovery. Similar results were shown for patients undergoing abdominoplasty [22].

Regarding the VAS in this study; total VAS in all 72 hours postoperatively were significantly lower at rest and during movement in the TAPB group in comparison to the non-blocked group, where our results show that for VAS in H1 was 0.14±0.52 to 4.07±1.81, H3 was 0.62±1.42 to 4.97±1.57, H6 was 0.76±1.24 to 4.41±1.35, H12 was 1.38±1.93 to 3.38±1.61, H24 was 1.17±2.12 to 4.21±1.63, H36 was 0.97±1.57 to 4.41±1.55, H48 was 1.03±1.82 to 3.72±1.75, H60 was 1.24±1.64 to 4.21±1.8, H72 was 0.62±1.42 to 4.69±1.34 respectively.

Regarding the time to first ambulation in this study, it was significantly shorter in the TAPB group in comparison to the non-blocked group. Where it was 4.62±1.08 hours and 12.41±5.04 hours respectively. Effective pain management and early ambulation are both linked together and had a recognized impact on recovery from major surgery [23]. The resumption of ambulation sooner in the immediate recovery period has been well established in reducing the incidence of thromboembolism. Several authors have suggested that there is a relationship between reduced mobility and increased risk of venous thromboembolism (VTE), proportional to the degree and length of time for which the patient is confined to bed [24,25,26].

Our results were in agreement with the results of Rolando, who found that liposomal bupivacaine injections for regional blocks in abdominoplasty with rectus plication indicate that patients resumed both earlier ambulation and normal activity [27].

Regarding time to first incentive spirometer 900 ml/min in this study, it was significantly shorter in the TAPB group in comparison to the non-blocked group, where our results show that it was 4.27±1.09 hours and 11.45±5.05 hours respectively.

General anesthesia and postoperative pain carry a risk of developing postoperative pulmonary complications including impaired respiratory drive, cough, and reduced immune system. It was found that residual neuromuscular blockade can be a major problem in the Canadian RECITE study (56.5% with a train of four ratios < 0.9 on arrival in PACU) [28].

Adequate reversal of muscle relaxants and adequate analgesia is vital to reduce postoperative pulmonary complications. Also, to allow patients to breathe deeply, cough, and mobilize. Chest physiotherapy, early ambulation, sitting up positioning, deep breathing, and coughing exercises may reduce postoperative pulmonary complications.

The incidence of CPAP requirement in this study was significantly lower in the TAPB group compared to the non-blocked group, where our results show that non of the patients in the TAPB group needed ventilatory support and for the non-blocked group it was 31%.

Conclusion

Postoperative pain continues to be inadequately managed in a lot of patients and is associated with numerous clinical side effects. The ultrasound-guided TAB block is a promising regional anesthetic

technique for postoperative pain relief in abdominal surgery, it offers a longer postoperative analgesia duration coverage and fewer analgesic requirements. We recommend the routine use of combined subcostal and posterior TAP block as a part of multimodal analgesia regimen after abdominoplasty to enhance the recovery process.

Abbreviations

TAP block
transversus abdominis plane block
VAS
visual analog scale
CPAP
continuous positive airway pressure

Declarations

Ethics approval and consent to participate: Hospital ethical committee approval done on 26/3/2017 (Al Kindi Specialised Hospital, Bahrain).

Consent for publication: Not applicable

Availability of data and materials: The data that support the findings of this study are available from the patient system of Al Kindi Specialised Hospital, Bahrain. An approval to release patients' medical data was taken from the hospital. Data are however available from the authors upon reasonable request and with permission of Al Kindi Specialised Hospital, Bahrain.

Competing interests: The author declared no conflicts of interest concerning the research, authorship, and publication of this article.

Funding: The author received no financial support for the research, authorship, or publication of this article.

Authors' contributions:

HS : Participating in general anesthesia, applying nerve block for all patients, data collection, data analysis for all patients, and manuscript writing.

AF : Performing abdominoplasty surgery for all patients.

MF : Reviewing article writing.

NA : participating in applying general anesthesia for patients.

All authors have read and approved the manuscript.

Acknowledgments: Not applicable

References

1. International Society of Aesthetic Plastic Surgery. Interna¬tional study on aesthetic/cosmetic procedures performed in 2013. Hanover: International Society of Aesthetic Plastic Surgery; 2014
2. Pedro Vidal, Juan Enrique Berner, Patrick A. Will: Managing Complications in Abdominoplasty: A Literature Review. Arch Plast Surg 2017; 44:457-468
3. Tercan M, Bekerecioglu M, Dikensoy O, et al. Effects of abdominoplasty on respiratory functions: a prospective study. Ann Plast Surg 2002; 49:617-20
4. Hatef DA, Kenkel JM, Nguyen MQ, et al. Thromboembolic risk assessment and the efficacy of enoxaparin prophylaxis in excisional body contouring surgery. PlastReconstrSurg 2008; 122:269-79.
5. Shaikh N, Hanssens Y, Kettern MA, et al. Cerebral fat embolism as a rare complication of liposuction with abdominoplasty. Rev Neurol 2008; 47:277-8.
6. Mast BA. Safety and efficacy of outpatient full abdominoplasty. Ann Plast Surg 2005; 54:256-9.
7. Tan C, Kun K, Onsiong M, Chan M, Chiu WK, Tai C. Postincisional local anesthetic infiltration of the rectus muscle decreases early pain and morphine consumption after abdominal hysterectomy. Acute Pain 2002; 4:49-52
8. Desai M. General inhalational anesthesia for cosmetic surgery. In: Friedberg B, editor. Anesthesia in Cosmetic Surgery. Cambridge: Cambridge University Press; 2007:110.
9. Bray DA, Nguyen J, Craig J, Cohen BE, Collins DR. Efficacy of a local anesthetic in abdominoplasty. PlastReconstrSurg 2007; 119:1054-9.
10. Bjerregaard N, Nikolajsen L, Bendtsen TF, Rasmussen BS. Transversus abdominis plane catheter bolus analgesia after major abdominal surgery. Anesthesiol Res Pract 2012; 2012:1-5
11. Niraj G, Searle A, Mathews M, Misra V, Baban M, Kiani S, et al. Analgesic efficacy of ultrasound-guided transversus abdominis plane block in patients undergoing open appendicectomy. Br J Anaesth 2009; 103:601-5.
12. Abdallah FW, LaffeyJG, Halpern SH, Brull R. Durationofanalgesic effectiveness after the posterior and lateral transversus abdominis plane block techniques for transverse lower abdominal incisions: a meta-analysis. British Journal of Anaesthesia. 2013; 111:721–35.
13. Bjerregaard N, Nikolajsen L, Bendtsen TF, Rasmussen BS. Transversus abdominis plane catheter bolus analgesia after major abdominal surgery. Anesthesiol Res Pract 2012; 2012:1-5.
14. Brodsky JB, Lemmens HJM. Regional anesthesia and obesity. ObesSurg 2007; 17:1146-9.
15. Araco A, Pooney J, Memmo L, Gravante G. The transversus abdominis plane block for body contouring abdominoplasty with flank liposuction. PlastReconstrSurg 2010; 125:181-2.
16. Abo-Zeid MA, Al-Refaey ARK, Zeina AM. Surgically-assisted abdominal wall blocks for analgesia after abdominoplasty: A prospective randomized trial. Saudi J Anaesth 2018; 12:593-8.

17. Abd El-Hamid AM, Afi fi EE. Transversus abdominis plane block versus local anesthetic wound infiltration in patients undergoing open inguinal hernia repair surgery. Indian J Anaesth. 2018 Jun; 62(6): 449–454.
18. Feng LJ. Painless Abdominoplasty: The efficacy of combined intercostal and pararectus blocks in reducing postoperative pain and recovery time. PlastReconstr Surg. 2010;126(3):1723-1732.
19. Hebbard P. Subcostal transversus abdominis plane block under ultrasound guidance. Anesthesia and Analgesia. 2008; 106:674–5
20. Azawi NH, Mosholt KSS, Fode M. Unilateral ultrasound-guided transversus abdominis plane block after nephrectomy; postoperative pain and use of opioids. Nephrourol Mon 2016; 8: e35356,1-5.
21. Kane SM, Garcia-Tomas V, Alejandro-Rodriguez M, Astley B, Pollard RR. Randomized trial of transversus abdominis plane block at total laparoscopic hysterectomy: effect of regional analgesia on quality of recovery. Am J Obstet Gynecol 2012; 207:419. e1–5
22. Sforza M, Andjelkov K, Zaccheddu R, Nagi H, Colic M. Transversus abdominis plane block anesthesia in abdominoplasties. PlastReconstrSurg 2011; 128: 529–35
23. Nygren J, Soop M, Thorell A, Hausel J, Ljungqvist O. An enhanced recovery protocol improves outcome after colorectal resection already during the first year: a single-center experience in 168 consecutive patients. Dis Colon Rectum 2009; 52: 978–85.
24. Hull RD, Schellong SM, Tapson VF, et al. Extended-duration venous thromboembolism prophylaxis in acutely ill medical patients with recently reduced mobility: a randomized trial. Ann Intern Med. 2010;153(1):8-18. http://dx.doi.org/10.7326/0003-4819-153-1201007060-00004. PMid:20621900.
25. Motykie GD, Caprini JA, Arcelus JI, et al. Risk factor assessment in the management of patients with suspected deep venous thrombosis. IntAngiol. 2000;19(1):47-51. PMid:10853685.
26. Samama MM. An epidemiologic study of risk factors for deep vein thrombosis in medical outpatients: the Sirius study. Arch Intern Med. 2000;160(22):3415-20. http://dx.doi.org/10.1001/archinte.160.22.3415. PMid:11112234.
27. Aesthetic Surgery Journal 33(8) 1148–1153 © 2013 The American Society for Aesthetic plastic surgery, Inc. Reprints and permission: http//www.sagepub.com/journals Permissions.navDOL:10.1177/1090820X13510720 www.aestheticsurgeryjournal.com
28. Cassidy MR, Rosenkranz P, McCabe K, Rosen JE, McAneny D. I COUGH: reducing postoperative pulmonary complications with a multidisciplinary patient care program. JAMA Surgery 2013; 148: 740–5.

Tables

		NON-BLOCKED GROUP	TAPB GROUP
Age/years			
	Range	21-58	22-62
	Mean	41.17241	42.96552
	SD	9.79092	10.73207
	P value	0.540	
	Standard error	*2.89146*	
	t-statistic	*0.620*	
BMI	*Range*	25.6-41.8	19.1-46
	Mean	32.3069	31.3345
	SD	4.10287	5.25237
	P-value	*0.416*	
	Standard error	*1.17904*	
	t-statistic	*-0.825*	
Gender	*Male*	3	3
	Female	26	26
	Total	29	29
	P-Value	*1.000*	
ASA	*I*	*13*	*17*
	II	*16*	*12*
	Total	*29*	*29*
	P Value	*0.285*	

P is significant at ≤ 0.05

Table (1): Demographic data

		NON-BLOCKED GROUP	TAPB GROUP
Morphine/mg	*Range*	2-10	2-8
	Mean	*6.9655*	*4.3793*
	SD	*1.97272*	*2.042649*
	P value	*< 0.0001*	
	Standard error	*0.54257*	
	t-statistic	*-4.767*	
Pethidine/mg	*Range*	100-400	0-50
	Mean	*208.6207*	*20.6897*
	SD	*85.63728*	*25.0615*
	P value	*< 0.0001*	
	Standard error	*17.13018*	
	t-statistic	*-10.971*	

P is significant at ≤ 0.05

Table (2): Medications used

		NON-BLOCKED GROUP	TAPB GROUP
H1	*Range*	2-6	0-2
	Mean	*4.0690*	*0.1379*
	SD	*1.81129*	*0.51576*
	P value	*< 0.0001*	
	Standard error	*0.36447*	
	t-statistic	*-10.786*	
H3	*Range*	2-6	0-6
	Mean	*4.9655*	*0.6207*
	SD	*1.56941*	*1.42463*
	P value	*< 0.0001*	
	Standard error	*0.37230*	
	t-statistic	*-11.670*	
H6	*Range*	2-6	0-4
	Mean	*4.4138*	*0.7586*
	SD	*1.35006*	*1.24370*
	P value	*< 0.0001*	
	Standard error	*0.31496*	
	t-statistic	*-11.605*	
H12	*Range*	2-6	0-6
	Mean	*3.3793*	*1.3793*
	SD	*1.61276*	*1.93490*
	P value	*< 0.0001*	
	Standard error	*0.48626*	
	t-statistic	*-4.113*	

H24	*Range*	2-6	0-6
	Mean	*4.2069*	*1.1724*
	SD	*1.63400*	*2.17237*
	P value	*< 0.0001*	
	Standard error	*0.49251*	
	t-statistic	*-6.161*	
H36	*Range*	2-6	0-6
	Mean	*4.4138*	*0.9655*
	SD	*1.54728*	*1.56941*
	P value	*< 0.0001*	
	Standard error	*0.41991*	
	t-statistic	*-8.212*	
H48	*Range*	2-6	0-6
	Mean	*3.7241*	*1.0345*
	SD	*1.75044*	*1.82214*
	P value	*< 0.0001*	
	Standard error	*0.40044*	
	t-statistic	*-6.717*	

P is significant at ≤ 0.05

Table (3) Total Visual Analog score

H60		NON-BLOCKED GROUP	TAPB GROUP
	Range	2-6	0-6
	Mean	*4.2069*	*1.2414*
	SD	*1.80038*	*1.64002*
	P value	*< 0.0001*	
	Standard error	*0.42832*	
	t-statistic	*-6.924*	
H72	*Range*	2-6	0-6
	Mean	*4.6897*	*0.6207*
	SD	*1.33907*	*1.42463*
	P value	*< 0.0001*	
	Standard error	*0.36447*	
	t-statistic	*-11.164*	

P is significant at ≤ 0.05

Table (3) Total Visual Analog score

Time to first Ambulation/hour		NON-BLOCKED GROUP	TAPB GROUP
	Range	8-30	3-7
	Mean	*12.4138*	*4.6207*
	SD	*5.04634*	*1.08278*
	P value	*< 0.0001*	
	Standard error	*0.94084*	
	t-statistic	*-8.283*	

P is significant at ≤ 0.05

Table (4): postoperative patient ambulation

Time to first Incentive Spirometer */hour*		NON-BLOCKED GROUP	TAPB GROUP
	Range	7-28	3-7
	mean	*11.4483*	*4.2759*
	SD	*5.04683*	*1.09859*
	P value	*< 0.0001*	
	Standard error	*1.01597*	
	t-statistic	*-7.060*	

P is significant at ≤ 0.05

Table (5): Postoperative Spirometry

Incidence of CPAP Requirement		NON-BLOCKED GROUP	TAPB GROUP
	Mechanically Ventilated (CPAP)	*9 (31%)*	*0*
	Not Mechanically Ventilated	*20*	*29*
	Total	*29*	*29*
	P value	*0.001*	

P is significant at ≤ 0.05

Table (6): Incidence of postoperative CPAP Requirement

Figures

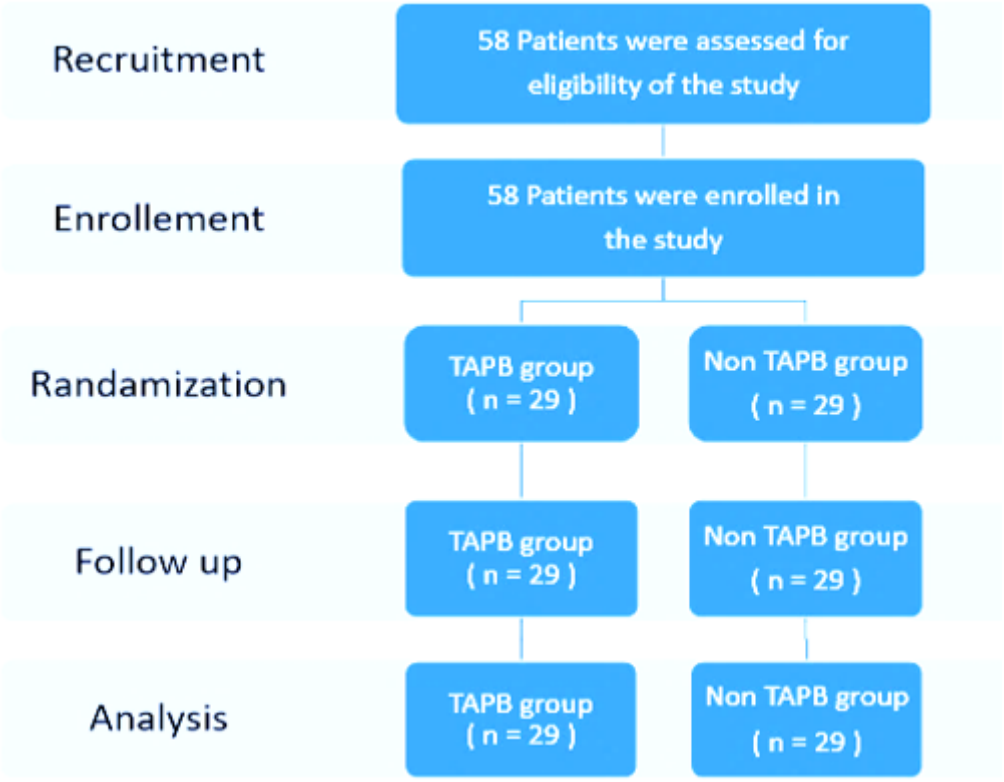

Figure 1

Consort flow chart of the studied patients. TAPB transversus abdominis plane block

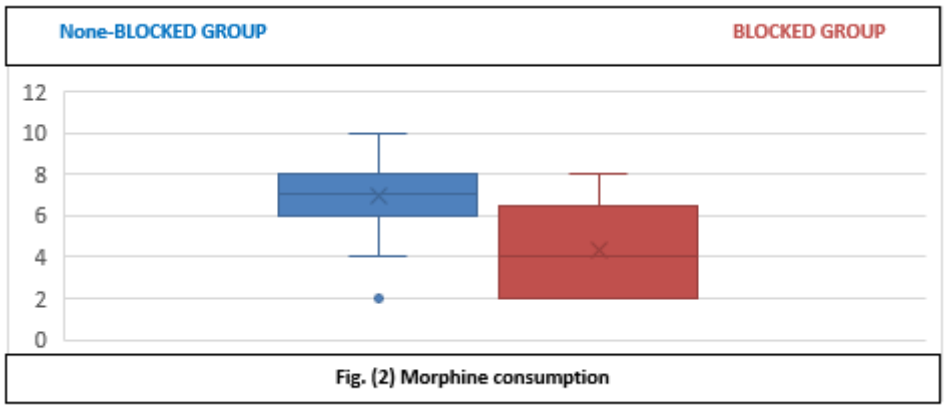

Figure 2

Morphine consumption

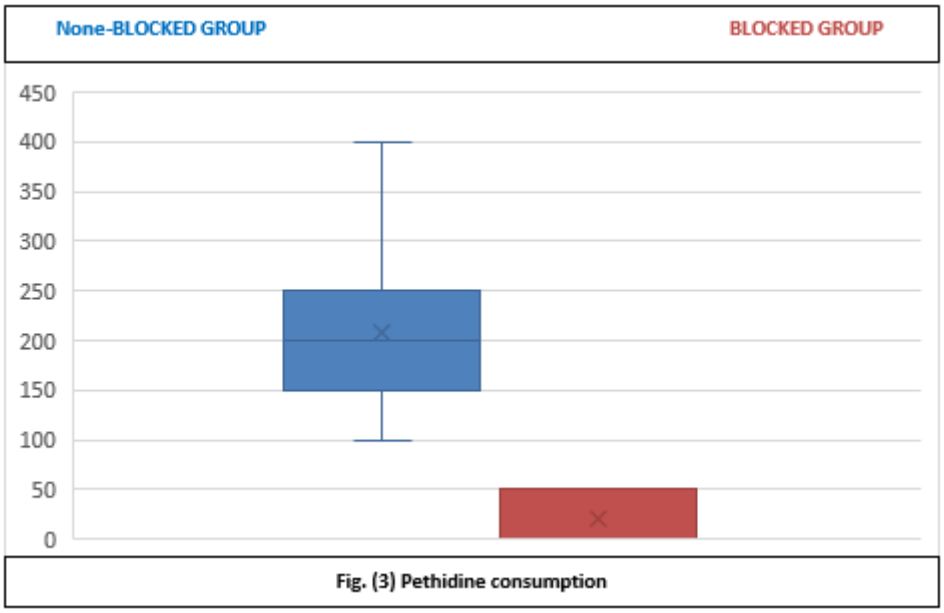

Figure 3

Pethidine consumption