Temporarily double-pin external fixator fixation following unstable ankle fracture

Yusong Yuan
Peking University People's Hospital
Hao Lu
Peking University People's Hospital
Yuhui Kou
Peking University People's Hospital
Haorun Lv
Peking University People's Hospital
Guicheng Li
Peking University People's Hospital
Shuo Feng
Peking University People's Hospital
Hailin Xu (xuhailinfa@163.com)
Peking University People's Hospital

Research Article

Keywords: unstable ankle fracture, external fixator, temporary reduction, distraction

Posted Date: March 23rd, 2021

DOI: https://doi.org/10.21203/rs.3.rs-315766/v1

Abstract

This study designed a new type of double-pin external fixator for temporary fixation of unstable ankle fractures, and the safety and effectiveness of this fixation method were explored. Cases were included in patients with ankle fractures treated in the Department of Traumatology and Orthopedics at Peking University People's Hospital from February 2016 to February 2020. Two groups of cases were obtained (cast group, n=19; double-pin external fixator group, n=21). All cases received the same postoperative care, and the VAS score before and after temporary fixation, the maintenance of fracture reduction, the complications of temporary fixation and the interval time were recorded. All patients completed follow-ups. There were 4 cases and 0 cases of complications in the cast and double-pin external fixator groups respectively. 6 cases and 1 case each had a loss of reduction in the cast and double-pin external fixator groups respectively. There was no difference in interval time for final open reduction with internal fixation between the two groups. The post-fixation VAS score of the double-pin external fixator group was significantly lower than that of the cast group. This technique is a simple, safe, and effective treatment for the temporary reduction of unstable ankle fractures with double-pin external fixator which can relieve patients' pain, effectively maintain the length of the lateral malleolus, and create good soft tissue conditions for elective surgery under the state of grasping the indications strictly.

Introduction

Ankle fractures account for about 3.9% of systemic fractures, ranking first among intra-articular fractures[1]. Although the use of conservative or surgical treatment for certain type of fractures is somewhat controversial, unstable ankle fractures are well known surgical indications[2].

Ideally, surgical treatment of closed unstable ankle fractures should be performed within 6 to 8 hours after injury. Hoiness et al. reported the incision healing rate of patients undergoing surgical treatment for ankle fractures within 8 hours after injury was significantly much lower than that of 5 days[3]. However, not all patients could undergo operations in time for some reasons, such as complicated systemic diseases, patient delay and insufficiency of surgeons. If delayed, there have to be 1 or 2 weeks until the soft tissue condition meets surgical needs.

In order to maintain the alignment of the ankle joint and accelerate the recovery of soft tissue, temporary reduction and external fixation of the fractures must be performed before the final open reduction and internal fixation (ORIF). Most commonly used methods are brace or cast and calcaneal traction. However, brace or cast is difficult to maintain the reduction for some cases of severe instability, such as malleolus fractures with dislocation. Calcaneal traction restricts the patient's autonomous activities and the comfort level is poor [4]. Therefore, there is urgent need for temporary external fixation which provides relatively stability and better comfort for patients with severely unstable ankle fractures.

Inspired by the staging surgery of Pilon fractures[5-7], we designed a new double-pin external fixator which can provide enough stability for ankle fractures as well as skeletal traction. The purpose of this study

was to evaluate the clinic effect and complications of this new external fixator for temporary fixation of unstable ankle fractures.

Materials And Methods

Patients

Consecutive patients with ankle fractures that underwent ORIF in our hospital between February 2018 and February 2020 were retrospectively reviewed. The informed consent was obtained from all subjects. All methods were carried out in accordance with relevant guidelines, random clinical trials and regulations. All protocols were approved by the Ethics Committee of Peking University People's Hospital.

Inclusion criteria were (1) age≥16 years, (2) closed ankle fracture with ankle dislocation or subluxation, and (3) emergency ORIF could not be performed. Talus dislocation or subluxation was defined as over 50% displacement of talus dome relative to the distal tibial plafond which was observed on anteroposterior (AP) or lateral radiographic view. Patients were excluded if they had (1) open fractures, (2) psychiatric disorders, or(3)previous surgery on the affected ankle.

Ultimately, a total of 40 patients were included in this study (26 males and 14 females, mean age= 57.0±12.2 years). 19 patients of them were fixed temporarily with cast after closed reduction(designated as cast group), while 21 patients were fixed with double-pin external fixator at first(designated as double-pin external fixator group). All of them underwent ORIF finally. As shown in Table 1, there was no significant difference in patient's age and sex (all P>0.05).

Table 1. Patient Demographics

	Cast Group (n=19)	Double-Pin External Fixator Group (n=21)
Sex, No. (%)		
male	13(68.4)	13(61.9)
female	6 (31.6)	8 (38.1)
Age, mean±SD□y	57.4±13.5	56.5±11.2
Fracture type (Danis-Weber) (n)		
A	0	0
B	5	6
C	14	15

Techniques

Cast Group

The ankle fracture with dislocation or subluxation was manually reduced and then fixed with U shape cast.

Double–pin External Fixator Group

Local anesthesia with 1% lidocaine was performed in the area where the pin penetrated the skin. 4.0mm K -wires were used as the transtibial and transcalcaneal pins. We placed the percutaneous transtibial pin at the midpoint of the tibial tubercle and fibular head on the lateral side in a direction perpendicular to the tibial axis from laterally to medially. The percutaneous transcalcaneal pin was placed from medially to laterally, parallel to the sole of the foot ,utilizing the technique described by Kwon et al.[8]. The hilt of scalpel handle was placed on the medial side of the posterior inferior calcaneal tuberosity and the pin was placed at the tip of the No. 10 scalpel blade[8].

The ankle fracture and dislocation was manually reduced after placement of transtibial and transcalcaneal pins. While the operator maintained the reduction, the assistant connected medial and lateral traction rods to transtibial and transcalcaneal pins with rod-pin clamps. Axial traction was applied by rotating the threaded knobs in the traction rods. Inversion traction was applied for patients with valgus fractures, while valgus traction was applied for patients with varus fractures. Intraoperative fluoroscopy was used to confirm the reduction of ankle dislocation or subluxation, recovery of the fibular length and distraction of the joint space (figure 1).

Post operation

Ice, limb elevation and medicines (Cesra, Arzneimittel GmbH □CO.KG) were given to reduce swelling. X-ray examination was taken to confirm maintenance of fracture reduction during operation andone day before final ORIF.

Follow-ups

Visual Analogue Scale (VAS) of ankle pain before temporary fixation and 1 day post-fixation was evaluated. The interval time between temporary fixation and final ORIF was recorded. The maintenance of reduction and complications of cast or double-pin external fixator were also assessed.

Statistics

The statistical analysis was performed by SPSS 18.0 software. Results were presented as mean ± standard deviation(SD). Independent sample t test was used to analyze the differences in the data of normal distribution in each group. Rank sum test was used to compare the differences between groups for non-normally distributed data. The significance level was set at 0.05.

Results

The VAS scores of the two groups before temporary fixation were 8.84±0.69 and 8.86±0.65, respectively, and the difference between the groups was not significant (P=0.881). The VAS score of patients in double-pin external fixator group was significantly lower than that in cast group 1 day post-fixation (P=0.015) (table 2). There was no significant difference in interval time between the two groups(P=0.112) (table 2).

Reduction loss was identified in 6 cases in cast group and 1case in double-pin external fixator group. Tension blister was found in 4 cases in cast group, while no complications in double-pin external fixator group.

Table 2 The situation after temporary fixation

	Cast Group	Double-Pin External Fixator Group	P value
Pre-fix VAS Score	8.84±0.69	8.86±0.65	0.881
Post-fix VAS Score	3.05±0.80	2.74±0.45	0.015
Interval Time (Days)	6.53±0.90	6.10±0.77	0.112
Reduction Loss	6/19	1/21	<0.001
Complications	4/19	0/21	<0.001

Discussion

Soft tissue swelling is not serious within 8 hours after ankle fractures. This is the best time for ORIF. If emergency surgery is delayed, the pressure of the subcutaneous tissue continues increasing and may lead to tension blister, which impairs surgical effect and increases the risk of postoperative complications[9]. In addition, fibrous tissue resulting from hematoma organization around the fracture site may hinder the reduction during operation, especially the restoration of the length of fibula. Therefore, if emergency ORIF can not be performed for any reason, the ankle fracture should be reduced and fixed temporarily to stimulate recovery of soft tissue.

Cast is the most widely used method for definite or temporary fixation for ankle fractures[10]. However, its disadvantage is that tightness of the cast is difficult to control. If the cast is fixed too loosely, the reduction cannot be maintained effectively. On the contrary, although over-tightening of the cast is conductive to maintenance of reduction, the soft tissue around the ankle becomes swelling increasingly during the first 3-day after fracture, thus the tightly wrapped cast may cause iatrogenic injury to soft tissue. As a result, the cast must be replaced or adjusted and the condition of soft tissue must be observed regularly[11]. When facing severely unstable ankle fractures, especially those with talus dislocation or subluxation, even a good cast can hardly guarantee the maintenance of reduction[12].

Calcaneal traction is also a frequently used method to restore the alignment of the ankle fracture and provide continuous traction, which is easy to operate. But it restricts patients' activities, makes it inconvenient for patients to turn over and causes difficulty in nursing. Most patients feel uncomfortable after calcaneal traction.

Staging surgery for high energy Pilon fractures has been previously reported by several authors[13-17] which includes temporary fixation with external fixator and subsequent final ORIF. There are only two published articles about temporary fixation of ankle fractures with external fixator. Lareau et al. reported that the use of external fixators to temporarily fix unstable ankle fractures in emergency department could effectively maintain the temporary reduction and reduce the damage of articular cartilage and soft tissue[18]. There was another temporary reduction method proposed by Richard A. Wawrose et al. that the injured ankle was fixed with three dimentional external fixator which took tibial tuberosity, calcaneus and fore foot as fixed points[19]. This kind of methods could provide more stability meanwhile more iatrogenic injuries. Therefore we designed a new double-pin external fixator (figure 2). This external fixator is simple in structure, easy to operate and only needs local anesthesia. In spite of its simple design, it provides much more stable fixation than cast. Reduction loss was identified only 1/21 in external fixator group, compared with 6/19 in cast group. Loosening of transcalcaneal pin was seen in only one elderly female patient with severe osteoporosis undergoing external fixator, resulting in fixation failure and reduction loss, which suggests this method may not bereliable for elderly patient with severe osteoporosis and traditional external fixator with ring frame and more pins may be indicated. However, double-pin external fixator has been able to meet the clinical needs as a temporary, transitional fixed method. In addition, another advantage of our design is continuous distraction of ankle joint, because we used extension rods with threaded knobs to connect pins. This improved design makes our external fixator provide continuous and adjustable distraction for ankle fractures, which draws the advantages of calcaneal traction and makes it easier to restore the length of fibula in final ORIF.

The postoperative VAS score of double-pin external fixator group was significantly lower than that of cast group, probably resulted from patients' better subjective experience. Patients could perform non-weight-bearing activities with external fixator, without the tight feeling of the cast, and it was more convenient to observe soft tissue condition or treat tension blister. Although the subjective feeling of patients was improved, there was no significant difference in the interval time between the two groups, which may indicate the double-pin external fixator could not accelerate the recovery of the soft tissue compared with the cast.

The pins in our design penetrated proximal tibia and calcaneus, not interfering with the ankle joint or irritating soft tissue around the incision area of ORIF. In this study, there was no pin infection and delayed pin wound healing after pin removing. So it is a safe method to fix unstable ankle fracture temporarily.

There are some limitations of this study. This was a retrospective study with a small sample size due to most patients with severely unstable ankle fractures undergoing emergency ORIF in our hospital. In the

future, a prospective clinical trial with a larger sample size should be conducted to further validate the clinic effect of this new double-pin external fixator for temporary fixation of unstable ankle fractures.

Conclusion

In summary, the temporary fixation of unstable ankle fractures with double-pin external fixator can provide patients with efficiency reduction, an improved subjective experience and good soft tissue conditions for the final internal fixation surgery in the absence of emergency surgery.

Declarations

Acknowledgments

Not applied.

Declaration of Conflicting Interests

The author(s) declared no potential conflicts of interest withrespect to the research, authorship, and/or publication of this article.

Funding

This study was supported by the Beijing Municipal Science and Technology Project, No. Z181100001718159; Capital's Funds for Health Improvement and Research, No. 2020-2-4086; Pilot project on clinical collaboration of major and difficult diseases of Chinese and Western medicine, No.201803190106; Health Science and Technology Project of Beijing Dongcheng District Health Commission, NO.[2018]-13; the Key Laboratory of Trauma and Neural Regeneration (Peking University), the Ministry of Education, No.BMU2019XY007-01; the Ministry of Education Innovation Program of China, No.IRT_16R01.

References

1 Koval, K. J. *et al.* Ankle fractures in the elderly: what you get depends on where you live and who you see. *J Orthop Trauma* **19**, 635-639, doi:10.1097/01.bot.0000177105.53708.a9 (2005).

2 Javed, O. A., Javed, Q. A., Ukoumunne, O. C. & Di Mascio, L. Surgical versus conservative management of ankle fractures in adults: A systematic review and meta-analysis. *Foot Ankle Surg* **26**, 723-735, doi:10.1016/j.fas.2019.09.008 (2020).

3 Hoiness, P. & Stromsoe, K. The influence of the timing of surgery on soft tissue complications and hospital stay. A review of 84 closed ankle fractures. *Ann Chir Gynaecol* **89**, 6-9 (2000).

4 von Keudell, A. G. *et al.* Closed Reduction of a Fractured and Dislocated Ankle. *N Engl J Med* **381**, e25, doi:10.1056/NEJMvcm1511693 (2019).

5 Chen, H., Cui, X., Ma, B., Rui, Y. & Li, H. Staged procedure protocol based on the four-column concept in the treatment of AO/OTA type 43-C3.3 pilon fractures. *J Int Med Res* **47**, 2045-2055, doi:10.1177/0300060519836512 (2019).

6 Minator Sajjadi, M. *et al.* The Outcomes of Pilon Fracture Treatment: Primary Open Reduction and Internal Fixation Versus Two-stage Approach. *Arch Bone Jt Surg* **6**, 412-419 (2018).

7 Tong, D. *et al.* Two-stage procedure protocol for minimally invasive plate osteosynthesis technique in the treatment of the complex pilon fracture. *Int Orthop* **36**, 833-837, doi:10.1007/s00264-011-1434-0 (2012).

8 Kwon, J. Y., Ellington, J. K., Marsland, D. & Gupta, S. Calcaneal traction pin placement simplified: a cadaveric study. *Foot Ankle Int* **32**, 651-655, doi:10.3113/FAI.2011.0651 (2011).

9 Toth, M. J., Yoon, R. S., Liporace, F. A. & Koval, K. J. What's new in ankle fractures. *Injury* **48**, 2035-2041, doi:10.1016/j.injury.2017.08.016 (2017).

10 Lin, C. W. *et al.* Rehabilitation for ankle fractures in adults. *Cochrane Database Syst Rev* **11**, CD005595, doi:10.1002/14651858.CD005595.pub3 (2012).

11 Zelle, B. A., Dang, K. H. & Ornell, S. S. High-energy tibial pilon fractures: an instructional review. *Int Orthop* **43**, 1939-1950, doi:10.1007/s00264-019-04344-8 (2019).

12 Willett, K. *et al.* Ankle Injury Management (AIM): design of a pragmatic multi-centre equivalence randomised controlled trial comparing Close Contact Casting (CCC) to Open surgical Reduction and Internal Fixation (ORIF) in the treatment of unstable ankle fractures in patients over 60 years. *BMC Musculoskelet Disord* **15**, 79, doi:10.1186/1471-2474-15-79 (2014).

13 Kottmeier, S. A., Madison, R. D. & Divaris, N. Pilon Fracture: Preventing Complications. *J Am Acad Orthop Surg* **26**, 640-651, doi:10.5435/JAAOS-D-17-00160 (2018).

14 Luo, T. D. & Pilson, H. in *StatPearls* (2020).

15 Muller, F. J. & Nerlich, M. Tibial pilon fractures. *Acta Chir Orthop Traumatol Cech* **77**, 266-276 (2010).

16 Chen, D. W., Li, B. & Yu, G. R. Comment on Tong et al.: Two-stage procedure protocol for minimally invasive plate osteosynthesis technique in the treatment of the complex pilon fracture. *Int Orthop* **36**, 1533-1534, doi:10.1007/s00264-012-1561-2 (2012).

17 Schulz, A. P. *et al.* Severe Fracture of the Tibial Pilon: Results with a Multidirectional Self-locking Osteosynthesis Plate Utilizing a Two-stage Procedure. *Eur J Trauma Emerg Surg* **34**, 391-396,

doi:10.1007/s00068-007-2209-6 (2008).

18 Lareau, C. R., Daniels, A. H., Vopat, B. G. & Kane, P. M. Emergency department external fixation for provisional treatment of pilon and unstable ankle fractures. *J Emerg Trauma Shock* **8**, 61-64, doi:10.4103/0974-2700.150400 (2015).

19 Wawrose, R. A. *et al.* Temporizing External Fixation vs Splinting Following Ankle Fracture Dislocation. *Foot Ankle Int* **41**, 177-182, doi:10.1177/1071100719879431 (2020).

Figures

Figure 1

A case type B unstable ankle fracture temporarily fixed with double-pin tractor . A and B are the X-ray film and three-dimensional reconstruction CT of the fracture, respectively. C and D are the film of intraoperative fluoroscopy.

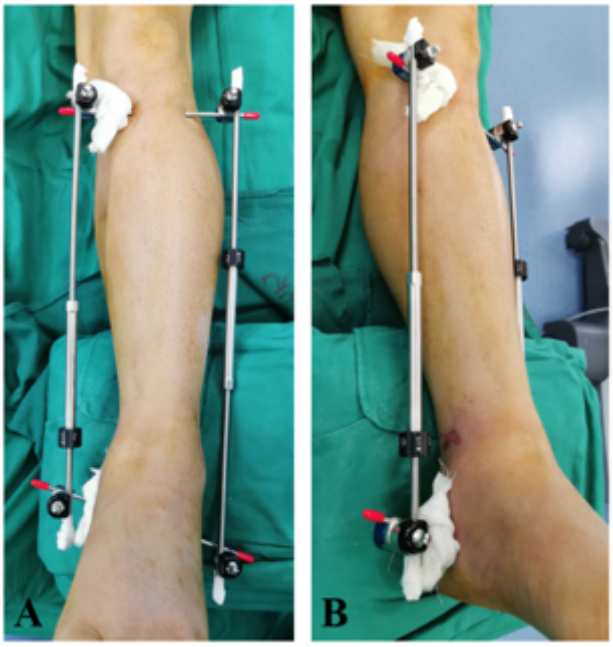

Figure 2

The anteroposterior and lateral view of the ankle joint after temporary fixation with a double-pin external fixatorpins fixator.