Surgical Treatment of Early Postpartum Hemorrhage Caused by Lower Uterine Segment Atony

Dubravko Habek (dubravko.habek@os.t-com.hr)
GENERAL HOSPITAL https://orcid.org/0000-0003-1304-9279

Ingrid Marton
Clinical Hospital “Sveti Duh”, School of Medicine University of Zagreb, Catholic University of Croatia

Matija Prka
Clinical Hospital “Sveti Duh”, School of Medicine University of Zagreb, Catholic University of Croatia
https://orcid.org/0000-0002-7226-0229

Ana Tikvica Luetić
Clinical Hospital “Sveti Duh”, School of Medicine University of Zagreb, Catholic University of Croatia

Mirjam Vitić
Clinical Hospital “Sveti Duh”, School of Medicine University of Zagreb, Catholic University of Croatia

Ana Jurković
Clinical Hospital “Sveti Duh”, School of Medicine University of Zagreb, Catholic University of Croatia
https://orcid.org/0000-0002-1360-3826

Research Article

Keywords: postpartum hemorrhage, uterine atony, lower uterine segment atony, management

Posted Date: March 31st, 2021

DOI: https://doi.org/10.21203/rs.3.rs-316854/v1

Abstract

Purpose: Lower uterine segment atony is recently being recognized as one of the major reasons for early postpartum hemorrhage.

Methods: We present our experience in surgical treatment of lower uterine segment atony patients that were delivered in our tertiary perinatal center during the 10 years period (2010-2019).

Results: This particular study enrolled total number of 29 543 deliveries with 215 cases of early PPH (0,72%). LUSA was diagnosed in 44 cases or in 29,93% in all uterine atony cases. Exploration of the lower uterine segment accompanied by evacuation of the coagula was conducted in 5 cases (11,36%), haemostatic ligation procedures according to authors: Losickaja in 2 cases, Hebisch-Huch in 9 cases, Habek in 5 cases, Hebisch-Huch+Losickaja in 9 cases. Evacuation procedures were combined with ligation techniques in 7 cases, evacuation methods with ligation techniques and balloon tamponade in 2 cases, exploration combined with gauze tamponade in 1 case and ligation procedures with balloon tamponade in 3 cases. According to our results, haemostatic ligation procedures alone or combined with tamponade, have shown to be highly effective in 88,63%.

Conclusion: Transvaginal approach for surgical treatment of lower uterine segment atony is accessible, feasible, successful and life saving. It can be easily performed in inpatient and outpatient care settings followed by administration of uterotonics, uterostiptics and tranexamic acid and fluid replacement. All of the above mentioned methods are of great importance in the prevention and treatment of obstetric hemorrhagic shock, development of coagulopathy, multiorgan failure, postpartum hysterectomy and finally vital for fertility preservation.

Introduction

Early or primary postpartum hemorrhage (PPH) is besides of obstetric shock, recognized as the main reason of maternal morbidity and mortality. Uterine atony, birth trauma, retained tissue and coagulation defects are know etiopatogenic factors of early PPH. Physiological mechanisms that limit postpartum blood loss are: contractions of the myometrium and local spreading of decidual hemostatic factors which cause clotting. The pathogenesis of most cases of PPH is a disturbance in one or both mechanisms [1–6]. The most common cause of PPH in more than 50% of cases is uterine atony, lack of effective contraction of the uterus after the delivery. In old textbooks and some recent papers, the distinction between diffuse (corporeal, fundal, upper uterine segment) uterine atony and lower uterine segment atony (LUSA) has been underlined. With diffuse atony, blood loss can be much greater than observed because a dilated and flaccid uterus may contain a significant amount of blood. When uterine atony is localized in the region of the lower uterine segment, the fundal region may be well contracted while the lower uterine segment is dilated and atonic and is detected during vaginal examination. When LUSA is the reason for PPH, conservative therapy is usually not sufficient, due to the fact that there are < 10% myofibrils in the region of lower uterine segment. Therefore, surgical hemostatic compressive and /

or ligation management is necessary [2, 3, 5–7, 9–13]. Till now, the incidence of LUSA remains unknown [(2,3,5,6]. Besides clinical signs of early PPH and effective contraction of fundal region, vaginal examination relieves dilated, ballooning and atonic lower uterine segment that is heavy bleeding [3, 6]. Ultrasound examination relives empty uterine cavity, ballooned out lower uterine segment and coagulum within. According to the literature there are many suggested procedures such: manual evacuation of the coagula, curettage, different compressive methods of uterine or vaginal tamponade, uterine compression sutures and uterine artery ligation techniques as well as administration of uterotonics, antifibrinolytics, tranexamic acid and peripartum hysterectomy as the last resort for the treatment of intractable severe PPH [3, 6, 9–14]. The main aim of surgical methods is prevention of obstetric hemorrhagic shock complicated by disseminated intravascular coagulopathy, preservation of uterus and fertility by sustaining from hysterectomy. Peri and postpartum hysterectomy is being mainly performed due to the heavy bleeding mainly caused by uterine atony or invasive malplacentation. Cesarean section and vaginal birth after cesarean section are associated with nine-old increased risk of peripartum hysterectomy [1, 2, 3, 4].

According to our clinical experience, it is of most importance to identify LUSA as a clinical entity as its management differs from the management of corporeal uterine atony. In this paper original results about identification, diagnostics and surgical management of LUSA are being presented and analyzed.

Material And Methods

We have conducted a retrospective, clinical study during a ten years period (2010–2019) in our institution that is tertiary perinatal university center. Research was approved by Ethical Committee of our Hospital. Condition identified as LUSA PPH was diagnosed according to the clinical findings, accompanied by severe uterine bleeding – early PPH > 500 mL that persisted after administration of oxytocin (Syntocinon 5–10 IU in 500 mL of saline intravenously), uterostiptics (methyergometrine 0,2 mg iv., carboprost tromethamine 1–4 amp) and antifibrinolytic drug (tranexamic acid (TXA) 1–2 g iv) therapy. Clinical examination reveals well contracted fundus and upper uterine segment while lower uterine segment is being ballooned; heavy bleeding from the cervix is being identified and lacerations and ruptures in the lower genital tract are being excluded (Fig. 1.). Ultrasound reveals contracted fundus of the uterus and empty uterine cavity while within the dilated uterine segment coagula are identified (Fig. 2.). The primary treatment of hemorrhagic obstetric shock is control of the source of the bleeding as soon as possible and fluid replacement (crystalloids, colloids and blood transfusion). All procedures were performed in prolonged existing peripartum epidural analgesia or without anesthesia, because anesthesia is not necessary to perform these procedures.

We have collected and investigated data of perinatal interest like: age of the patient, parity, gestational age, comorbidity, course of the labor and delivery (induction of labor, spontaneous labor, fetal malpresentation, operative vaginal delivery), date about newborn (peripartal fetal hypoxia, gender, birth weight/length, Apgar score). Furthermore, we investigated different techniques of transvaginal surgical management of LUSA PPH: evacuation techniques (removal of retained placental tissues or coagula

manually or instrumentally), ligation techniques (Losickaja, Hebitsch-Huch, Habek) and compressive techniques (Gauze, balloon thamponade). Blood loss was closely monitored in order to identify the grade of obstetric hemorrhagic shock (grade III/IV with the loss of 2000–2500 mL of blood volume) and need for fluid replacement, (massive) blood transfusion and need for intensive care monitoring in the intensive care unit (ICU). We also evaluate the need for peripartum hysterectomy. We did not record any deaths associated with LUSA PPH. All analyzed results are presented in numbers and percentage in Table 1.

Table 1
Obstetric dana of lower uterine segment atony with postpartum hemorrhage

n = 44	**n**	**%**
Age	24–43 (32,18)	6.82%
Parity	1–5 (1,77)	6.82%
Gestational age	34–41 (39,3)	6.82%
Comorbidity during pregnancy	3	13.64%
Anaemia gestationis	3	
Hypertensia / preeclampsia	3	
Hypothyreosis	6	
Gestational diabetes mellitus (GDM)		
Birth	12	**27.27%**
Induction	2	4.55%
Vaginal birth after caesarean (VBAC)	10	**22.73%**
Preterm rupture of membrane (RVP) with stimulation	3	6.82%
Fetal malpresentation (occipitum dorsoposterior)	3	6.82%
Oligohydramnios	2	4.55%
Polyhydramnios	7	15,.91%
Vaginal assisted procedures	3	6.82%
Episiotomy	1	2.27 %
Vacuum extraction		
Shoulder dystocia management		

n = 44	n	%
Newborn	44	100%
Head praesentation	2	4.55%
Fetal intrapartal hypoxia	9–10 (9,95)	61,36%
Apgar score (1 min)	10 (10)	38.64%
Apgar score (5 min)	27	9.09 %
Female	17	
Male	2050–4480 (3563,23)	
Birth weight	4	
¬ *4000 g*	46–55 (51,43)	
Birth lenght		
Hemostatic surgical transvaginal procedures	5	11.36%
Uterine exploration	2	4.55%
Losickaja ligature	9	20.45%
Hebisch - Huch ligature	5	11.36%
Habek's haemostatic sutures	9	20.45%
Hebisch - Huch + Losickaja	4	9.09%
Uterine exploration + Hebisch - Huch	1	2.27%
Uterine exploration + Hebisch - Huch + gauze thamponade	1	2.27%
Uterine exploration et Hebisch - Huch + Balon thamponade	2	4.55%
Uterine exploration + Habek	1	2.27%
Uterine exploration + Habek + Balon thamponade	1	2.27%
Uterine exploration + Hebisch - Huch + Losiskaja	1	2,27%
Uterine exploration + Gauze thamponade	3	6.82%
Hebisch - Huch + Losickaja + Balon thamponade		
Shock hemorrhagicus	1	2.27%
Need for transfusion	21	47.72 %
- massive transfusion	1	2.22 %
Need for hysterectomy	0	
Intensive care unit management	6	13.63 %

Results

This particular study, conducted on our center conducted during 10 years period of time (2010–2019) enrolled total number of 29 543 deliveries with 215 cases of early PPH (0,72%). LUSA was diagnosed in 44 cases or in 29,93% in all uterine atony cases. We did not record LUSA PPH after cesarean delivery, but exclusively in vaginal births (and VBAC).

Average age of parturient women was 32,18 years, parity 1,77 and gestational age 39,3 weeks. Gestational diabetes was diagnosed in 6 cases, and in 3 cases hypertension with or without anemia was identified. In 50% of the all LUSA cases labor was stimulated after the premature rupture of membranes. In 3 cases oligohydramnios and in 2 polyhydramnios and vaginal birth after cesarean section (VBAC) were diagnosed. Episiotomy was performed 7 times during delivery, instrumental delivery (vacuum extraction) was conducted 3 times and releasing impacted shoulders in 1 case by different maneuvers (shoulder dystocia). All newborns were in vertex presentation, 3 in dorsoposterior occipital presentation. Due to the fetal hypoxia 2 newborns were delivered instrumentally (vacuum extraction). Apgar score of all newborns was ≥ 9/10 in the 1st and 5th minute. Statistically there were more female newborns. The was only 9% of babies that were large for gestational age (> 4000g).

Exploration of the lower uterine segment accompanied by evacuation of the coagula was conducted in 5 cases (11,36%), haemostatic ligation procedures according to authors: Losickaja in 2 cases, Hebisch-Huch in 9 cases, Habek in 5 cases, Hebisch-Huch + Losickaja in 9 cases. Evacuation procedures were combined with ligation techniques in 7 cases, evacuation methods with ligation techniques and balloon tamponade in 2 cases, exploration combined with gauze tamponade in 1 case and ligation procedures with balloon tamponade in 3 cases. According to our results, haemostatic ligation procedures alone or combined with tamponade, have shown to be highly effective in 88,63%.

There was just 1 case of severe obstetric hemorrhagic shock complicated with disseminated coagulopathy of 2nd grade that required massive transfusion. Total number of 21 patients (47,72%) were treated with blood transfusion and fresh frozen plasma due to obstetric hemorrhagic shock, but only 6 of them were stationed in ICU for intensive care and monitoring. We have not performed any transabdominal procedures including hysterectomy. We have not recorded any early or late postoperative complications like stenosis, lacerations or bleeding, progression in 3nd grade of coagulopathy and multiorgan failure.

Discussion

In the recent literature there are only 9 papers that are identifying LUSA as a special clinical entity and as a type of early PPH that requires different diagnostic and therapeutic approach to resolving PPH. It is interesting that old obstetric manuals have pointed out the problem of LUSA as well as very logical transvaginal approach to resolving it (tamponade of uterus and vagina according to Dührssen and Mange) [2, 5]. It should be mentioned that Losickaja has applied stitch of the posterior lip of the cervix in

the year 1965. as a method for resolving uterine atony [7], while Hebisch-Huch have established successful method of mechanical ligation of cervical braches of the uterine artery that are simultaneously contracted through the cervicohypotalamic reflex [13]. Balak and Kafali have reported their experience about haemostatic cervical suturing that controls site of the hemorrhage on the cervical lips and on the lower uterine segment, and was proven to be effective even in the cases of LUSA [14, 15]. Habek has recently presented his own compressive surgical technique of perpendicular inverted cervical sutures that was very effective in 9 cases of LUSA where it was used as a primary surgical method for preventing further development of PPH and obstetric hemorrhagic shock and eventually preserving fertility [9].

Introducing TXA into the algorithms of treating PPH has significantly lower maternal morbidity in the sense of the development of obstetric shock, coagulopathy and need for massive transfusions [16]. TXA was first introduced in Croatia in the year 2009 and algorithm for prophylactic use of TXA and treatment for early PPH was presented in our Clinic. In our textbook (Obstetric operations, Habek and cooworks) that was published in the year 2009 we have described different transvaginal surgical procedures applied for patients with uterine atony especially with LUSA: haemostatic ligation procedures (Losickaja, Hebitsch-Huch), tamponade (Menge, balloon/gauze (impregnated in carboprost or TXA) tamponade, Bakri balloon, Sengestaken-Blakemore tube). We believe that traction of the uterus towards vagina has certain impact that resembles so called Pringel maneuver by obstruction of circulation and decreasing the amount of haemorrhage. All of the mentioned methods are relatively simple and applicable especially because they are being performed vaginally [3].

Known risk factors for LUSA are: prolonged and precipitated delivery, polyhydramnios, fetal malpresentation or malposition (deflection of the fetal head), multiparity, low-lying placenta, VBAC, assisted reproduction, hysteroscopy, rarely LUSA may be caused by cervical and myometrial lacerations [2, 3, 5–7, 9–15]. In our research there were no significant maternal or fetal risk factors for developing LUSA, except of labor induction and labor stimulation. Induction of labor was present in 27,27% of cases, and 22,73% of labor were stimulated due to preterm rupture of membranes, what accounts for 50% of known peripartal risk factors. According to our results, induction or stimulation of labor was identified as an isolated risk factor for developing LUSA.

In recent papers, surgical treatment of LUSA was described by means of different methods like: curettage, embolisation, vaginal packing, bilateral cervix apex clamping, transvaginal cervicouterine artery ligation, double balloon tamponade, obstruction of vascularisation by means of uterine traction towards vagina, “holding the cervix” technique, “fishing for the balloon shaft” and perpendicular compressive cervical stitches and finally hysterectomy [6, 9, 10–23]. Panda et al. [6] in 2009. published very appreciable paper about clinical entity known as primary LUSA that should be clearly distinguished from corporeal uterine atony. 10 out of 16 described cases of LUSA were treated by curettage; uterine packing was applied in 3 cases, uterine artery embolisation as well in 3 cases and hysterectomy was performed in 1 patient. 8 patients (50%) required blood transfusion.

We would like to emphasize, that we have obtained similar results in our research; blood transfusion was administrated in 47,72% of patients, while only 1 patient required massive transfusion, as already noted. In more than 40% of cases we have successfully applied one or two combined ligation techniques (Hebitsch-Huch, Losickaja), followed by Habek modified compressive technique or compressive methods with balloon or gauze tamponade. We did not use curettage because we thought that we would damage the already damaged dilated surface of the cervix, we were guided by the philosophy of obstruction of circulation with ligatures and tamponade with therapy with uterotonics and tranexamic acid, to establish the missing mechanism of thrombo- and myotamponade.

Kafali and coworkers [15] have presented efficacy of applied haemostatic sutures in 3 cases of uncontrolled bleeding from the lower uterine segment. They have applied and compressed 2 longitudinal stitches through anterior and posterior cervical lip and obtained adequate hemostasis. Kavak has published 7 cases of LUSA, 5 out of 7 patients delivered by cesarean section; in all presented cases compressive method known as double cervical ripening balloon [17] while Seror et al. [11] reported successful use of Sengstaken Blakemore tube in the serial of 17 patients. In the year 2018 technique known as Matsubara-Takahashi was first introduced for achieving hemostasis in patients with placenta accrete spectrum (PAS) disorder and PPH. Matsubara-Takahashi technique was described as a cervix-holding technique (MT-holding) for achieving hemostasis for PPH in 50% of patients with PAS disorders and MT method had an overall success rate of 75% for PPH, comparable to other uterus sparing procedures [19]. Noninvasive procedure of bilateral cervix apex clamping (BCAC) first described by Jiang [21] was shown to be effective in cases of refractory PPH. In the total number of 13 359 vaginal deliveries, BCAC was performed in 44 cases (0,33%) with efficacy of 93,2%. Recent studies have shown good hemostasis accomplishment in the treatment of LUSA with the use of Chitosan gauze [12, 22]. Dueckelmann and coworkers [12] have presented results of their comparative study in the treatment of women with PPH with either uterine packing with chitosan covered gauze compared to balloon tamponade. The major reason for PPF was LUSA. In the group of patients treated with balloon tamponade postpartum hysterectomy was performed in 3 patients, while in the group of patients treated with uterine packing covered with Chitosan gauze there was no need for such a procedure. Therefore, authors according to their results, suggest the use of uterine packing covered with Chitosan gauze in the cases of LUSA, placenta previa bed bleeding and/or coagulopathy.

Transvaginal approach for surgical treatment of LUSA is accessible, feasible, successful and life saving. It can be easily performed in inpatient and outpatient care settings followed by administration of uterotonics, uterostiptics and TXA and fluid replacement. All of the above mentioned methods are of great importance in the prevention and treatment of severe PPH, obstetric hemorrhagic shock, development of coagulopathy, multiorgan failure, postpartum hysterectomy and finally vital for fertility preservation.

Conclusion

LUSA should definitely be identified and understood as a clinical entity. With proper medicamentous therapy transvaginal surgical procedures should be applied. We suggest evacuation of coagula from balonated cervix followed by haemostatic ligation methods (Hebitsh-Huch, Losickaja, Habek) that reduce the bleeding from the cervical blood supply and from the wide cervical surface. Tamponade balloon/gauze should be applied if bleeding persists. Above mentioned methods have shown to be highly effective for fertility preservation.

Declarations

Funding: None

Conflicts of interest/Competing interests: The authors declare that they have no conflict of interest.

Compliance with Ethical Standards: All ethical principles were respected

Authors Contribution: D Habek, M Prka, I Marton: Project development, Data Collection, Manuscript writing; M Prka, M. Vitić, AM Jurković: Data collection**;** D Habek, AT Luetić: Manuscript writing

Acknowledgments: None

References

1. Kallianidis AF, Maraschini A, Danis J et al (2020) Epidemiological analysis of peripartum hysterectomy across nine European countries. Acta Obstet Gynecol Scand 99:1364–1373. doi:10.1111/aogs.13892
2. Koller Th (1948) Lehrbuch der Geburtshilfe II. Karger Verlag, Basel
3. Habek D (2009) Surgical treatment od intrapartal and postpartal hemorrhage. In: Habek D (ed) Obstetrics operation. Medicinska naklada, Zagreb
4. Kainer F, Hasbargen U (2008) Emergencies associated with pregnancy and delivery: peripartum hemorrhage. Dtsch Arztebl Int 105:629–638. doi:10.3238/arztebl.2008.0629
5. Von Mikulitz Radecki (1950) Geburtshilfe des praktischen Arztes. Barth Verlag, Leipzig
6. Panda B, Laifer S, Stiller R, Kleinman G (2009) Primary atony of the lower uterine segment as a distinct cause of early postpartum haemorrhage: a case series and management recommendations. J Obstet Gynaecol 29:628–632. doi:10.1080/01443610903114493
7. Losickaja VA (1965) Primenenie poprečnogo šva na šeiku matki pri atoničeskinm krvorečenijan v ranem poslijerodoviom periode. Akush Gin Moskva 1;28
8. Logothetopulos K (1926) Eine absolut sichere Blutstillungsmethode bei vaginalen und abdominalen gynakologischen Operationen. Zentralbl Gynakol 50:3202–3204
9. Habek D (2021) Transvaginal perpendicular cervical waveforms sutures in treatment of early postpartum hemorrhage caused by lower uterine segment atony. Taiw J Obstet Gynecol (in press)

10. Yüksel H (2015) A novel approach to primary lower uterine segment atony. Taiwan J Obstet Gynecol 54:452–454. doi:10.1016/j.tjog.2014.05.010
11. Seror J, Allouche C, Elhaik S (2005) Use of Sengstaken-Blakemore tube in massive postpartum hemorrhage: a series of 17 cases. Acta Obstet Gynecol Scand 84:660–664. doi:10.1111/j.0001-6349.2005.00713.x
12. Dueckelmann AM, Hinkson L, Nonnenmacher A et al (2019) Uterine packing with chitosan-covered gauze compared to balloon tamponade for managing postpartum hemorrhage. Eur J Obstet Gynecol Reprod Biol 240:151–155. doi:10.1016/j.ejogrb.2019.06.003
13. Hebisch G, Huch A (2002) Vaginal uterine artery ligation avoids high blood loss and puerperal hysterectomy in postpartum hemorrhage. Obstet Gynecol 100:574–578. doi:10.1016/s0029-7844(02)02121-x
14. Balák K, Pokorný P (1984) Urgent (emergency) suture of the cervix for hemorrhage after childbirth. Cesk Gynekol 49:263–266. PMID: 6378399
15. Kafali H, Demir N, Soylemez F, Yurtseven S (2003) Hemostatic cervical suturing technique for management of uncontrollable postpartum haemorrhage originating from the cervical canal. Eur J Obstet Gynecol Reprod Biol 110:35–38. doi: 10.1016/s0301-2115(03)00104-0. PMID: 12932868
16. Li B, Miners A, Shakur H, Roberts I (2018) WOMAN Trial Collaborators. Tranexamic acid for treatment of women with post-partum haemorrhage in Nigeria and Pakistan: a cost-effectiveness analysis of data from the WOMAN trial. Lancet Glob Health 6:e222–e228
17. Kavak SB, Kavak E, Demirel I, Ilhan R (2014) Double-balloon tamponade in the management of postpartum hemorrhage: a case series. Ther Clin Risk Manag 10:615–620. doi:10.2147/TCRM.S62574
18. Grönvall M, Tikkanen M, Tallberg E, Paavonen J, Stefanovic V (2103) Use of Bakri balloon tamponade in the treatment of postpartum hemorrhage: a series of 50 cases from a tertiary teaching hospital. Acta Obstet Gynecol Scand 92:433–438. doi:10.1111/j.1600-0412.2012.01531.x. Epub 2012 Oct 17
19. Takahashi H, Ohkuchi A, Usui R, Suzuki H, Baba Y, Matsubara S (2018) Matsubara-Takahashi cervix-holding technique for massive postpartum hemorrhage in patients with placenta previa with or without placenta accreta spectrum disorders. Int J Gynaecol Obstet 140:357–364. doi:10.1002/ijgo.12390
20. Matsubara S, Baba Y, Takahashi H (2015) Preventing a Bakri balloon from sliding out during "holding the cervix": "fishing for the balloon shaft" technique (Matsubara). Acta Obstet Gynecol Scand 94:910–911. PubMed: 25620109
21. Jiang L (2019) Bilateral cervix apex clamping procedure can be used as a new noninvasive second line therapy for postpartum hemorrhage. Eur J Obstet Gynecol Reprod Biol 241:66–70 /j. ejogrb. 2019.08.005) :. doi: 10.1016
22. Carles G, Dabiri C, Mchirgui A et al (2017) Uses of chitosan for treating different forms of serious obstetrics hemorrhages. J Gynecol Obstet Hum Reprod 46:693–695. doi: 10.1016/j.

jogoh.2017.08.003
23. Wax JR, Channell JC, Vandersloot JA (1993) Packing of the lower uterine segment – new approach to an old technique. Int J Gynaecol Obstet 43:197–198

Figures

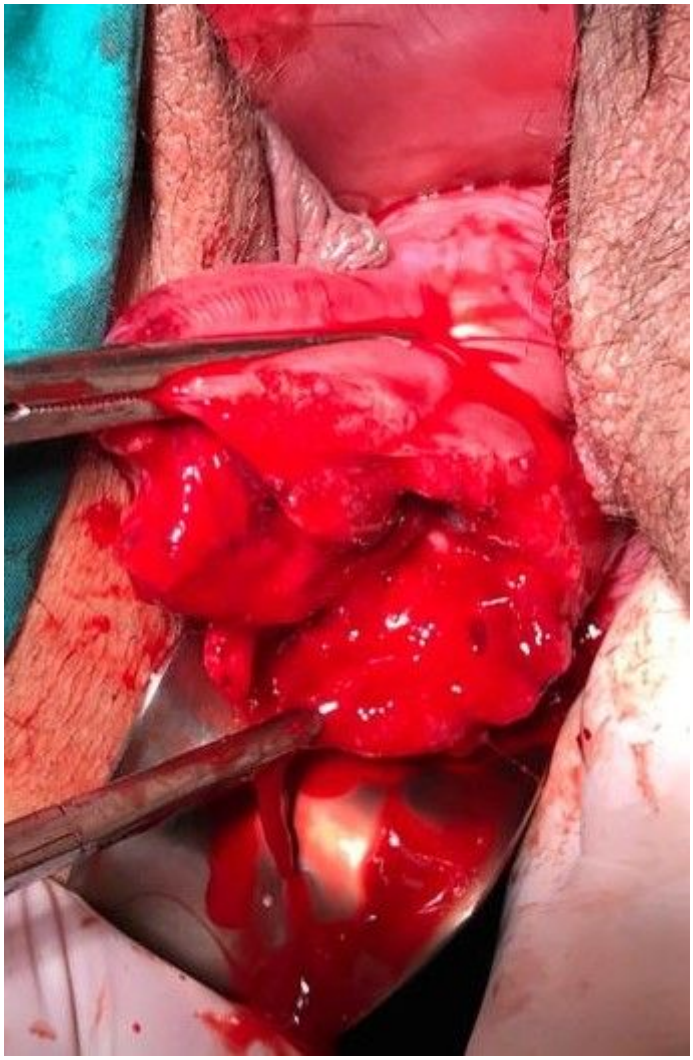

Figure 1

Lower uterine segmentatony

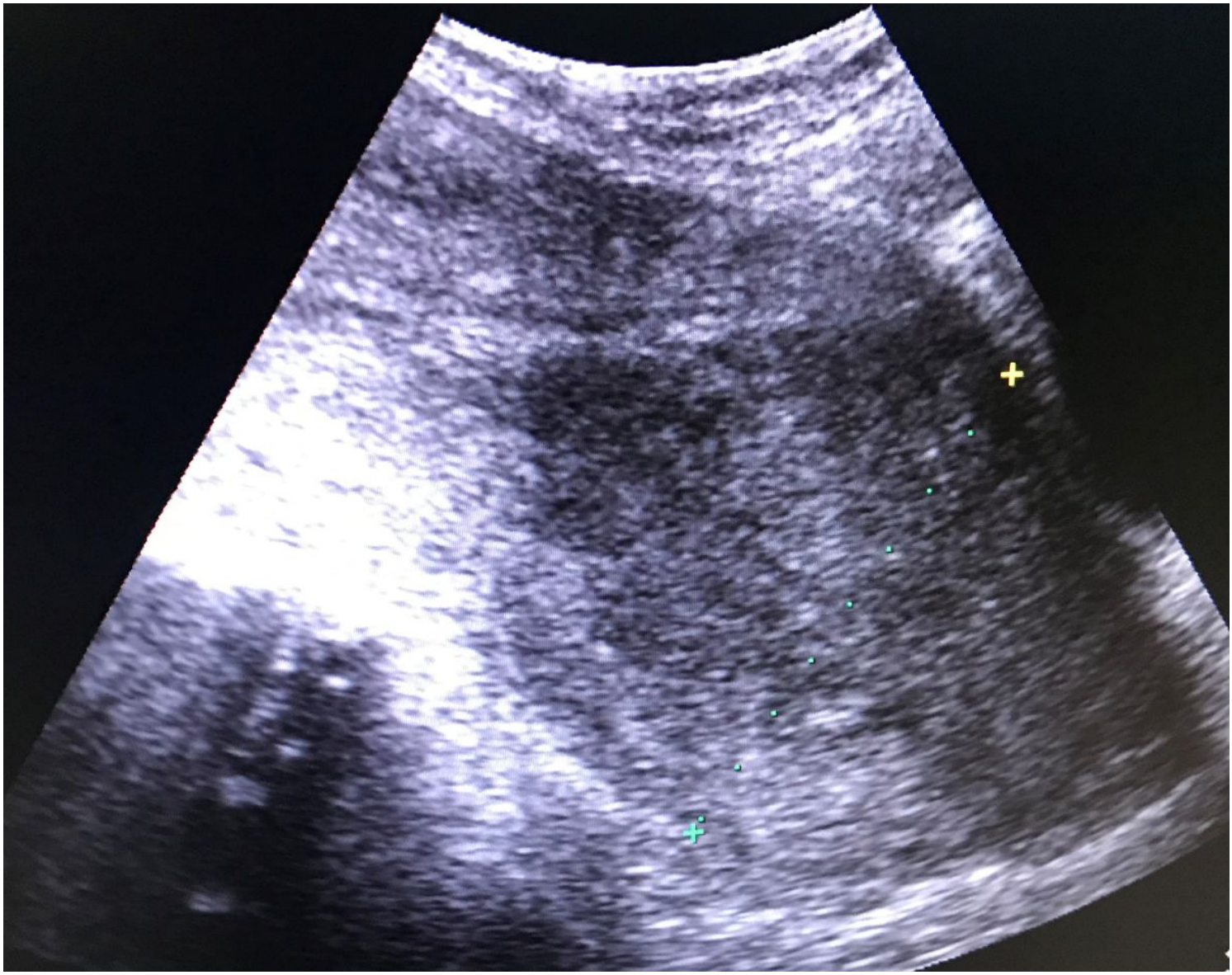

Figure 2

Ultrasound pictures of lower uterine segmentatony