Comparison of percutaneous vertebroplasty with a side-hole push rod and conventional percutaneous vertebroplasty for the treatment of OVCFs

Zhengshuai Jin
the Affiliated Jiangsu Shengze Hospital of Nanjing Medical University
Hailong Zhou
the Affiliated Jiangsu Shengze Hospital of Nanjing University
Xuefei Yan
the Affiliated Jiangsu Shengze Hospital of Nanjing Medical University
Chunming Wang
the Affiliated Jiangsu Shengze Hospital of Nanjing Medical University
Yuanqing Mao
the Affiliated Jiangsu Shengze Hospital of Nanjing Medicial University
Qiaolian Tao
the Affiliated Jiangsu Shengze Hospital of Nanjing Medical University
Jinfang Qian
the Affiliated Jiangsu Shengze Hospital of Nanjing Medical University
Jun Gu
the Affiliated Jiangsu Shengze Hospital of Nanjing Medical University
Sheng Chen (kyle18800@163.com)
the Affiliated Jiangsu Shengze Hospital of Nanjing Medical University https://orcid.org/0000-0002-1372-8741

Research article

Keywords: Percutaneous vertebroplasty, Percutaneous kyphoplasty, Osteoporotic vertebral compression fractures, Cement leakage rate, Cement distribution

Posted Date: June 5th, 2020

DOI: https://doi.org/10.21203/rs.3.rs-32093/v1

Abstract

Objective

The aim of this study was to compare the clinical efficacy of percutaneous vertebroplasty with a side-hole push rod (modified PVP) and conventional PVP in treating osteoporotic vertebral compression fractures (OVCFs).

Materials and methods

This study included 69 patients with 1-level OVCFs. Perioperative indicators, including the operative time, cement injection volume, cement leakage rate, and distribution of cement in the fractured area, were analysed. The visual analogue scale (VAS) and Oswestry disability index (ODI) were administered pre- and postoperatively.

Results

No significant differences were observed in the operative time or cement injection volume between the two groups ($p > 0.05$). The total diffusion score of bone cement in the PVP group was significantly lower than that in the modified PVP group ($p < 0.05$). Compared with the conventional PVP group, the modified PVP group had a significantly lower VAS score at 3 days postoperatively ($p < 0.05$). There were no differences in the VAS or ODI scores between the two groups at the last follow-up ($p > 0.05$). Bone cement leakage was observed in 15 cases in the conventional PVP group (15/32) and in 9 cases in the modified PVP group (9/37).

Conclusion

The modified version of PVP provides sufficient cement to fill the fractured area and is associated with a lower incidence of cement leakage and undesired postoperative results than is conventional PVP, indicating that modified PVP is a safe and effective new technique for the treatment of OVCFs.

Introduction

Osteoporotic vertebral compression fractures (OVCFs), caused by osteoporosis, have been shown to decrease quality of life (QOL)[1, 2]. In addition, OVCFs lead to disability and a heavy burden on society[3]. At present, there are three main types of clinical treatments for OVCFs: conservative treatment, surgical treatment, and minimally invasive treatment[4]. Today, surgeons prefer minimally invasive therapies, and minimally invasive therapies will become the prevailing treatment for OVCFs due to its advantages, including a smaller incision, a shorter treatment time, less blood loss, less severe pain, a shorter recovery time, and a shorter duration of hospitalization[5].

Galibert was the first to propose percutaneous vertebroplasty (PVP) [6] to treat vertebral angioma, and it is now commonly used to treat OVCFs and spinal tumours. Percutaneous kyphoplasty (PKP) is a modified version of PVP that was developed after Reiley invented inflatable bone tamps. These two minimally invasive surgical techniques are the techniques that were most commonly used in the past ten years, and they demonstrated remarkable clinical efficacy[7].

PVP, wherein cement is injected by a horizontal pressure, is the optimal treatment for OVCFs. However, the application of this surgical treatment remains controversial because the cement cannot be spread to the margins using a catheter, as this would result in a high risk of cement extravasation and recurrence of fractures. Accordingly, there are many scholars who have introduced modified versions of PKP or PVP. For example, Yimin et al. proposed a new method of PKP[8]. The difference between the modified PKP and traditional PKP techniques is mainly that in the improved PKP technique, balloon deflation did not occur during contralateral bone cement infusion. Compared with PKP, modified PKP prevents the loss of (prevents a decrease in) vertebral height, which occurs in PKP during balloon deflation, yielding a taller vertebral height, improved Cobb angle correction, and improved QOL in patients with OVCFs. Zhu et al. attempted to compare whether the addition of

mineralized collagen polymethyl methacrylate (PMMA) into bone cement during the treatment of OVCFs with PKP can improve clinical prognoses and imaging outcomes[9].

In our study, we designed a new side-hole push rod for PVP. The modified version of PVP is similar to traditional PVP, except that the front of the joystick used in modified PVP is sealed off, and a side groove is inserted. To help spine doctors understand the modified version of PVP, we further explored the clinical application of traditional PVP and modified PVP in the treatment of OVCFs. Therefore, we conducted this study to systematically evaluate the clinical safety and effectiveness of traditional PVP and modified PVP in treating OVCFs.

Materials And Methods

Ethical approval

This study was approved by the local institutional ethics committee. All patients signed an informed consent form.

Clinical data

A total of 69 patients with a single OVCF were treated at the Affiliated Jiangsu Shengze Hospital of Nanjing Medical University (Jiangsu, China) from December 2015 to March 2018. Thirty-seven patients underwent PVP with a side-hole push rod (modified PVP group), while the remaining 32 patients were treated with conventional PVP (conventional PVP group). The inclusion criteria were as follows: (1) an age of ≥ 65 years; (2) a fresh single vertebral fracture; (3) bone density examination results suggesting T < −2.5; and (4) the absence of surgical contraindications (infection, coagulation abnormality, etc). The exclusion criteria were as follows: (1) two or more vertebral fractures; (2) high-energy injuries with canal stenosis requiring internal pedicle fixation; (3) secondary osteoporosis; (4) rheumatoid arthritis; (5) a history of hormone therapy for more than 3 months; (6) a pathological fracture caused by a malignant tumour; and (7) severe cardiopulmonary dysfunction resulting in the inability to tolerate the surgery. The same surgical team performed this operation, and two surgeons performed the bilateral PVP procedure. The two groups underwent the same perioperative-related measurements, regardless of the differences in surgical treatments. The ethics committee affiliated with Nanjing Medical University approved the study. All enrolled patients were required to provide written informed consent for publication of their data.

Surgical techniques

Conventional PVP

The OVCF patients underwent surgical treatment according to the following procedure: after anaesthesia was induced, the patient remained in a prone position so that the injured vertebra could be treated. The fracture site was marked. The fractured vertebra was identified by C-arm fluoroscopy. According to the surface projection of the pedicle, the puncture point was identified. With C-arm fluoroscopy, the puncture sleeve was drilled to be parallel with the upper and lower edges of the pedicle and positioned slightly forward and downward so that the tip of the puncture sleeve reached 1/3 of the anterior and lower parts of the vertebral body from the lateral perspective and was positioned between the pedicle and the spinous process from the positive perspective. When the bone cement had a “toothpaste-like” appearance, a straight-mouth push rod was used to gradually inject the bone cement from the front to the back.

Modified PVP

All patients were anaesthetized, positioned and punctured in the same way as the patients in the conventional PVP group. When the tip of the puncture sleeve reached the operating position from the positive and lateral perspectives, we used a side-hole push rod to centre the fracture area, rotated the side-hole push rod and injected bone cement gradually from the top to the nonfracture area above and below the fracture area.

Clinical and radiological measurements

In the clinical evaluation, the following information was recorded: patient age, gender, BMI, BMD, operation segment, operative time, bone cement injection volume, and VAS and ODI scores (which were collected by the surgeons for analysis). BMI was calculated as the patient's weight in kilograms divided by the square of his or her height in metres; dual energy X-ray absorptiometry was used to determine the lumbar BMD (T value). We invited all participants to attend follow-up clinical evaluations at 3 days, 1 month and 1 year after the operation. The follow-up period was at least 1 year. The visual analogue scale (VAS) and ODI scores were recorded at each follow-up. The presence of bone cement leakage and the cement distributions were evaluated by CT scans. According to the diffusion scoring standard for bone cement used by Sun et al.[10], the bone cement distribution was considered (1) excellent (3 points) when the distribution of bone cement in the vertebral body was more than 75% and the cement was near the upper and lower endplates; (2) good (2 points) when the distribution of bone cement in the vertebral body was 50% - 75%; (3) moderate (1 point) when the distribution of bone cement in the vertebral body was 25% - 50%; and (4) poor (0 points) when the distribution of bone cement in the vertebral body was less than 25%. The total diffusion score of bone cement was calculated as the sum of the diffusion scores of the sagittal bone cement, coronal bone cement, and transverse bone cement. The total score ranged between 0 and 9; 9 points indicated good dispersion, and less than 9 points indicated poor dispersion. All analyses were performed in the picture archiving and communication system (PACS) independently and objectively to minimize bias.

Statistical analysis

SPSS 23.0 (SPSS Inc., Chicago, IL, USA) was used to analyse the data. The measurement data are expressed as the means ± standard deviations. The enumeration data are represented by the rates and were analysed by the Chi-square test. A p-value of $p< 0.05$ was considered to indicate a statistically significant difference.

Results

A total of 69 patients were divided into two groups by the treatment they underwent. The results for age, gender, BMI, BMD, and T-score are shown in Table 1. No obvious differences were observed between the groups ($p > 0.05$). The operation segment is shown in Table 2. The operative times in the PVP group and modified PVP group were 43.16±4.33 min and 42.92±4.93 min, respectively. There were no statistically significant differences between the two groups ($p > 0.05$). The cement injection volumes in the PVP group and modified PVP group were 5.63±1.88 ml and 6.00±1.89 ml, respectively. There were no statistically significant differences between the two groups ($p > 0.05$). The total diffusion score of bone cement in the PVP group (5.66±0.19 points) was significantly lower than that in the modified PVP group (7.89±0.52 points) ($p < 0.05$). These data are shown in Table 3.

The VAS and ODI scores are shown in Table 4, and these two indexes were used to evaluate pain relief and functional recovery. All patients exhibited significant pain relief postoperatively compared with preoperatively ($p < 0.05$). The results indicated that the two treatments had the same effect with regard to pain relief. In addition, the long-term follow-up results indicated that even after 1 year, the VAS score and ODI score of the two groups did not change significantly ($p> 0.05$). However, compared with the conventional PVP group, the modified PVP groups showed a significantly lower VAS score at 3 days postoperatively ($p < 0.05$).

With these surgeries, there is a risk of several severe complications, such as pulmonary embolism, spinal stenosis, spinal cord compression, and nerve injury. However, in this study, no complications were observed. Bone cement leakage was observed in 15 cases in the conventional PVP group (15/32) and in 9 cases in the modified PVP group (9/37). The patients with bone cement leakage did not show obvious clinical symptoms.

Table 1. The demographic data of the patients in two groups.

Group	Modified PVP	PVP	P-value
N	37	32	
Age(year)	74.38±6.78	72.38±7.12	0.24
Male/Female	17/20	14/18	0.56
BMI（Kg/m^2）	21.75±2.41	21.11±2.08	0.25
BMD	-3.77±0.68	-3.91±0.73	0.41

Table 2. The operation segment data of the patients in two groups.

Distribution of injured vertebral	Modified PVP	PVP
T11	7	5
T12	11	8
L1	10	8
L2	3	5
L3	2	3
L4	4	3
Total	37	32

Table 3. The clinical data of the patients in two groups.

Group	Operating Time	cement injection volume	The total diffusion score of bone cement
PVP	43.16±4.33	5.63±1.88	5.66±0.19
Modified PVP	42.92±4.93	6.00±1.89	7.89±0.52
P	0.84	0.41	0.00*

*There were significant differences(P<0.05) between the two groups

Table 4. Postoperative VAS and ODI scores of the modified PVP and conventional PVP groups.

Group	VAS*				ODI*			
	Pre	3d	1m	1y	pre	3d	1m	1y
PVP	7.54±0.90	2.66±0.67	2.16±0.60	1.41±1.12	74.22±9.24	26.05±7.25	23.57±6.99	21.84±6.66
Modified PVP	7.38±1.01	2.00±0.94	2.13±0.66	1.31±0.90	72.19±8.51	24.44±7.23	23.81±7.68	20.88±6.04
P	0.47	0.00*	0.81	0.71	0.35	0.36	0.89	0.96

*There were significant differences(P<0.05) between

Declarations

With the extension of life expectancy and ageing of the general population, osteoporosis has become a significant health problem. Osteoporotic fractures are severe consequences of osteoporosis. Among osteoporotic fractures, vertebral compression fractures have the highest incidence[11]. The current treatment methods for OVCFs include conservative treatment and surgical treatment. Conservative treatment for patients with long-standing back pain is not very clinically effective[12]. PVP has been recommended for patients with compression fractures who have pain and are not satisfied with the conservative treatment results[13]. The conventional PVP technique relies on the injection of bone cement due to external pressure to open the vertebral body. The injected bone cement cannot reach the cavity in different directions, which easily causes bone cement leakage[14]. The success rate of PVP in the treatment of OVCFs is 89% - 93%, as reported in the literature[15].

In 1997, Jensen et al. described a PVP technique involving a puncture and catheterization based on the surface projection of the pedicle[16]. With C-arm fluoroscopy, the puncture sleeve was drilled to be parallel to the upper and lower edges of the pedicle and positioned slightly forward and downward so that the tip of the puncture sleeve reached the anterior and inferior 1/3 sections of the vertebral body under lateral fluoroscopy. Clearly, this kind of puncture ultimately leads to the bone cement injection point being fixed at the anterior and lower parts of the vertebral body, but the fracture areas are not the same across patients. Clinically, it can be observed that the fracture areas in patients with OVCFs can involve the upper, middle or lower parts of the vertebral fracture body, two of these parts, or even three of these parts at the same time; when using straight-mouth push rods, it is difficult to disperse the amount of bone cement recommended by studies in the literature in the fracture area, which is located relatively far away from the point of injection of the bone cement[17]. Thus, conventional PVP can lead to insufficient dispersion of bone cement in the fracture area in some patients. It has been reported that the clinical effect of PVP is directly proportional to the degree of diffusion of bone cement[18, 19].

To optimize the PVP technique, we improved the push rod used in PVP. With the modified PVP technique, the direction of the puncture needle is adjusted under fluoroscopy during the operation so that the tip of the puncture trocar, namely, the bone cement injection point, is positioned as close as possible to the plane of the fracture area. At the same time, a side-hole push rod was used to control the direction in which the bone cement was injected, and the fracture area was taken as the centre to inject bone cement into the nonfracture area above and below the fracture area. The modified PVP technique can diffuse bone cement well in the cancellous bone space of the vertebral body, serving as an anchor and providing improved stability. Molloy et al. observed that the filling rate of bone cement in a fractured vertebral body was significantly positively correlated with the stiffness of the vertebral body[20].

This study showed that there were no significant differences in intraoperative bone cement injection results between conventional PVP and modified PVP. Compared with conventional PVP, modified PVP can lead to the cement being filled in the fracture area more accurately. The cement was dispersed better in the cancellous bone space of the nonfracture area. In addition, the leakage rate of bone cement in the modified PVP group was only 24.3%, which was significantly lower than that in the control group (46.9%). Zhu et al. concluded that the leakage rate of PVP bone cement reached 58.2%[21]. According to the relevant literature, the leakage rate of bone cement in conventional PVP surgery is 30%~70%, and 66% of postoperative complications are related to the leakage of bone cement[22]. The full dispersion of bone cement can reduce the amount of leakage of bone cement, which also shows that the modified PVP technique could reduce the amount of leakage of bone cement to a certain extent. There were no cases of bone cement leakage to the posterior edge of the vertebral body or spinal canal. On postoperative day 3, the VAS score of the modified PVP group was better than that of the conventional PVP group, which may be because the bone cement can diffuse better in the fracture line, leading to fixation of the fractured bone trabeculae, a reduction in the micromotion of the fracture end, an improvement in the immediate stability of the postoperative vertebral body, a reduction in the stimulation of the nerve endings and, thus, pain relief.

In this study, the sample sizes of the groups are limited, which may cause deviations in the parameter measurements. Despite the above limitation, we found that modified PVP is safe and effective in the treatment of OVCFs, according to the values of

relevant parameters. Compared with the traditional technique, the modified technique can lead to the sufficient diffusion of bone cement, a smaller amount of bone cement leakage, and better short-term effects. However, additional data must be collected and additional statistical analyses conducted to determine the long-term efficacy.

Conclusions

Our results indicated that conventional PVP and modified PVP have the same clinical results in OVCFs treatment. In addition, modified PVP can provide better filling effect and lower incidence of cement leakage, which is a safe and effective new technique for the treatment of OVCFs.

Abbreviations

Percutaneous vertebroplasty (PVP); Osteoporotic vertebral compression fractures (OVCFs); Visual analogue scale (VAS); Oswestry disability index (ODI); Quality of life (QOL); Percutaneous kyphoplasty (PKP); Polymethyl methacrylate (PMMA); Body mass index (BMI); Bone mineral density (BMD); Computed tomography (CT); Picture archiving and communication system (PACS).

Declarations

Ethics approval and consent to participate

This experiment was approved by the ethics committee of the affiliated Jiangsu Shengze hospital of Nanjing Medical University, and data collection and analysis were completed under the guidance of the committee.

Consent for publication

We have finished the form.

Availability of data and materials

The datasets generated and/or analysed during the current study are not publicly available due to this research results will be used to apply NFSC project but are available from the corresponding author on reasonable request.

Competing interests

The authors declare that they have no competing interests

Funding

This research was supported by grants from Suzhou Science and Technology Bureau Science and Technology Livelihood Project 2018(SS201850), Suzhou key subject (SZXK201824) and Wujiang District Science and Education 2017 and 2018(wwk201709, wwk201820).

Authors' contributions

All authors were involved in writing the manuscript. Zhengshuai Jin, Hailong Zhou and Xuefei Yan collected data under the guidance of Sheng Chen. Chunming Wang and Yuanqing Mao analyzed the image results. Qiaolian Tao,Jinfang Qian and Jun Gu performed the statistical analysis. All authors read and approved the final manuscript.

Acknowledgements

Not applicable.

References

1. Ström O, Borgström F, Kanis JA, Compston J, Cooper C, Mccloskey EV, Jönsson B: Osteoporosis: burden, health care provision and opportunities in the EU A report prepared in collaboration with the International Osteoporosis Foundation (IOF) and the European Federation of Pharmaceutical Industry Associations (EFPIA). *Archives of Osteoporosis* 2011, 6(1-2):p.59-155.
2. Karmakar A, Acharya S, Biswas D, Sau A: Evaluation of Percutaneous Vertebroplasty for Management of Symptomatic Osteoporotic Compression Fracture. *Journal of Clinical & Diagnostic Research* 2017, 11(8):RC07-RC10.
3. Harvey N, Dennison E, Cooper C: Osteoporosis: impact on health and economics. *Nature Reviews Rheumatology* 2010, 6(2):99-105.
4. Yang E-Z, Xu J-G, Huang G-Z, Xiao W-Z, Liu X-K, Zeng B-F, Lian X-F: Percutaneous Vertebroplasty Versus Conservative Treatment in Aged Patients With Acute Osteoporotic Vertebral Compression Fractures. *Spine* 2016, 41(8):653-660.
5. Gerard, Wen, Wei, Ee, Jiang, Lei, Chang, Ming, Guo, William: Comparison of Clinical Outcomes and Radiographic Measurements in 4 Different Treatment Modalities for Osteoporotic Compression Fractures: Retrospective Analysis. *Journal of Spinal Disorders & Techniques* 2015.
6. Galibert P, Deramond H, Rosat P, Le GD: [Preliminary note on the treatment of vertebral angioma by percutaneous acrylic vertebroplasty]. *Neurochirurgie* 1987, 33(2):166-168.
7. Lavelle W, Carl A, Lavelle ED, Khaleel MA: Vertebroplasty and Kyphoplasty. *Medical Clinics of North America* 2007, 91(2):299-314.
8. Qi Y, Zeng Y, Jiang C, Liang B, Sui J, Zhao L, Wang D: Comparison of Percutaneous Kyphoplasty Versus Modified Percutaneous Kyphoplasty for Treatment of Osteoporotic Vertebral Compression Fractures. *World Neurosurgery* 2018.
9. Zhu J, Zhang K, Luo K, Qiu Z, Yang S, Cui F, Weng X, Jiang G: Mineralized Collagen Modified Polymethyl Methacrylate Bone Cement for Osteoporotic Compression Vertebral Fracture at 1-Year Follow-up. *Spine* 2019, 44.
10. Min Z, Li YQ, Wang XD, Li HB, Zhang JH, Orthopaedics DO: Relationship between bone cement dispersion within pathologic vertebrae and fracture time in vertebroplasty. *Chinese Journal of Tissue Engineering Research* 2015.
11. Ho-Joong K, Saejong P, Soo-Hyun P, Jiwon P, Chang BS, Choon-Ki L, Yeom JS: Prevalence of Frailty in Patients with Osteoporotic Vertebral Compression Fracture and Its Association with Numbers of Fractures. *Yonsei Medical Journal* 2018, 59(2):317-.
12. Cheng X, Long HQ, Xu JH, Huang YL, Li FB: Comparison of unilateral versus bilateral percutaneous kyphoplasty for the treatment of patients with osteoporosis vertebral compression fracture (OVCF): a systematic review and meta-analysis. *European Spine Journal* 2016, 25(11):3439-3449.
13. Mcgraw JK, Cardella J, Barr JD, Mathis JM, Sanchez O, Schwartzberg MS, Swan TL, Sacks D: Society of Interventional Radiology Quality Improvement Guidelines for Percutaneous Vertebroplasty. *Journal of Vascular & Interventional Radiology Jvir* 2003, 14(7):827-831.
14. Gupta, Sanjay: Intra-Arterial Liver-Directed Therapies for Neuroendocrine Hepatic Metastases. *Semin Intervent Radiol* 2013, 30(01):028-038.
15. Mcconnell CT, Wippold FJ, Ray CE, Weissman BN, Angevine PD, Fries IB, Holly LT, Kapoor BS, Lorenz JM, Luchs JS: ACR Appropriateness Criteria Management of Vertebral Compression Fractures. *Journal of the American College of Radiology* 2014, 11(8):757-763.
16. Jensen ME: Percutaneous polymethylmethacrylate vertebroplasty in the treatment of osteoporotic vertebral body compression fractures : technical aspects. *Ajnr Am J Neuroradiol* 1997, 18(10):1897-1904.
17. Chen YJ, Chen HY, Lo DF, Chen HT, Hsu HC: Kirschner wire-guided technique for inserting a second needle into inadequately filled vertebrae in vertebroplasty: a technical report. *Spine Journal* 2014, 14(12):3025-3029.
18. Lee HH, Chao KH, Wang SJ, Wu SS: The Timing of Vertebroplasty in the Treatment of Painful Osteoporotic Vertebral Compression Fractures. *Journal of Medical Sciences* 2004, 24(3):129-134.

19. Santiago F, Kelekis A, álvarez L, Filippiadis D: Interventional Procedures of the Spine. *Seminars in Musculoskeletal Radiology* 2014, 18(03):309-317.
20. Molloy S, Mathis JM, Belkoff SM: The Effect of Vertebral Body Percentage Fill on Mechanical Behavior During Percutaneous Vertebroplasty. *Spine* 2003, 28(14):1549-1554.
21. Zhu SY, Zhong ZM, Wu Q, Chen JT: Risk factors for bone cement leakage in percutaneous vertebroplasty: a retrospective study of four hundred and eighty five patients. *International Orthopaedics* 2016, 40(6):1205-1210.
22. Hulme PA, Krebs JR, Ferguson SJ, Berlemann U: Vertebroplasty and Kyphoplasty: A Systematic Review of 69 Clinical Studies. *Spine* 2006, 31(17):1983-2001.

Figures

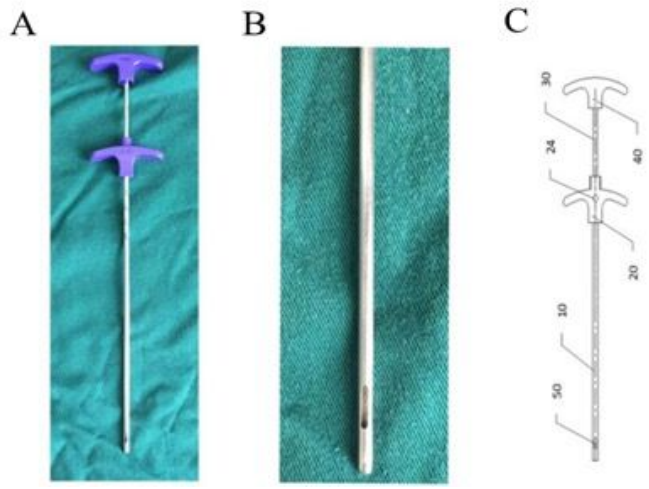

Figure 1

Instruments used in modified PVP. (A) General graph of the modified facility. (B) Enlarged graph showing the details of the instrument. (C) Components of the instrument.

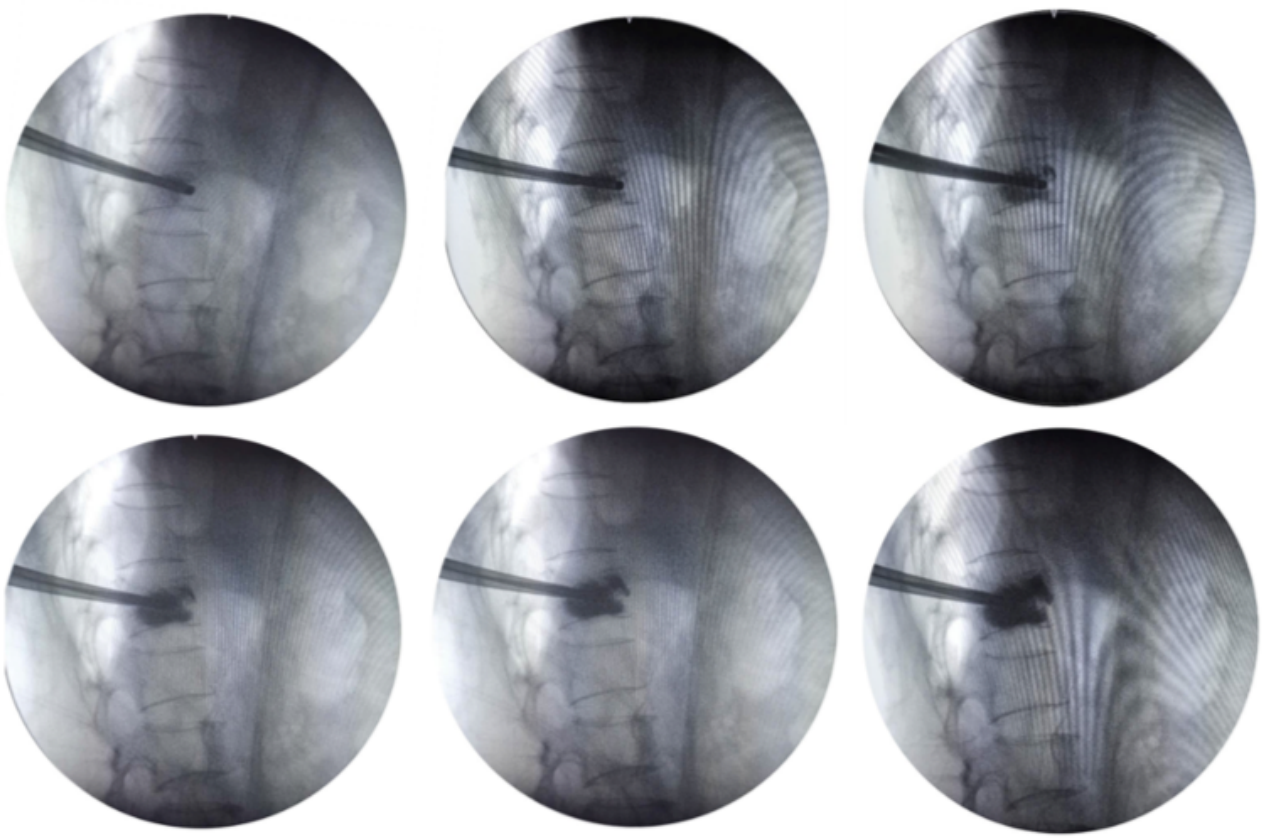

Figure 2

Modified PVP instrumentation: When the side hole of the push rod is facing upward, the cement mainly disperses to the upper part of the vertebral body, and when it is facing downward, the cement mainly disperses to the lower part of the vertebral body. The fracture area and surrounding nonfracture area are sufficiently filled with cement.