Tooth Extraction is Risk Factor for Maxillary Sinus Pneumatization : A Case Control Study

Hakan Ocak
Private Practice

Halis Ali Çolpak (halisalicolpak@gmail.com)
Alanya Alaaddin Keykubat University

Umut Demetoğlu
Aydın Adnan Menderes University

Damla Soydan
Erciyes University

Erdem Kılıç
Bezm-i Alem Vakıf University

Murat E Canger
Erciyes University

Alper Alkan
Bezm-i Alem Vakıf University

Research article

Keywords: sinus pneumatization, teeth extraction, posterior maxillary, radiographic assessment

Posted Date: August 9th, 2019

DOI: https://doi.org/10.21203/rs.2.12521/v1

Abstract

Purpose Maxillary sinus pneumatization following teeth extraction may require various treatment plans such as sinus lifting and alveolar grafting procedures to obtain sufficient alveolar bone height for implant surgery. The aim of this study was to identify sinus pneumatization and to help in determining the proper time for preprosthetic surgery following extraction of maxillary sinus related teeth. Methods We evaluated 75 teeth extraction related to maxillary sinus floor. The panoramic radiographs were evaluated before and after extraction of the posterior maxillary teeth. The radiographs were divided into 5 groups according to duration after extraction. Two reference points (the first point corresponds to the nasal spine while the second point corresponds to the most inferior point of the floor of the maxillary sinus wall) were determined on digital panoramic radiographs before and after teeth extraction and the distance between both aforementioned points was measured. Results The amount of pneumatization was found to be increased with time. The pneumatization within the first 6 months was limited. However, a sudden increase of pneumatization after 6th month, especially the highest between 18th and 24th months, was observed. The mean pneumatization amount was found to be highest in the 1st molar group. Conclusion According to the results of the present study, surgeons should not be waited any more than 6 months after tooth extraction for preprosthetic surgery in the posterior maxillary region as long as physiological healing of extraction socket is allowed.

Background

Currently, dental implant supported protetic treatment is most common prosedure for lack of teeth. However, due to pneumatization and severe alveolar bone ridge vertical problems related sinus floor, the implants could not be implemented. Although various treatment plans such as sinus lifting or bone grafting procedures to increased alveolar bone height for implant surgery, it is more importtant to understand that correlation between process of sinus pneumatization and related factors [1].

Maxillary sinus has the largest volume in all paranasal sinuses. It continues to pneumatize until the permanent teeth erupt in alveolar bone after birth. Pneumatization is a physiologic process that leads to an increase in the volume of paranasal sinuses during the growth term [2,3]. It is known that the maxillary sinus floor reaches the same level with the nasal floor in age at 12–13. Maxillary sinus pneumatization ends after the third molar eruption. Pneumatization period appears on the osteoid layer with osteoclastic resorption of the cortical walls of the sinus in histological studies [4].

The biologic process of the sinus is not clearly understood. Previous studies reported that heredity [5], the pressure of the mucous membrane of the nose [3], craniofacial settlement, bone density, growth hormones [2], the air pressure in the sinus [1] and the sinus surgery [6] may play an effective role in this process.

Although, the clinicans and researchers presume that the sinus pneumatization releavent to maxillary teeth extraction is common knowledge, there are only a few radiographic studies in the literature that

investigate changes in the maxillary sinus floor level in relation to the other anatomic structures before and after removal of the tooth [2,4,7–9]. This phenomenon was described with some ways such as disuse atrophy and the decrease of functional forces transferred to the bone after tooth loss causes a shift in the remodeling process toward bone resorption [2,4] so the sinus volume expanded towards to the edentulous alveolar ridge. The rate and degree of the pneumatization after removal of the teeth may be affected by; Roots extend into the sinus have a thin cortical bone layer [2,4]. This thin bone may break and dislocate during extraction, so the sinus may expand toward the socket. And also, larger pneumatization has occurred after molar extraction [7].A larger defect can be observed in the alveolar bone after molar extraction, so this requires a longer healing time, to allow the sinus to pneumatize.

Cone-beam Computed Tomography (CBCT) is a current diagnostic tool which provide three-dimensional (3D) images and detailed sections for evaluating relation between margin of the alveolar bone and the maxillary sinus floor status [1]. However, there is lack of studies using CBCT scans to analyze sinus floor pneumatization in edentulous posterior maxilla. Additionally, in order to obtain correct knowledges of conventional panoramic evaluation is still curical for private clinics at the first stage of many health system of countries which dont use CBCT.

The purpose of this study was to evaluate the maxillary sinus pneumatization in relation to tooth extraction according to time, type of tooth and the other factors with using reference lines and landmarks on panoramic view. Also, it was aimed to identify an ideal time for bone grafting or implant treatment procedures and to determine the possible need for sinus lifting procedures.

Methods

The participants were patients who underwent at least one premolar or molar tooth extraction associated with the sinus membrane in Erciyes University Faculty of Dentistry Department of Oral and Maxillofacial Surgery. The informed consent form was taken from all patients by the written. Panoramic radiographs which were taken before and after extractions were assessed (Cliniview Dental Imaging Programme Cliniview, Finland). A total of 128 panoramic films of 42 patients (19 female, 23 male) were examined. The ages of participanrs were between 46 and 70 years old. A total of 75 extractions (5 premolars, 27 first molars, 33 second molars, 10 third molar) were performed. Patients were divided into 5 groups according to follow-up time between the first and second radiological examination. The follow-up periods and the number of patients for each group were shown in Table 1.

Follow-up period is at least 1 day up to 2 years. Two reference point was selected on the panoramic films and the amount of pneumatization is calculated by measuring the distance between these two reference points using the Cliniview Software Programme(Cliniview, Finland). The first reference point was a parallel line to the Frankfurt horizontal plane which is passed from the most superior point of the anterior nasal spine. The second reference point was a parallel line to the Frankfurt horizontal plane which is passed from the most inferior point of the sinus *(Figure 1).*

The distance between these two points is regarded as the amount of sinus pneumatization *(Figure 2).* For the determination of the amount of magnification from the panoramic films taken before and after the extractions, the distance between the parallel line the Frankfurt horizontal plane which is passed the top of the crown and the apex of the root of the canine or premolar tooth was calculated. In edentulous patients, the distance between the top and the bottom of the metal ball in the panoramic radiographs was measured and amount of magnification was calculated by use of a simple ratio and this ratio was performed on the post-extraction radiographs to calculate the amount of the actual pneumatization *(Figure 3).* The average amount of pneumatization was calculated by dividing the obtained total amount of pneumatization from each group to the number of subjects.

Statistical analysis

The data analysis was performed with SigmaPlot 12.0 programme..The Shapiro-Wilk analysis test was used for data coherence to the normalized range. Mann-Whitney *U*-test was performed for the comparison between the sinus pneumatization pre-extraction and postextraction sites according to gender. The Kruskal-Wallis one direction variance analysis was used for tooth type, time periods and multiple tooth extraction *(Figure 4,5,6).* In all analyses, a significance level of $p<0,05$ was used.

Results

The amount of pneumatization obtained from the subjects in 5 different time interval groups was recorded. The average amount of pneumatization, the maximum and minimum amounts of pneumatization and the tooth number caused the pneumatization after the extraction are given *(Table 2).* The amount of pneumatization was increased with the follow-up time, in the first 6 months the sinus pneumatization was limited, after 6 months pneumatization was suddenly increased and between the 18–24 months, the amount of pneumatization was maximum.

The maximum amount of pneumatization was 6 mm. It was observed after the extraction of the first molar. The average amount of pneumatization according to the tooth type is given *(Table 3).* The amount of pneumatization was increased after the extractions of infected root and the molar teeth which curvingly lifted the sinus membrane by their roots.

Discussion

Dental implant installation in upper posterior region, an accurate diagnosis and a better understanding of bone remodeling at the area may be more valuable for a optimum treatment planning. Currently, Cone-beam Computed Tomography (CBCT) is a common diagnostic tool which support three-dimensional (3D) images and thin detailed sections in order to asses relation between maxillary sinus floor and alveolar bone ridge. Although it reduces the overlapping of anatomical structures and enable a better assesment, still there is lack of studies using CBCT scans to analyze sinüs floor pneumatization in posterior maxilla.

Additionally, to obtain correct knowledges of conventional panoramic evaluation is still curical for private clinics at the first stage of many health system of countries which dont use CBCT [1]. The purpose of this study was to determine the amount of sinus pneumatization after extraction of maxillary teeth in the premolar and molar region which was associated with maxillary sinus via evaluation of panoramic views.

In spite of common blief, only a few studies describe the phenomenon of pneumatization of maxillary sinus [2,4,7–10]. Previous studies which were conducted by assesing via panoramic radiographs or repetetive radiographs, the potencial of differences in scales and/or mismatching which might arise from comparing two different panoramic radiographs which had differences associated with the machine, the software, and the patient's position and posture [8].

Pachota et al. investigated the bone level changes in the molar region after extraction of premolar and molar teeth. The measurements were evaluated at panoramic views. The lines that pass through the sinus lower border that parallel to the Frankfurt parallel line and passes through the Spina nasalis anterior were taken as reference lines to measure the vertical changes of bone [11–13]. Spina nasalis anterior was also taken as a reference point by Yua-Hoa et al to measure the bone changes at maxillary sinus at panoramic views [14]. Spina nasalis anterior is located at the midline of the maxilla. It is the least affected point with the different head positions and magnification in panoramic views. Spina nasalis anterior was taken as a reference point due to these aforementioned radiographic features.

Sharan et al. also investigated the relationship between teeth extraction and sinus pneumatization. Excessive sinus expansion was seen after the extraction of second molar teeth in their study [2]. Previous studies also showed close proximity between the second molar root ends and maxillary sinus border. Extracting the second molar tooth can cause cortical bone fractures which are placed between root end and maxillary sinus. Thus, the extraction of the second maxillary molar tooth was considered to cause excessive sinus pneumatization [2,15,16]. In the presented study, a larger sinus pneumatization was observed after the first molar extraction. Also, widely sinus expansion was seen after 2nd molar extraction. In a study by Sharan et al., the larger sinus pneumatization was seen after the extraction of the teeth that elevated the sinus floor [2]. These findings are similar to ours. Additionally, larger sinus expansions were seen after removal of the teeth that was related to periapical lesion. No statistical differences were observed with the removal of the teeth that directly associated with the maxillary sinus. These findings are consistent with the studies of Wehrbein and Deidrichs [2,4].Minimally 6 months are needed for the healing of tooth extraction socket. Post-extraction pneumatization occurs in the first 4 to 6 months before bone maturation. After 6 months sinus pneumatization is probably reduced [2].

Contrarily, our study shows precipitous sinus expansion in the first 6 months. Therefore, preprosthetic treatments like dental implant surgery should be achieved in the first 6 months after extractions at the molar region. Otherwise, additional procedures like sinus lifting and grafting might be needed.

Extensive sinus expansion was occurred in cases of extractions of more than one tooth in the same area. At multiple extraction sites, bone resistance is reduced and severe sinus pneumatization can be occurred [2]. After extraction, adjacent teeth transport the occlusal forces to extraction socket. It was considered

that this force transmission to alveolar bone reduces the amount of sinus expansion [2]. This can be the reason why in our study after first upper molar extraction resulted in a larger sinus expansion than the 2nd upper molar extraction.

The immediate grafting of the extraction sockets using particulate bone grafts or bone substitutes with using a barrier membrane or tissue engineering procedures to keep the alveolar bone volume and height via osteoconductive or osteoinductive effect [17]. Therefore, these methods could be prevent maxillary sinus pneumatization related posterior teeth extraction. Levi et al. suggested that sinus pneumatization following maxillary posterior tooth extraction could be reduced by socket preservation procedures [18]. A systematic review by Van der Weijden and colleagues, reported a mean alveolar bone height change of 3–12 months post extraction without socket preservation. Alveolar bone preservation procedures can be effective to significantly decrease the vertical and horizontal alveolar bone dimensional changes [19].

There are a few limitations of the present study. One of these is the use of panoramic radiographs to measure changes in alveolar ridge and maxillary sinus dimensions. Although reference points were used to certainly superimpose the different radiographs, the use of cone-beam computerized tomography (CBCT) could verify sinus pneumatization changes. Secondly, the pneumatization associated with various factors except for tooth extraction in the maxillary posterior region. We evaluated only the correlation between teeth extraction and pneumatization with small sample size in the population. For the further studies including higher sample size and using CBCT should be conducted simultaneously evaluating different factors in order to confirm these findings.

Conclusion

In conclusion, larger sinus pneumatization occurs mostly after extraction of two or more adjacent teeth, first or third second molar teeth that have thinner bone construction, teeth that elevated the sinus floor or teeth that in the sinus mucosa. According to our findings, implant placement is suggested in the first 6 months after extraction. Therefore, surgeons can avoid additional procedures like sinus elevation surgery which can be complicated and needs longer treatment time.

Additionally, the clinician should evaluate preserving bone height by immediate implantation with simultaneously bone grafting at the time of teeth extractions. Further studies should investigate the effect of socket grafting with not only different graft materials but also PRF or tissue engineering procedures via stem cells and/or immediate implantation for preservation on the pneumatization of the maxillary sinus.

Abbreviations

Cone-beam Computed Tomography (CBCT)

Declarations

Ethics Approval and Concent to Participate

The permission for the study was taken from Erciyes University Ethics Committee, and it has been conducted in full accordance with the World Medical Association Declaration of Helsinki. Also, the informed consent form was taken from all patients by the written.

Availability of data and materials

All data generated or analysed during this study are included in this published article.

Funding

No funding received.

Competing Interests

The authors declare that they have no competing interests.

Authors' Controbutions

HO desired and planned this study. HO, UD and EK conducted the extraction of the Posterior teeth from patient. DS and EMC analyzed and interpreted the patient data regarding the radiologic examination of the changes of the maxillary sinus, and HC was a major contributor in writing the manuscript.Lastly, AA contributed to edit the final manuscript for publication. All authors read and approved the final manuscript.

Consent to Publish

Not Applicable

Acknowledgements

Not Applicable

References

1. Cavalcanti MC, Guirado ET, Sapata VM, Costa C, Punniti CM, Jung ER. Maxillary sinus floor pneumatization and alveolar ridge resorption after tooth loss: a cross-sectional study. Brazilian oral research. 2018; 32.
2. Sharan A, Madjar D.Maxillary sinus pneumatization following extractions: a radiographic study. Int J Oral Maxillofac Implant. 2008;23.
3. Thomas A, Raman RA. Comparative study of the pneumatization of the mastoid air cells and the frontal and maxillary sinuses.Am J Neuroradiol. 1989;10: 88
4. Wehrbein H, Diedrich P. The initial morphological state in the basally pneumatized maxillary sinus a radiological-histological study in man (in german). Fortschr kieferorthop.1992;53.
5. Nowak R, Mehlis G. Studies on the state of the pneumatization of the maxillaries. Anat Anz.1975;138.
6. Kosko JR, Hall BE, Tunkel DE.Acquired maxillary sinus hypoplasia: A consequence of endoscopic sinus surgery? Laryngoscope.1996;106.
7. Wehrbein H, Diedrich P. The initial morphological state in the basally pneumatized maxillary sinus – a radiological-histological study in man. Fortschr Kieferorthop 1992; 53.
8. Levi I, Halperin-Sternfeld M, Zigdon-Giladi H, Machtei EE, Horwitz J. Dimensional changes of the alveolar ridge in the posterior maxilla and sinus pneumatization following teeth extraction. Journal of Molecular and Clinical Medicine.2018;*1(*2).
9. Harorh A, Bocutoglu O. The comparison of vertical height and width of maxillary sinus by means of Waters' view radiograms taken from dentate and edentulous cases. Ann Dent.1995;54.
10. Xie Q, Wolf j, Ainamo A. Quantitative assessment of vertical heights of maxillary and mandibular bones in panoramic radiographs of elderly dentate and edentulous subjects. Acta Odontol Scand.1997; 55.
11. Shahbazian M, Xue D, Hu Y, Cleynenbreuge JV, Jacobs R. Spiral computed tomography based maxillary sinus imaging in relation to tooth loss, ımplant placement and potential grafting procedure J Oral Maxillofac.2010;1(1):7.
12. Pachota GV, Hoover JN, Neufeld BD. A study of the height of intact alveolar bone on panoramic radiographs of adult patients.J Prosthet Dent. 1998;60.
13. Xie Q, Wolf j, Ainamo A. Quantitative assessment of vertical heights of maxillary and mandibular bones in panoramic radiographs of elderly dentate and edentulous subjects. Acta Odontol Scand.1996;25.
14. Jung YH, Cho BH. Comparison of panoramic radiography and cone beam computed tomography for assessing the relationship between the maxillary sinus floor and maxillary molars Korean J Oral Maxillofac Radiol 2009;39.
15. Eberhardt JA, Torabinejad M, Christiansen EL. A computed tomographic study of the distances between the maxillary sinus floor and the apices of the maxillary posterior teeth. Oral Surg Oral Med Oral Pathol 1992;73.

16. Kwak HH, Park HD, Yoon HR, Kang MK, Koh KS, Kim HJ. Topographic anatomy of the inferior wall of the maxillary sinus in Koreans. Int J Oral Maxillofac Surg. 2004;33.
17. Iasella JM, Greenwell H, Miller RL. Ridge preservation with freeze-dried bone allograft and a collagen membrane compared to extraction alone for implant site development: a clinical and histologic study in humans. J Periodontol. 2003;7.
18. Levi I, Halperin-Sternfeld M, Zigdon-Giladi H, Machtei EE, Horwitz J. Dimensional changes of the maxillary sinus following tooth extraction in the posterior maxilla with and without socket preservation. Clinical implant dentistry and related research.2017;19.5.
19. Van der Weijden F, Dell'acqua F, Slot DE. Alveolar bone dimensional changes of post-extraction sockets in humans: a systematic review. J Clin Periodontol. 2009;36.

Tables

Table 1. Follow-up between panoramic films before and after the extractions and number of subjects

	TIME PERIOD	NUMBER OF EXPERİMENTS
GROUP 1	0-3 MONTHS	31
GROUP 2	3-6 MONTHS	35
GROUP 3	6-9 MONTHS	28
GROUP 4	9-18 MONTHS	29
GROUP 5	18-24 MONTHS	26

Table 2. The sinus pneumatization amount according to groups

Groups	Time periods	Number of experiments	The average of pneumatization	The maximum pneumatize amount - Tooth type	The minimum pneumatize amount-tooth type
Group 1	0-3 Months	36	0.93 mm	2.8 mm-1.molar	0 mm-2.molar
Group 2	3-6 Months	35	1.057 mm	3.7 mm-2.molar	0.2 mm-premolar
Group 3	6-9 Months	29	1.582 mm	4.8 mm-3.molar	0.3 mm-2.molar
Group 4	9-18 Months	29	1.841 mm	4.5 mm-3.molar	0.1 mm-2.molar
Group 5	18-24 Months	27	3.677 mm	6.0 mm-1.molar	0.9 mm-2.molar

Table 3. The sinus pneumatization amount according to tooth type.

Tooth type	Average pneumatize amount	Number of experiment	The maximum pneumatize amount	The minimum pneumatize amount
Premolar	1.88 mm	17	4.3 mm	0.1 mm
First molar	2.17 mm	54	6.0 mm	0.2 mm
Second molar	1.10 mm	62	4.2 mm	0 mm
Third molar	2.14 mm	23	4.5 mm	0.4 mm

Figures

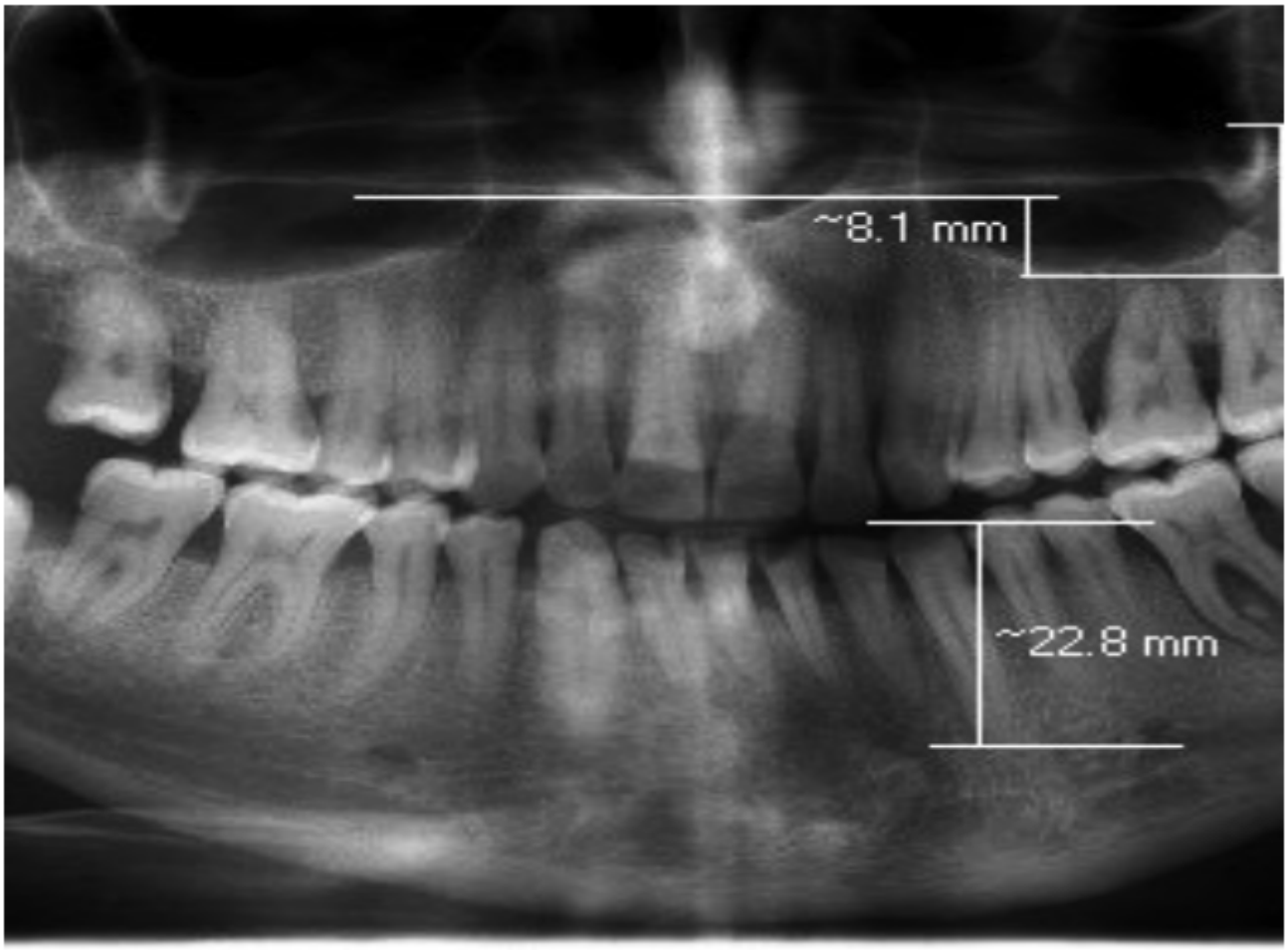

Figure 1

The distance between these two points is regarded as the amount of sinus pneumatization

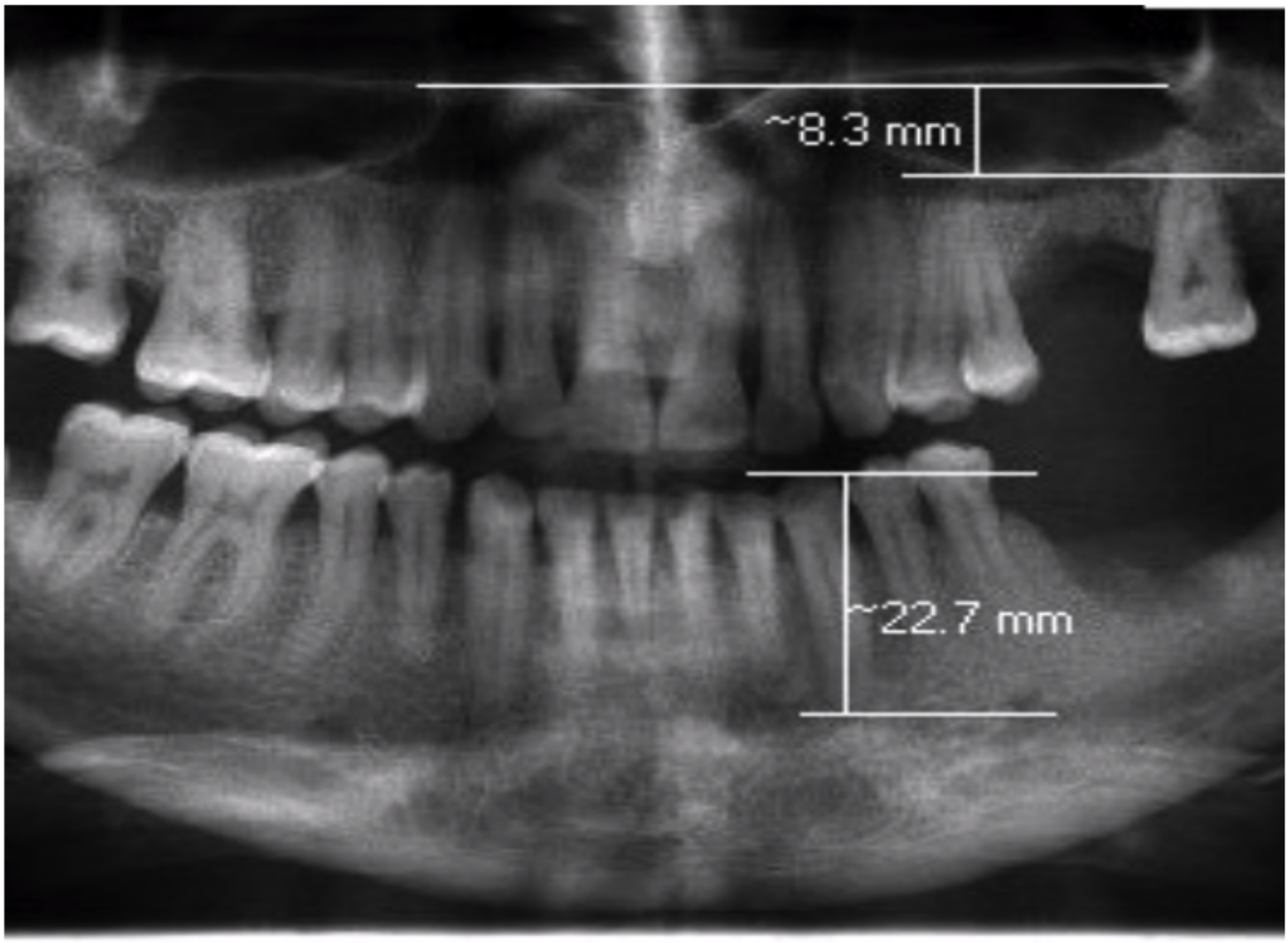

Figure 2

The distance between these two points is regarded as the amount of sinus pneumatization.

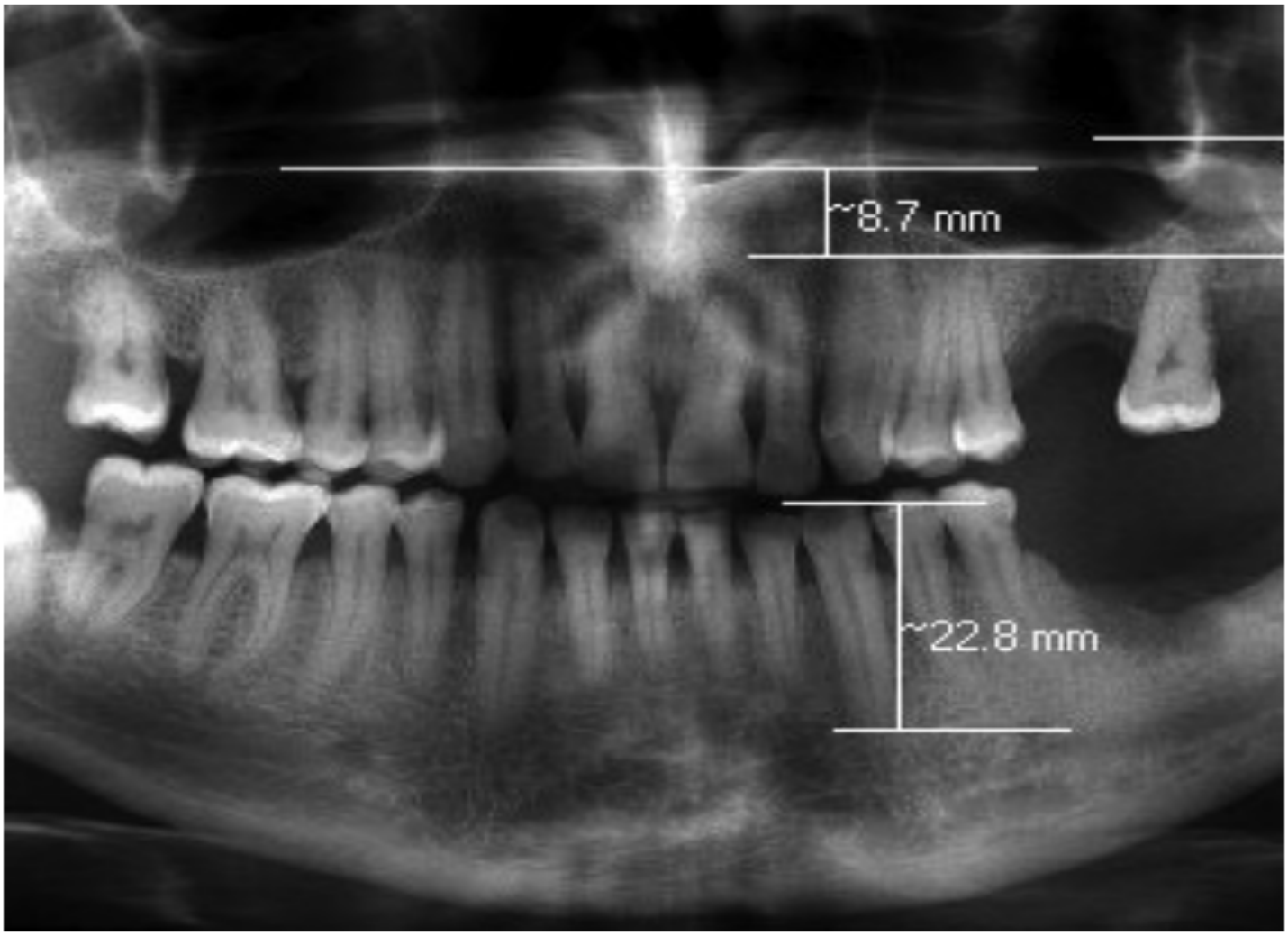

Figure 3

The Post-extraction radiographs to calculate the amount of the actual Pneumatization

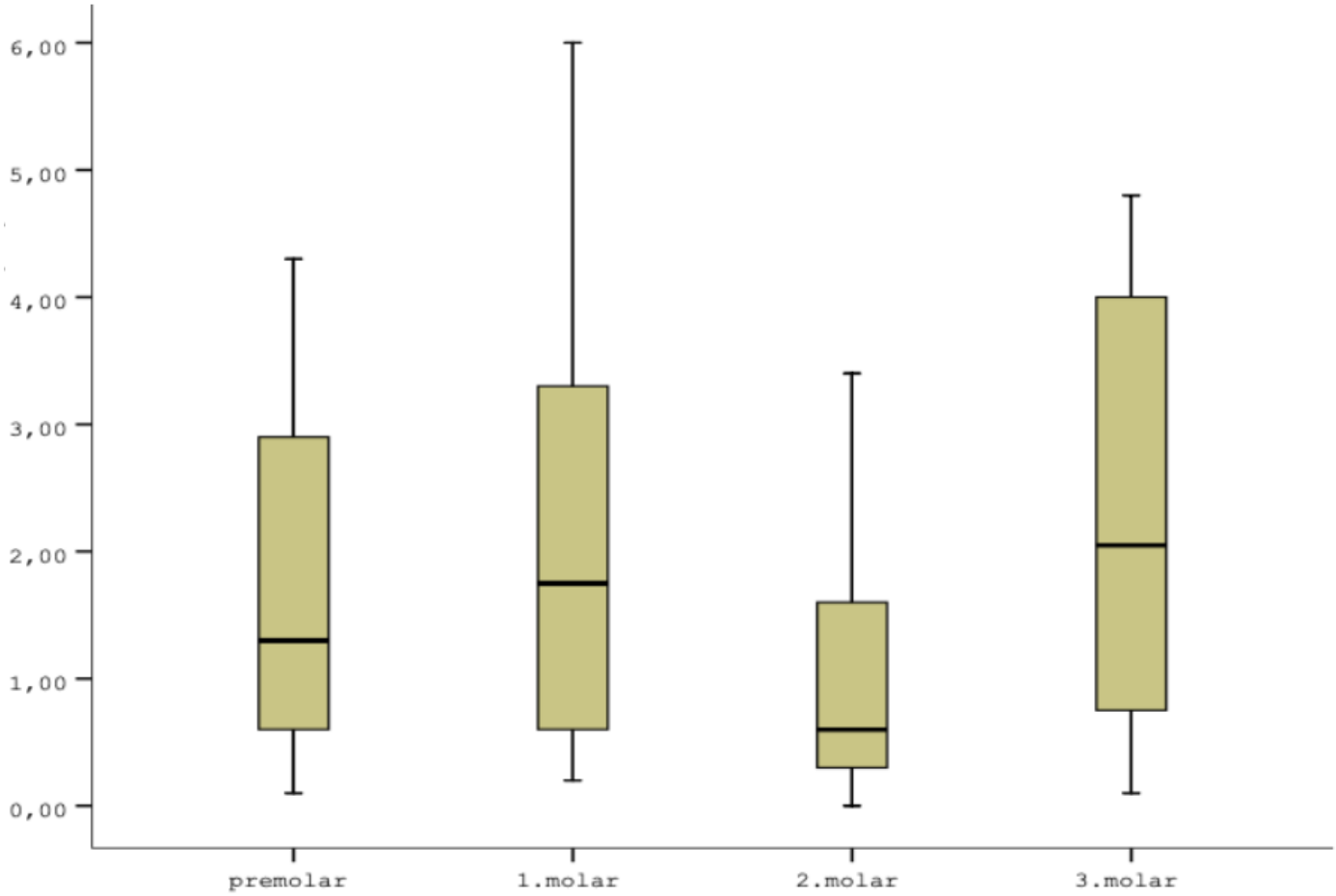

Figure 4

Pneumatization changes by tooth type.

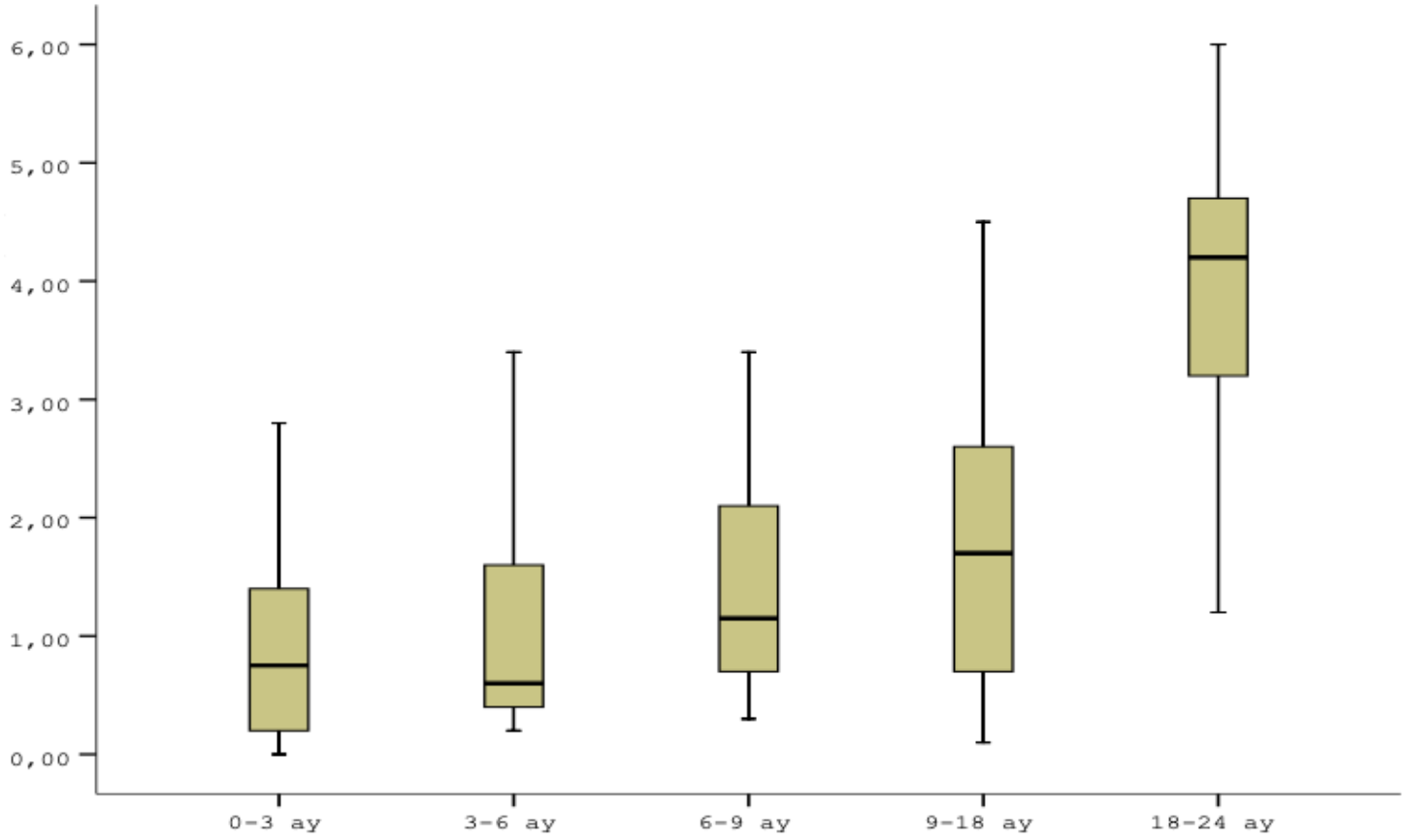

Figure 5

Pneumatization change by time interval.

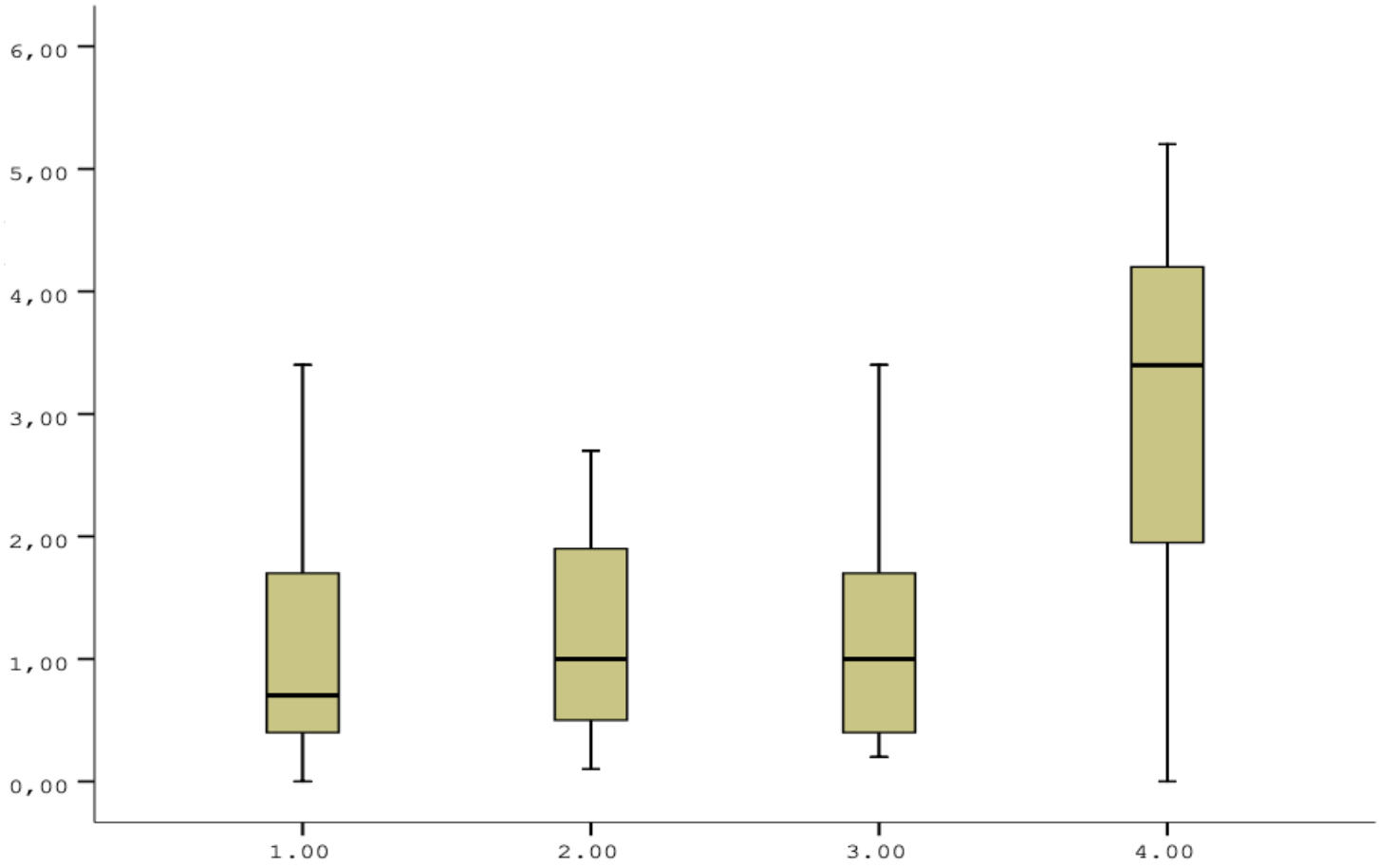

Figure 6

Pneumatization changes by number of extracted tooths.