Tooth Extraction as a Risk Factor for Maxillary Sinus Pneumatization: A Case-control Study

Hakan Ocak
Private Practice

Halis Ali Çolpak (halisalicolpak@gmail.com)
Alanya Alaaddin Keykubat University https://orcid.org/0000-0002-5958-0084

Umut Demetoğlu
Aydın Adnan Menderes University

Damla Soydan
Erciyes University

Erdem Kılıç
Bezm-i Alem Vakıf University

Murat E Canger
Erciyes University

Alper Alkan
Bezm-i Alem Vakıf University

Research article

Keywords: Sinus pneumatization; Tooth extraction; Posterior maxillary; Radiographic assessment

Posted Date: January 2nd, 2020

DOI: https://doi.org/10.21203/rs.2.12521/v4

Abstract

Purpose Maxillary sinus pneumatization following teeth extraction may require various treatment plans such as sinus lifting and alveolar grafting procedures to obtain sufficient alveolar bone height for implant surgery. The aim of this study was to identify sinus pneumatization and to help in determining the proper time for preprosthetic surgery following extraction of maxillary sinus related teeth. Methods We evaluated 75 teeth extraction related to maxillary sinus floor. The panoramic radiographs were evaluated before and after extraction of the posterior maxillary teeth. The radiographs were divided into 5 groups according to duration after extraction. Two reference points (the first point corresponds to the nasal spine while the second point corresponds to the most inferior point of the floor of the maxillary sinus wall) were determined on digital panoramic radiographs before and after teeth extraction and the distance between both aforementioned points was measured. Results The amount of pneumatization was found to be increased with time. The pneumatization within the first 6 months was limited. However, a sudden increase of pneumatization after 6th month, especially the highest between 18th and 24th months, was observed. The mean pneumatization amount was found to be highest in the 1st molar group. Conclusion According to the results of the present study, surgeons should not be waited any more than 6 months after tooth extraction for preprosthetic surgery in the posterior maxillary region as long as physiological healing of extraction socket is allowed.

Background

Currently, dental implant-supported prosthetic treatment is the most common procedure for edentulism. However, due to pneumatization and severe alveolar bone ridge height problems related to the sinus floor, implant placement might not be feasible. Although there are various treatments, such as sinus elevation or bone grafting procedures, to increase the alveolar bone height for implant surgery, it is important to understand the correlation between the process of sinus pneumatization and related factors [1].

The maxillary sinus has the largest volume of all paranasal sinuses. It continues to pneumatize until the permanent teeth erupt from alveolar bone after birth. Pneumatization is a physiological process that leads to an increase in the volume of the paranasal sinuses during growth [2,3]. It is known that the maxillary sinus floor reaches the same level as the nasal floor at age 12-13. Maxillary sinus pneumatization ends after eruption of the third molars. The pneumatization period appears in the osteoid layer on histology, with osteoclastic resorption of the cortical walls of the sinus [4].

The biological process of sinus formation is not clearly understood. Previous studies have reported that heredity [5], nasal mucous membrane pressure [3], craniofacial settlement, bone density, growth hormones [2], sinus air pressure [1] and sinus surgery [6] may play roles in this process.

Although clinicians and researchers presume that sinus pneumatization in relation to maxillary tooth extraction is common knowledge, there have only been a few radiographic studies published in the literature investigating changes in the maxillary sinus floor level in relation to the other anatomical

structures before and after the removal of a tooth (2,4,9,10). This phenomenon has been described in various ways, such as disuse atrophy and a decrease in functional forces transferred to the bone after tooth loss causing a shift in the remodeling process toward bone resorption [2,4] and expansion of the sinus volume toward the edentulous alveolar ridge. The rate and degree of pneumatization after tooth removal may be affected by roots extending into the sinus having a thin cortical bone layer [2,4]. This thin bone may break and dislocate during extraction, potentially causing the sinus to expand toward the socket. Additionally, larger amounts of pneumatization can occur after molar extraction [1,2,4]. These larger defects can be observed in the alveolar bone after molar extraction, and the longer healing period required allows the sinus to pneumatize.

Cone-beam computed tomography (CBCT) is a current diagnostic tool that provides three-dimensional (3D) images and detailed sections for evaluating the relationship between the margin of the alveolar bone and the maxillary sinus floor status. However, only a few studies used CBCT to analyze sinus floor pneumatization in the edentulous posterior maxilla (Lombardi, Calvacanti, Hameed) (1,7,8). Additionally, to obtain correct knowledge by conventional panoramic evaluation is still crucial for private clinics at the first stage of many health systems in countries that do not use CBCT.

The purpose of this retrospective study was to evaluate the maxillary sinus pneumatization in relation to tooth extraction according to time, tooth type and other factors using reference lines and landmarks on a panoramic view. Additionally, this study aimed to identify an ideal time for bone grafting or implant treatment procedures and to determine the possible need for sinus elevation procedures.

Methods

The participants were patients who underwent extraction of at least one premolar or molar with the apex in close radiographic proximity with the sinus floor in Erciyes University Faculty of Dentistry Department of Oral and Maxillofacial Surgery. All patients provided written informed consent. Panoramic radiographs taken before and after extraction were assessed (CLINIVIEW dental imaging software, CLINIVIEW, Finland). Patients were divided into 5 groups according to the follow-up time between the first and second radiological examinations. The follow-up periods and the number of patients in each group are shown in Table 1.

The follow-up period ranged from 1 day to 2 years. Two reference points were selected on the panoramic films, and the amount of pneumatization was calculated by measuring the distance between these two reference points using the CLINIVIEW software program (CLINIVIEW, Finland). The first reference point was a line parallel to the Frankfort horizontal plane passing through the most superior point of the anterior nasal spine. The second reference point was a line parallel to the Frankfort horizontal plane passing through the most inferior point of the sinus **(Figure 1)**.

The distance between these two points was regarded as the amount of sinus pneumatization **(Figure 2).** For determination of the amount of magnification from the panoramic films taken before and after extraction, the distance between the lines parallel to the Frankfort horizontal plane passing through the

top of the crown and the apex of the root of the canine or premolar was calculated. In edentulous patients, the distance between the top and the bottom of the metal ball in the panoramic radiographs was measured, and the amount of magnification was calculated using a simple ratio. This ratio was applied to the postextraction radiographs to calculate the amount of actual pneumatization **(Figure 3).** The average amount of pneumatization was calculated by dividing the obtained total amount of pneumatization from each group by the number of subjects.

Statistical analysis

Data analysis was performed with SigmaPlot 12.0. The Shapiro-Wilk test was used to determine the normality of the data distribution. The Mann-Whitney *U* test was performed for the comparison of sinus pneumatization between preextraction and postextraction according to sex. The one-way Kruskal-Wallis test was used for the comparison of tooth types, time periods and cases of multiple tooth extractions **(Figures 4, 5, 6).** In all analyses, a significance level of $p<0.05$ was used.

Results

A total of 128 panoramic films from 42 patients (19 females, 23 males) were examined. The ages of the participants were between 46 and 70 years old. A total of 75 extractions (5 premolars, 27 first molars, 33 second molars, 10 third molar) were performed.

The amount of pneumatization obtained from the subjects in the 5 different interval groups concerning to the time as month was recorded. These groups are 0-3, 3-6, 6-9, 9-18 and 18-24 months respectively. The average amount of pneumatization, the maximum and minimum amounts of pneumatization and the number of teeth causing pneumatization after extraction are given **(Table 2)**. The average amount of pneumatizations according to groups are 0.93 mm, 1,057mm, ,1.582mm, 1.841mm and 3,677mm respectively **(Table 2)**. The amount of pneumatization increased over time during the follow-up period. In the first 6 months, sinus pneumatization was limited. After 6 months, pneumatization suddenly increased, and between 18-24 months, the amount of pneumatization was at its maximum.

The maximum amount of pneumatization was 6 mm, which was observed after the extraction of a first molar **(Table 3).** The amount of pneumatization was greater after the extraction of teeth with an infected root and the extraction of molars, which lifted the sinus membrane by their roots in a curved manner.

Discussion

Dental implant installation in the upper posterior region, an accurate diagnosis and a better understanding of bone remodeling in the area may be valuable for optimum treatment planning. Currently, cone-beam computed tomography (CBCT) is a common diagnostic tool that supports three-dimensional (3D) imaging and provides thin, detailed sections to assess the relationship between the maxillary sinus floor and the alveolar bone ridge. Although this method reduces the overlapping of anatomical structures and enables a better assessment, a few studies used CBCT to analyze sinus floor

pneumatization in the posterior maxilla [1,2,7-9]. The purpose of this study was to determine the amount of sinus pneumatization after the extraction of maxillary teeth in the premolar and molar regions associated with the maxillary sinus via the evaluation of panoramic views.

In spite of common belief, only a few studies have described the phenomenon of pneumatization of the maxillary sinus [2,4,9-11]. Previous studies that were conducted by assessing panoramic radiographs or repeated radiographs have demonstrated the potential for differences in scale and/or mismatching, which might arise from comparing two different panoramic radiographs with differences in terms of the machine, the software, or the patient's position or posture [10].

Pachota et al. investigated the bone level changes in the molar region after the extraction of premolars and molars. The measurements were evaluated in panoramic views. The lines passing through the lower sinus border parallel to the Frankfort horizontal plane and passing through the spina nasalis anterior were taken as reference lines to measure vertical changes in the bone [13-15]. The spina nasalis anterior was also taken as a reference point by Yua-Hoa et al. to measure changes in the bone at the maxillary sinus on panoramic views [14]. The spina nasalis anterior is located at the midline of the maxilla. It is the point least affected by differences in head position and magnification on panoramic views. The spina nasalis anterior was taken as a reference point due to these aforementioned radiographic features.

Sharan et al. also investigated the relationship between tooth extraction and sinus pneumatization. Excessive sinus expansion was observed after the extraction of second molars in their study [2]. A few previous studies have also shown close proximity between the second molar root ends and the maxillary sinus border. Extracting the second molar can cause cortical bone fractures between the root end and the maxillary sinus. Thus, the extraction of second maxillary molars is considered to cause excessive sinus pneumatization [2,7-9]. In the present study, greater sinus pneumatization was observed after the extraction of first molars. Additionally, sinus expansion was commonly observed after 2nd molar extraction. In a study by Sharan et al., greater sinus pneumatization was observed after the extraction of teeth that elevated the sinus floor [2]. These findings are similar to ours. Additionally, greater sinus expansion was observed after the removal of teeth related to periapical lesions. No significant differences were observed with the removal of teeth that were directly associated with the maxillary sinus. These findings are consistent with those of studies by Wehrbein and Deidrichs [2,4]. At a minimum, 6 months are needed for the extraction socket to heal. Postextraction pneumatization occurs in the first 4 to 6 months before bone maturation. After 6 months, sinus pneumatization is less extensive sinus pneumatization occurs. [2].

In contrast, our study shows rapid sinus expansion in the first 6 months. Therefore, preprosthetic treatments, such as dental implant surgery, should be performed in the first 6 months after extractions in the molar region. Otherwise, additional procedures, likesuch as sinus elevation and grafting, might be needed.

Extensive sinus expansion occurred in cases of the extraction of more than one tooth in the same area. At sites of multiple extractions, bone resistance is reduced, and severe sinus pneumatization can occur [2].

After extraction, adjacent teeth transport the occlusal forces to the extraction socket. This force transmission to the alveolar bone has been considered to reduce the amount of sinus expansion [2]. This may be the reason why in our study, we found greater sinus expansion after the extraction of first upper molars than 2nd upper molars.

Immediate grafting of the extraction socket can be performed using particulate bone graft materials or bone substitutes with a barrier membrane or tissue engineering procedures to maintain the alveolar bone volume and height via osteoconductive or osteoinductive effects. These methods could prevent maxillary sinus pneumatization related to posterior tooth extraction. Levi et al. suggested that sinus pneumatization following maxillary posterior tooth extraction could be reduced by alveoler ridge preservation (ARP) procedures [9]. A systematic review by van der Weijden and colleagues reported a mean alveolar bone height change of 3–12 months after extraction without ARP which can be effective to significantly decrease the vertical and horizontal alveolar bone dimensional changes [18].

There are a few limitations to the present study. One of these is the use of panoramic radiographs to measure changes in alveolar ridge and maxillary sinus dimensions. Although reference points were used to superimpose different radiographs, the use of cone-beam computerized tomography (CBCT) could verify sinus pneumatization changes. Second, pneumatization was associated with various factors except for tooth extraction in the maxillary posterior region. We evaluated only the correlation between tooth extraction and pneumatization with a small sample size. Further studies including CBCT examinations and larger sample sizes should be conducted to evaluate different factors and confirm these findings.

Conclusion

In conclusion, greater sinus pneumatization occurs mostly after the extraction of two or more adjacent teeth, first or third second molars with thinner bone, teeth that elevate the sinus floor and teeth in the sinus mucosa. According to our findings, implant placement is suggested to be performed in the first 6 months after extraction. Therefore, surgeons can avoid additional procedures, such as sinus elevation surgery, which can be complicated and require longer treatment times.

Additionally, the clinician should consider preserving bone height by immediate implantation with simultaneous bone grafting at the time of tooth extraction. Further studies should investigate the effect of socket grafting with not only different grafting materials but also PRF or tissue engineering procedures involving stem cells and/or immediate implantation for the prevention of pneumatization of the maxillary sinus.

Abbreviations

Cone-beam computed tomography (CBCT)

Declarations

Ethics Approval and Consent to Participate

Permission for the study was granted by the Erciyes University Ethics Committee (Decision Number:2019-170), and it was conducted in full accordance with the World Medical Association Declaration of Helsinki. Additionally, written informed consent form was obtained from all patients.

Consent to Publish

Not applicable.

Availability of data and materials

All data generated or analyzed during this study are included in this published article.

Funding

No funding was received.

Competing Interests

The authors declare that they have no competing interests.

Authors' Contributions

HO conceived and planned this study. HO, UD and EK conducted the extraction of posterior teeth from the patients. DS and EMC analyzed and interpreted the patient data regarding the radiological examination of the changes in the maxillary sinus, and HC was a major contributor in the writing of the manuscript. AA contributed to editing the final manuscript for publication. All authors have read and approved the final manuscript.

Acknowledgements

Not applicable.

References

1. Cavalcanti MC, Guirado ET, Sapata VM, Costa C, Punniti CM, Jung ER. Maxillary sinus floor pneumatization and alveolar ridge resorption after tooth loss: a cross-sectional study. Brazilian oral research. 2018; 32.
2. Sharan A, Madjar D .Maxillary sinus pneumatization following extractions: a radiographic study. Int J Oral Maxillofac Implant. 2008;23.

3. Thomas A, Raman RA. Comparative study of the pneumatization of the mastoid air cells and the frontal and maxillary sinuses.Am J Neuroradiol. 1989;10: 88
4. Wehrbein H, Diedrich P. The initial morphological state in the basally pneumatized maxillary sinus a radiological-histological study in man (in german). Fortschr kieferorthop.1992;53. (7. Referans ile aynı)
5. Nowak R, Mehlis G. Studies on the state of the pneumatization of the maxillaries . Anat Anz.1975;138.
6. Kosko JR, Hall BE, Tunkel DE .Acquired maxillary sinus hypoplasia: A consequence of endoscopic sinus surgery? Laryngoscope.1996;106.
7. Lombardi, T., Bernardello, F., Berton, F., Porrelli, D., Rapani, A. et al. Efficacy of Alveolar Ridge Preservation after Maxillary Molar Extraction in Reducing Crestal Bone Resorption and Sinus Pneumatization: A Multicenter Prospective Case-Control Study. *BioMed research international*, *2018:9*.
8. Hameed, S., Bakhshalian, N., Alwazan, E., Wallace, S. S.,Zadeh, H. H.. Maxillary Sinus Floor and Alveolar Crest Alterations Following Extraction of Single Maxillary Molars:A Retrospective CBCT Analysis. *International Journal of Periodontics & Restorative Dentistry*. 2019: *39*(4).
9. Levi I, Halperin-Sternfeld M, Zigdon-Giladi H, Machtei EE, Horwitz J. Dimensional changes of the alveolar ridge in the posterior maxilla and sinus pneumatization following teeth extraction. Journal of Molecular and Clinical Medicine.2018;*1*(2).
10. Harorh A, Bocutoglu O. The comparison of vertical height and width of maxillary sinus by means of Waters' view radiograms taken from dentate and edentulous cases. Ann Dent.1995;54.
11. Xie Q, Wolf j, Ainamo A. Quantitative assessment of vertical heights of maxillary and mandibular bones in panoramic radiographs of elderly dentate and edentulous subjects. Acta Odontol Scand.1997; 55.
12. Shahbazian M, Xue D, Hu Y, Cleynenbreuge JV, Jacobs R. Spiral computed tomography based maxillary sinus imaging in relation to tooth loss, ımplant placement and potential grafting procedure J Oral Maxillofac.2010;1(1):7.
13. Pachota GV, Hoover JN, Neufeld BD. A study of the height of intact alveolar bone on panoramic radiographs of adult patients.J Prosthet Dent. 1998;60.
14. Jung YH, Cho BH. Comparison of panoramic radiography and cone beam computed tomography for assessing the relationship between the maxillary sinus floor and maxillary molars Korean J Oral Maxillofac Radiol 2009;39.
15. Eberhardt JA, Torabinejad M, Christiansen EL. A computed tomographic study of the distances between the maxillary sinus floor and the apices of the maxillary posterior teeth. Oral Surg Oral Med Oral Pathol 1992;73.
16. Kwak HH, Park HD, Yoon HR, Kang MK, Koh KS, Kim HJ. Topographic anatomy of the inferior wall of the maxillary sinus in Koreans. Int J Oral Maxillofac Surg. 2004;33.

17. Iasella JM, Greenwell H, Miller RL. Ridge preservation with freeze-dried bone allograft and a collagen membrane compared to extraction alone for implant site development: a clinical and histologic study in humans. J Periodontol. 2003;7.
18. Van der Weijden F, Dell'acqua F, Slot DE. Alveolar bone dimensional changes of post-extraction sockets in humans: a systematic review. J Clin Periodontol. 2009;36.

Tables

Table 1. .Follow-up between panoramic films before and after the extractions and number of subjects

	TIME PERIOD (Month)	NUMBER OF EXPERIMENTS (n)
GROUP 1	0-3 MONTHS	31
GROUP 2	3-6 MONTHS	35
GROUP 3	6-9 MONTHS	28
GROUP 4	9-18 MONTHS	29
GROUP 5	18-24 MONTHS	26

Table 2: The sinus pneumatization amount according to groups

Groups	Time periods (Month)	Number of experiments (n)	The average of pneumatization (mm)	The maximum pneumatize amount (mm) - Tooth type	The minimum pneumatize amount- tooth type
Group 1	0-3	36	0.93	2.8 - 1.molar	0 - 2.molar
Group 2	3-6	35	1.057	3.7 - 2.molar	0.2 – 2.premolar
Group 3	6-9	29	1.582	4.8 - 3.molar	0.3 - 2.molar
Group 4	9-18	29	1.841	4.5 - 3.molar	0.1 - 2.molar
Group 5	18-24	27	3.677	6.0 - 1.molar	0.9 - 2.molar

Table 3. The sinus pneumatization amount according to tooth type.

Tooth type	Average pneumatize amount (mm)	Number of experiment (n)	The maximum pneumatize amount (mm)	The minimum pneumatize amount (mm)
Premolar	1.88	17	4.3	0.1
First molar	2.17	54	6.0	0.2
Second molar	1.10	62	4.2	0
Third molar	2.14	23	4.5	0.4

Figures

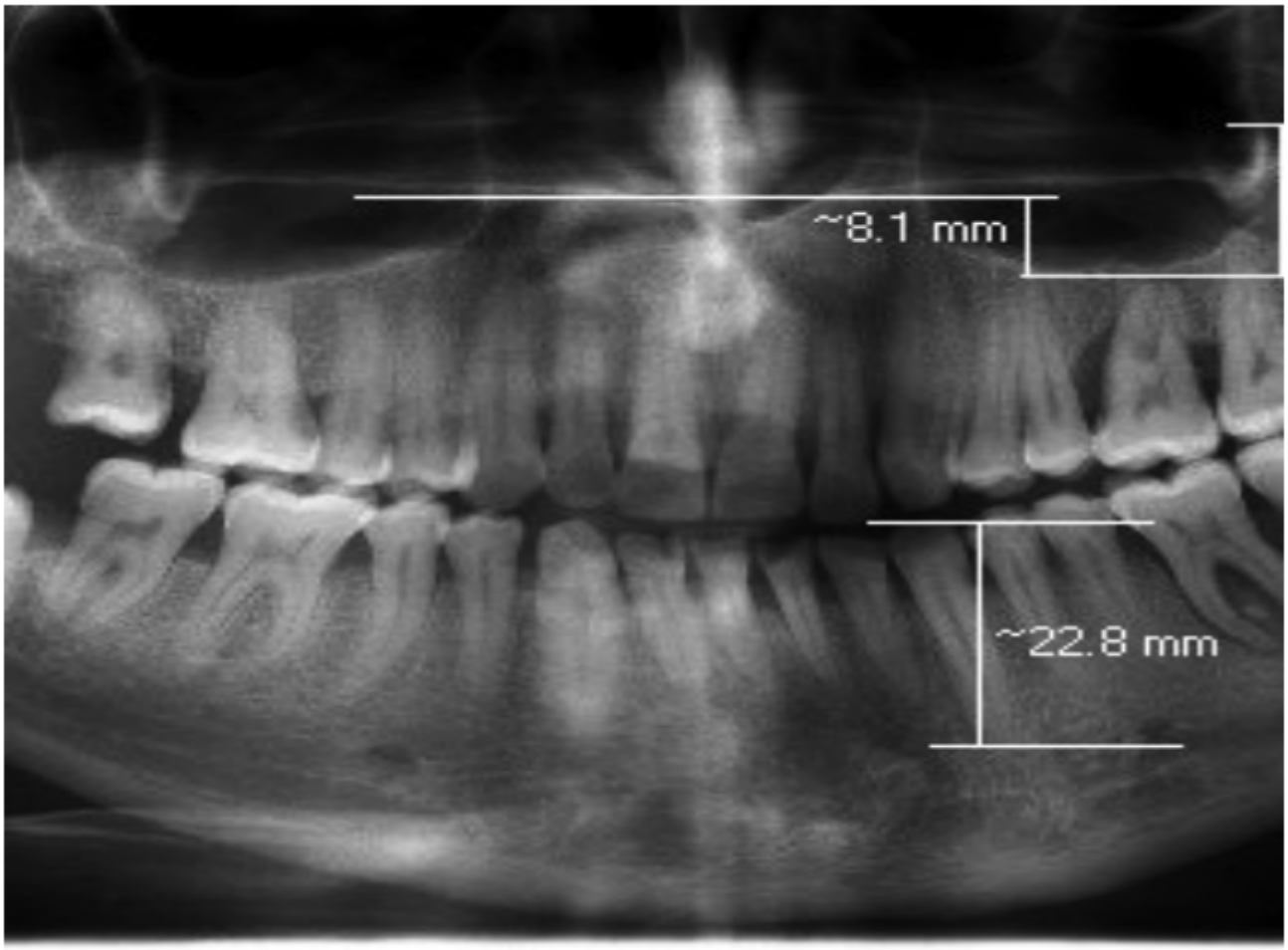

Figure 1

The distance between these two points is regarded as the amount of sinus pneumatization.

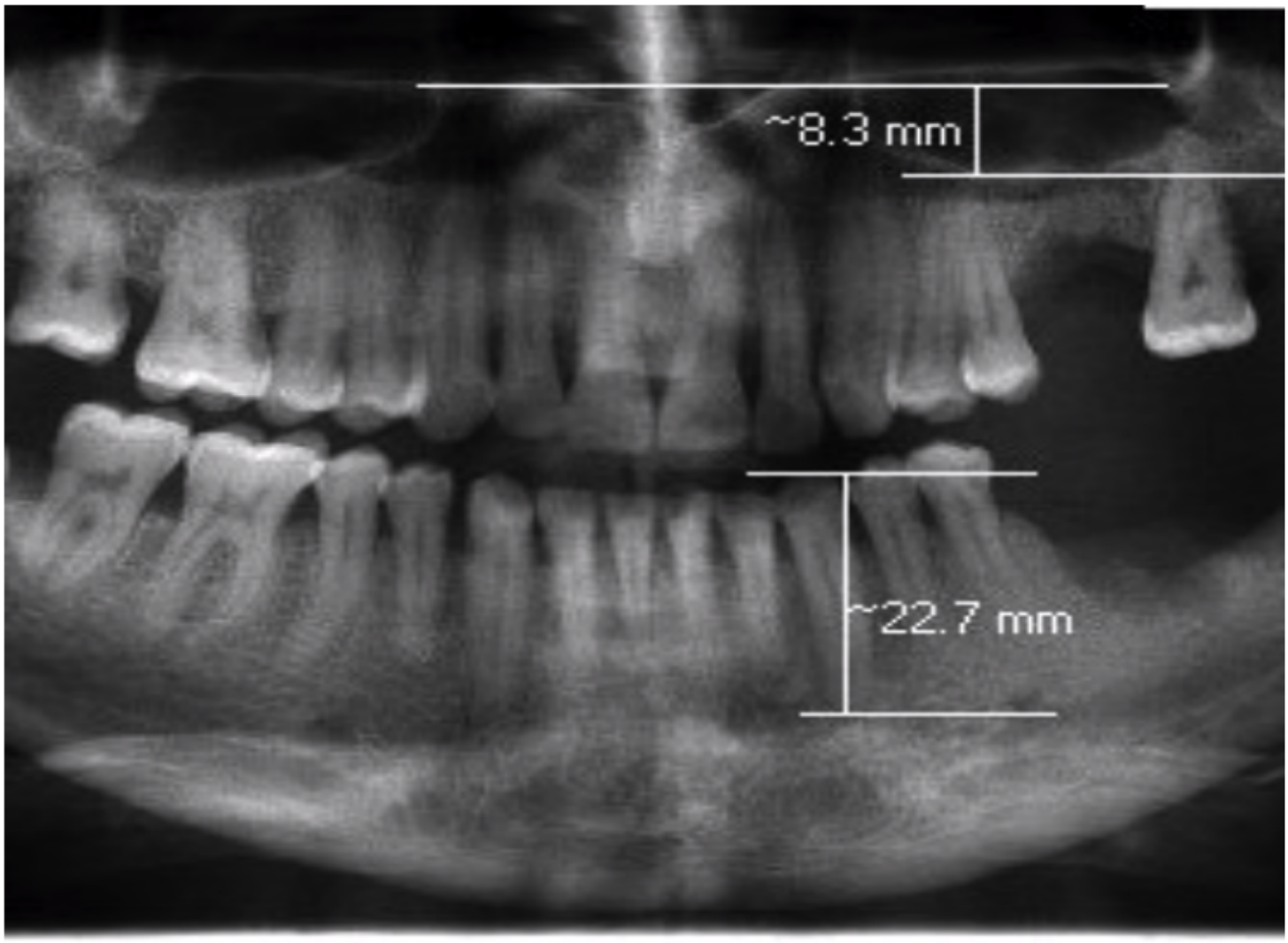

Figure 2

The distance between these two points is regarded as the amount of sinus pneumatization.

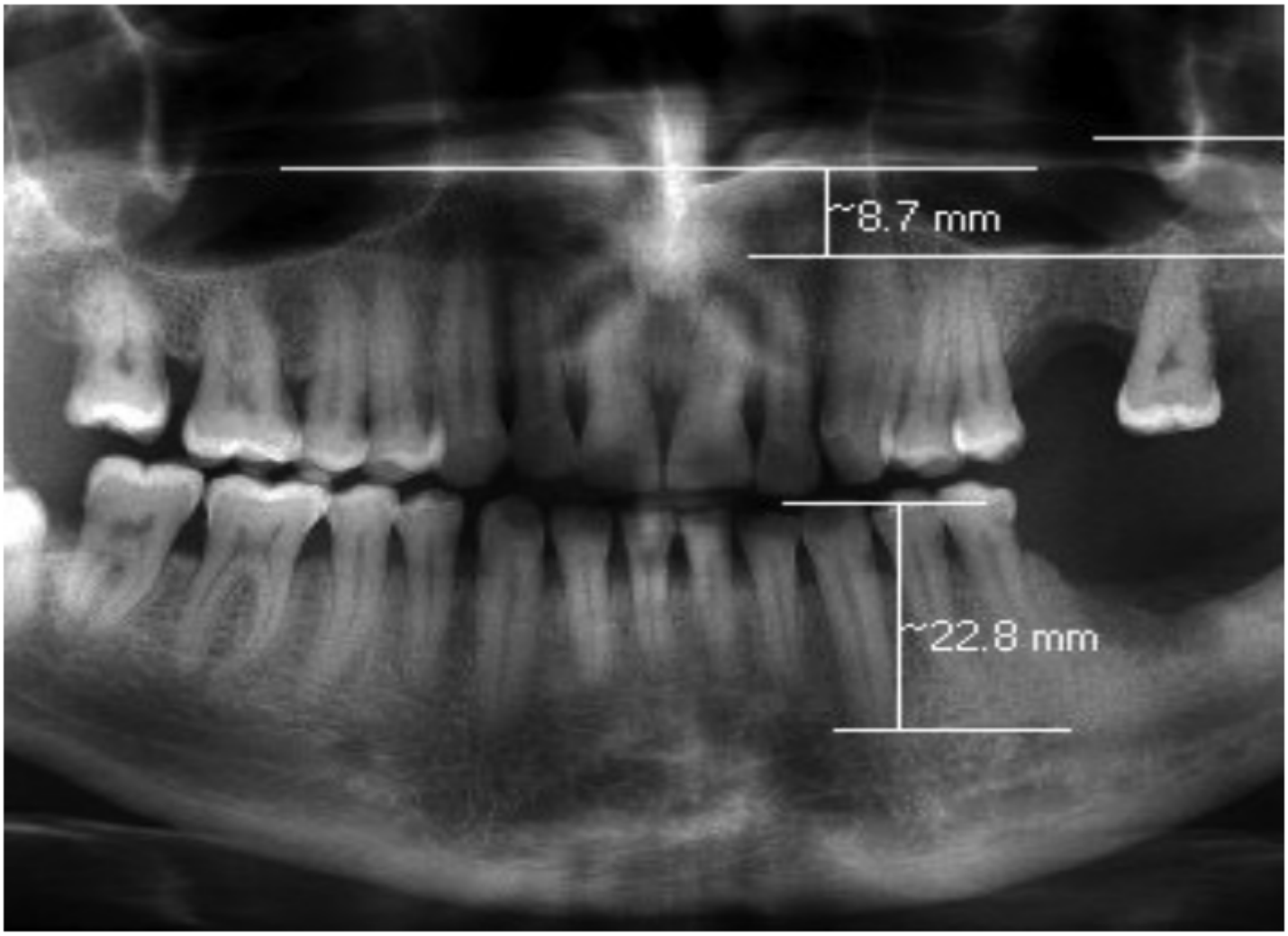

Figure 3

Postextraction radiographs were used to calculate the amount of the pneumatization.

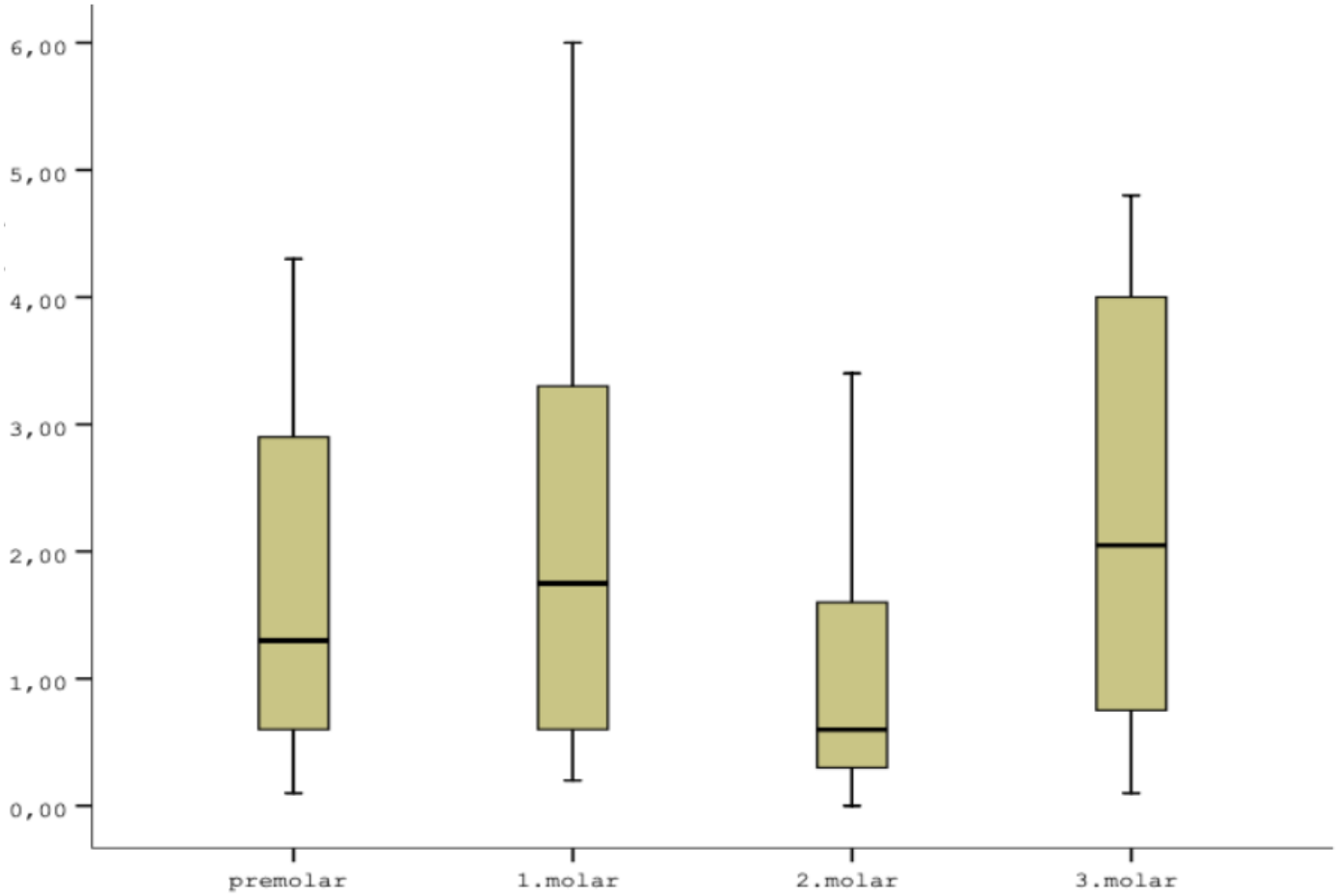

Figure 4

Differences in pneumatization by tooth type.

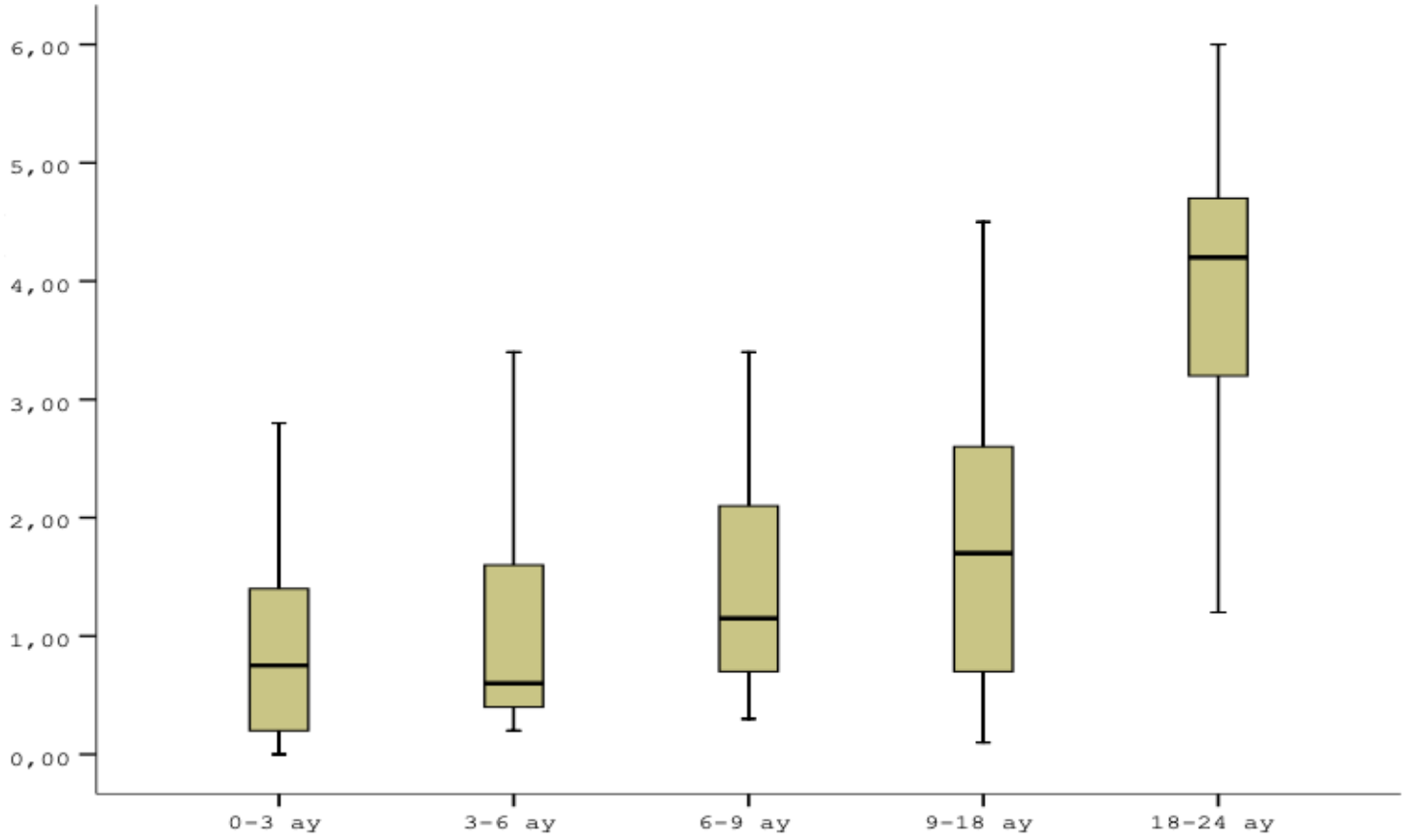

Figure 5

Changes in pneumatization over time.

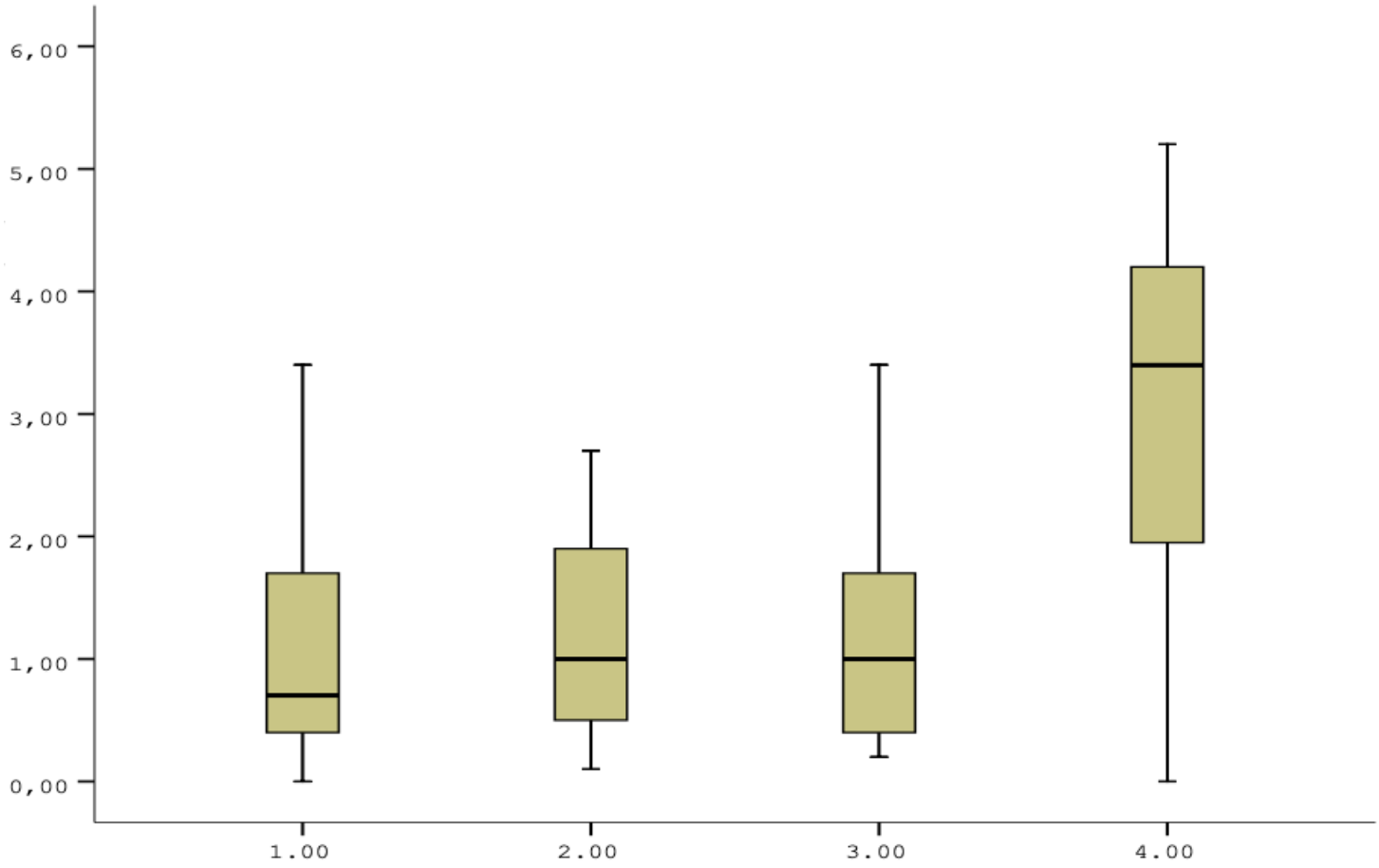

Figure 6

Differences in pneumatization by number of extracted teeth.