Case Report: Giant Thyroid Cyst with Critical Airway Compresion

Irene Grao Torrente (iregrt@gmail.com)
Hospital Infanta Sofia: Hospital Universitario Infanta Sofia https://orcid.org/0000-0002-3458-3561

Fátima Sánchez - Cabezudo
Infanta Sofia University Hospital: Hospital Universitario Infanta Sofia

María Antonia Vaquero
Infanta Sofia University Hospital: Hospital Universitario Infanta Sofia

Paloma Mate
Infanta Sofia University Hospital: Hospital Universitario Infanta Sofia

Sara Nuñez
Infanta Sofia University Hospital: Hospital Universitario Infanta Sofia

Jose Antonio Balsa
Infanta Sofia University Hospital: Hospital Universitario Infanta Sofia

Susana Novo
Infanta Sofia University Hospital: Hospital Universitario Infanta Sofia

Antonio Luis Picardo
Infanta Sofia University Hospital: Hospital Universitario Infanta Sofia

---

Research Article

Keywords: thyroid, cyst, airway compression, aspiration

Posted Date: September 7th, 2021

DOI: https://doi.org/10.21203/rs.3.rs-329367/v1

Abstract

Thyroid nodules with cystic component are common and the vast majority of them do not cause symptoms. Their neck location, close to airway and vascular structures, makes them a potentially life-threating condition if they become bigger or suffer from an acute haemorrhage. In this case report we expose the case of a twenty-two year old man who went to our emergency service suffering from odynophagia and neck swelling. He was diagnosed with giant thyroid cyst and critical tracheal compression. Initially, in order to relieve symptoms, we carried out two ultrasound-guided aspirations; later, as final treatment, the patient underwent thyroid lobectomy. He progressed successfully without postoperative complications. In our experience, surgery is an effective and definitive treatment to consider in cases for big thyroid cyst in young patients.

Introduction

Thyroid nodules with cystic component are quite common, reaching even more than 40% of the total nodules depending on the series[1]. A large proportion of them do not produce symptoms and they are usually diagnosed after a self-patient physical examination or in images taken for other reasons. In their evaluation is mandatory to rule out thyroid cancer[2]. Occasionally, they could trigger symptoms as pain, dysphagia or dyspnoea as a consequence of compression of surrounding structures due to acute haemorrhage or progressive growth.

Case Presentation

Man of twenty-two years old with history of type one diabetes, who came to our emergency services reporting three days of odynophagia and neck swelling. On physical examination he was eupneic (oxygen saturation 98%) and a lump on his neck was appreciated (Picture 1). Given the findings, we did an urgent CT scan that showed a 7.6 centimetres cyst nodule dependant of the left thyroid lobe (Pictures 2 and 3). The cyst displaced the carotid artery and the jugular vein and caused a 6 millimetres tracheal stricture. The same day, we carried out an ultrasound-guided aspiration getting 150 millilitres of colloid material and obtaining an improvement of the symptoms. The patient was admitted for further evaluation and planning definitive treatment. Vocal cords were mobile in indirect laryngoscopy, there were not other lesions in right thyroid lobe and the patient was euthyroid.

Due to the reappearance of cervical swelling 4 days later, we performed a new CT scan. It showed a 5.6 centimetres cyst and 10 millimetres tracheal stricture (Picture 4), thus a second ultrasound-guided aspiration was conducted extracting 70 millilitres. Finally, two days later, a left thyroid lobectomy (Pictures 5 and 6) with intraoperative laryngeal neuromonitoring was carried out. The patient did not present postoperative complications and was discharged 24 hours after surgery. The definitive pathology reported a nodular hyperplasia with partial cyst transformation.

Discussion

Thyroid nodules with cyst component rarely become a life-threating condition[5]. However, due to their location in the neck, patients with big lesions[6] or acute cyst haemorrhage[7] are at risk of airway, oesophagus or vascular structures compression. Therefore, special follow up should be considered.

In the case reported, the patient did not show respiratory insufficiency even with the reduced trachea diameter. This evidence indicated a gradual growth of the cyst. In this scenario, the patient was able to tolerate critical airway compression but the collapsed oesophagus probably triggered the odynophagia.

With regards to the treatment of this type of lesions, a large number of interventional approaches have been described during last decades but none of them has become an absolute gold standard. Some of the most popular are: aspiration[8], etanol ablation[9], radiofrequency[10], or sclerosing[11]. Initially, two aspirations were carried out in four days in order to relieve the symptoms. However, the rapid refilling, the big size of the cyst and the young age of the patient forced the need to consider a more definitive solution.

In a multidisciplinary team with endocrinologist, radiologist and pathologist a consensus was reach in performing a surgery[12]. It was considered that a left thyroid lobectomy would be the optimum treatment with the objective to remove the cyst, rule out cancer, relieve symptoms completely and preserve thyroid and parathyroid function.

Our experience in treating a big thyroid cyst in a young male with surgery has been successful. However, more studies with a bigger volume of patients are necessary to establish the best approach to manage this pathology.

Declarations

Funding:

No funding was received

Conflict of Interest:

All the authors declare that they have no conflict of interest.

Availability of data and material:

All data underlying the results are available as part of the article and no additional source data are required.

Code availability:

Not applicable

Ethics approval:

Not applicable

Consent to participate and for publication:

The patient has been told about the use of his data for academic purpose. He showed his agreement and he signed the proper informed consent.

Authors' contributions:

All authors discussed the case. I. Grao wrote the manuscript. All the authors provided critical feedback and contributed to the final version of the manuscript. F. Sánchez Cabezudo, M.A. Vaquero y A.L.Picardo supervised the project.

References

1. Alexander EK, Heering JP, Benson CB, Frates MC, Doubilet PM, Cibas ES, Marqusee E. Assessment of nondiagnostic ultrasound-guided fine needle aspirations of thyroid nodules. J Clin Endocrinol Metab. 2002 Nov;87(11):4924-7. doi: 10.1210/jc.2002-020865. PMID: 12414851.
2. de los Santos ET, Keyhani-Rofagha S, Cunningham JJ, Mazzaferri EL. Cystic thyroid nodules. The dilemma of malignant lesions. Arch Intern Med. 1990 Jul;150(7):1422-7. doi: 10.1001/archinte.150.7.1422. PMID: 2196027.
3. Gallant SC, Fritz MA, Paul BC, Costantino PD. Management of airway compromise following thyroid cyst hemorrhage after thrombolytic therapy. Laryngoscope. 2015 Mar;125(3):604-7. doi: 10.1002/lary.24841. Epub 2014 Jul 14. PMID: 25043767.
4. Irfan M, Jihan WS, Shahid H. Unusual presentation of a solitary thyroid cyst. Ann Acad Med Singap. 2010 Jan;39(1):68 – 9. PMID: 20126821.
5. Vijapurapu R, Kaur K, Crooks NH. A case of airway obstruction secondary to acute haemorrhage into a benign thyroid cyst. Case Rep Crit Care. 2014;2014:372369. doi: 10.1155/2014/372369. Epub 2014 Aug 21. PMID: 25215246; PMCID: PMC4158169.
6. Harada K, Fujikawa T. Giant adenomatous thyroid nodule compressing the trachea. J Gen Fam Med. 2018 Aug 29;19(6):219–220. doi: 10.1002/jgf2.203. PMID: 30464871; PMCID: PMC6238239.
7. Al-Khalifa MA, Sharif H, AlShehabi M. From Neck Swelling to Abrupt Compromised Airway: A Case of a Hemorrhagic Ruptured Thyroid Cyst. Saudi J Med Med Sci. 2016 Sep-Dec;4(3):229–232. doi: 10.4103/1658-631X.188250. Epub 2016 Aug 11. PMID: 30787737; PMCID: PMC6298341.

8. Howel-Evans W, Sykes D. A giant thyroid cyst. Postgrad Med J. 1987 Jul;63(741):577-8. doi: 10.1136/pgmj.63.741.577. PMID: 3658867; PMCID: PMC2428376.
9. Valcavi R, Frasoldati A. Ultrasound-guided percutaneous ethanol injection therapy in thyroid cystic nodules. Endocr Pract. 2004 May-Jun;10(3):269 – 75. doi: 10.4158/EP.10.3.269. PMID: 15310546.
10. Sung JY, Kim YS, Choi H, Lee JH, Baek JH. Optimum first-line treatment technique for benign cystic thyroid nodules: ethanol ablation or radiofrequency ablation? AJR Am J Roentgenol. 2011 Feb;196(2):W210-4. doi: 10.2214/AJR.10.5172. PMID: 21257865.
11. Sibbitt RR, Palmer DJ, Sibbitt WL Jr. Reciprocating procedure device for thyroid cyst aspiration and ablative sclerotherapy. J Laryngol Otol. 2009 Mar;123(3):343-5. doi: 10.1017/S0022215108003551. Epub 2008 Sep 17. PMID: 18796180.
12. Abbas G, Heller KS, Khoynezhad A, Dubner S, Sznyter LA. The incidence of carcinoma in cytologically benign thyroid cysts. Surgery. 2001 Dec;130(6):1035-8. doi: 10.1067/msy.2001.118387. PMID: 11742334.

Figures

Figure 1

Picture 1: Neck swelling in patient with thyroid cyst

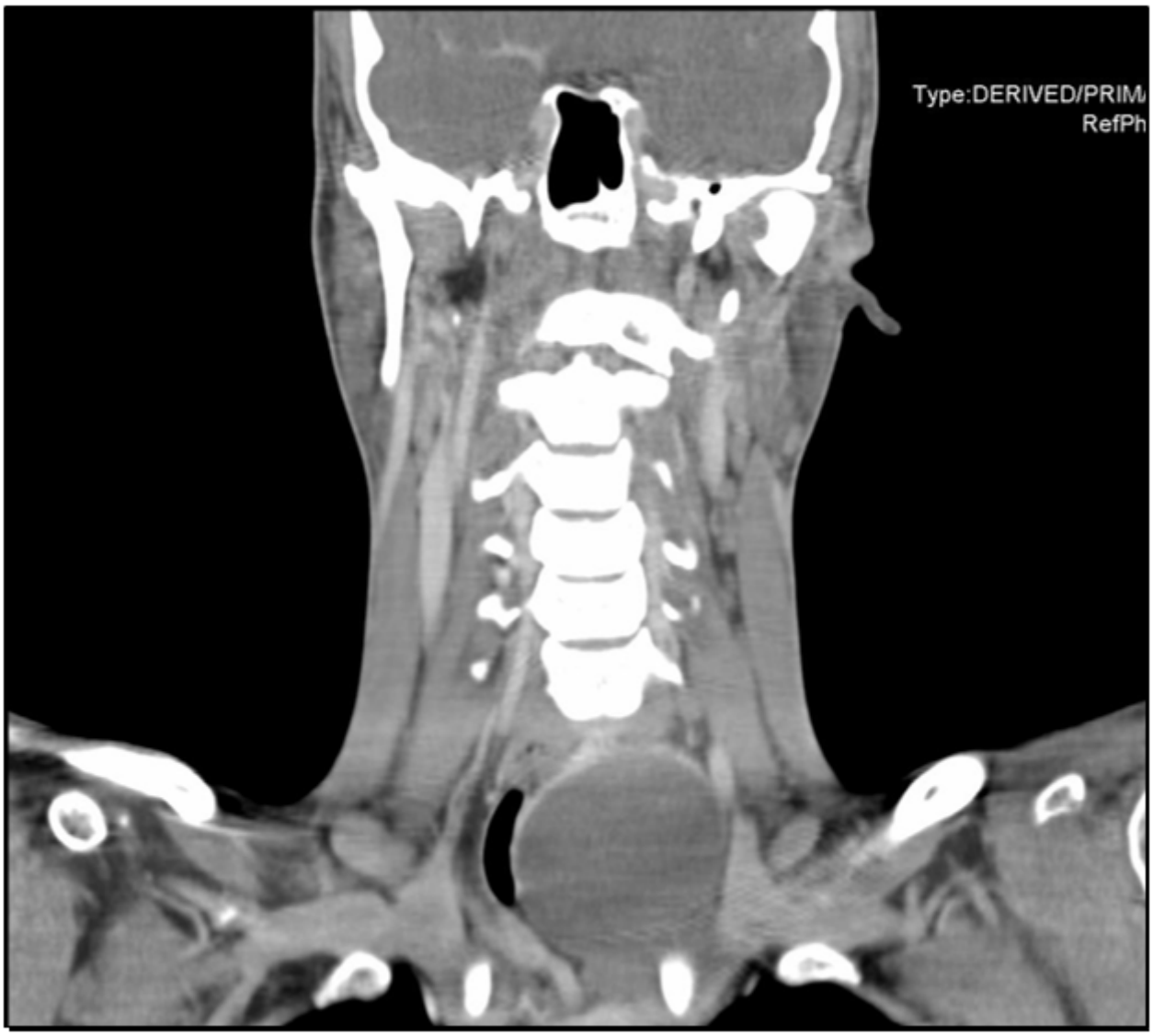

Figure 2

Picture 2: Coronal views of trachea stricture and thyroid cyst in first CT scan

Figure 3

Picture 3: Axial view of trachea stricture and thyroid cyst in first CT scan

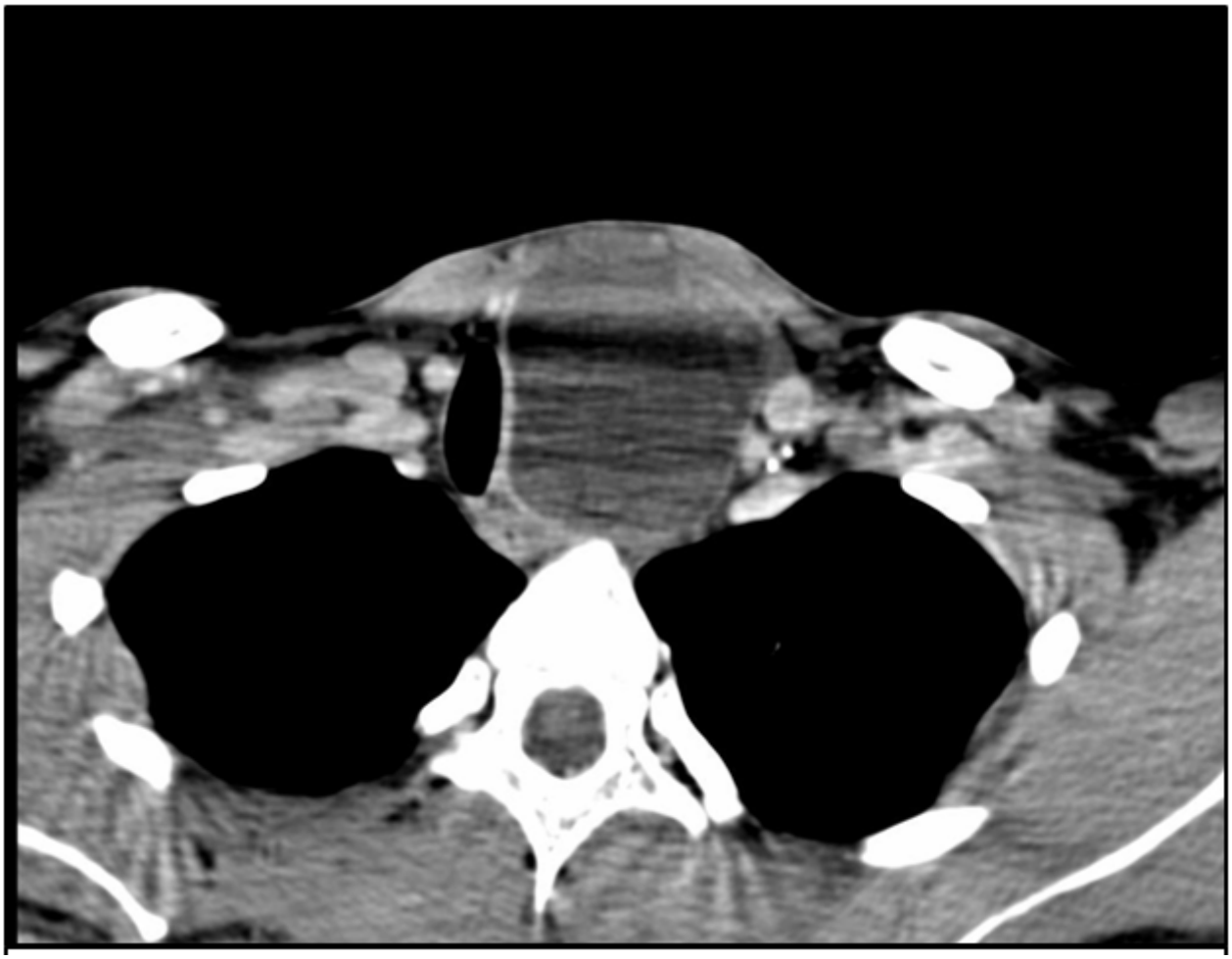

Figure 4

Picture 4: Axial view of trachea stricture and thyroid cyst in second CT scan previous to the second ultrasound – guide aspiration.

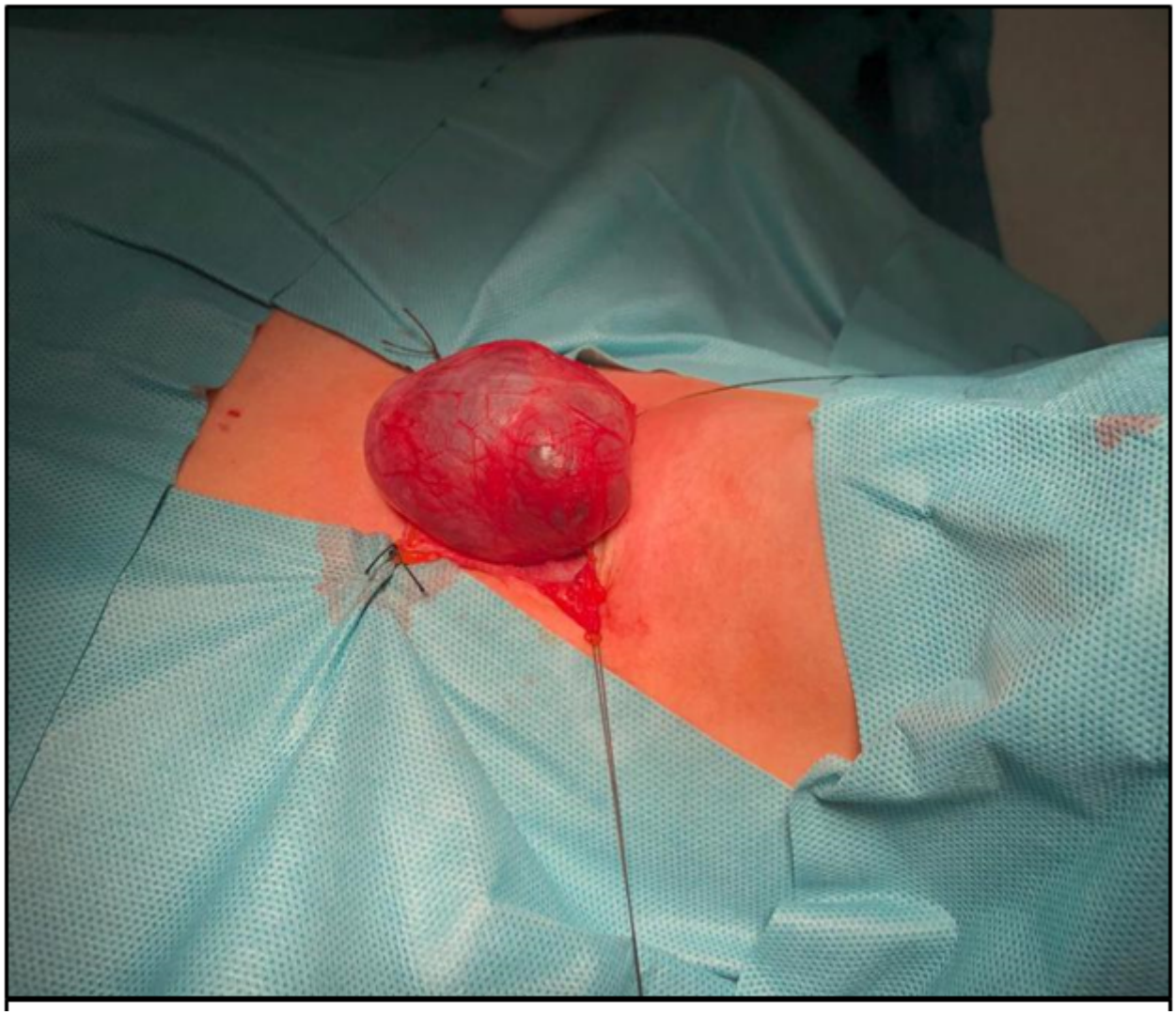

Figure 5

Picture 5: Cyst in left thyroid lobe during surgery

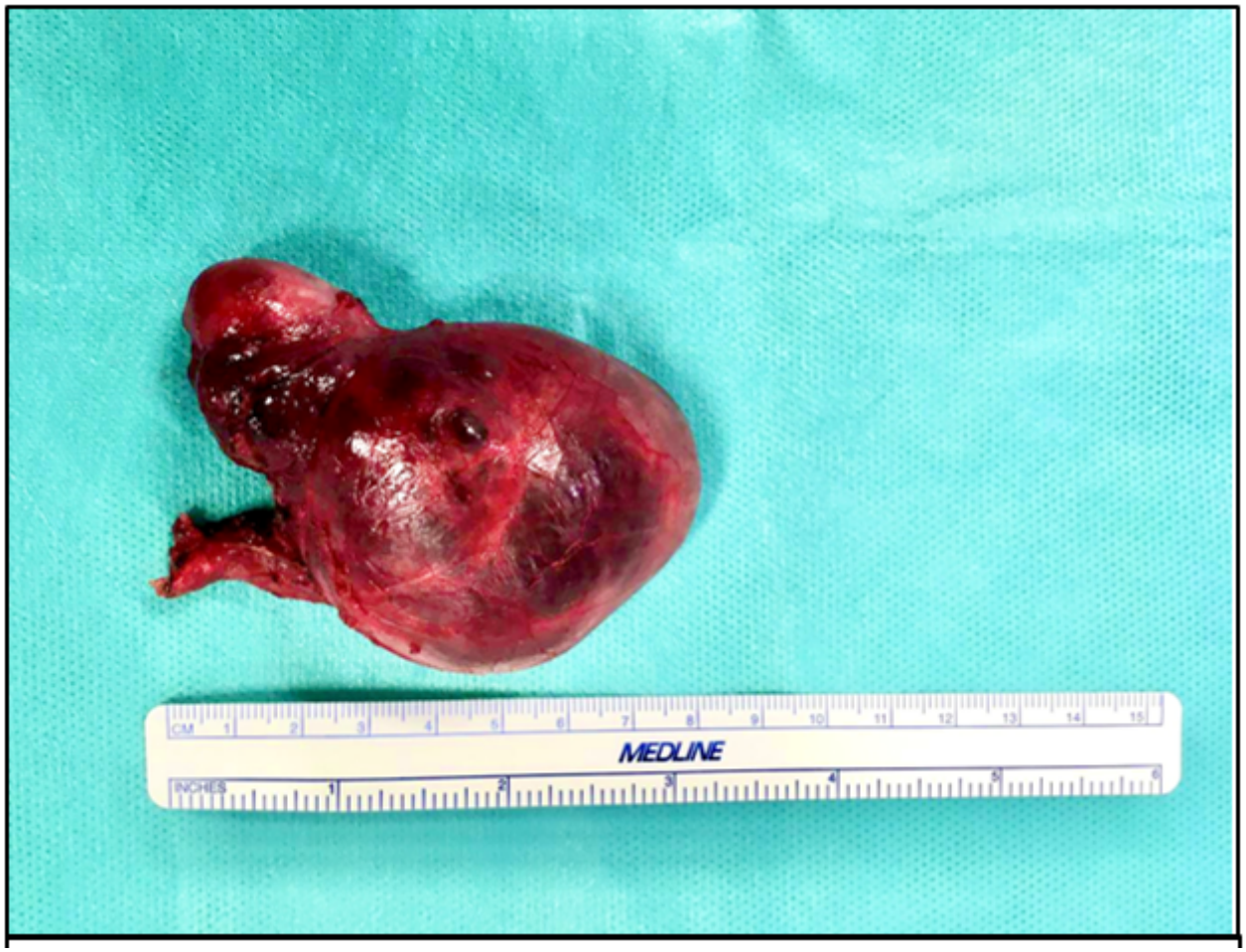

Figure 6

Picture 6: Specimen after left thyroid lobectomy