Patient with Nutcracker Syndrome Treated by Spiral Vein Graft Bypass

drmohammad alşalaldeh (dr-alshalaldeh@hotmail.com)
mohammad alşalaldeh https://orcid.org/0000-0001-9775-7090
Ali Vefa Özcan
Pamukkale University School of Medicine: Pamukkale Universitesi Tip Fakultesi
Gökhan Yiğit TANRISEVER
Denizli State Hospital: Denizli Devlet Hastanesi

Research Article

Keywords: nutcracker syndrome, renal vein, spiral vein graft, surgical technique

Posted Date: September 7th, 2021

DOI: https://doi.org/10.21203/rs.3.rs-331289/v1

Abstract

Nutcracker syndrome is a vascular pathology result from compressing the left renal vein between the superior mesenteric artery (SMA) and abdominal aorta. Patients usually complain of abdominal pain and symptoms from renal venous hypertension. In this case, a 32-year-old male patient presented with chronic abdominal pain for two years. İnvestigations showed the left renal artery compressed between SMA and abdominal aorta. He was operated on by using a spiral saphenous vein graft. The operation was done successfully with no complications.

Introduction

left renal vein (LRV) entrapment syndrome or Nutcracker syndrome can be symptomatic with a chief complaint of abdominaş pain, fatigue, dyspareunia, varicocele, dysmenorrhea, and haematuria as well as it me be asymptomatic. The management of this syndrome varies from stenting via interventional radiological technique to open surgery. Management with open surgery has different surgical techniques. Saphenous graft, spiral saphenous graft or synthetic grafts bypass, transposition of the LRV, nephropexy, and nephrectomy are examples of such techniques. the decision of When and how to operate depends on the patient's situation, the degree of the compression, the severity of the symptoms, comorbidities, and the surgeon’s experience. The main goal of all techniques is to decompress the renal vein or to achieve a good outflow from the renal vein.

Case Report

A 32-year-old male patient presented to our clinics complaining of long-standing mid and upper abdominal pain for more than two years, associated with recurrent attacks of urinary tract infections and loss of appetite. İnvestigations were done and the abdominal CT-Scan with contrast showed the left renal vein was compressed between SMA and abdominal aorta for more than 80% (Fig. 1). The case was diagnosed as Nutcracker syndrome and the decision of operation was taken.

Surgical Technique

On the day of the operation, the patient was taken to the operation room, and in the supine position, under general anesthesia, he was intubated and nasogastric was inserted. After dyeing and covering, a midline laparotomy was done. The abdominal wall was opened in layers. The left transverse colon was pulled upward while the small intestine was pulled to the right side by sterile wet compresses. Gentle dissection was done and the left renal vein and inferior vena cava (IVC) were liberated and secured by vascular tapes. A fibrous band between SMA and IVC was found and divided by the cautery. A saphenous graft of about 25 cm long was taken from the patient's right leg and opened longitudinally then sutured in a spiral fashion over a plastic rod of about 2 cm in diameter (Fig. 2).

Anticoagulant (heparin) was given in a dose of 1mg/kg to keep the activated clotting time (ACT) up to 250–350 seconds. After 3 minutes of heparin administration, side vascular clamps were applied on the mid-portion of the left renal vein and the VCI, 2 cm inferior to the left renal vein insertion site. The spiral vein graft was anastomosed to VCI and left renal vein by anastomosing each end of the graft to each vein in (end-to-side) fashion. Side vascular clamps were removed after de-airing and hemostasis was secured (Fig. 3). A soft drain was inserted up to the site of operation. The abdominal wall was closed layer by layer and the patient was transferred to the floor where the daily dressing was done and medications were given. On the 5.th day postoperatively the patient was discharged on oral antibiotics and antiaggregant. He was followed up as an outpatient with no complications or complaints.

Discussion

Nutcracker syndrome is one of the vascular syndromes which result from the compression of the left renal vein (LRV) and associated with embryological LRV development from the aortic collar at 6–8 weeks gestation [1]. The prevalence of nutcracker syndrome is unknown but it usually has peaks in middle-aged adults and the 2.nd to 3.rd decades and more frequently in females, although a later study demonstrated equal prevalence between males and females [1, 2]. Patients may present with symptoms such as abdominal pain, fatigue, or clinical features as proteinuria and hematuria [2] while they may be asymptomatic and diagnosed incidentally. In our case, the patient presented with a history of intermittent abdominal pain with fatigue and recurrent attacks of urinary tract infections for a long time.

In cases that require surgery, many surgical techniques had been described. Stent implantation, transposition of LRV or SMA, nephropexy, saphenous vein graft bypass even renal autotransplantation, and nephrectomy are some of the possible surgical treatment methods [3].

In our case, the patient is young and fit for surgery, so we decided to use the technique of using saphenous vein spiral graft bypass between the IVC and the mid-portion of the LRV. The operation was done with no complication and the patient was found free of the previous complaints completely as he confessed on his first control as an outpatient.

The idea of using a spiral graft is to give enough graft diameter for the blood return from LRV. We have not used synthetic graft that has risks of thrombosis and infection [4].

Stenting treatment is one of the treatment methods which can be used in such cases but carries the risk of thrombosis, dislocation, and migration of the stent. In a retrospective study done in 2011, the authors found that the majority of the patients (96%, 59 of 61) who had been treated with stenting of the LRV for nutcracker syndrome continued complaining of flank pain and hematuria for about 6 months post-procedure. Stent, thrombosis, migration, and dislodgement were also reported [5].

Transposition of the LRV and renal autotransplantation are other open surgical treatment methods, they are more aggressive procedures and carry the risks of ischemia and hematoma. SMA transposition

surgical technique has the risk of possible SMA thrombosis and bowl ischemia so, the higher postoperative complication rate has minimized the popularity of this technique [6].

We preferred to use the surgical techniques of spiral vein graft to be far from the possible complications that may result from the other techniques such as thrombosis, dislocation, and migration of the stents in stenting technique, or ischemia of the bowls or kidney in SMA transposition technique, or hematoma and the possible need of nephrectomy in the transposition of the LRV and renal autotransplantation.

Intraoperatively, when we used side clamps for both IVC and LRV we did not occlude the blood return of the renal vein or IVC, so there was no need to clamp the renal artery and leaving the left kidney under the risk of ischemia.

In conclusion; many surgical techniques can be used in managing patients with nutcracker syndrome. Using a saphenous vein spiral graft has the advantages of being a biological graft with less possibility of occlusion or infection besides it has enough diameter to be suitable for the renal vein. Applying side clamps instead of cross clamps in this technique keeps the return of the blood flow from the kidney and does not require arterial clamping. This surgical technique can be done successfully with Satisfying results.

Declarations

Funding:

The authors received no financial support for the research and/or authorship of this article.

conflicting interests:

All the authors declared no conflicts of interest concerning the authorship and/or publication of this article.

Ethics approval:

the ethical approval has been taken from the patient himself to publish his case and photos of the operation.

Consent to participate:

Informed consent has been obtained from the patient for participation and publication of his case report and accompanying images.

Consent for publication:

Informed consent has been obtained from the patient for participation and publication of his case report and accompanying images.

Availability of data and material (data transparency):

available.

Code availability (software application or custom code):

It is a case report.

Authors' contributions:

Mohammad Alşalaldeh (corresponding author): designer and writer othe paper.

Ali Vefa ÖZCAN: Co-author.

Gökhan Yiğit TANRISEVER: Co-author

References

1. Ananthan K, Onida S, Davies AH. Nutcracker syndrome: an update on current diagnostic criteria and management guidelines. European journal of vascular endovascular surgery. 2017;53(6):886–94.
2. Alaygut D, Bayram M, Soylu A, Cakmakcı H, Türkmen M, Kavukcu S. Clinical course of children with nutcracker syndrome. Urology. 2013;82:686–90.
3. Said SM, Gloviczki P, Kalra M, Oderich GS, Duncan AA, Fleming D. M, et al. Renal nutcracker syndrome: surgical options. Semin Vasc Surg. 2013;26:35–42.
4. Pennel T, Zilla P. Clinical Applications and Limitations of Vascular Grafts. Tissue-Engineered Vascular Grafts 2020;3–34.
5. Chen S, Zhang H, Shi H, Tian L, Jin W, Li M. Endovascular stenting for treatment of Nutcracker syndrome: report of 61 cases with long-term followup. J Urol. 2011;186:570e5.
6. Reed NR, Kalra M, Bower TC, Vrtiska TJ, Ricotta 2nd JJ, Gloviczki P. Left renal vein transposition for nutcracker syndrome. J Vasc Surg. 2009;49:386e93. discussion 393e4.

Figures

Figure 1

CT-Scan with contrast showing the LR V compressed between SMA and abdominal aorta

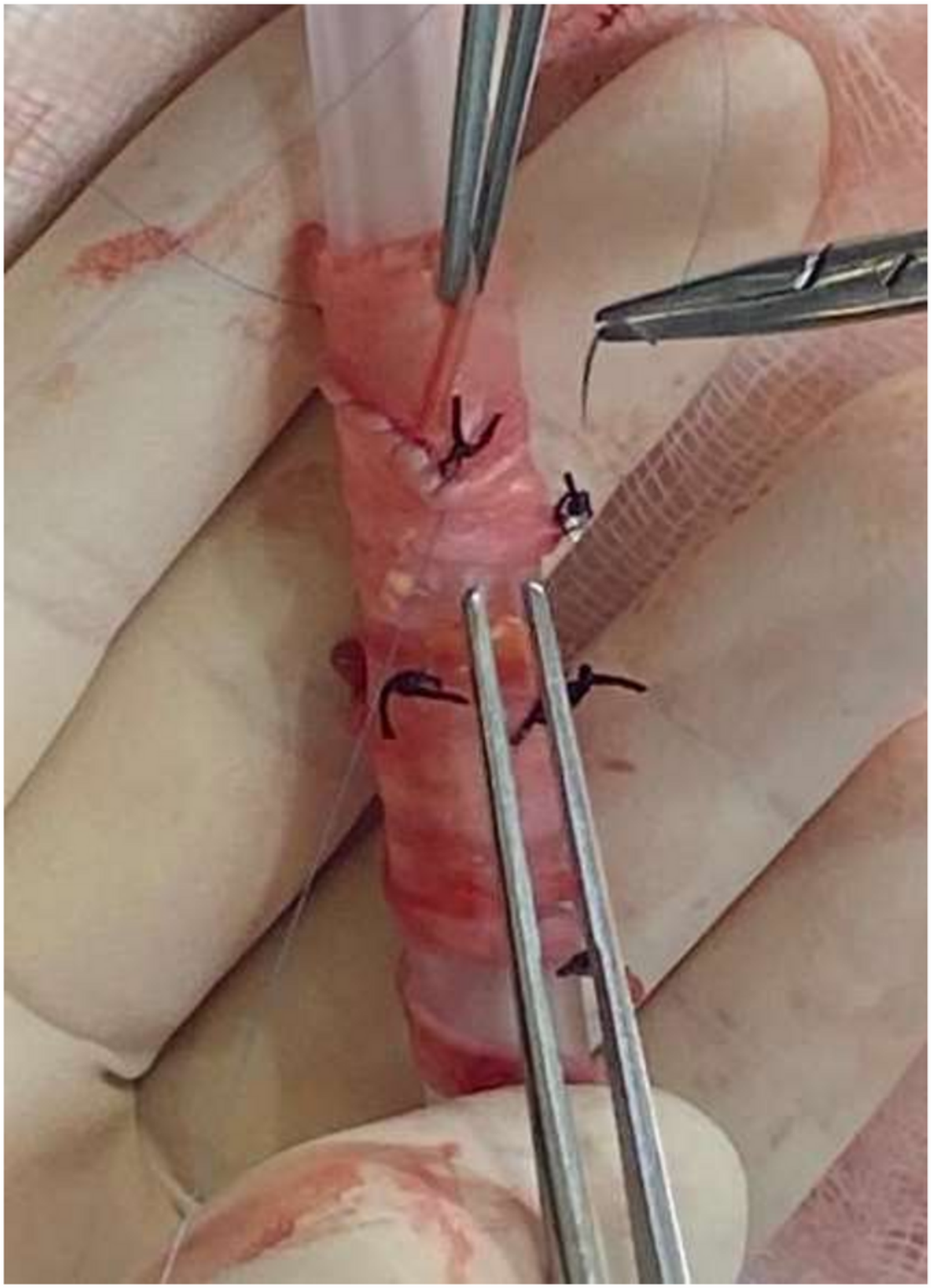

Figure 2

preparation of the spiral saphenous vein graft

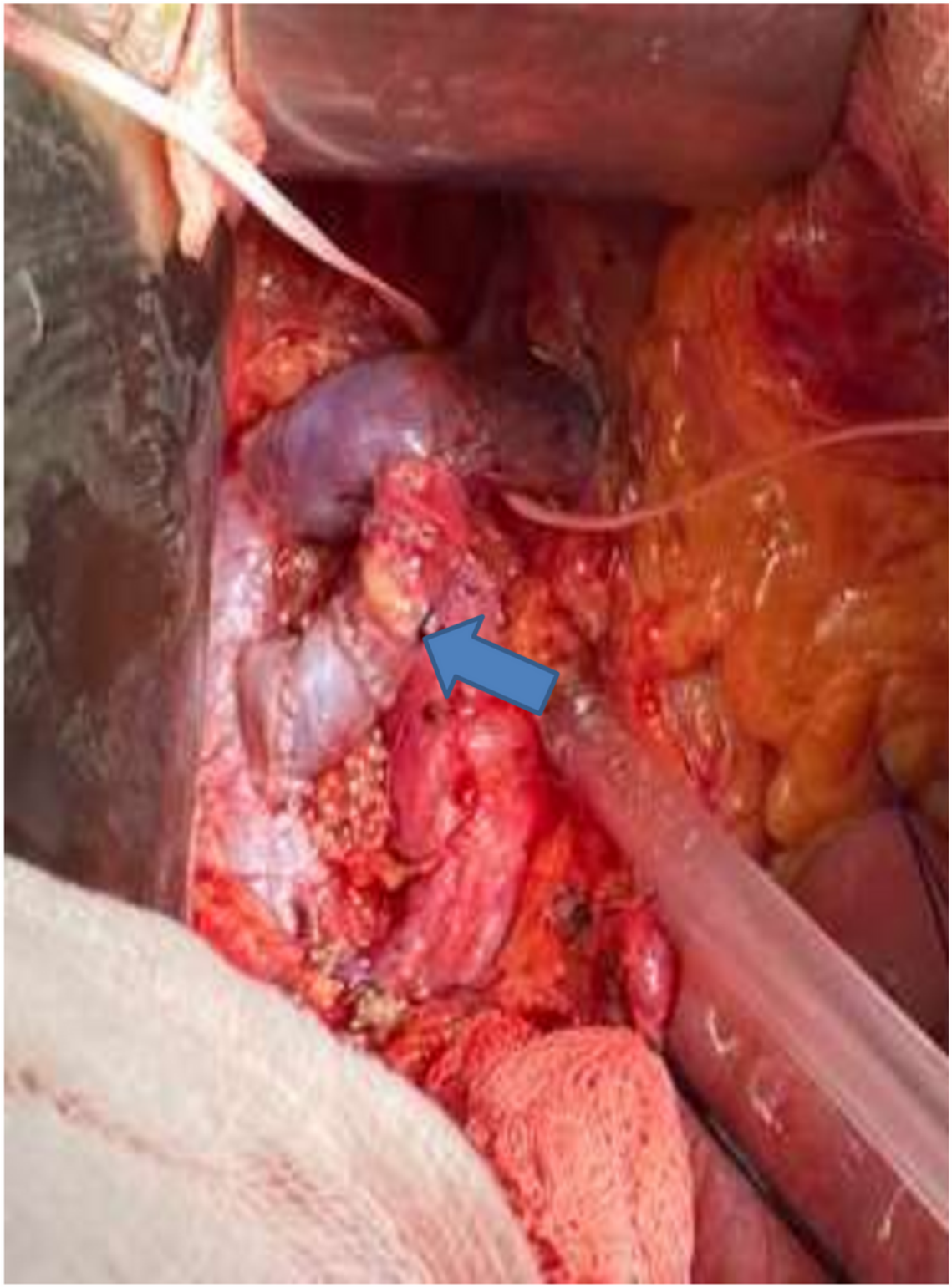

Figure 3

spiral saphenous vein graft after had been anastomosed in (end-to-side) fashion to the LRV and IVC