# Acute clouding of hydrophilic acrylic copolymer intraocular lenses:four cases report

**Xiaochen Wang**
Shandong Eye Institute https://orcid.org/0000-0001-6509-4990

**Yusen Huang** ( Huang_yusen@126.com )
Shandong Eye Institute

**Xiaoming Wu**
Shandong Eye Hospital

**Case Report**

**Keywords:** Opacification, transient, temperature, material, cataract

**Posted Date:** February 14th, 2019

**DOI:** https://doi.org/10.21203/rs.2.333/v1

# Abstract

**Background:** Intraoperative acrylic intraocular lenses (IOLs) transient clouding of several kinds of hydrophilic IOLs have been reported due to temperature changes. However, we ignored the particularity of its material and the handling methods.

**Case presentation:** We present four cases of acute clouding of hydrophilic acrylic intraocular lenses (IOLs). Four patients underwent phacoemulsification cataract surgery with implantation of L-312, 809M, and 839M IOLs, respectively. The IOLs became opaque in varying degrees during surgery. Lens replacement was performed immediately in one case, while the cloudy IOLs were remained in the other three cases. Postoperatively, all IOLs recovered transparency.

**Conclusions**Temperature fluctuation was the cause of the acute opacification of these IOLs made of hydrophilic acrylic copolymers, which reminds us of attaching importance to the temperature of IOL storage and delivery in winter months.



**Keywords:** Opacification, transient, temperature, material, cataract.


# Background

Opacity of acrylic intraocular lenses (IOLs) is an uncommon complication during cataract surgery. In the past decade, intraoperative transient clouding of a few kinds of acrylic IOLs has been reported due to temperature changes in winter. [1-4] In our practice, we encountered four cases of IOL opacification during implantation and evaluated the possible causes. The aim of this report was to emphasize the importance of storage and delivery in an appropriate temperature for hydrophilic acrylic copolymer IOLs and recommend proper handling for such IOL clouding.

# Case Presentation

### Case 1

A 64-year-old woman with a cortex cataract in the right eye received phacoemulsification with implantation of the LENTIS L-312 lens (Oculentis; +21.0 D, SN: 91306104022). It had taken over one hour for the supplyer to deliver the IOL at an outdoor temperature of around −3 °C. After kept in the theater (21 °C) for about 2 hours, the IOL was implanted into the eye, but the lens optic became cloudy immediately (Fig. 1A). This was the first time that we encountered such a situation. The surgeon replaced the IOL with another LENTIS L-312 lens at once, and the same phenomenon was observed (Fig. 1B). The second IOL was not removed, and the surgery was completed. Under a slit-lamp microscope, the opacification was found to be alleviated after 2 hours (Fig. 1C). On postoperative day 1, the IOL became transparent (Fig. 1D). Best corrected visual acuity (BCVA) was improved from preoperative 20/40 to 20/25.

### Case 2

Uneventful cataract surgery was performed on the left eye of a 54-year-old man with a cortex cataract, and a +19.5 D acrylic IOL (AL LISA tri 809M; Carl Zeiss, SN 1S1710870057) was implanted. His preoperative BCVA was 20/50. Before implantation, the lens had been stored at room temperature for 1.5 hours following 1-hour transportation at an outside temperature of -8 °C. A few seconds after the IOL was placed into the capsular bag, clouding occurred (Fig. 2A) and failed to clear after 5 minutes. The surgery was completed. On the following day, the lens was detected to be clear without any abnormality (Fig. 2B), and BCVA was measured to be 20/20.

### Case 3

A 62-year-old woman with cortex cataracts in both eyes was scheduled to undergo phacoemulsification. A +21.5 D acrylic IOL (AL LISA tri 809M; Carl Zeiss, SN 1S1713970329) was first implanted into the left eye after 1-hour delivery when the temperature outside was −8 °C and 2-hour placement in the theater. The IOL was transparent prior to implantation (Fig. 3A). As the IOL was implanted into the capsular bag, it became cloudy immediately (Fig. 3B). The opacification disappeared spontaneously on the following day (Fig. 3C). Three days later, another +22.0 D IOL (AL LISA tri 809M; Carl Zeiss, SN 1S1715830258), which had been stored in the theater for 3 days, was inserted into the right eye after cataract extraction, and no opacification occurred.

### Case 4

Cataract surgery was uneventfully performed on the left eye of a 46-year-old man with a cortex cataract, and a +19.0 D acrylic IOL (AL LISA tri 839M; Carl Zeiss, SN 1S1706750238) was implanted to correct his vision, which was finger counting before the eye. The IOL was delivered to the theater at an outdoor temperature of −4 °C and 3 hours ahead of the implantation. As the IOL was placed into the eye, it became opacified (Fig. 4A). After irrigation, the IOL started to clear (Fig. 4B).

## Discussion

Temperature changes can impact on the biological characteristics of crystals and thus cause IOL opacification.[5-7] Acrylics and many other polymers show viscous flows at temperatures above Tg, from their rigid glassy state to soft rubbery state.[8] Lower the Tg of the material, more deformable and easily foldable the lens is.[9] When the environment temperature is low, an unfolded hydrophobic lens becomes hard.[7,8]It was also reported that the change in the equilibrium water content caused by temperature fluctuation between 30 °C and 40 °C is an important factor in glistening formation.[10] Temporary turbidity of acrylic IOLs related to temperature difference is not common, but once it occurs, panic may be generated by both the surgeon and the patient.[1-4] Replacement of the clouded IOL was performed sometimes. In one report, [3] the patient waited for the substitutional IOL for more than an hour on the operating table. This should be avoided for the increased risk of intraoperative infection.

All our cases occurred in winter, when the outdoor temperatures were below zero（Table 1）. We noted that the lower the outdoor temperature, and the shorter the indoor placement time, more seriously the IOLs were affected. In Case 4, the IOL was stored in the room for a comparatively long time, and the turbidity was light and disappeared during surgery. We also found that the clouded IOLs were all hydrophilic acrylate lenses with a hydrophobic surface. Such materials seem to be liable to suffer temporary clouding. The IOLs of a single material, such as a completely hydrophobic or hydrophilic material (Softec HD, AO, and iSert251), however, were not found to have any acute clouding because of the sudden temperature changes in our institution.  Another factor may be the pure water in the sterile bottle which could not rise to the room temperature in a short period of time and was imbibed by the composite lens material from the anterior chamber because of temperature gradient. As a matter of fact, the instructions to the IOLs remind us of the possibility of clouding. For the L-312 lens, it is suggested to be transported at an environment temperature between 5 °C and 50 °C and stored at room temperature for at least 1 hour before use. For the AT LISA 809M crystal, room temperature is indicated at the time of surgery to avoid temporary clouding of the lens optic after implantation. Fortunately, no permanent structural or mechanical change of the IOLs occurred in our cases. We should attach importance to the manufacturers' recommendation and particularly to the correct storage of IOLs.

# Conclusions

In conclusion, this IOL clouding phenomenon, which is rarely encountered clinically, may take place in cold winter months. Hydrophilic acrylic copolymers are more likely to form this temporary turbidity. In light of this knowledge, it is usually unnecessary to replace the IOL. Moreover, the suppliers need to keep a correct warm temperature in the process of transportation and deliver the IOLs in advance in very cold days. It is favorable to store the artificial crystal in the operating room for at least 1 day to avoid any sudden temperature fluctuation in its surrounding environment.

# Abbreviations

BCVA：Best corrected visual acuity; IOL: intraocular lens;

# Declarations

**Acknowledgements** Not applicable.

**Funding** This study was supported by the Nation Nature Science Foundation of China(81670839) and Key Research and Development Project of Shandong Province(2018CXGC1205);No concrete role.

**Availability of data and materials** Not applicable.

**Authors’ contributions**

WXC and HYS were responsible for the conception and design of the study. WXC acquired the data. WXV analyzed and interpreted the data. WXC wrote the draft. HYS and WXC revised the manuscript critically. All authors have read and approved the final manuscript.

**Ethics approval and consent to participate** This study followed the tenets of the Declaration of Helsinki.

**Consent for publication** Written informed consent was obtained from the patients for publication of these case reports and any accompanying images.Copies of the written consent are available for review by the Editor of this journal.

**Competing interests** The authors declare that they have no competing interests.

# References


1. Helvaci S. Acute opacification of hydrophobic acrylic intraocular lens during implantation: result of temperature variation. Arquivos Brasileiros de Oftalmologia 2015; 78:267
2. Tyagi P, Shah N, Jabir M. Intraoperative clouding of a posterior chamber intraocular lens. Int Ophthalmol 2011; 31:483-484
3. Liu Q, Zhang S, Wang X, Cao W, Jia Y. Acute clouding of trifocal lens during implantation: a case report. BMC Ophthalmol 2017; 17:242
4. McKibbin M, Seemongal-Dass RR, Atkinson PL. Transient fogging of acrylic (Acrysof) intraocular lenses. Eye 1999; 13 (Pt 5):672-673
5. Werner L. Causes of intraocular lens opacification or discoloration. J Cataract Refract Surg 2007; 33:713-726
6. Gamidov AA, Fedorov AA, Novikov IA, Kas'yanov AA, Siplivyy VI. [Analyzing causes for opacification of acrylic IOLs]. Vestnik Oftalmologii 2015; 131:64-70
7. Tetz M, Jorgensen MR. New hydrophobic IOL materials and understanding the science of glistenings. Curr Eye Res 2015; 40:969-981
8. Jung GB, Jin KH, Park HK. Physicochemical and surface properties of acrylic intraocular lenses and their clinical significance. J Pharm Investig 2017; 47:453-460
9. Lee JY, Kim JY. Optic fracture of the preloaded intraocular lens during insertion. Korean J Ophthalmol 2016; 30:79-80
10. Miyata A, Yaguchi S. Equilibrium water content and glistenings in acrylic intraocular lenses. J Cataract Refract Surg 2004; 30:1768-1772


# Tables

Due to technical limitations, Table 1 has been placed in the Supplementary Files section.

# Figures

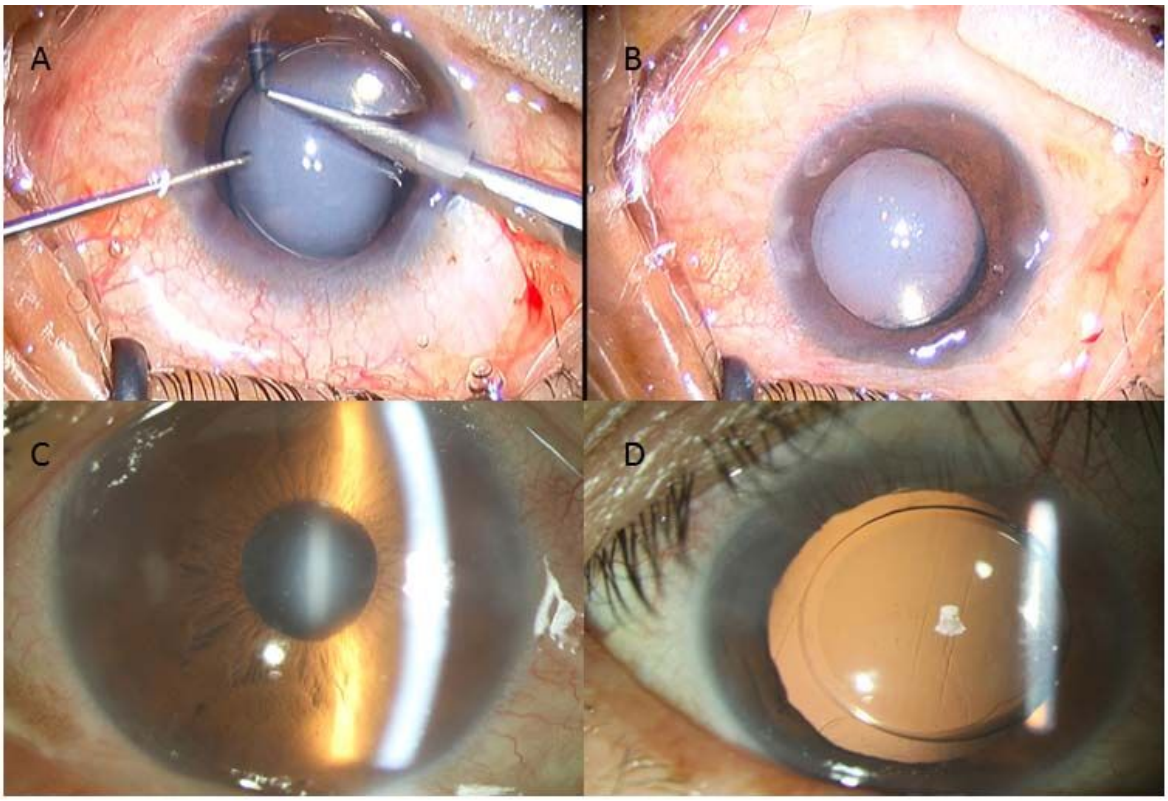


**Figure 1**

Case 1. A: The clouding of the optical region immediately after the IOL implantation. B: The opacification of the second IOL after implanted into the eye. C: Alleviated clouding 4 hours later. D: The transparent IOL at 1 day after surgery.

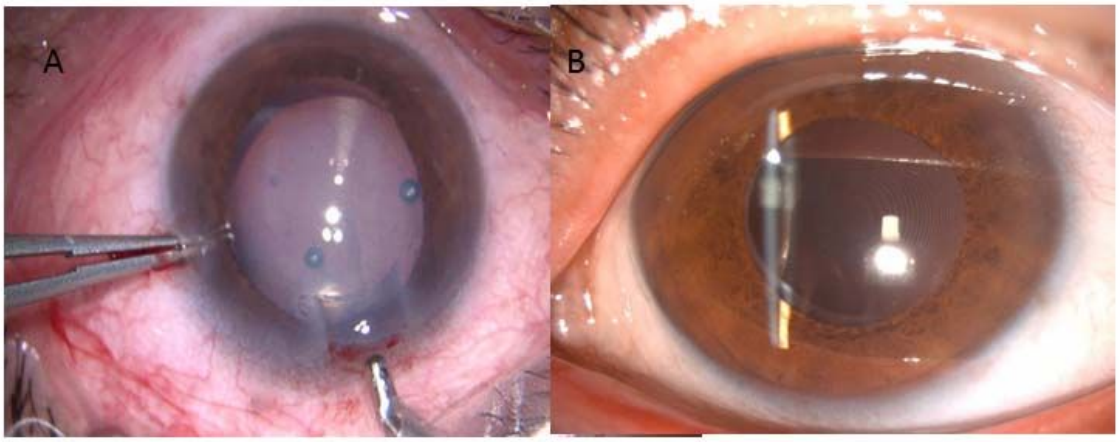


**Figure 2**

Case 2. A: Intraoperative IOL opacity. B: IOL transparency on postoperative day 1.

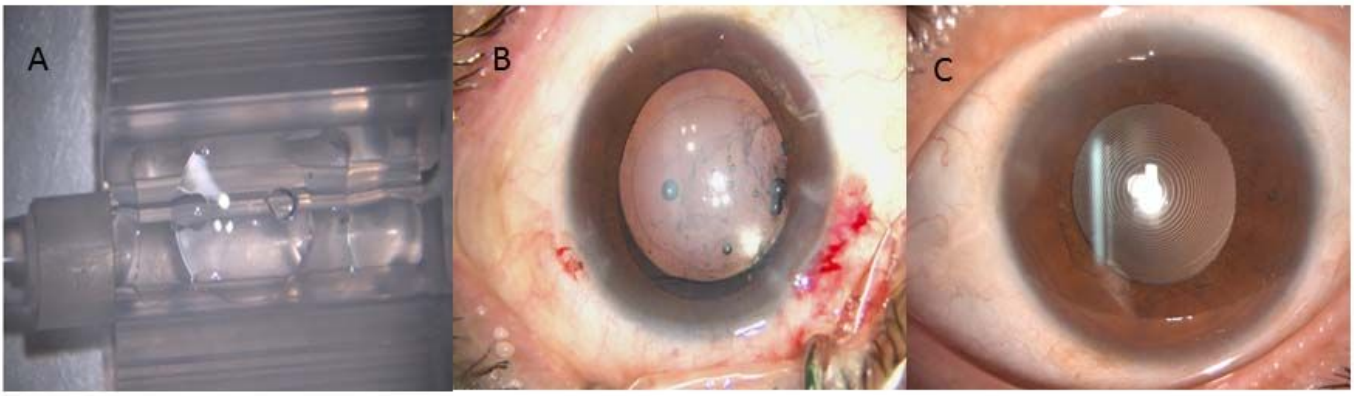


**Figure 3**

Case 3. A: The transparent IOL before use. B: Sudden intraoperative IOL clouding. C: The clear IOL at 1 day after surgery.

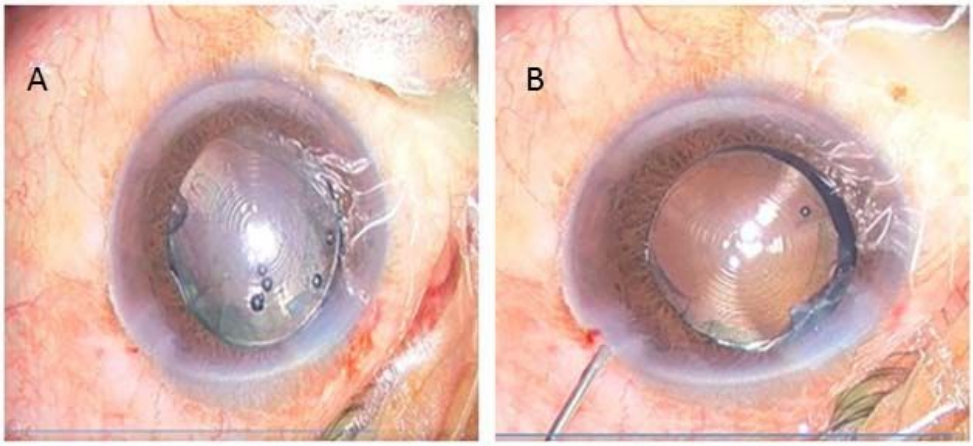


**Figure 4**

Case 4. A: Intraoperative IOL opacity. B: No opacification after irrigation.

## Supplementary Files

This is a list of supplementary files associated with this preprint. Click to download.

- supplement1.png
- supplement1.pdf