Changes in Local Bone Mineral Density in Patients With Rupture of the Anterior Cruciate Ligament and Its Guiding Significance for Treatment

Hao Liu
Wuxi Ninth People's Hospital affiliated to Soochow University https://orcid.org/0000-0002-1318-5783

Sanjun Gu
Wuxi Hand Surgery Hospital

Jun Liu
Wuxi Hand Surgery Hospital

Yongwei Wu
Wuxi Ninth People's Hospital affiliated to Soochow University

Yongjun Rui (wxjyryj@yeah.net)

Research article

Keywords: Bone mineral density, anterior cruciate ligament, ligament reconstruction, osteoporosis

Posted Date: June 12th, 2020

DOI: https://doi.org/10.21203/rs.3.rs-33751/v1

Abstract

Background: It is recognized that there are many factors that affect the outcomes of anterior cruciate ligament(ACL) reconstruction. However, there were few studies on the effect of local bone conditions on the reconstruction of the ACL. This study aimed to summarize the changes in local bone mineral density (BMD) of the knee after rupture of the ACL and to guide the treatment.

Methods: Eighty patients with ACL rupture treated in our department from January 2017 to April 2019 were routinely measured for local bone mineral density before surgery, and according to the bone mineral density, the appropriate method of ligament reconstruction and fixation under arthroscopy was selected: if the local bone mineral density of the affected knee was not significantly lower than that of the healthy side, squeeze fixation was used, and suspension fixation was used when the local bone mineral density of the affected knee was lower than that of the healthy knee. The conditions of tunnel cutting or screw splitting and tunnel enlargement or screw pull-out were observed during the operation, and the fixation mode was adjusted in time according to the situation. The function of the knee joint was evaluated regularly by physical examination, imaging data, the IKDC scale and the Lysholm score table after the operation.

Results:A total of 80 patients with unilateral ACL rupture were included in this group. There were 44 males and 36 females. Sixty-eight patients had decreased bone mineral density in the affected knee. The bone mineral density of patients with a history of more than 3 months was lower than that of patients with a history of less than 3 months. Tunnel enlargement and screw pull-out occurred in 2 patients, screw splitting occurred in 1 patient, and no adverse conditions occurred in the rest of the patients. In 3 patients, the fixation mode was adjusted in time during the operation. The patients were followed for 12 months (mean 20.65±5.12 months). The IKDC score increased from 43.07±2.66 before the operation to 89.17±3.28 at the final follow-up, and the Lysholm score increased from 43.49±2.38 to 89.67±2.97.

Conclusions: The measurement of local bone mineral density before surgery is of guiding significance for the selection of reconstruction and fixation of the ACL. It is recommended that patients undergo surgical reconstruction within 3 months after injury. When the bone mineral density of the affected knee decreases significantly to at least 70% lower than that of the healthy side, suspension fixation is recommended and the brace fixation time is prolonged.

Introduction

Anterior cruciate ligament (ACL) rupture is one of the most common injuries in sports medicine. With the development of minimally invasive concepts and the continuous maturity of arthroscopic technology, arthroscopic ACL reconstruction has become the main method for the treatment of this disease. However, there are still some patients who do not achieved very good results, and even need to undergo a second revision operation. How to reduce the failure rate of ACL reconstruction surgery is a hot topic in sports medicine at home and abroad. At present, it is recognized that the factors that affect the outcomes of

anterior cruciate ligament reconstruction include the choice of graft[1], the choice of fixation mode, the location of the bone tunnel and so on. However, there are few studies on the effect of local bone conditions on the reconstruction of the ACL[2, 3]. Some patients with abnormal bone around the knee joint will undergo screw splitting and pull-out during the operation[4]. Since January 2017, the local bone mineral density (BMD) of the affected knee has been measured routinely in patients with ACL rupture in our department, and the corresponding fixation methods have been selected according to the bone conditions of the patients, achieving good results reported as follows.

1 Data And Methods

1.1 General information

From January 2017 to April 2019, 80 patients with ACL rupture were treated surgically in our department:44 males and 36 females. The age ranged from 19 to 58 years old, with an average of 37.68 ± 9.13 years old. The time of injury ranged from 3 days to 12 months. There were 56 patients with a history of 3 months, 31 males and 25 females, with an average age of 37.70 ± 9.47 years. There were 24 patients with a history of more than 3 months, 13 males and 11 females, with an average age of 37.63 ± 8.46 years. All patients were injured in one knee:27 cases on the left and 53 cases on the right. X-ray film, magnetic resonance imaging and bone mineral density were measured in both knees routinely after admission. Case selection criteria[5]: 1. only ACL rupture (including meniscus tear) was found, excluding posterior cruciate ligament and collateral ligament rupture; 2. there was no history of knee joint trauma or surgery; 3. there was joint instability and a positive Lachman test or anterior drawer test; and 4. cases of primary osteoporosis (postmenopausal osteoporosis and senile osteoporosis) were excluded.

There is a standardized database reference for the bone mineral density T value of the lumbar vertebrae and hip joint, but there is no database comparison for the local bone mineral density of the knee joint. In this study, we compared the bone mineral density (g/cm^2) of the affected knee joint with that of the healthy knee joint[6]. The results were statistically analysed by paired t tests. The measuring instrument was American Norland XR-36 dual energy X-ray absorptiometry.

1.2 Surgical Methods

1.2.1 Selection of operative methods

In this study, patients were grouped according to the degree of decrease in local bone mineral density before the operation: the density of the affected knee was not significantly lower than that of the healthy side (normal bone mineral density group), the local bone mineral density of the affected knee was lower than 70% of the healthy side (low bone mineral density group), and the local bone mineral density of the affected knee decreased but not by more than 30% of the healthy side. If tunnel cutting or screw splitting and tunnel enlargement or screw pull-out occurred during the operation, the fixation mode was adjusted

in time according to the situation: an additional plate with a loop was used for suspension fixation at the outer entrance of the tunnel, and if the tunnel was obviously enlarged, it was necessary to carry out artificial bone grafting[7].

1.2.2 Extrusion Fixation Method

After successful anaesthesia, the patient was placed in the supine position, and the affected limb was placed in the 90°flexion position. Routine disinfection and towel laying were performed. An anterior medial L-shaped incision was made under the tibial tubercle of the knee, the semitendinosus tendon and gracilis tendon were cut, the muscle was removed, and the tendon line was woven at both ends. At the level of the knee joint space, an opening of 8 mm was made on both sides of the patellar ligament to the articular cavity, which was disposed into the arthroscope from the lateral entrance, additionally, the intercondylar fossa was cleared, and the scar tissue and residual ACL were removed. The tibial end of the ACL was located with a guide needle, and the tibia of the corresponding diameter was drilled to open the tibial tunnel. Then, the femoral footprint of the ACL was located with a guide needle, and the femur drill was used to open the femoral tunnel by approximately 35 mm. The braided tendon was introduced with the guide needle, and the knee was flexed by 20°. Reverse traction was implemented at both ends of the femur and tibia to maintain a certain tension, and passive movement of the affected knee was carried out to provide appropriate tension of the tendon. The femoral tunnel was fixed with a 25 mm long polylactic acid hydroxyapatite screw. The tibial tunnel was fixed with a tibial fixation wing and a 25 mm long polyetheretherketone screw (both screws and wings were produced by Smith & Nephew). The knee was moved passively, and the anterior drawer test was performed. If the knee joint was stable and the autologous tendon tension was moderate, then suturing and pressure bandaging were performed. If screw splitting or tendon cutting occurred during the operation, the mode of fixation was adjusted to suspension fixation. If the tunnel was enlarged or screws were pulled out due to osteoporosis during the operation, adjustment to suspension fixation could be carried out. Alternatively, on the basis of extrusion fixation, a loop steel plate was added to the outer entrance of the tunnel to carry out suspension fixation. If the tunnel was obviously enlarged, it was necessary to carry out artificial bone grafting[8].

1.2.3 Suspension Fixation Method

Harvesting of the transplanted tendon and the cleaning process of the joint cavity were carried out in the same manner as the extrusion fixation method. After the joint cavity was cleaned, the guide needle was used to locate the tibial attachment of the ACL, and the tibia was drilled to expand the tibial tunnel. Then, the femoral footprint of the ACL was located, and the femur was drilled and enlarged by approximately 35 mm in a long tunnel. The guide needle was introduced into the autologous tendon, which was pulled at both ends of the tunnel to provide a certain tension; passive movement of the affected knee was carried out, providing the autologous tendon with the appropriate tension. A plate with a loop (Smith & Nephew) was used, the loop was cut, the tendon traction line was passed through both of the plate holes

outside the thigh, and the plate was pushed forward to make sure the plate was adhered to the femoral cortex; multiple knots were made on the surface of the plate so that the plate was firmly stuck at the outer entrance of the femoral tunnel to achieve suspension fixation. The outer entrance of the tibial tunnel was also suspended and fixed with a plate with a loop. The affected knee was moved passively again, and the anterior drawer test was performed. If the knee was stable and the tension of the transplanted tendon was moderate, the knee was sutured and bandaged under pressure.

1.3 Postoperative Management

After the operation, a local cold compress was applied, the affected limb was raised, hinge braces were worn, and isometric contraction training of the quadriceps femoris and hamstring muscles was performed every day. One to two weeks after the operation, the affected limb was locked in a completely straight position, and the use of double crutches was supported until complete loading. Passive flexion and extension could be performed daily starting 3 to 4 weeks after the operation, reaching knee flexion ≥ 120°. Five to eight weeks after the operation, the affected knee joint could be actively moved to reach 90° of knee flexion, and semi-squatting exercises could be used to improve muscle strength. Starting at the 9th week after the operation, forward uniform speed running and backward running could be carried out.

1.4 Postoperative Follow-up And Evaluation Of The Curative Effect

The patients were followed 1 month, 2 months, 3 months, 6 months and 12 months after the operation. All patients were examined by the anterior drawer test and Lachman test. Patients with suspension fixation were re-examined by X-ray, and squeeze fixation did not need to be photographed because the screw was not visible. The function of the knee joint was evaluated by the IKDC scale score and Lysholm knee joint scale score.

1.5 Statistical Processing

The data of this study were analysed by the statistical software SPSS 19.0, and the measurement data were expressed as the mean ± standard deviation. Paired t-tests were used to compare the bone mineral density of both knee joints and the functional score of the affected knee before and after the operation. Group t-tests were used to compare the decreasing degree of bone mineral density within 3 months and more than 3 months. $P < 0.05$ was considered statistically significant.

2 Results

The measurement of local bone mineral density of the knee joint in 80 patients showed that 68 patients had varying degrees of bone mass loss relative to the healthy side. The BMD of the contralateral knee

joint was 1.256 ± 0.153 g/cm^2, and that of the affected knee was 0.927 ± 0.283 g/cm^2; the difference was statistically significant (Table 1). There was no significant difference in age or sex between patients with a history of less than 3 months and those with a history of more than 3 months.According to the degree of decrease in bone mineral density, the local bone mineral density of the affected knee was less than 70% of the contralateral value in 28 patients and higher than 70% of the contralateral value in 40 patients. The longer the time after injury, the more obvious the decrease was in relative bone mineral density. In this group of patients, the BMD of the affected knee was 0.956 ± 0.217 g/cm^2 for those with a history of less than 3 months and was 0.914 ± 0.176 g/cm^2 for those with a history of more than 3 months. The difference was statistically significant (Table 2).

Table 1
Comparison of local BMD of bilateral knee joints(g/cm^2)

	Local BMD
Non-operated sides	1.256 ± 0.153
Operated sides	0.927 ± 0.283
t	10.18
P	0.00

Table 2
Comparison of the decreasing degree of local BMD(g/cm^2)

	Non-operated sides	**Operated sides**	**Relative decline**	**t**	**P**
TFIS < 3m(56 cases)	1.266 ± 0.113	0.956 ± 0.017	0.228 ± 0.082	20.30	0.00
TFIS > 3m(24 cases)	1.237 ± 0.132	0.914 ± 0.076	0.345 ± 0.036	10.39	0.00
t	0.99	3.94	6.70	-	-
P	0.32	0.00	0.00	-	-
TFIS: Time from injury to surgery					

All patients were followed for 12 to 30 months (mean 20.65 ± 5.12 months). During the last follow-up, the symptoms of knee instability disappeared in all patients before the operation, 5 patients complained of mild knee pain, and physical examination showed that the results of the Lachman test and anterior drawer test were negative. At the last follow-up, the IKDC score of the affected knee was 89.17 ± 3.28, and the Lysholm knee score was 89.67 ± 2.97, which were significantly higher scores than those before the operation, and the difference was statistically significant (Table 3). The range of motion and muscle function of the knee joints of all patients returned to normal. In the normal bone mineral density group, tunnel enlargement and screw pull-out occurred in 2 patients, and screw splitting occurred in 1 patient.

Among them, the patients with screw splitting and tunnel enlargement were adjusted to suspension fixation in time during the operation, and the other patient with tunnel enlargement was fixed by suspension with a plate with a loop on the basis of extrusion fixation. All 3 patients recovered well after follow-up.

Table 3
Comparison of IKDC and Lysholm functional score of affected knee

	IKDC score	Lysholm score
Before operation	43.07 ± 2.66	43.49 ± 2.38
Last follow-up	89.17 ± 3.28	89.67 ± 2.97
t	97.64	108.53
P	0.00	0.00

3 Discussion

The anterior cruciate ligament (ACL) is a statically stable structure of the knee joint that plays an important role in the stability of the knee joint. Once injured, it is difficult to heal and can even lead to progressive meniscus and articular cartilage wear, so it is usually necessary to reconstruct the ligament under arthroscopy. ACL attachment fixation is the most important link in reconstruction surgery[9], and most reconstruction failures are caused by unstable attachment fixation[10]. Vopat et al.[11] believed that the failure of ACL reconstruction often occurs on the fixed side, not on the transplanted tendon itself. Through their experimental study, they believed that reliable postoperative immediate stability could be obtained by interfacial screw extrusion. Additionally, the operation of interface screw fixation is relatively simple, as long as it is screwed into the tunnel along the guide needle. Therefore, in the past, when dealing with this kind of disease, our department usually chose the method of extrusion fixation and achieved good results. However, with the increase in the number of surgical cases, we found that a small number of patients had symptoms of ligament relaxation and joint instability after the operation, especially in elderly women and patients with old injuries. Therefore, we inferred that the local bone mass of the affected knee decreased due to postmenopausal osteoporosis and disuse bone atrophy, thus reducing the holding force of the screw[12, 13]. Therefore, starting from January 2017, we routinely measured the local bone mineral density of both knees and took an X-ray of the affected knee in the patients with ACL rupture in our department before surgery, evaluated the bone condition of the affected knee, selected the ACL attachment fixation method according to the decreasing degree of bone mineral density, and achieved good results.

For ACL rupture, the common attachment fixation methods in our department include extrusion fixation and suspension fixation[14]. For suspension fixation with plates, it was previously believed that because it was far away from the normal ACL anatomical attachment, the longitudinal movement between the

autogenous tendon and the bone canal could produce a "bungee jumping" effect, and the transverse movement could produce a "wiper" effect, which led to the enlargement of the bone tunnel, and synovial fluid immersion would also affect the tendon-bone healing. However, through interface screw extrusion fixation, we can operate under direct vision, according to hand feeling and mirror observation, and this method is more firm and reliable. The polylactide hydroxyapatite screw does not need to be removed for the second time and does not affect the magnetic resonance examination. Therefore, in general, we usually prefer the extrusion fixation method. However, extrusion fixation is not an omnipotent fixation method, and its indication and curative effect are closely related to the local bone condition of the affected knee[15]. Through previous surgical observations, we found that some patients suffered from screw splitting and that the transplanted tendon was cut by the edge of the bone tunnel when squeezing the screw. In addition, some patients suffered from screw loosening or even pull-out and bone tunnel enlargement when the knee was passively moved during the operation[16]. Therefore, there are still some limitations in extrusion fixation. During the operation, once a bad condition occurs during extrusion fixation, immediate adjustment to the suspension fixation mode should be carried out. When the plate with a loop is used for suspension fixation, the attachment crosses the outer entrance of the bone tunnel, and there is no need to consider the effect of bone condition, so it can be used for patients with osteoporosis and osteosclerosis. The force provided by suspension fixation and the contractile force of the transplanted tendon belong to a pair of acting forces and reaction forces, which are kept in a straight line in the opposite direction and have a strong anti-pull-out ability. The stress is concentrated between the plate and the outer entrance of the tunnel, and the suspension force is positively correlated with the contact area between them.

For some patients, especially those with old ACL fractures (course of disease > 3 months), firm fixation with screws is usually difficult because of the local osteoporosis during the operation. Flexion and extension of the affected knee several times during the operation can lead to screw loosening, tendon relaxation and, finally, suspension fixation. If the preoperative equipment is not fully prepared and the fixed mode cannot be adjusted in time, benefits can be lost and concerns will ensue.

Preoperative bone mineral density examination, combined with X-ray film, can help doctors more accurately understand the bone condition around the knee joint and guide the preoperative preparation and selection of knee joint functional reconstruction. If the bone mineral density of patients is different, the appropriate individual fixation method will accordingly be adopted. For patients with old injuries, due to a long-term lack of exercise, there is usually severe osteoporosis in the affected knee, so we can guide them to carry out functional exercises in the outpatient clinic, provide anti-osteoporosis treatment with drugs, after a period of preparation, and then perform the reconstructive operation in order to reduce the risk of extrusion fixation failure. Even if the osteoporosis of the patient does not improve and the local bone mineral density of the affected knee is always less than 70% of the contralateral value, we can still complete ACL reconstruction by suspension fixation. However, the time of external fixation must be extended appropriately to ensure the curative effect.

We are still constantly evaluating how much the reduction of bone mineral density is suitable for each fixation method due to the lack of clinical data. In addition, this was not a randomized controlled study, and the intraoperative fixation method was changed according to the intraoperative conditions, which requires a certain degree of experience. According to the experiences and lessons of our department in recent years, we believe that for those with normal bone, extrusion fixation should be selected. Suspension fixation should be used for those whose local bone mineral density is lower than 70% of the healthy side. For those whose local bone mineral density of the affected knee is decreased but not lower than 70% of the healthy side, extrusion fixation is preferred. We suggest that anterior cruciate ligament reconstruction should be carried out within 3 months after injury to avoid a further decrease in the bone mass of the affected knee and to avoid affecting the outcomes of fixation. Of course, even according to the above criteria, there will still be cases of fixation failure in individual patients, so for each patient, we must consider the operation plan as a whole, including the patient's age, sex, past history, injury time, and so on. Only in this way can we maximize the effectiveness of the operation.

Abbreviations

ACL
anterior cruciate ligament; BMD:bone mineral density; TFIS:Time from injury to surgery

Declarations

Ethics approval and consent to participate

The study protocol was approved by the ethics committee of Wuxi NinthPeople's Hospital affiliated to Soochow University.

Consent for publication

All authors agree to publish.

Availability of data and materials

The datasets used and analyzed during the current study are available from the corresponding author on reasonable request.

Competing interests

All authors have no conflicts of interest to disclose. All authors have read and approved the final submitted manuscript.

Funding

Not applicable.

Authors' contributions

Hao Liu and Sanjun Gu designed the study. Yongwei Wu, Jun Liu and Sanjun Guperformed the operations. Hao Liu collected the clinical data, and completed the manuscript. Yongjun Rui participated in theoperations and was the team leader. All authors have no conflicts of interest todisclose. All authors have read and approved the final submitted manuscript.

Acknowledgements

No.

References

1. Kang RW, Strauss EJ, Barker JU, Bach BR. Jr. Effect of donor age on bone mineral density in irradiated bone-patellar tendon-bone allografts of the anterior cruciate ligament. Am J Sports Med. 2011;39(2):380–3.
2. Stener S, Kartus J, Ejerhed L. Anterior cruciate ligament reconstruction reduces bone mineral areal mass. Arthroscopy: the journal of arthroscopic related surgery : official publication of the Arthroscopy Association of North America the International Arthroscopy Association. 2013;29(11):1788–95.
3. Mariani PP, Margheritini F, Bellelli A. Bone mineral density of the proximal metaphysis of tibia: clinical relevance in posterior cruciate ligament reconstruction. Knee Surg Sports Traumatol Arthrosc. 2005;13(4):263–7.
4. Balci A, Gezer NS, Tatari MH, Erduran M, Saleky B, Kaya E, Ozaksoy D. Measurement of regional trabecular bone attenuation of the knee following anterior cruciate ligament rupture. Arch Orthop Trauma Surg. 2016;136(10):1453–7.
5. Mansson O, Sernert N, Ejerhed L, Kartus J. Long-Term Examination of Bone Mineral Density in the Calcanei After Anterior Cruciate Ligament Reconstruction in Adolescents and Matched Adult Controls. Arthroscopy: the journal of arthroscopic related surgery : official publication of the Arthroscopy Association of North America the International Arthroscopy Association. 2016;32(4):615–23.
6. van Meer BL, Waarsing JH, van Eijsden WA, Meuffels DE, van Arkel ER, Verhaar JA, Bierma-Zeinstra SM, Reijman M. Bone mineral density changes in the knee following anterior cruciate ligament rupture. Osteoarthritis cartilage. 2014;22(1):154–61.
7. Zong JC, Ma R, Wang H, Cong GT, Lebaschi A, Deng XH, Rodeo SA. The Effect of Graft Pretensioning on Bone Tunnel Diameter and Bone Formation After Anterior Cruciate Ligament Reconstruction in a Rat Model: Evaluation With Micro-Computed Tomography. The American journal of sports medicine 2017, 45(6): 1349–1358.
8. Uchida R, Toritsuka Y, Mae T, Kusano M, Ohzono K. Healing of tibial bone tunnels after bone grafting for staged revision anterior cruciate ligament surgery: A prospective computed tomography analysis.

Knee. 2016;23(5):830–6.

9. Tie K, Wang H, Wang X, Chen L. Measurement of bone mineral density in the tunnel regions for anterior cruciate ligament reconstruction by dual-energy X-ray absorptiometry, computed tomography scan, and the immersion technique based on Archimedes' principle. Arthroscopy: the journal of arthroscopic related surgery : official publication of the Arthroscopy Association of North America the International Arthroscopy Association. 2012;28(10):1464–71.
10. Lee YS, Nam SW, Hwang CH, Lee BK. Computed tomography based evaluation of the bone mineral density around the fixation area during knee ligament reconstructions: clinical relevance in the choice of fixation method. Knee. 2012;19(6):793–6.
11. Vopat B, Paller D, Machan JT, Avery A, Kane P, Christino M, Fadale P. Effectiveness of low-profile supplemental fixation in anterior cruciate ligament reconstructions with decreased bone mineral density. Arthroscopy: the journal of arthroscopic related surgery : official publication of the Arthroscopy Association of North America the International Arthroscopy Association. 2013;29(9):1540–5.
12. Domnick C, Herbort M, Raschke MJ, Habermann S, Schliemann B, Petersen W, Weimann A. Anterior Cruciate Ligament Soft Tissue Graft Fixation in the Elderly: Is There a Reason to Use Interference Screws? A Human Cadaver Study. Arthroscopy: the journal of arthroscopic related surgery : official publication of the Arthroscopy Association of North America the International Arthroscopy Association. 2017;33(9):1694–700.
13. Mundermann A, Payer N, Felmet G, Riehle H. Comparison of volumetric bone mineral density in the operated and contralateral knee after anterior cruciate ligament and reconstruction: A 1-year follow-up study using peripheral quantitative computed tomography. Journal of orthopaedic research: official publication of the Orthopaedic Research Society. 2015;33(12):1804–10.
14. Meller R, Neddermann A, Willbold E, Hesse E, Haasper C, Singh A, Knobloch K, Krettek C, Hankemeier S. The relation between tunnel widening and bone mineral density after anterior cruciate ligament reconstruction: an experimental study in sheep. Arthroscopy: the journal of arthroscopic related surgery : official publication of the Arthroscopy Association of North America the International Arthroscopy Association. 2010;26(4):481–7.
15. Jarvinen TL, Nurmi JT, Sievanen H. Bone density and insertion torque as predictors of anterior cruciate ligament graft fixation strength. The American journal of sports medicine 2004, 32(6): 1421–1429.
16. Germann M, Snedeker JG, Stalder M, Nuss KM, Meyer DC, Farshad M. Incorporating BMP-2 and skeletal muscle to a semitendinosus autograft in an oversized tunnel yields robust bone tunnel ossification in rabbits: Toward single-step revision of failed anterior cruciate ligament reconstruction. Knee. 2018;25(5):765–73.

Figures

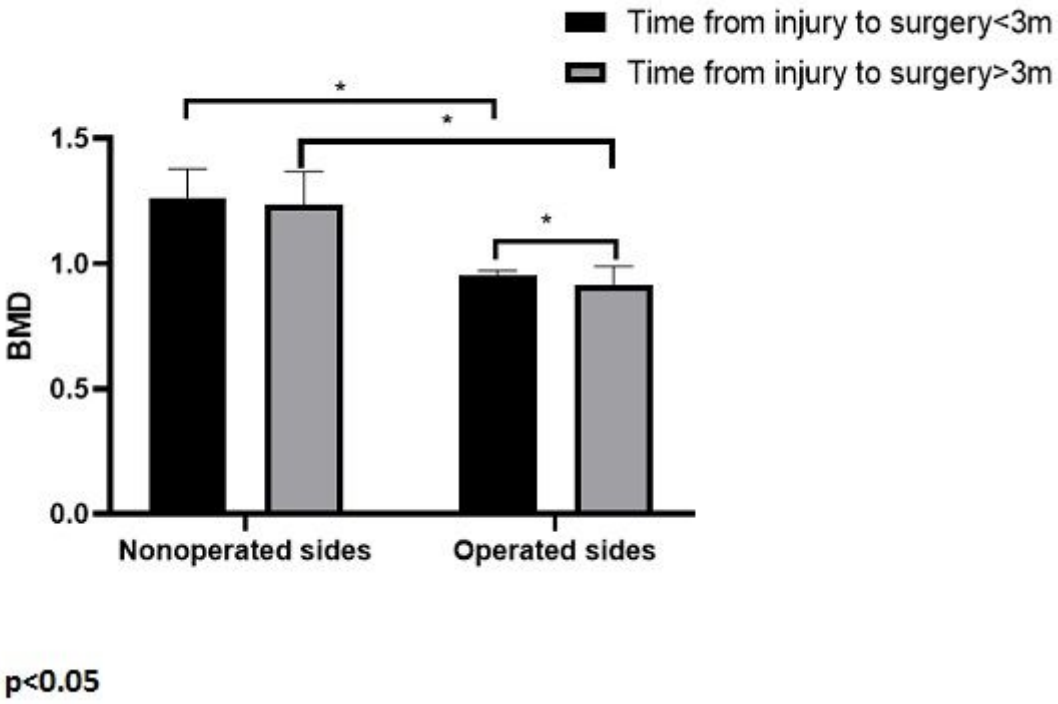

Figure 1

Comparison of the decreasing degree of local BMD

Figure 2

A 39-year-old male, rupture of anterior cruciate ligament of left knee, screw fixation under arthroscopy was performed 16 months after injury. Passive movement during operation showed enlargement of femoral and tibial tunnels and loosening of screws. For strengthening, the miniature plate was used for suspension fixation on the basis of extrusion fixation.