Level of Excision Matters in Morton Neuroma Surgery.

metin uzun (drmetinuzun@gmail.com)
Acibadem University https://orcid.org/0000-0002-2911-4031

fatma tokat
Acibadem Maslak Hastanesi

Research article

Keywords: Morton neuroma, Excision, level

Posted Date: July 1st, 2020

DOI: https://doi.org/10.21203/rs.3.rs-33754/v1

Abstract

Introduction:

Morton’s neuroma (MN) is mechanical neuropathy of plantar interdigital nerve. It is one of the most common causes of forefoot pain. One of the most undesirable complications of MN surgery is recurrent neuroma. Excision level of MN is important to prevent recurrence. In this study, we aimed to figure out preferred excision levels of orthopedic surgeons by evaluating pathological samples.

Methods:

192 samples sent with the diagnosis of Morton neuroma to the pathology department of our hospital between years 2010-2017 were added to our study. Mean age was 45,8 (between 23 to 73). All of 192 patients were primary diagnosed 22 of them was left foot and the other 170 were right foot was. 139 of them were female, and 53 were male. Recurrent neuromas, pathological sample more than one piece from one surgical site were excluded from the study.

Results:

192 pathological specimens were prepared and examined by the same pathologist. Gross pathological appearance and histopathology findings were recorded. Mean sample length was 2,05 cm (between 0,8cm and 6 cm).145 samples was smaller (75.5%) than 3cm and only 47 sample (24.5%) was bigger than 3 cm.

Conclusion:

In conclusion our database results showed that majority of surgeons didn't take into account plantarly directed nerve branches.

Introduction

Morton’s neuroma (MN) is mechanical neuropathy of plantar interdigital nerve. It is one of the most common causes of forefoot pain (1). MN is located usually at third intermetatarsal space and affects social life of patients. The pain is often worse when walking or wearing shoes that squash the feet. Patients suffer from burning pain and tenderness usually over the 3rd and 4th metatarsophalangeal joints, with pain radiating along other toes (2).

When conservative treatment fails, surgical treatment is performed. Although removal of the neuroma is the most common surgical techniques, decompression of the nerve with either open or endoscopic manner can be performed (3).

One of the most undesirable complications of MN surgery is recurrent neuroma (3, 4). Recurrence causes are well-known and often worked on it. It may occur due to inadequate surgical transection or

inappropriate transposition of the proximal nerve stumps. Each common digital nerve has plantarly directed nerve tetherings(4). These nerve tetherings are probably the most ignored and little-known cause of high incidence of recurrence. Dissection level of MN is important for this reason.

Few specific recommendations and studies have been made so far regarding appropriate resection level of the nerve to prevent recurrent neuroma. Some surgeons prefer resection as far proximally as possible while others prefer 1 to 2 cm proximal to the bifurcation of the proper digital branches (4–7). Most of the surgeons found it appropriate to exclude the neuroma from the section where it is visibly selectable but in this case plantar nerve tetherings may be overlooked.

There aren't certain answers in the current literature concerning how far proximal nerve should be resected to prevent recurrence as far as we know. In this study, we aimed to find the answer to the question "At what level do orthopedic surgeons perform Morton neuroma excision?"

Methods

Our pathology department works as a center and accepts samples from several hospitals. We searched Morton neuroma as a keyword at our pathology center's database. We aimed to evaluate the samples sent with the diagnosis of Morton neuroma to the pathology department of our hospital by combining them with the samples of our patients.

Totally 192 samples between years 2010–2017 was added to our study. The most common interspace affected was the third at 171 (89%) patients, followed by the second at 21 (11%). Mean age was 45, 8 (23 to 73). All of 192 patients were primary diagnosed 22 of them was left foot and the other 170 were right foot was. 139 of them were female, and 53 were male. Recurrent neuromas, pathological sample more than one piece from one surgical site were excluded from the study.

Results

192 pathological specimens were prepared and examined by the same pathologist. Gross pathological appearance and histopathology findings were recorded. There were apparent differences among surgeons according to the excision levels of interdigital nerve (Table 1). Total length of the excised nerve (proper digital branches + common digital branches from the distal end of the DTML) was recorded. Mean sample length was 2,05 cm (between 0,8 cm and 6 cm).145 samples was smaller (75.5%) than 3 cm and only 47 sample (24.5%) was bigger than 3 cm. Table 1 and graphics shows brief summary of results.

Table 1
Lengths of the samples.

Sample lenght	0-0.99 cm	1-1.99 cm	2-2.99 cm	3-3.99 cm	4-4.99 cm	> 5 cm
Sample count	3	64	78	19	6	1
GRAPHİCS						
Graphic 1: X-Y graphic compares the sample lenght and sample count.						

Discussion

The cause of MN has not clearly been established. There are several anatomical explanations try to explain the cause. The most commonly known theory is compression at tunnel theory (6). The tunnel is anatomical box composed of two metatarsal heads, tendons and distal metatarsal transverse ligament (DMTL). The theory is based on compressing and pulling of interdigital nerve by DMTL during walking in both the mid-stance and the heel-off stage (8).

Another anatomical explanation for Morton neuroma is about neural anatomy. Tibial nerve divides into two medial and lateral plantar branches below medial malleolus. Medial plantar nerve also is divided to hallux digital nerve and common digital nerves for first, second and third interspace. Lateral plantar nerve forms fifth toe digital nerve and fourth interspace digital nerve. Anatomic nerve variation, present 66.2% of the cases, arises from the 4th interspace make anastomosis with the common digital nerve at 3th interspace. A bulge before bifurcation in the digital nerves just distal to DMTL creates MN clinics (8).

Recurrence after Morton neuroma surgery is an undesirable outcome. Amis et al. found an anatomical cause in a cadaver study which aimed to investigate the causes of recurrence (4). They found plantarly directed nerve branches (PDNB) along the course of common digital nerves of second and third web spaces. Resected nerve stump may not move away from weight bearing area of the foot because of PDNB and this might be a cause of recurrence. Any injury to PDNB during excision of Morton neuroma may lead to formation of traumatic neuroma with similar clinical findings to Morton neuroma (9). Current studies indicate that to prevent recurrence, after achieving a good visualization nerve must be resected at least 3 cm proximal to the deep transverse ligament because there are plantar directed nerve tetherings at 3 cm proximal to the proximal edge of DMTL (4, 10).

Since the length of the foot will affect the length of the nerve and therefore the length of the nerve to be excised, it is a weak point of our study that the foot length is not specified in our study. Another weak point about our study is we didn’t consider clinical scores of the patient jus focused on pathological samples. This is because our study is a pathological database study. We did not have the opportunity to make contact with the patients because we made evaluation on the samples that came to our hospital.

Conclusion

In conclusion our database results showed that majority of surgeons preferred to use a line 2–4 even 3–4 distances according to macroscopic appearance (Fig. 1) but anatomical truths based literature recommend line 1–4 to prevent recurrence. There are plantarly directed nerve branches (PDNB) at the line 1–2 sections that we usually ignore. That means we should excise at least 1 cm more from the proximal part of the nerve.

Abbreviations

MN
Morton’s neuroma; DMTL:distal metatarsal transverse ligament; PDNB:plantarly directed nerve branches.

Declarations

Ethics approval and consent to participate: All procedures performed in studies involving human participants were in accordance with the ethical standards of the institutional and/or national research committee and with the 1964 Helsinki Declaration and its later amendments or comparable ethical standards.

Consent for publication: Not applicable

Availability of data and materials: The data used and analyzed during the current study was available from the corresponding author on reasonable request.

Competing interests: The authors declare that they have no competing interests.

Funding: Not applicable

Author’s contributions: MU conceived the project and analyzed the data. All authors contributed towards the interpretation and the collection of the data. All authors contributed towards the interpretation and the collection of the data. All authors wrote and approved the final manuscript.

Acknowledgements: Not applicable

References

1. Zelent ME, Kane RM, Neese DJ, Lockner WB. Minimally invasive Morton's intermetatarsal neuroma decompression. Foot Ankle Int. 2007;28(2):263–5.
2. Mann RA, Reynolds JC. Interdigital neuroma–a critical clinical analysis. Foot Ankle. 1983;3(4):238–43.
3. Bennett GL, Graham CE, Mauldin DM. Morton's interdigital neuroma: a comprehensive treatment protocol. Foot Ankle Int. 1995;16(12):760–3.

4. Amis JA, Siverhus SW, Liwnicz BH. An anatomic basis for recurrence after Morton's neuroma excision. Foot Ankle. 1992;13(3):153–6.
5. Giannini S, Bacchini P, Ceccarelli F, Vannini F. Interdigital neuroma: clinical examination and histopathologic results in 63 cases treated with excision. Foot Ankle Int. 2004;25(2):79–84.
6. Hassouna H, Singh D. Morton's metatarsalgia: pathogenesis, aetiology and current management. Acta Orthop Belg. 2005;71(6):646–55.
7. Morscher E, Ulrich J, Dick W. Morton's intermetatarsal neuroma: morphology and histological substrate. Foot Ankle Int. 2000;21(7):558–62.
8. Di Caprio F, Meringolo R, Shehab Eddine M, Ponziani L. Morton's interdigital neuroma of the foot: A literature review. Foot Ankle Surg. 2018;24(2):92–8.
9. Pinter Z, Odom C, McGee A, Paul K, Huntley S, Johnson JL, et al. Morton's Neuroma Excision: What Are We Really Doing? Which Retractor Is Superior? Foot Ankle Spec. 2019;12(3):272–7.
10. Weinfeld SB, Myerson MS. Interdigital Neuritis: Diagnosis and Treatment. J Am Acad Orthop Surg. 1996;4(6):328–35.

Figures

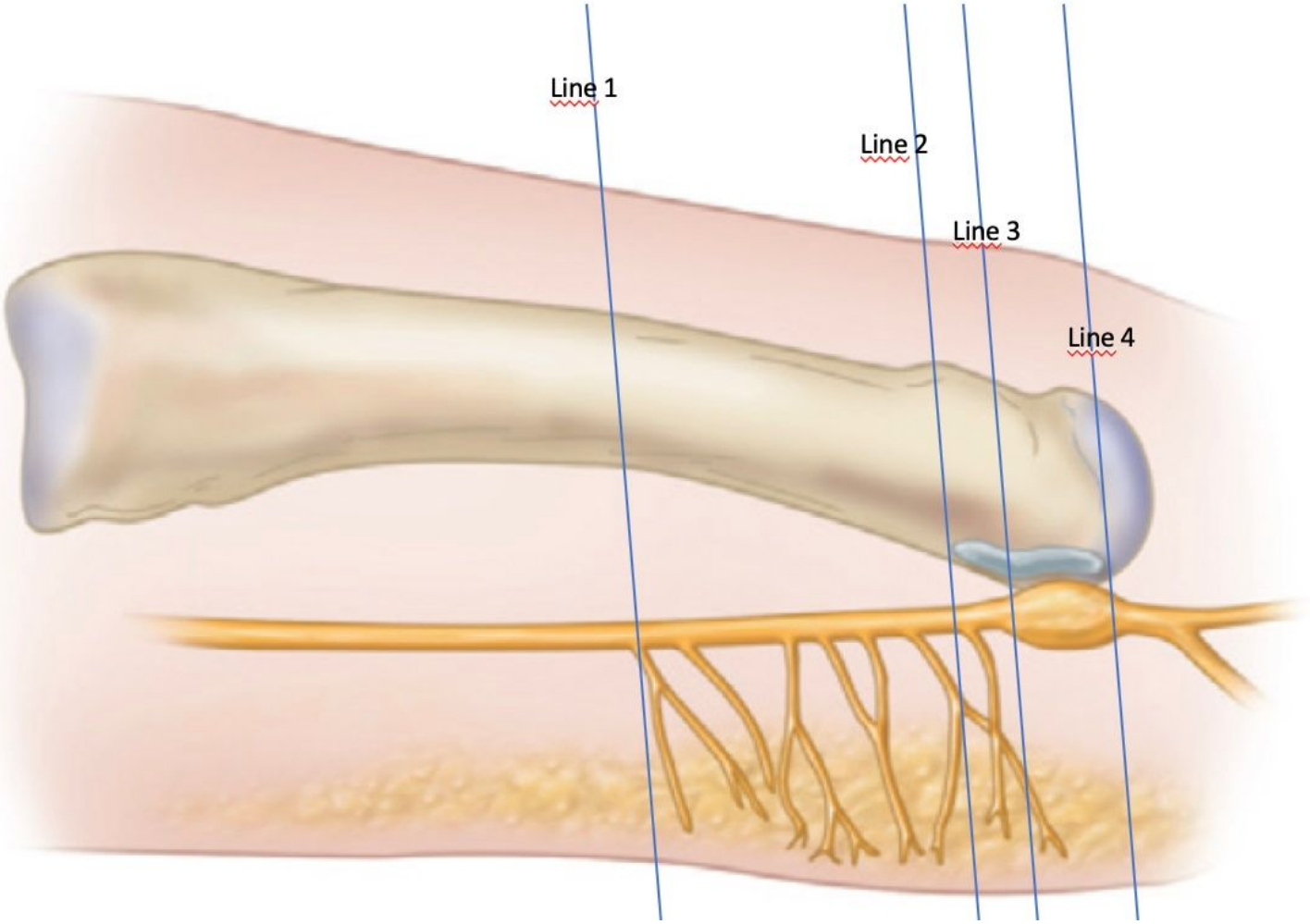

Figure 1

1)Expected proximal neurectomy level 2)Usually performed proximal surgical neurectomy level 3)IML level 4)Usually performed distal surgical neurectomy level 1-3 distances : Recommended proximal neurectomy distance according to IML 2-4 distances: Generally performed neurectomy length, 1-4 distances: Recommended neurectomy length.

Supplementary Files

This is a list of supplementary files associated with this preprint. Click to download.

- Grafik.doc