

Sudden Sensorineural Hearing Loss with Auditory Neuropathy: Evidence Based on Audiological Test and Inner Ear MRI

Yu Ai

Shandong Provincial ENT Hospital

Na Hu

Shandong Provincial ENT Hospital

Mingming Wang (✉ wmmship@126.com)

Shandong Provincial ENT Hospital <https://orcid.org/0000-0003-2034-7338>

Case report

Keywords: Sudden sensorineural hearing loss, auditory neuropathy, demyelination, MRI

Posted Date: April 7th, 2021

DOI: <https://doi.org/10.21203/rs.3.rs-338045/v1>

License:   This work is licensed under a Creative Commons Attribution 4.0 International License.

[Read Full License](#)

Abstract

Background: Sudden sensorineural hearing loss (SSNHL), defined as a hearing loss of ≥ 30 dB affecting at least three consecutive frequencies occurring over a 72-hour period, is commonly in audiologic and otolaryngologic practice. However, SSNHL with auditory neuropathy is rarely reported. We described the clinical characteristics of a patient with SSNHL and auditory neuropathy, together with its etiologic mechanism.

Case presentation: A 27-year-old woman was referred to our otological clinic with acute diminished hearing on the left ear, associated with persistent tinnitus, aural fullness and vertigo, all for a duration of 20 days. Audiological examination showed presence of otoacoustic emissions and cochlear microphone with absent ABR on the left ear, which was consistent with the criteria of auditory neuropathy. Magnetic resonance images of the brain and inner ear implicated demyelinating lesions in the auditory nerve. Forty months after onset, all the auditory retests were normal and symmetric T2-FLAIR signals of both auditory nerves were found in inner ear magnetic resonance images.

Conclusion: We showed that the SSNHL with auditory neuropathy could be caused by demyelination. The case also suggests that some SSNHL caused by demyelination is reversible.

Background

Sudden sensorineural hearing loss (SSNHL) is an unexplained, rapid loss of hearing either all at once or over a few days[1]. SSNHL happens because of abnormality in the cochlea, auditory nerve, or central auditory system. The cause of SSNHL is often not readily apparent[2]. Possible etiologies of SSNHL include viral infection, microcirculatory disturbance, autoimmune diseases, ototoxic agents, noise, and head trauma[3]. Here we described the audiological and radiological characteristics of a patient with SSNHL, likely caused by demyelination of the auditory nerve with characteristics of auditory neuropathy. The case also suggests that some SSNHL caused by demyelination is reversible and myeline of the auditory nerve could be repaired or regenerated.

Case Presentation

A 27-year-old woman was referred to our otological clinic with acute diminished hearing on the left ear, associated with persistent tinnitus, aural fullness and vertigo, all for a duration of 20 days. The patient displayed a normal "A" type tympanogram in both ears. Pure-tone audiometry showed hearing thresholds of ~ 70 to 100 dB HL between 125 and 8,000 Hz (Fig. 1). No auditory brainstem responses (ABR) was able to be evoked from the left ear. However, distortion-product otoacoustic emissions (DPOAE) were detected in both ears with comparable values (Fig. 2). Vestibular examinations detected no abnormalities.

After admitted to the hospital, the patient received a combination therapy of postauricular injection of 40 mg methylprednisolone and oral administration of Ginkgo biloba extract and Methyl cobalamin for 12

days. Pure tone audiogram showed normal hearing after 8 days of treatment, while words recognition scores (WRSs) were 76%. Twelve days after treatment WRSs were improved to 88%, and Speech Reception Threshold, which is compatible with pure tone threshold, was 15.5 dB HL. Nevertheless, ABR retested in 5 weeks presented no evidence of any peaks at 80 dB nHL with normal cochlear microphone (CM) response. Follow-up ABR recorded respectively in 7, 9 and 12 weeks showed evident but delayed wave V and the latency of wave V decreased gradually (Fig. 3).

The patient displayed no fluctuating hearing loss during follow-up for three years. Auditory function was retested 40 months after onset. Normal audiogram, WRS, ABR (Fig. 1e) and DPOAEs were observed.

Magnetic resonance images (MRIs) of the brain and inner ear were obtained at 3 and 12 weeks after onset. MRIs showed that the left auditory nerve and the brain stem adjacent to the nerve (include left dorsolateral medulla, cerebellar flocculus, cerebellar midfoot next to the fourth ventricle and cerebellar inferior foot) displayed T1 weight hypointense and T2-FLAIR hyperintensities (Fig. 4a). There were no other noticeable abnormalities in the enhanced MRI. MRIs were also retested 40 months after the onset. Compared with those in the diseased stage, MRIs indicated significantly shrunk in the area of lesion, and symmetric T2-FLAIR signals were seen in auditory nerves in both ears (Fig. 4b).

Discussion

Audiological tests before treatment showed that the suffered ear had the characteristics of auditory neuropathy. This implied that the patient had normal outer hair cell function but abnormal neural conduction [4]. MRIs showed T1 weight hypointense and T2-FLAIR hyperintensities at the left auditory nerve and the brain stem adjacent to the nerve in the primary stage. Furthermore, retested MRI indicated markedly shrunk in the area of lesion. These were consistent with the imaging characteristics of demyelinating lesions in the auditory nerve [5]. Taken together, all evidence suggests that SSNHL in the left ear of this patient was not due to abnormality in mechanosensitive hair cells but likely due to demyelination in the auditory nerve. Thus, demyelination in the auditory nerve fibers could cause SSNHL, which presented characteristics of auditory neuropathy. This is in line with the study of Starr et al, which showed marked loss of nerve fibers and demyelination of many of the remaining fibers in the examination of human temporal bones from subjects with AN[6]. Matsunaga et al also found patients with AN from acoustic neuromas presented the similar pathological characteristics in proximity to the region of compression [7].

In the current patient, audiological follow-up demonstrated that although pure tone audiograms showed normal hearing at four weeks after the onset, ABR waveforms were still abnormal at 12 weeks. This is in line with the radiological finding. MRIs retested in the same day still exhibited retrocochlear lesions in the left auditory nerve and the brain stem adjacent to the nerve. However, the shorten latency of wave V implies neural conduction is recovered by some degrees. In 40 months after onset, normal ABR waveforms were consistent with MRI finding, which displayed symmetric T2-FLAIR signals in both auditory nerves, suggesting that myeline of the auditory nerve could be repaired or regenerated.

Conclusion

Herein, we provided radiological and audiological evidence of SSNHL that was likely originated from demyelination of the auditory nerve. We showed that the SSNHL with auditory neuropathy could be caused by demyelination. The fact that normal hearing was restored in four weeks suggests that SSNHL caused by demyelination is reversible and myeline of the auditory nerve could be repaired or regenerated.

Declarations

Availability of data and materials

Not applicable.

Ethics approval and consent to participate

The study has been approved by the ethics committee of Shandong Provincial ENT Hospital and performed in accordance with the ethical standards laid down in the 1964 declaration of Helsinki and its later amendments.

Consent for publication

Written informed consent for publication of their clinical details and clinical images was obtained from the patient.

Competing interests

The authors declare that they have no competing interests.

Funding

This work was supported by the Key Technology Research and Development Program of Shandong (2019GSF108248).

Authors' contributions

Mingming Wang conceived the case report and revised the manuscript. Na Hu described the patient's radiological characteristics and revised the manuscript. Yu Ai drafted the manuscript. All authors read and approved the final manuscript.

Acknowledgements

Not applicable

Abbreviations

SSNHL sudden sensorineural hearing loss

ABR auditory brainstem response

DPOAE distortion-product otoacoustic emissions

WRS words recognition score

CM cochlear microphone

MRI magnetic resonance image

AN auditory neuropathy

References

1. National Institute of Deafness and Communication Disorders. Sudden deafness. 2000. <http://www.nidcd.nih.gov/health/hearing/sudden.htm>.
2. Stachler RJ, Chandrasekhar SS, Archer SM, et al. Clinical practice guideline: sudden hearing loss. *Otolaryngol Head Neck Surg*. 2012;146(3 suppl):1–35.
3. Chandrasekhar SS, Tsai Do BS, Schwartz SR, et al. Clinical practice Guideline: Sudden Hearing Loss (Update). *Otolaryngol Head Neck Surg*. 2019;161(1 suppl):1–45.
4. Starr A, Picton TW, Sininger Y, Hood LJ, Berlin CI. Auditory neuropathy. *Brain*. 1996;119(Pt 3):741–53.
5. Ayrignac X, Carra-Dallière C, Labauge P. Atypical inflammatory demyelinating lesions and atypical multiple sclerosis. *Rev Neurol*. 2018;174(6):408–18.
6. Starr A, Michalewski HJ, Zeng FG, Fujikawa-Brooks S, Linthicum F, Kim CS, Winnier D, Keats B. Pathology and physiology of auditory neuropathy with a novel mutation in the MPZ gene (Tyr145>Ser). *Brain*. 2003;126(Pt 7):1604–19.
7. Matsunaga T, Kanzaki J. Morphological evidence that impaired intraneural microcirculation is a possible mechanism of eighth nerve conduction block in acoustic neuromas. *Eur Arch Otorhinolaryngol*. 2000;257(8):412–7.

Figures

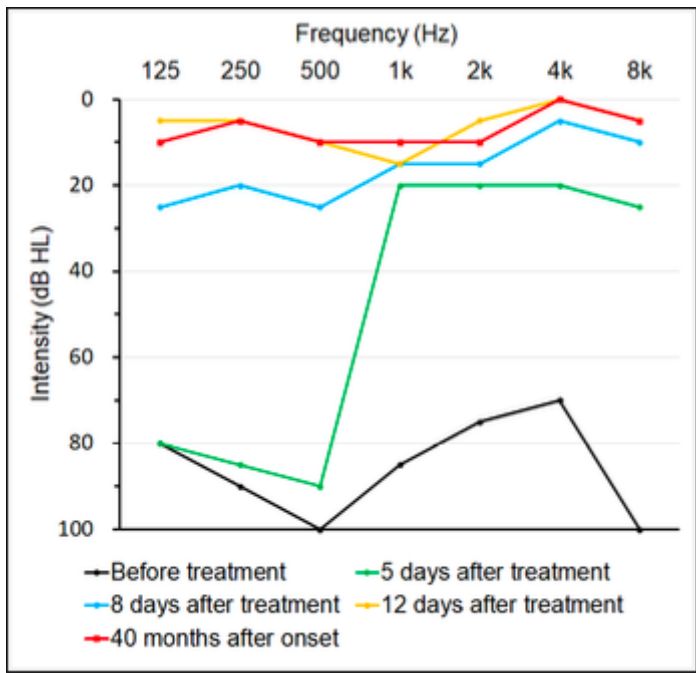


Figure 1

Pure tone audiometry at different time points.

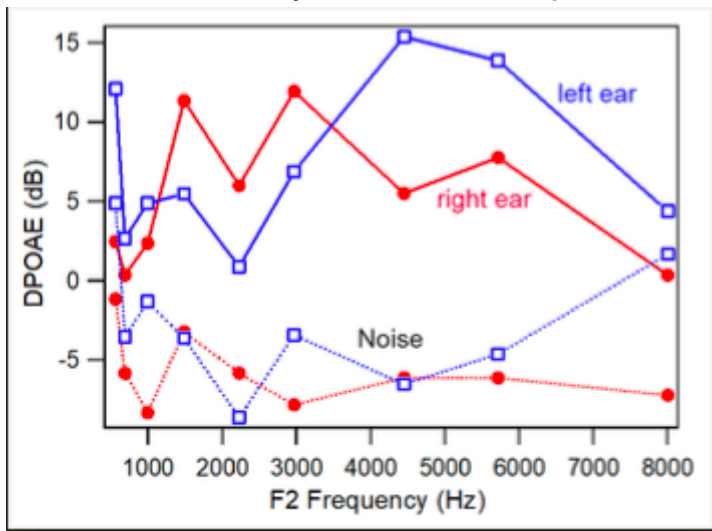


Figure 2

DPOAEs of the right and left ear measured during SSNHL.

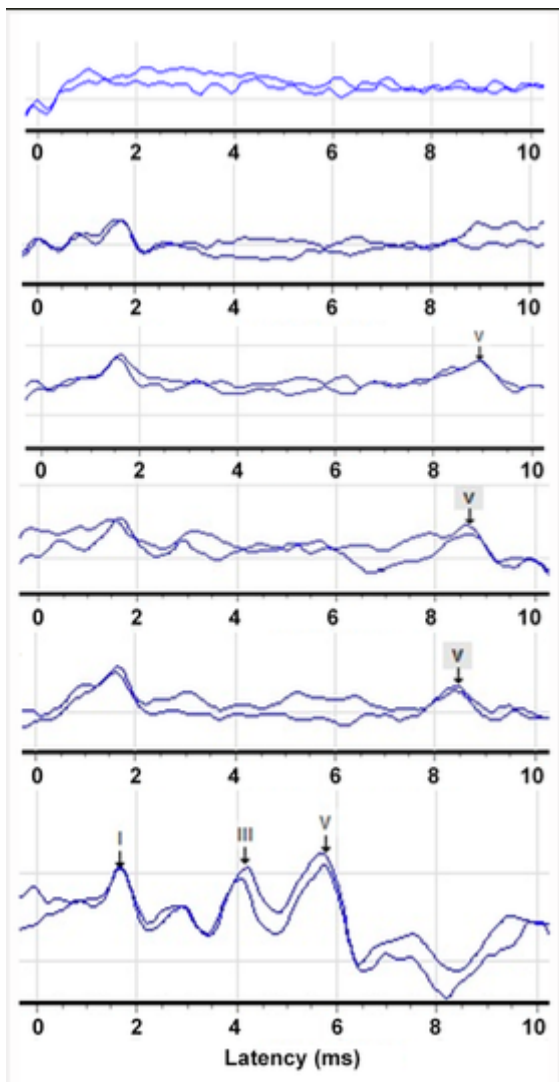


Figure 3

Click-ABRs evoked by 80 dB nHL at 3, 5, 7, 9, 12 weeks and 40 months after SSNHL onset.

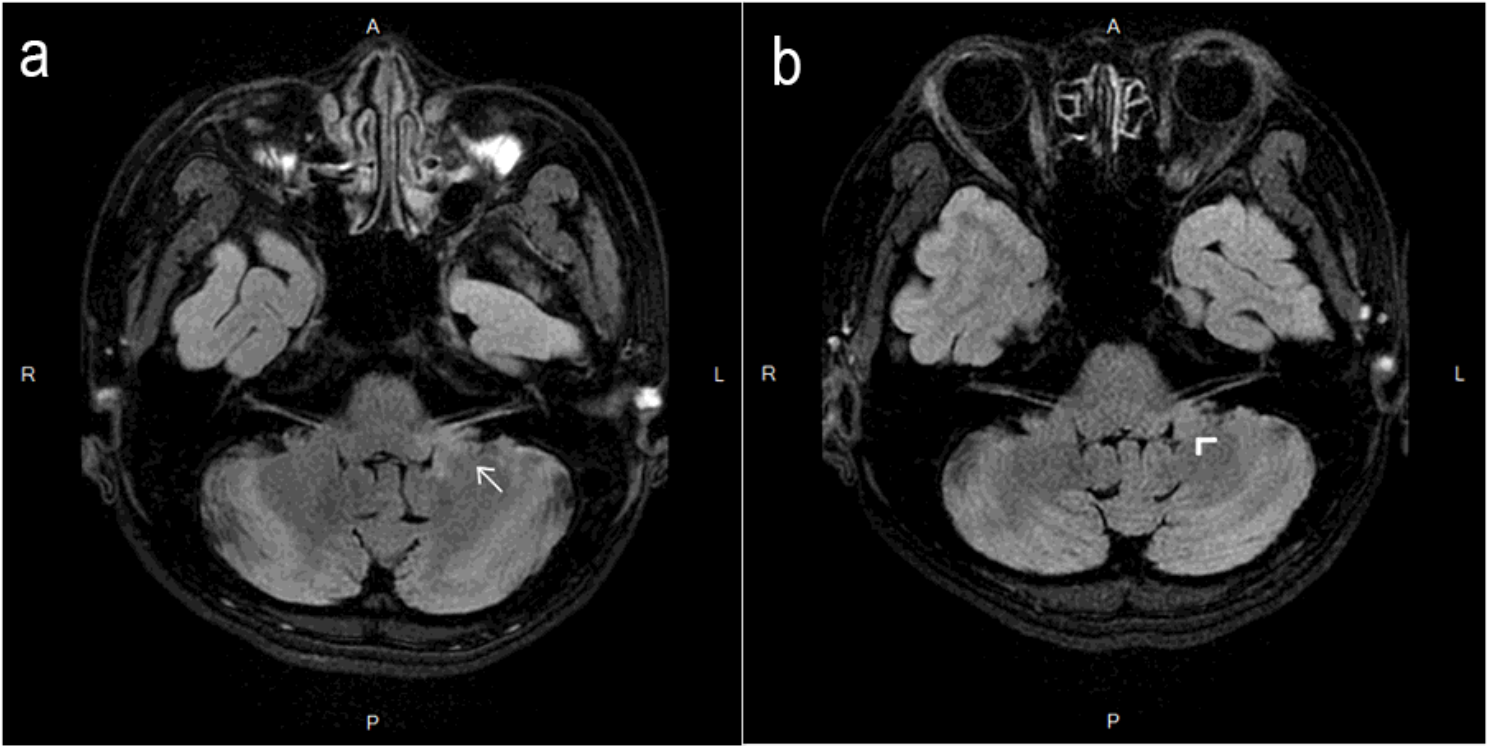


Figure 4

a:T2-FLAIR MRI at the level of auditory nerve in the primary stage. b:T2-FLAIR MRI at the level of auditory nerve in 40 months after onset