Does Thoracic Kyphosis Have Any Importance in Selective Versus Nonselective Fusion Preference in Patients With Lenke Type 5C Adolescent Idiopathic Scoliosis? A Contribution to the Guidance of the Lenke Classification

Gökhan Karademir
Acıbadem Hospitals Group: Acibadem Saglik Grubu
Kerim Sarıyılmaz
Acıbadem Üniversitesi: Acibadem Universitesi
Okan Özkunt
Medicana International Istanbul Hospital
Mehmet Demirel (dr88.mehmet.demirel@gmail.com)
Istanbul Universitesi Istanbul Tip Fakultesi
Fatih Dikici
Acıbadem Üniversitesi: Acibadem Universitesi
Ünsal Domaniç
Istanbul University: Istanbul Universitesi

Research article

Keywords: Lenke classification, thoracic kyphosis, Lenke Type 5C Adolescent Idiopathic Scoliosis, selective fusion (SF), nonselective fusion (NSF)

Posted Date: March 30th, 2021

DOI: https://doi.org/10.21203/rs.3.rs-340655/v1

Abstract

Background

Although Lenke classification analyses the sagittal plane as (+), N, and (-), it does not consider it in the choice of treatment, and it has limitations with overall thoracic kyphosis (TK). To investigate the importance of TK for treatment preference in patients with Lenke 5C adolescent idiopathic scoliosis (AIS) by comparing radiological outcomes of the patients who underwent selective fusion (SF) or nonselective fusion (NSF).

Methods

Thirty-two patients with Lenke type 5C AIS were included and then divided into two groups as per the fusion procedure used in the surgical treatment. SF group including 17 patients (15 females; mean age = 16 years, age range, 14–21) with normal TK and NSF group including 15 patients (11 females; mean age = 17 years, age range, 13–26) with thoracic hyper-kyphosis. Thorocolumbar/lumbar (TL/L) Cobb, thoracic (T) Cobb, TK and lumbar lordosis (LL) were measured on standing spine radiographs preoperatively and at the final follow-up. The correction rates (CR) of each radiographic parameter were calculated.

Results

No significant differences were observed in the mean CR of all radiographic parameters, except TK and LL correction rates. The mean CR of TK was significantly higher in NSF group (-17% [range, -100–69]) than in SF group (67% [range, 9–100]) ($p = 0.000$). Likewise, the mean CR of LL was found significantly higher in NSF group (12.47% [range, -100–51]) than in SF group (-2.41% [range, -75–47]) ($p = 0.036$).

Conclusion

In patients in whom Lenke's sagittal modifier is N, SF can be performed efficiently. NSF should be preferred in those with Lenke's sagittal modifiers (+) as TK can be better controlled with NSF.

Level of Evidence: 3

Background

The main goals of corrective surgery in adolescent idiopathic scoliosis (AIS) are to obtain an optimally corrected and well-balanced spine, to prevent curve progression, and to provide maximum functionality of the spine with minimal fused motion segments [1, 2]. Considering these goals, the concept of selective fusion (SF), in which the structural curve is fused while sparing the nonstructural curves to preserve the mobility of the spine, has gained popularity among spine surgeons for the past few decades [2–7]. Most of these surgeons utilized the King-Moe classification until the 1980s. Lenke et al. [8] defined a new classification in 2001 to address King-Moe classification's shortcomings such as poor reliability and

reproducibility [9]. Unlike King-Moe classification, the Lenke classification, which evaluates not only the coronal plane but also the sagittal plane, is the most widely used classification today (Table 1) [10].

Table 1
Curve types based on the Lenke Classification of Adolescent idiopathic scoliosis

Curve Type	Proximal Thoracic	Main Thoracic	Thoracolumbar/lumbar	Description
Type 1	Non-Structural	Structural (Major)*	Non-Structural	Main Thoracic
Type 2	Structural	Structural (Major)*	Non-Structural	Double Thoracic
Type 3	Non-Structural	Structural (Major)*	Structural	Double Major
Type 4§	Structural	Structural (Major)*	Structural	Triple Major
Type 5	Non-Structural	Non-Structural	Structural (Major)	Thoracolumbar/lumbar
Type 6	Non-Structural	Structural	Structural (Major)	Thoracolumbar/lumbar-Main Thoracic

*Major = Largest Cobb measurement, always structural

Minor = All other curves with structural criteria applied

§*Type 4 - Main thoracic or thoracolumbar/lumbar can be major curve*

STRUCTURAL CRITERIA

Proximal Thoracic - Side Bending Cobb ≥ 25 degrees

T2-T5 Kyphosis ≥ 20 degrees

Main Thoracic - Side Bending Cobb ≥ 25 degrees

T10-L2 Kyphosis ≥ 20 degrees

Thoracolumbar/lumbar -Side Bending Cobb ≥ 20 degrees

T10-L2 Kyphosis ≥ 20 degrees

MODIFIERS

Lumbar Spine Modifier	Center Sacral Vertical Line to Lumbar Apex
A	Between pedicles
B	Touches spinal body
C	Completely medial

Thoracic Sagittal Profile T5-T12	
Modifier	Cobb angle
- (Hypo)	< 10°
N(Normal)	10° – 40°
+(Hyper)	> 40°

According to the Lenke classification, type 5 represents the third most prevalent curve type of AIS, and this curve type is characterized by a single structural thoracolumbar/lumbar (TL/L) curve with non-

structural or compensatory thoracic (T) curve (Table 1). The Lenke classification suggests a selective TL/L fusion for all of the type 5 curves [8]. On the other hand, remarkable number of experienced scoliosis surgeons prefer considerably non-selective fusion (NSF) for the type 5 curves [11, 12]. This often leads to the questioning of the treatment recommendations of the Lenke Classification [7, 10]. Although Lenke classification analyses the sagittal plane as (+), N, and (-), it does not consider it in the choice of treatment, and it has limitations with overall TK. This situation can be a dilemma for the spine surgeon who refers to the Lenke Classification in the choice of treatment, especially in the treatment of AIS patients with advanced sagittal plane deformity.

The aim of this study is to investigate the importance of thoracic kyphosis (TK) for the treatment choice in Lenke type 5C patients by comparing the radiological outcomes of the patients who underwent SF or NSF with respect to this criterion. We hypothesize that NSF provides better correction rates of the TK and lumbar lordosis (LL) and has negligible superiority on restoring pelvic parameters in cases with (+) Lenke's sagittal modifier whereas SF improves T/TL Cobb and T Cobb angles as effective as NSF in cases with Lenke's sagittal modifier is N.

Methods

This retrospective study was conducted on patients who were diagnosed and operated for Lenke type 5C AIS by a single spine surgeon between 1998 and 2009 in a single tertiary referral center. Inclusion criteria for the study were: (1) a diagnosis of Lenke type 5C AIS with thoracic normal or hyperkyphosis; (2) surgical treatment with posterior pedicle screw instrumentation; (3) no history of previous spinal surgery; (4) complete sets of preoperative and final follow-up standing full-length anteroposterior (AP) and lateral radiographs of the spine; and (5) being willing to participate in the study. Exclusion criteria were: (1) a diagnosis of Lenke type 5C AIS with thoracic hypokyphosis; (2) a history of previous spinal surgery (hybrid or anterior pedicle screw instrumentation, or corrective osteotomies); (3) lost to follow-up; (4) inadequate radiographic imaging; (5) concomitant neuromuscular or congenital disorders; and (6) being unwilling to participate in the study.

A total of 40 patients were evaluated based on the above eligibility criteria. After excluding 8 patients, remaining 32 with Lenke type 5C AIS who met the inclusion criteria were included in the study and invited to a final follow-up examination for radiographic assessment. The study protocol was approved by local ethical committee (Ref. number 2017/17 – 3; approval issue date Oct. 27, 2017). Parents were informed that medical records could be used for scientific purposes only; thus, written informed consent was obtained at the final visit.

Patients included in the study were categorized into two groups based on the fusion procedure used in the surgical treatment and thoracic kyphosis angle: SF group including patients with normal thoracic kyphosis and NSF group including patients with thoracic hyper-kyphosis (Fig. 1). Normal thoracic kyphosis is defined as 10° to 40° of thoracic convexity, and thoracic hyper-kyphosis as 40° or higher [8].

Surgical Technique

All surgical procedures were performed by the same senior surgeon. All patients underwent general anesthesia and placed in a prone position on a surgical table. After a posterior midline incision was made, subperiosteal paraspinal muscles were dissected to expose the posterior elements of the spinal fusion levels. The pedicle screws were inserted by a free-hand technique and checked with intraoperative fluoroscopy [13]. First, a lordotic shape titanium rod was placed at the convex side of curvature to obtain lordosis and correct the coronal deformity. The concave rod was given less lordosis than the first rod. Curve correction was achieved using the rod-rotation maneuver with convex rod, followed by slight convex compression and concave distraction. After decortication of the posterior elements and facet excision autogenous and allogenic bone grafts were used for fusion.

Radiographical Assessment

Radiographic parameters examined in the study were:

- Coronal spinal parameters: (1) thorocolumbar/lumbar (TL/L) Cobb angle and (2) thoracic (T) Cobb angle;
- Sagittal spinal parameters: (3) thoracic kyphosis (TK) angle and (4) lumbar lordosis (LL) angle;
- Pelvic parameters: (5) pelvic incidence (PI), (6) sacral slope (SS), and (7) pelvic tilt (PT).

All radiographic measurements were performed on standing anteroposterior and lateral radiographs of the entire spine, by a single attending surgeon, who did not participate in the treatment of the patients, using a validated software (Surgimap™, Nemaris Inc, New York), preoperative and at the final follow-up. TK angle was measured from the superior endplate of T5 vertebra to the inferior endplate of T12 vertebra. LL angle was measured from the superior endplate of L1 vertebra to the superior endplate of S1 vertebra.

The correction rate of each radiographic parameter in both groups was calculated as following equation: (preoperative X angle – final follow-up X angle)/preoperative X angle in the standing film × 100.

Statistical Analysis

IBM SPSS Statistics software, version 22.0 (IBM Corp., Armonk, New York, NY, USA), was used for statistical analysis. A $p < 0.05$ was considered statistically significant. Normality tests were conducted using the Kolmogorov-Smirnov test. Between-group comparisons were performed using the Student t-test for parametric variables, Mann–Whitney U test for non-parametric variables, and Fisher's exact test for categorical variables. Statistical significance was set at $p < 0.05$.

Results

The mean follow-up was 41 (range, 24–77) months in the SF group and 42 (range, 24–65) in the NSF group (Table 2). The patients' radiographic outcomes in each group are demonstrated in (Table 3). In the preoperative measurements between the two groups, no significant differences were observed in all

radiographic outcome measurements, except TK and LL angles. The mean TK angle was 28.7° (range, 16°–40°) in SF group and 53.93° (range, 41°–79°) in NSF group (p = 0.000). The mean LL angle was 53.65° (range, 24°–93°) in SF group and 60.71° (range, 31°–88°) in NSF group (p = 0.049). In the final follow-up measurements, the significant difference was only observed in the mean TK angle, which was 31.35° (range, 12°–57°) in SF group and 23.52° (range, 4°–47°) in NSF group (p = 0.007).

Table 2
Demographic characteristics of the study participants.

	Group *SF (17 patients)*	***Group NSF (15 patients)***	***p* values***
Gender	15F, 2M	11F, 4M	0,383[a]
Mean age at surgery (year)	16 (range, 14–21)	17 (range, 13–26)	0.682[b]
Follow-up duration (month)	41 (range, 24–77)	42 (range, 24–65)	0,655[b]
[a] Fisher's exact test; [b] Mann-Whitney U test; *p < 0,05			
SF: Selective fusion, NSF: Non-selective fusion,			

Table 3
Radiographic outcome measures at all study interval assessments

Variables		Preoperative measurements			Final follow-up measurements		
		Group SF	Group NSF	*p* value	Group SF	Group NSF	*p* value
TL/L Cobb angle	Mean ± SD	38.71 ± 9.51	42.47 ± 10.32	0.278	10.24 ± 9.97	10.93 ± 8.119	0.502
	Range	27–61	27–66		1–36	1–32	
T Cobb angle	Mean ± SD	16.12 ± 7.01	24.33 ± 12.52	0.44	5.35 ± 4.52	6.80 ± 5.34	0.526
	Range	6–29	3–45		0–17	0–15	
TK angle	Mean ± SD	28.71 ± 6.95	53.93 ± 10.76	0.000*	31.35 ± 9.172	23.52 ± 9.51	0.007*
	Range	16–40	41–79		12–57	4–47	
LL angle	Mean ± SD	53.65 ± 13.43	60.71 ± 13.874	0.049*	52.24 ± 9.9	49 ± 9.67	0.313
	Range	28–84	31–88		31–68	32–69	
PI	Mean ± SD	54.12 ± 17.442	54.67 ± 14.51	0.987	50.47 ± 13.02	52.47 ± 16.48	0.526
	Range	24–93	37–82		34–77	19–75	
PT	Mean ± SD	15.88 ± 11.05	16.53 ± 9.84	0.823	17.47 ± 10.11	18.80 ± 9.98	0.682
	Range	-4–33	-5–35		2–38	2–39	
SS	Mean ± SD	38.53 ± 9.40	38.33 ± 9.56	0.852	32.47 ± 9.11	35.67 ± 5.01	0.455
	Range	21–63	21–55		12–43	27–45	

*The significance level was set at $p < 0.05$.

TL/L: Thoracolumbar/Lumbar; T: Thoracic; TK: Thoracic kyphosis; LL: lumbar lordosis; PI: pelvic incidence; SS: Sacral slope; PT: Pelvic tilt; SF: Selective fusion, NSF: Non-selective fusion.

The correction rate of each radiographic parameter in both groups is presented in (Table 4). Between the two groups, there were no significant differences in the mean correction rates of all radiographic parameters, except TK and LL angles. The mean correction rate of TK angle was significantly higher in NSF group (53.8 ± 24.38 % [range, -9–92]) than in SF group (-17.71 ± 48.95 % [range, -100–69]) (p = 0.000). Likewise, the mean correction rate of LL angle was found significantly higher in NSF group (12.47 ± 37.67 % [range, -100–51]) than in SF group (-2.41 ± 29 % [range, -75–47]) (p = 0.036).

Table 4
Comparative results for correction rates of radiographic parameters between both groups

Correction rates (%)		Group SF	Group NSF	*p* value
TL/L Cobb angle	Mean ± SD	75.63 ± 24.95	73.27 ± 17.65	0.344
	Range	7–98	40–98	
T Cobb angle	Mean ± SD	67 ± 22.81	72.87 ± 19.39	0.461
	Range	9–100	40–100	
TK angle	Mean ± SD	-17.71 ± 48.95	53.8 ± 24.38	0.000*
	Range	-100–69	-9–92	
LL angle	Mean ± SD	-2.41 ± 29	12.47 ± 37.67	0.036*
	Range	-75–47	-100–51	
PI	Mean ± SD	-0.35 ± 33.27	3.40 ± 21.84	0.748
	Range	-71–40	-25–48	
PT	Mean ± SD	-1.65 ± 82.374	-7.73 ± 52.577	0.692
	Range	-162–200	-100–83	
SS	Mean ± SD	8.76 ± 31.18	3.27 ± 18.57	0.265
	Range	-90–52	-40– 27	

*The significance level was set at $p < 0.05$.

TL/L: Thoracolumbar/Lumbar; T: Thoracic; TK: Thoracic kyphosis; LL: lumbar lordosis; PI: pelvic incidence; SS: Sacral slope; PT: Pelvic tilt; SF: Selective fusion, NSF: Non-selective fusion.

Discussion

In the surgical treatment of Lenke type 5 AIS, SF of the structural TL/L curve has been considered to be the leading treatment method [5, 8, 14]. Many studies have reported satisfactory radiological and clinical outcomes, and also spontaneous T curve correction with SF. However, Lenke type 5 AIS is unique, and it differentiates from other types as the T kyphosis cannot be controlled by only fusing the structural TL curve. Although Lenke classification identifies the T kyphosis as (+), N, and (-), it made no recommendation regarding kyphosis. Contrary to the recommendations of the Lenke Classification, some spine surgeons have been reported to perform NSF in 27% of patients with Lenke type 5 AIS [11]. The main reason for performing NSF has been to control the T coronal plane deformity [11]. However, it has been stated that maintaining sagittal balance is crucial for favorable radiological and clinical outcomes, and it should not be neglected in AIS [12, 15]. T5-T12 T kyphosis and T1-T4 sagittal alignment were determined as the criterion to be considered in achieving sagittal balance [12, 16]. In a study by Connolly et al., sagittal plane parameters have been stated to be more substantial in the long-term health of the

spine [17]. Consistent with this statement, in another study by Takayama et al. [18], it was reported that patients with low functional scores were the ones whose sagittal balances could not have been restored. Considering that the importance of the sagittal plane in the treatment of AIS has been supported by current publications [6], another reason to extending the fusion to T spine may be to control and restore the T kyphosis [6]. Accordingly, it was planned to investigate effects of T kyphosis on the treatment choice and radiological outcomes in Lenke type 5C patients in the current study. Moreover, the importance of the correction of TL kyphosis and T hypokyphosis was also emphasized in a study by Suk et al. [16] In our study, hypokyphotic patients were not included in the study due to underpowering, thus only normokyphotic and hyperkyphotic patients were compared.

In a study by Lark et al., 58 Lenke Type 5 patients underwent SF or NSF, and a significant difference was reported in both postoperative TL/L Cobb and T Cobb angles in the matched groups. (The mean TL/L Cobb angle was 19° ± 6° in SF group and it was 13° ± 6° in NSF group, $p < 0.001$; mean T Cobb was 22° ± 9° in SF and it was 12° ± 6° in NSF, $p < 0.001$). In our study, there was no significant difference between the groups in terms of postoperative TL/L Cobb and T Cobb angles. (The mean TL/L Cobb angle was 10.24° ± 9.97° in SF and 10,93° ± 8.12° in NSF group [$p = 0.718$]; the mean T Cobb angle was 5.35°± 4.52° in SF group and 6,80° ± 5.34° in NSF group [$p = 0.198$]). In that study, TK increased in the group SF and it decreased in the group NSF postoperatively. In parallel, TK increased in the group SF (5,2%) and decreased in the group NSF (56,4%) in our study ($p < 0.001$). Contrary to reported postoperative hypokphosis (mean: 18° ± 6°) by Lark et al. in the group NSF, the patients in both groups in our study had normokyphosis postoperatively. The reason for this difference may be that patients who underwent NSF were hyperkyphotic ones in our study, whereas they were normokyphotic ones in that study. Another reason for that may be the longer time required for the normalization of the sagittal profile, as stated in a meta-analysis by Pasha et al. [19]. Unlike that study, the other spinopelvic parameters were also evaluated in our study. Coherent with our findings, in the preoperative evaluation of Lenke type 5 patients, the mean values of spinopelvic parameters reported by Farshad et al. [20] were as 48° ± 13°, 36° ± 9°, 12° ± 7°, 50° ± 12° for the PI, SS, PT, LL; respectively. As reported in the literature, increased sacral slop was present in our patient series as well to probably compensate for increased LL (Table 4) [20–22]. In our study, PI did not change similar to previously reported [20–22], yet SS decreased while PT increased significantly postoperatively ($p = 0.434$, $p = 0.037$, $p = 0.001$) in both groups. However, the observed difference between the groups was not statistically significant.

Lonner et al. reported that the frequency of complications has been increasing related to AIS surgery [19]. In another study, it was reported that post junctional kyphosis (PJK) developed in 28% of patients with AIS. In a study in which PJK was reported as 8.5% in Lenke type 5 AIS, hyperkyphosis was defined as the main risk factor. Also, Wang et al. reported that PJK was frequently seen in short-segment instrumentation [6]. In our study, it has been demonstrated that SF can be performed in patients with Lenke type 5 and T sagittal profile can be restored better with NSF in patients with TK. Contrary to those reported in the literature, the reason for developing PJK in none of the 32 patients in our series with a mean of 42,3 months follow-up might be due to the consideration of the sagittal plane analysis in the preference of surgical treatment method.

In our retrospective case series, the patients with Lenke type 5 AIS who underwent SF or NSF were compared radiologically. When the Cobb angles are evaluated in both groups, the mean T curves angles was not high, so they can be considered as non-structurally. Whereas SF can be performed for both groups according to the Lenke Classification, the surgeon included the T region into the fusion area in those who have high TK based on his own experience. While the sagittal modifier of Lenke remains N in patients undergoing SF, it changed from (+) to N in most of the patients who underwent NSF. These findings show us that the sagittal plane evaluation of the Lenke Classification System may be insufficient to guide the treatment. In this study, in the mid-to-long term follow-up, it has been shown that SF can be performed for the patients with Lenke Type 5 AIS, additionally the sagittal plane is restored better with NSF in patients with TK.

To the best of the authors' knowledge, this study is the first study to demonstrate that TK, which the Lenke Classification does not consider in the treatment recommendation, can be an important determinant in the choice of SF versus NSF in patients with Lenke 5C AIS by evaluating TL/L, T Cobb angles, TK, LL as well as PI, SS, PT. It must be noted that the findings of this study should be supported by prospective randomized controlled trials involving a larger number of patients.

This study was retrospective in nature and it contains similar deficiencies with other retrospective studies. First, the outcomes of SF and NSF treatments were evaluated only radiologically. The sample size was relatively small. The decision to perform a SF versus NSF was based on TK and there was no control group. However, this potential study bias was minimized by the preoperative similarity in terms of age, gender, follow-up duration, and preop coronal and sagittal plane parameters except for T5-T12 TK of both groups being compared. The patients in the study were homogeneous and they underwent posterior instrumentation and fusion by the same surgeon with the same pedicle screw instrumentation system. Also, a considerable length of follow-up duration a mean of 41,7 months is another strength of the study.

Conclusion

The findings of this study support that it is important to consider TK in the preference of NSF versus SF in patients with Lenke Type 5 AIS. In cases in which Lenke's sagittal modifier is N, SF can be performed efficiently. NSF should be preferred in those with Lenke's sagittal modifiers (+) since TK can be better controlled with NSF.

Abbreviations

TK: Thoracic kyphosis

AIS: Adolescent idiopathic scoliosis

SF: Selective fusion

NSF: Nonselective fusion

TL/L: Thorocolumbar/lumbar

T: Thoracic

LL: Lumbar lordosis

CR: Correction rate

Declarations

Funding

None

Ethics approval

The study protocol was approved by local ethical committee (Ref. number 2017/17-3; approval issue date Oct. 27, 2017).

Consent to participate

Written informed consent was obtained from all the participants.

Conflict of interest

The authors declared that they have no conflict of interest.

Compliance with Ethical Standards

Disclosure of potential conflicts of interest

All authors certify that they have no affiliations with or involvement in any organization or entity with any financial interest or non-financial interest in the subject matter or materials discussed in this manuscript.

Research involving Human Participants and/or Animals

Not applicable

Informed consent

Informed consent was obtained from all individual participants included in the study.

References

1. Schulz J, Asghar J, Bastrom T, Shufflebarger H, Newton PO, Sturm P, Betz RR, Samdani AF, Yaszay B (2014) Optimal radiographical criteria after selective thoracic fusion for patients with adolescent

idiopathic scoliosis with a C lumbar modifier: does adherence to current guidelines predict success? *Spine.* 39:1368-1373. doi: 10.1097/BRS.0000000000000580.

2. Edwards CC, Lenke LG, Peelle M, Sides B, Rinella A, Bridwell KH (2004) Selective thoracic fusion for adolescent idiopathic scoliosis with C modifier lumbar curves: 2-to 16-year radiographic and clinical results. *Spine.* 29:536-546. doi: 10.1097/01.brs.0000109992.22248.77.
3. Senkoylu A, Luk KD, Wong YW, Cheung KM (2014) Prognosis of spontaneous thoracic curve correction after the selective anterior fusion of thoracolumbar/lumbar (Lenke 5C) curves in idiopathic scoliosis. *Spine J.* 14:1117-1124. DOI: 10.1016/j.spinee.2013.07.467
4. McCance SE, Denis F, Lonstein JE, Winter RB (1998) Coronal and sagittal balance in surgically treated adolescent idiopathic scoliosis with the King II curve pattern: a review of 67 consecutive cases having selective thoracic arthrodesis. *Spine.* 23:2063-2073. doi: 10.1097/00007632-199810010-00005.
5. Weinstein SL, Dolan LA, Cheng JC, Danielsson A, Morcuende JA (2008) Adolescent idiopathic scoliosis. *Lancet.* 371:1527-1537. DOI: 10.1016/S0140-6736(08)60658-3
6. Wang F, Xu XM, Wei XZ, Zhu XD, Li M (2015) Spontaneous thoracic curve correction after selective posterior fusion of thoracolumbar/lumbar curves in Lenke 5C adolescent idiopathic scoliosis. *Medicine.* 94:29:1155. doi: 10.1097/MD.0000000000001155.
7. Puno RM, An KC, Puno RL, Jacob A, Chung SS (2003) Treatment recommendations for idiopathic scoliosis: an assessment of the Lenke classification. *Spine.* 28:2102-2114. DOI: 10.1097/01.BRS.0000088480.08179.35
8. Lenke LG, Betz RR, Harms J, Bridwell KH, Clements DH, Lowe TG, Blanke K. Adolescent idiopathic scoliosis: a new classification to determine extent of spinal arthrodesis. *J Bone Joint Surg Am* 83:1169-1181.
9. Cummings RJ, Loveless EA, Campbell J, Samelson S, Mazur JM (1998) Interobserver reliability and intraobserver reproducibility of the system of King et al. for the classification of adolescent idiopathic scoliosis. *J Bone Joint Surg Am* 80:1107. DOI: 10.2106/00004623-199808000-00003
10. Clements DH, Marks M, Newton PO, Betz RR, Lenke L, Shufflebarger H (2001) Did the Lenke classification change scoliosis treatment? *Spine.* 36:1142-1145. DOI: 10.1097/BRS.0b013e318207e9c4
11. Lark RK, Yaszay B, Bastrom TP, Newton PO (2013) Adding thoracic fusion levels in Lenke 5 curves: risks and benefits. *Spine* 38:195-200. DOI: 10.1097/BRS.0b013e3182634c85
12. Ilharreborde B (2018) Sagittal balance and idiopathic scoliosis: does final sagittal alignment influence outcomes, degeneration rate or failure rate? *European Spine Journal.* 27:48-58. DOI: 10.1007/s00586-018-5472-9
13. Yang X, Liu L, Song Y, Zhou C, Zhou Z, Wang L, Wang L (2015) Pre-and postoperative spinopelvic sagittal balance in adolescent patients with lenke type 5 idiopathic scoliosis. *Spine.* 40:102-108. DOI: 10.1097/BRS.0000000000000685

14. Qiu G, Zhang J, Wang Y, Xu H, Zhang J, Weng X, Lin J, Zhao Y, Shen J, Yang X, Luk KD (2005) A new operative classification of idiopathic scoliosis: a Peking Union Medical College method. *Spine.* 30:1419-1426. DOI: 10.1097/01.brs.0000166531.52232.0c.
15. Roussouly P, Labelle H, Rouissi J, Bodin A (2013) Pre-and post-operative sagittal balance in idiopathic scoliosis: a comparison over the ages of two cohorts of 132 adolescents and 52 adults. *Eur Spine J.* 22:203-215. DOI: 10.1007/s00586-012-2571-x.
16. Suk SI, Kim WJ, Kim JH, Lee SM (1999)Restoration of thoracic kyphosis in the hypokyphotic spine: a comparison between multiple-hook and segmental pedicle screw fixation in adolescent idiopathic scoliosis. *J Spinal Disord.* 12:489-495.
17. Connolly PJ, Von Schroeder HP, Johnson GE, Kostuik JP (1995) Adolescent idiopathic scoliosis. Long-term effect of instrumentation extending to the lumbar spine. *J Bone Joint Surg Am* 77:1210-1216. DOI: 10.2106/00004623-199508000-00011
18. Takayama K, Nakamura H, Matsuda H (2009) Low back pain in patients treated surgically for scoliosis: longer than sixteen-year follow-up. *Spine.* 34:2198-2204. DOI: 10.1097/BRS.0b013e3181b3f31f
19. Lonner BS, Ren Y, Newton PO, Shah SA, Samdani AF, Shufflebarger HL, Asghar J, Sponseller P, Betz RR, Yaszay B (2017) Risk factors of proximal junctional kyphosis in adolescent idiopathic scoliosis—the pelvis and other considerations. *Spine deform.* 5(3):181-188. DOI: 10.1016/j.jspd.2016.10.003
20. Farshad M, Catanzaro S, Schmid S (2016) The spinopelvic geometry in different Lenke curve types of adolescent idiopathic scoliosis. *Spine deform.* 4:425-431. DOI: 10.1016/j.jspd.2016.08.003
21. Schwab F, Lafage V, Patel A, Farcy JP (2009) Sagittal plane considerations and the pelvis in the adult patient. *Spine.* 34:1828-1833. DOI: 10.1097/BRS.0b013e3181a13c08
22. Barrey C, Roussouly P, Le Huec JC, D'Acunzi G, Perrin G (2013) Compensatory mechanisms contributing to keep the sagittal balance of the spine. Eur Spine J. 22:834-841. DOI: 10.1007/s00586-013-3030-z

Figures

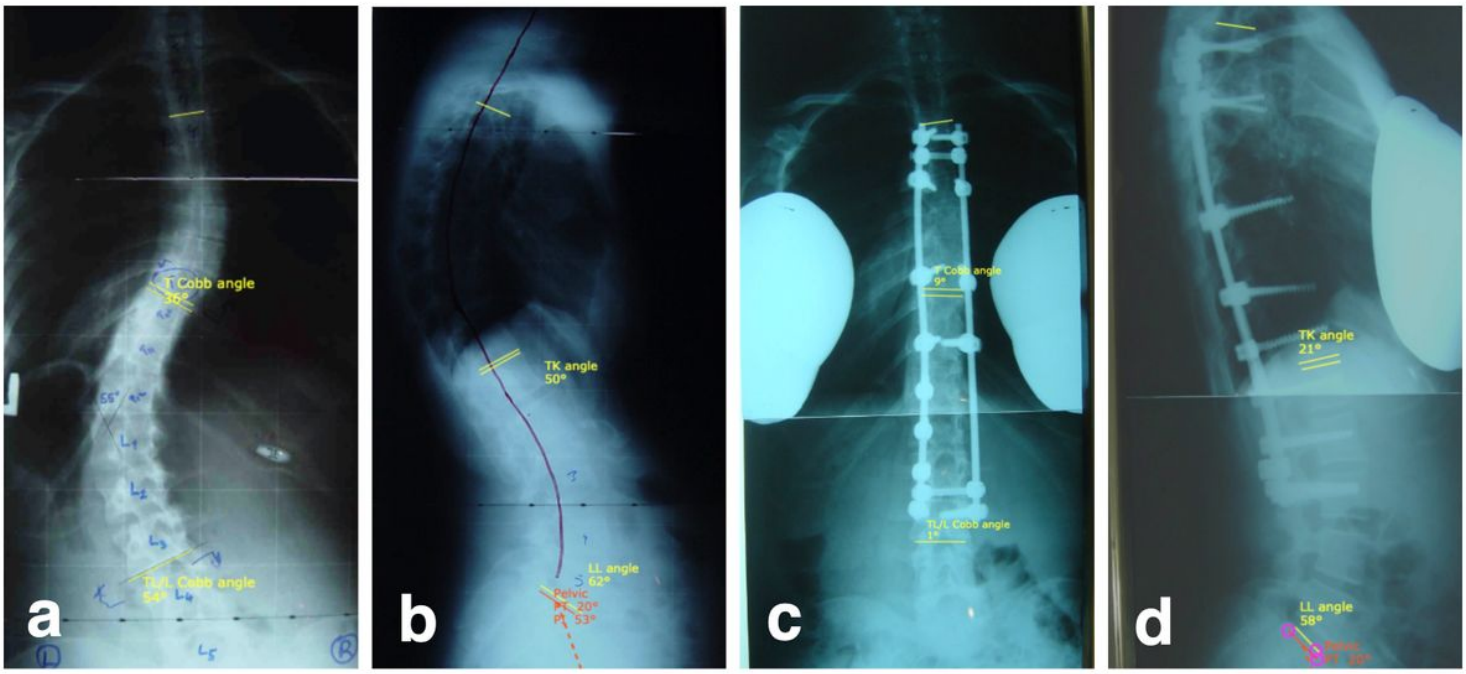

Figure 1

Preoperative (a and b) and 37 month-follow-up radiographs (c and d) of a 25-year - old female patient with a 54° TL/L Cobb angle, 36° T Cobb angle, and 50° T hyper-kyphosis were corrected by non-selective fusion procedure. TL/L Cobb, T Cobb and T kyphosis were 1°, 9°, and 2°; respectively.