Endoluminal Vacuum Assisted Closure (E-Vac) Therapy for Postoperative Esophageal Fistula: Successful Case Series and Literature Review

Carolina Rubicondo (carolinarubicondo1988@gmail.com)
Aziende Socio Sanitarie Territoriale Papa Giovanni XXIII https://orcid.org/0000-0002-2002-4793

Andrea Lovece
Aziende Socio Sanitarie Territoriale Papa Giovanni XXIII

Domenico Pinelli
Aziende Socio Sanitarie Territoriale Papa Giovanni XXIII

Amedeo Indriolo
Aziende Socio Sanitarie Territoriale Papa Giovanni XXIII

Alessandro Lucianetti
Aziende Socio Sanitarie Territoriale Papa Giovanni XXIII

Michele Colledan
Aziende Socio Sanitarie Territoriale Papa Giovanni XXIII

Case report

Keywords: E-Vac therapy, oesophageal fistula, oesophageal leaks, anastomotic leaks, bronchogenic cyst

Posted Date: June 11th, 2020

DOI: https://doi.org/10.21203/rs.3.rs-34105/v1

Version of Record: A version of this preprint was published at World Journal of Surgical Oncology on November 14th, 2020. See the published version at https://doi.org/10.1186/s12957-020-02073-6.

Abstract

Background: Treatment of esophageal perforations and postoperative anastomotic leaks of the upper gastrointestinal tract remains a challenge. Endoluminal vacuuma assisted closure (E-vac) therapy has positively contributed, in recent years, to the management of upper gastrointestinal tract perforations by using the same principle of vacuum assisted closure therapy of external wounds. The aim is to provide continuous wound drainage and to promote tissue granulation, decreasing the needed time to heal with a high rate of leakage closure.

Report of cases: A series of two different cases with clinical and radiological diagnosis of esophageal fistulas, recorded during the 2018 to 2019 period at our institution, is presented. The first one is a case of anastomotic leak after esophagectomy for cancer complicated by pleuro-mediastinal abscess; while the second one is a leak of an esophageal suture, few days after resection of a bronchogenic cyst perforated into the esophageal lumen. Both cases were successfully treated with E-vac therapy.

Conclusion: Our results confirm the usefulness of E-vac therapy in the management of anastomotic and non-anastomotic esophageal fistulas. Further research is needed to better define its indications, to compare it to traditional treatments and to evaluate its long-term efficacy.

Background

Esophageal perforations and postoperative eesophageal anastomotic leaks are still a life-threatening condition; the reported mortality ranges from 10% to 25%, when therapy is started within 24 hours, and from 40% to 60% when the treatment is delayed[1]. Iatrogenic perforation is the leading cause of esophageal perforations, accounting for around 60% of all cases. Less frequent causes are trauma at the upper abdomen or chest, Boerhaave's syndrome or spontaneous perforations induced by straining and vomiting[2]. Esophageal anastomotic leak remains one of the most devastating complications after esophagectomy and gastrectomy, with a wide range of reported incidences from 0 to 35% after esophagectomy and 2.7% to 12.3% after total gastrectomy[3].The key point of a correct treatment includes resuscitation of the patient, assessment of the defect and timely decision-making[4,5]. Surgical revision is usually challenging and carries a high risk of severe secondary complications. In the last few years, endoscopy has gained a primary role in both diagnosis and treatment of esophageal perforations and leaks. Several minimally invasive treatments have become available, including application of metal clips, fibrin glue and placement of self-expanding metal or plastic stents[6]. However, these treatments may not always lead to a sufficient sealing of the leakage.

A promising method to manage anastomotic leaks and perforations is the endoscopic vacuum-assisted closure system. Vacuum assisted therapy is broadly used in the management of skin and muscular defects, the first report dating back to 1962[7]. The permanent suction reduces wound secretion and oedema, improves microcirculation, induces granulation of the wound and decreases wound size by retraction. Since the 1990s, the number of indications for VAC Therapy has been steadily increasing[8-9],

more recently including its endoscopic application to perforations and fistulae of the digestive tract, mainly in the rectum and esophagus.

This paper reports the successful closure of two different kinds of oesophageal fistula; the first one is a complex anastomotic leak, complicated by pleuro-mediastinal abscess, after esophagectomy for cancer, which is the most common indication for this treatment. The second one is a leak of esophageal suture, few days after resection of a rare bronchogenic cyst perforated into the oesophageal lumen.

The E-VAC method.

The E-VAC[9] system for different type of postoperative esophageal leak consists in a sponge, to be placed across the defect, connected by a tubing to an external vacuum pomp and a reservoir (ESO-Sponge®). The application system includes an application tube and a pusher. The treatment is performed in the operating theatre with the patient in a supine position, anaesthetised and intubated. General anaesthesia is required to facilitate insertion of the E-VAC device. First, the fistula cavity is explored and measured with a flexible endoscope. The application tube (overtube) is pushed over the endoscope and brought up to the distal end of the leakage cavity. The endoscope is retracted and the sponge is pushed into the overtube to its end. A metallic marker placed on the skin may help in the positioning and avoid sponge displacement. The application system is then removed and the sponge tubing is passed and exited through the nostril and connected to the vacuum pump. Continuous suction with a negative pressure of 125 mm Hg is applied. Figure 1 provide a pathway for a correct placement of the sponge. In accordance with the experience of VAC therapy for skin defect, the procedure is repeated by replacing the sponge every 72 hours, until granulation leads to obliteration of the cavity.

Case Presentation 1

A 62-year-old woman diagnosed with esophageal cancer was referred to our hospital. Her work up included esophagogastroduodenoscopy (EGDS), Contrast-enhanced Computed tomography (CT) scan and ^{18}F-fluorodeoxyglucose-positron emission tomography (^{18}F-FDG-PET), leading to the diagnosis of esophageal adenocarcinoma (T3N+M0. She received two cycles of neoadjuvant chemotherapy, consisting in docetaxel, cisplatin and 5-fluorouracil, in 3-week intervals. Post-treatment CT scan revealed a reduction in both primary tumor size and lymphadenopathies. The patient underwent then an Ivor-Lewis esophagectomy.

Post-operative course was normal until postoperative day 9, when she became feverish and white cell count rose to 21 k/mm^3. Chest CT scan revealed a frank anastomotic leak with a periesophageal, loculated abscess formation (Figure2). Broad-spectrum antibiotic coverage was initiated in the form of Piperacillin-Tazobactam every eight hours. EGDS confirmed a >1 cm disruption at the gastroesophageal anastomosis.

Usually, in our experience, standard endoscopic treatment consisted of external drainage, endoscopic lavage, debridement of the fistula and, if possible, implantation of covered stents. Unfortunately, in this

case, the pleuro-mediastinal abscess was very difficult to reach by external drainages and the anastomotic leakage was very high. With the aim of resolving the leakage and controlling the abscess, we opted for E-VAC treatment. This was performed for a total of 22 days while the sponge was changed 6 times. Excellent granulation of the wound was achieved, together with a progressive reduction of the cavity size and of the pleuro-mediastinal abscess (Figure 3). Patient conditions dramatically improved with normalization of temperature and white cell count and no sign of sepsis. At the end, both an endoscopic and radiologic check confirmed the closure of the leak. The recovery was then uneventful and oral nutrition was re-administered. The patient was discharged without sign of recurrence 3 month after the initial surgery.

Case Presentation 2

A 25-year-old man was referred to our hospital in 2014 for a suspected right bronchogenic cyst. He underwent a trans-esophageal biopsy to confirm the diagnosis. After a few days he started to complain of fever and acute chest pain. A contrast-enhanced CT scan revealed a massive pleural effusion in the right hemithorax with complete atelectasis of the ipsilateral lung (Figure 4).

The consequent work-out included a barium-swallow study and an endoscopic evaluation, which didn't reveal any esophageal leak. The initial treatment with multiple drainage of the right hemithorax and broad-spectrum antibiotic therapy couldn't lead to complete resolution. A right thoracoscopy was therefore performed, in order to achieve a better debridement and drainage. Even during this procedure, no esophageal perforation was seen. The following clinical course was normal, so the patient was discharged on postoperative day 15.

In December 2019, the patient was referred to our Emergency Department because of the sudden onset of fever (39°C) with acute chest pain. He underwent a CT-scan which revealed a suspected esophageal perforation with acute mediastinitis and right pleural effusion. A subsequent gastroscopy showed, at 35cm from dental arch, an erosion of the esophageal wall 1,5 cm long and a 2 mm perforation with a small leak of purulent liquid. Furthermore, an endoscopic ultrasound revealed the presence of the bronchogenic cyst just outside the erosive area. Thus, a right thoracotomy with intraoperative endoscopy was performed. An esophageal perforation at the level of the cyst was found, so the right hemithorax was cleaned, the cyst was opened in order to better understand its margin, and then resected, while the esophageal wall was closed with two interrupted, absorbable stitches. A 24 Ch drain was left in place. After two days, salivary material appeared into the drain, so the patient underwent an EGDS, which revealed a 7 mm hole of the esophageal wall at the level of the previous suture (Figure 5-A). Thus, an E-Vac therapy was placed into the perforation (Figure 5-B).

The duration of the endoscopic treatment was 17 days, with a total of 5 E-Vac changes (Figure 5 C-D). After the removal of the last sponge, the patient started an oral diet without complications. One last barium swallow study showed no leak, so the patient was discharged home. Pathology confirmed the diagnosis of bronchogenic cyst. At three months follow-up, there was no sign of recurrence.

Discussion And Literature Review

The present paper describes two different cases of esophageal fistulas, with different origin and frequency, successfully managed by E-Vac therapy.

Regarding Case n°1, postoperative esophageal anastomotic leak is a severe condition that negatively impacts postoperative outcomes[10]. The incidence ranges between 0 to 35%[3] after esophagectomy and 2.7% to 12.3% after total gastrectomy with up to 60% mortality[11].

As regards Case n°2, only few bronchogenic cysts communicating with the esophagus have been reported in the available literature[14]. Only one case of bronchogenic cyst complicated with post-operative esophageal perforation was reported[15].

The management of esophageal fistula, regardless the cause, requires a multidisciplinary approach between surgeons, gastroenterologists, radiologists and intensive care physicians. The key point of treatment is the control of sepsis, achieved by containing the ongoing leakage from the esophagus, draining the pleural, mediastinal or abdominal cavities and giving appropriate antibiotic therapy. Nutritional support is mandatory, preferably with the enteral way or via parenteral nutritional when the former is not available[12]. Surgical closure of the esophageal defect is generally complex and scarcely effective. On the other hand, during the last decades, numerous endoscopic techniques have been developed, the real cornerstone of which being the endoscopic stent implantation[13], with a demonstrated clinical success rate of over 80%. In 2008, Weidenhagen et al.[22] reported on Endo-VAC treatment of anastomotic leakages after rectal resections. Only a few years later, Loske et al. started to transfer this treatment in patients with leakages in the upper gastrointestinal tract[23].

In the last decade, the E-VAC therapy for the treatment upper GI defects has become a valid endoscopic alternative. This has been demonstrated in published case series of more than 200 patients, in numerous German endoscopic centers[24].

In 2017, Kuehn et al.[25] published a Medline analysis of 11 case series with over 210 patients with upper GI tract defects treated with E-VAC. In this review, success rate was 90 and 96% respectively for anastomotic leakages and esophageal perforations. Currently, there are no prospective randomized clinical trials available comparing endoscopic stenting, E-VAC therapy and surgical revisions in upper GI leakages or perforations.

Our initial practice in E-VAC therapy for treatment of esophageal postoperative fistula confirms some technical rules:

- Crucial for E-vac placement is the dimension of the esophageal defect: it should be crossed with a standard diagnostic endoscope. In case of small wall defects, widening of the insufficiency hole is required to put the sponge into the leak cavity (Fig 2-4).

- Granulation tissue often ingrowths in to the sponge, leading to more difficult removal. More frequent changes of the device reduce the risk of bleeding and the complexity of the sponge extraction. We always changed the sponge within 72 hours without problems.

- Enteral feeding should be the mainstay of nutrition support (by nasojejunal feeding tube, PEG or surgical jejunostomy); parenteral nutrition should be established as a bridge strategy.

Conclusion

Our cases confirm that the open-cell sponge together with the topical application of negative pressure helps sealing the leak while providing an additional and simultaneous drainage of the cavity distal to it. This transluminal drainage allows an effective and continuous drainage of the abscess cavity, which is often difficult to address radiologically, therefore controlling and reducing the sepsis.

Both our cases, despite different pathologies and type of perforations, were successfully treated with the E-VAC therapy, confirming its promising prospects for all kind of oesophageal perforations, combined with a correct treatment of sepsis and risk of malnutrition.

Abbreviations

VAC: Vacuum Assisted Closure; EGDS: Esophagogastroduodenoscopy; CT: Computed Tomography; PET: Positron-Emission Tomography

Declarations

- Ethics approval and consent to participate: Not applicable
- Consent for publication: Patient’s consent for publication was obtained.
- Availability of data and materials: Not applicable
- Competing interests: The authors declare that they have no competing interests
- Funding: The authors declare that they have no funding
- Authors' contributions: CR and AL searched the literature and were a major contributor in writing the manuscript. AL and AI participated at the operation and the endoscopic treatment and were a contributor in writing and reviewing the manuscript. DP and MC reviewed the manuscript and were a contributor in writing it. All authors read and approved the final manuscript.
- Acknowledgements: not applicable

References

1. Biancari F, D'Andrea V, Paone R et al. Current treatment and outcome of esophageal perforations in adults: systematic review and meta-analysis of 75 studies. World J Surg. 2013 May; 37(5):1051-9.

2. Chirica M, Kelly MD, Siboni S et al. Esophageal emergencies: WSES guidelines. World J Emerg Surg. 2019; 14: 26
3. Blencowe NS, Strong S, McNair AGK et al. Reporting of short-term clinical outcomes after esophagectomy: a systematic review Ann Surg, 255 (2012), pp. 658-666
4. Sdralis EIK, Petousis S, Rashid F et al. Epidemiology, diagnosis and management of esophageal perforations: systematic review. Dis Esophagus. 2017 Aug 1;30(8):1-6
5. Søreide JA, Viste A. Esophageal perforation: diagnostic work-up and clinical decision-making in the first 24 hours. Scand J Trauma Resusc Emerg Med. 2011; 19: 66.
6. Rogalski P, Daniluk J, Baniukiewicz A. Endoscopic management of gastrointestinal perforations, leaks and fistulas. World J Gastroenterol. 2015 Oct 7; 21(37): 10542–10552.
7. Safronov AA: Vacuum therapy of trophic ulcers with simultaneous autoplastic skin transplantation (Article in Russian). Novyi Khirurgicheskii Arkhiv 1962; 3: 3–8.
8. Still S, Mencio M, Ontiveros E. Primary and Rescue Endoluminal Vacuum Therapy in the Management of Esophageal Perforations and Leaks. Ann Thorac Cardiovasc Surg. 2018; 24(4): 173–179.
9. Bludau M, Hölscher AH, Herbold T et al. Management of upper intestinal leaks using an endoscopic vacuum-assisted closure system (E-VAC). Surg Endosc. 2014 Mar;28(3):896-901.
10. Whooley BP, Law S, Alexandrou A et al. Critical appraisal of the significance of intrathoracic anastomotic leakage after esophagectomy for cancer. Am J Surg, 181 (2001), pp. 198-203
11. Lang H, Piso P, Stukenborg C et al. Management and results of proximal anastomotic leaks in a series of 1114 total gastrectomies for gastric carcinoma. Eur J Surg Oncol, 2000 Mar;26(2):168-71.
12. Messagera M, Warlaumonta M, Renaud F et al. Recent improvements in the management of esophageal anastomotic leak after surgery for cancer. Eur J Surg Oncol. 2017 Feb;43(2):258-269
13. Hünerbein M, Stroszczynski C, Moesta KT, et al. Treatment of thoracic anastomotic leaks after esophagectomy with self-expanding plastic stents. Ann Surg 2004; 240:801–807.
14. Sasaki K, Tanaka S, Koizumi et al. A case of Para-esopageal Bronchogenic Cyst With esophageal communication. Article in Japanese. Kyobu Geka. 1992 Aug;45(9):813-6.
15. Fukushima H, Hashimoto M, Sato Y. A case of giant bronchogenic cyst complicated with postoperative esophageal perforation. Article in Japanese. Kyobu Geka 1995 Jul;48(7):595-8.
16. Thacker PG, Rao AG, Hill JH et al. Congenital lung anomalies in children and adults: current concepts and imaging findings, Radiol Clin N.Am.52(1)(2014) 155–181.
17. Ko S, Hsieh MJ, Lin JW et al (2006) Bronchogenic cyst of the esophagus: clinical and imaging features of seven cases. Clin Imaging. Sep-Oct 2006;30(5):309-14
18. Suen HC, Mathisen DJ, Grillo HC et al. Surgical management and radiological characteristics of bronchogenic cysts. Ann Thorac Surg 1993;55:476-81.

19. Trotman-Dickenson B, Congenital lung disease in the adult: guide to the evaluation and management, J.Thorac. Imaging30(1)(2015)46–59.
20. Leguen Y. Hureaux J Treatment of a compressive bronchogenic cyst by CT guided needle aspiration. Rev Mal Respir 2005;22
21. Kawaguchi Y, Hanaoka J, Asakura. Takuya FujitaInfected Bronchogenic Cyst Treated With Drainage Followed by Resection. Ann Thorac Surg. 2014 Jul;98(1):332-4
22. Weidenhagen R, Hartl WH, Gruetzner KU. Anastomotic leakage after esophageal resection: new treatment options by endoluminal vacuum therapy. Ann Thorac Surg 90(5):1674–1681
23. Loske G, Schorsch T, Müller C (2011) Intraluminal and intracavitary vacuum therapy for esophageal leakage: a new endoscopic minimally invasive approach. Endoscopy 43(6):540–544 7.
24. Schniewind B, Schafmayer C, Voehrs G et al. Endoscopic endoluminal vacuum therapy is superior to other regimens in managing anastomotic leakage after esophagectomy: a comparative retrospective study. Surg Endosc 27(10):3883–3890
25. Kuehn F, Loske G, Schiffmann L et al. Endoscopic vacuum therapy for various defects of the upper gastrointestinal tract. Surg Endosc 2017 Sep;31(9):3449-3458

Figures

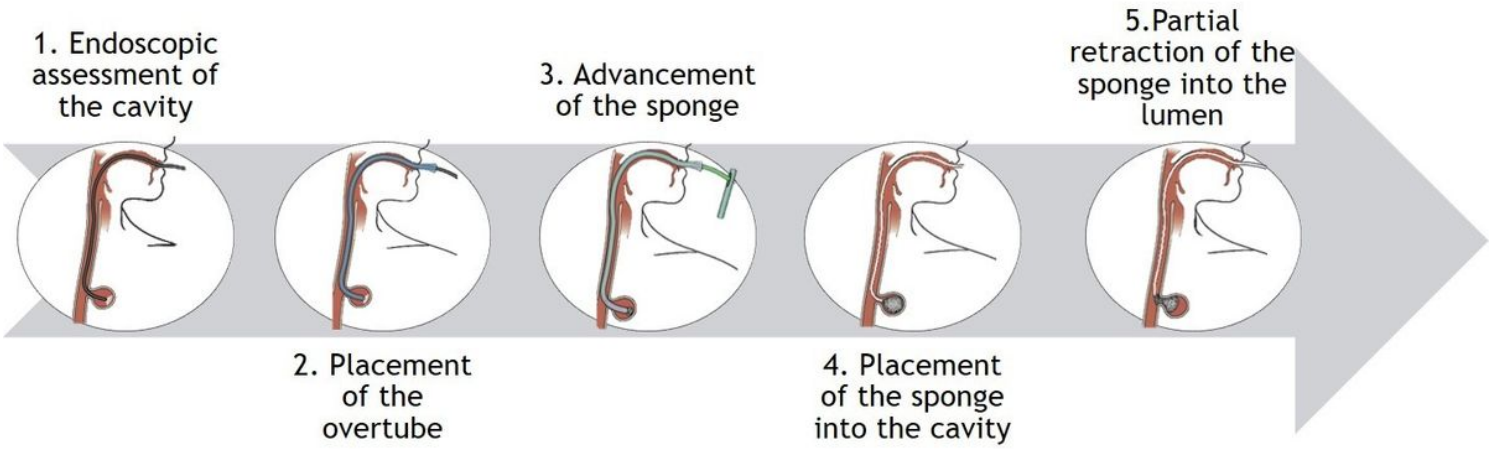

Figure 1

Pathway of correct Eso-Sponge® placement.

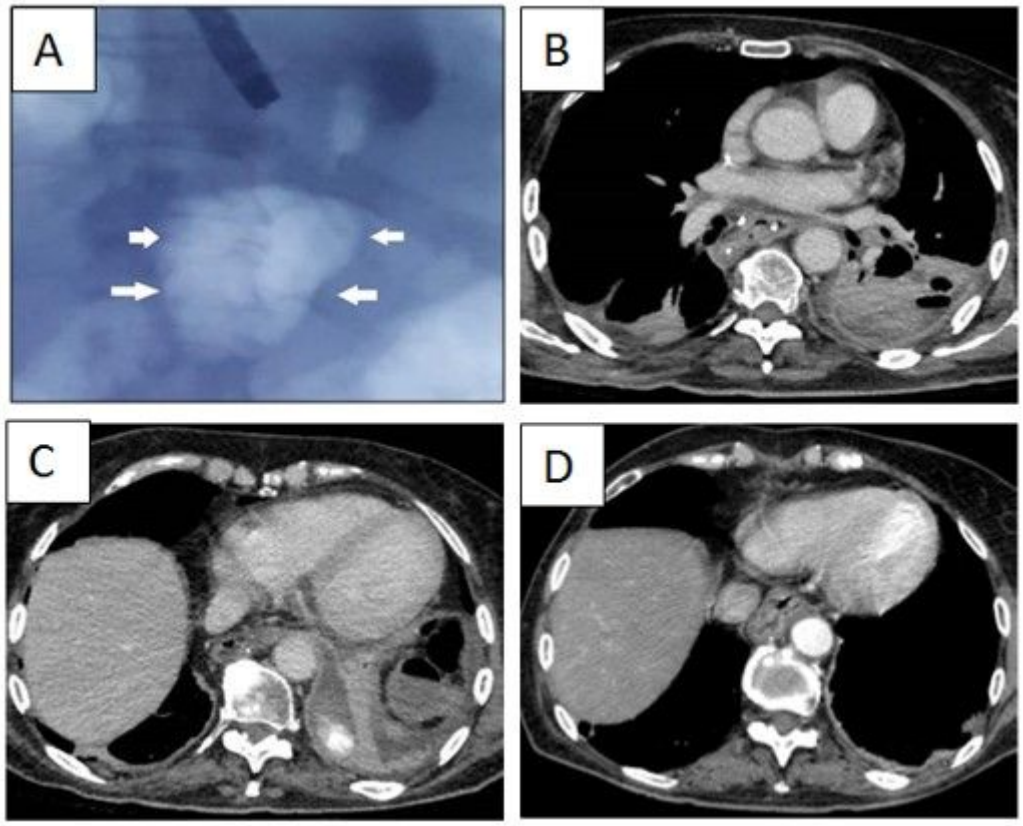

Figure 2

A) Radiologic view of the paraesophageal abscess (white arrows) during endoscopic examination. B-C) CT scan showing a left pleuro-mediastinal abscess. D) 3-months follow-up.

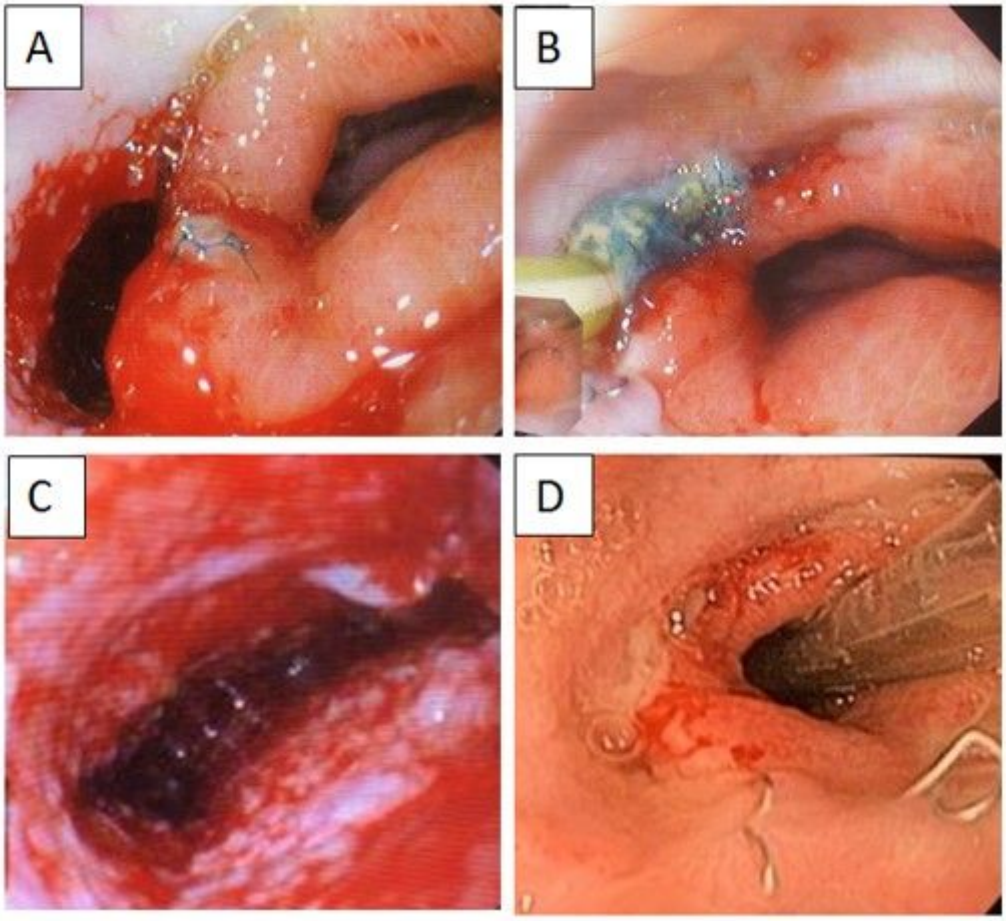

Figure 3

A) anastomotic leak; B) Eso-sponge® placement into the fistula; C) granulation tissue during the treatment; D) 3-months follow-up (nasogastric tube in place)

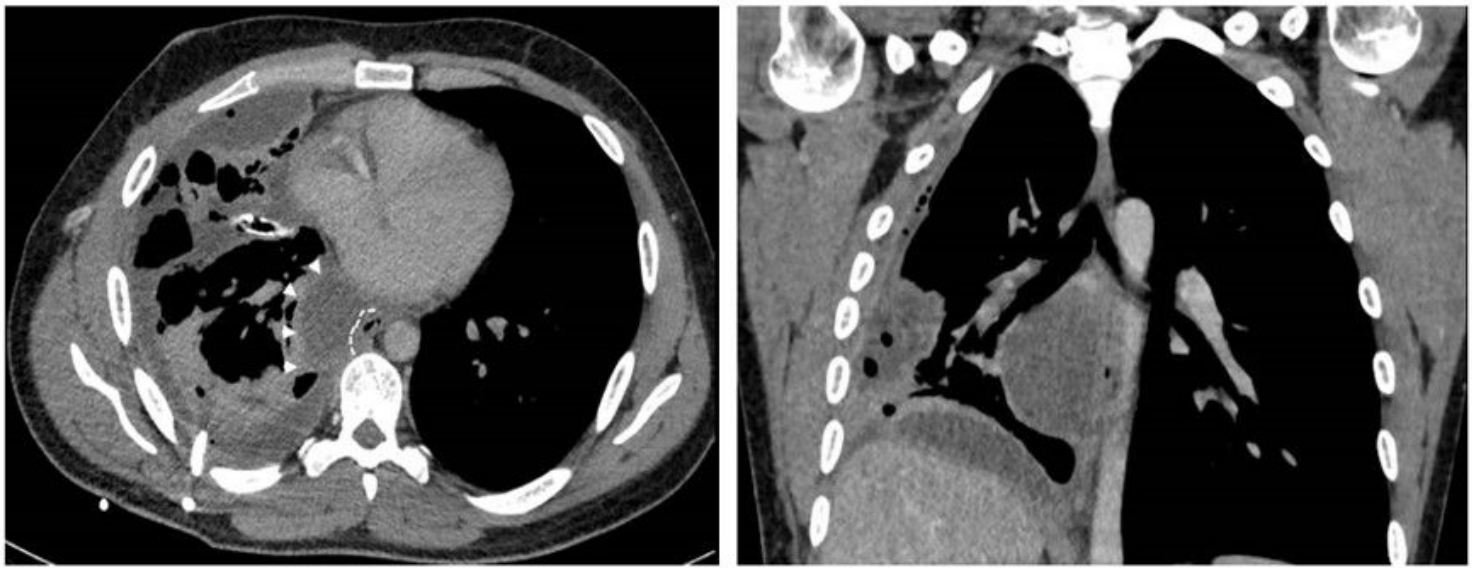

Figure 4

CT scan with a massive pleural effusion in the right hemithorax and complete atelectasis of the ipsilateral lung

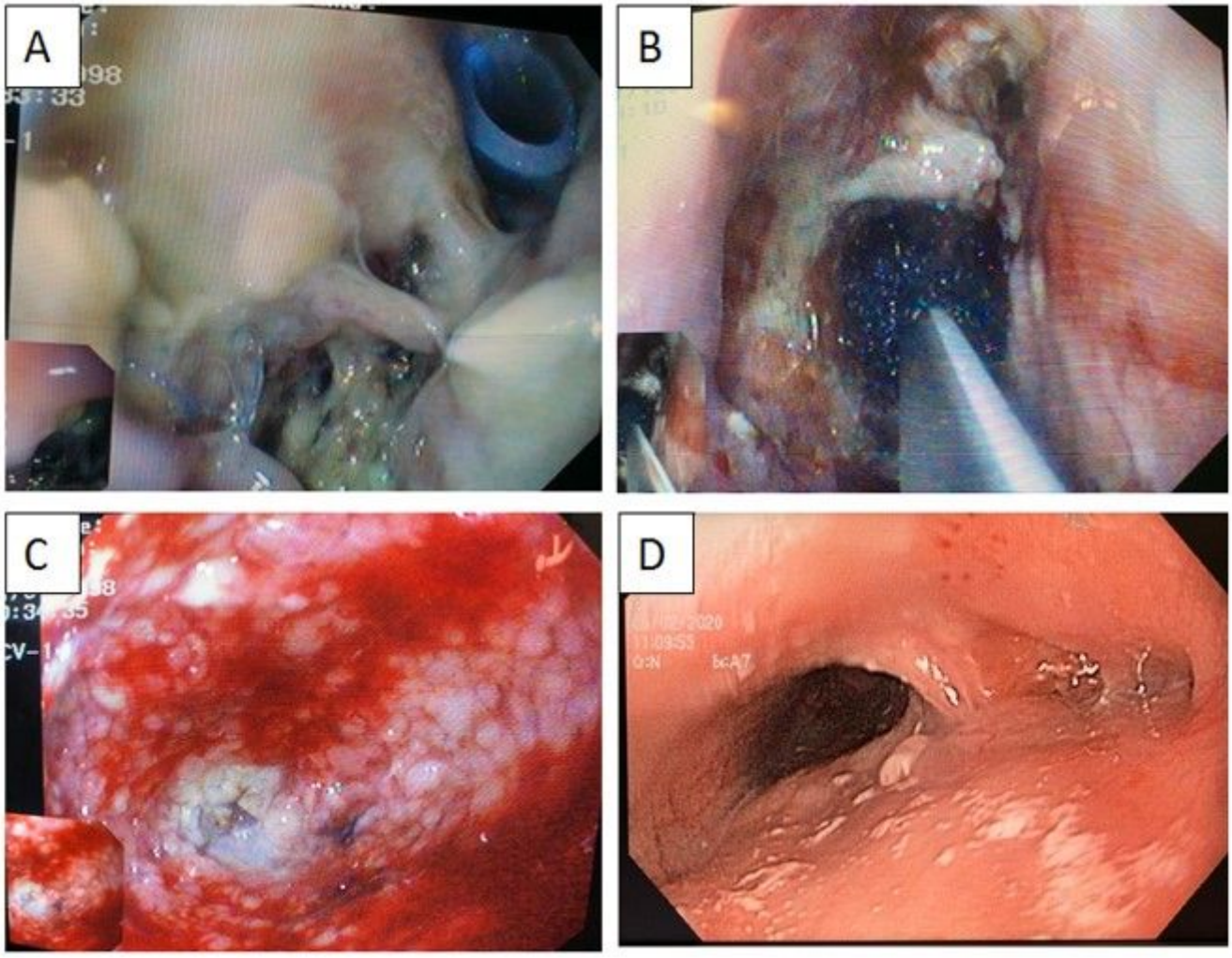

Figure 5

A) Post-surgical leak with the thoracic drain in place; B) Positioning of the Eso-sponge® into the cavity; C) Granulation tissue during the treatment D) 3-months follow-up