Double Sequential External Synchronization for Hemodynamically Stable Patients with Refractory Ventricular Tachycardia Storm: A Case Report

Yu-Ta Chien
Taipei Medical University Shuang Ho Hospital Ministry of Health and Welfare
Ting-Yun Huang (g167108010@tmu.edu.tw)
Taipei Medical University Shuang Ho Hospital Ministry of Health and Welfare

Case report

Keywords: Stable refractory ventricular tachycardia, Double sequential external synchronization, Acute myocardial infarction

Posted Date: March 23rd, 2021

DOI: https://doi.org/10.21203/rs.3.rs-346031/v1

Abstract

Background:

Refractory ventricular tachycardia (VT) can progress to acute heart failure, ventricular fibrillation, and sudden cardiac death. We introduced an alternative treatment for refractory hemodynamically stable VT storm, that is, double sequential external synchronization (DSES).

Case presentation:

We present a case report of a middle-aged Asian male diagnosed with refractory hemodynamically stable VT storm in which DSES successfully restored cardiac rhythm to normal sinus rhythm after several attempts of treatment with pharmacological agents and single-dose electrical cardioversion failed. The patient's symptoms were relieved after termination of VT storm.

Conclusion:

This article provides a potential treatment option for hemodynamically VT that has poor response to conventional pharmacological and single electrical cardioversion.

Introduction

Obstinate ventricular tachycardia with hemodynamic stability poses a threat to cardiovascular outcome and was quite frustrating to emergency physicians. This article offers another therapeutic tool for those suffering from refractory VT storms: double sequential external synchronization.

Hemodynamic stability takes priority when any patient with tachycardia is being evaluated. Immediate electrical cardioversion is reserved for the management of unstable tachycardia (2017 American Heart Association (AHA) guidelines). Generally, we treat relatively stable patients with tachycardia first with pharmacological cardioversion agents, such as procainamide, amiodarone, and lidocaine, and electrical cardioversion is applied only in instances of myocardial ischemia or failed pharmacological treatment. Double sequential external defibrillation and cardioversion have shown promise as treatments for refractory ventricular fibrillation or unstable VT. Treatment options for hemodynamically stable patients with refractory ventricular tachycardia (VT) include electrical cardioversion (class I), IV procainamide (class IIa), and IV amiodarone or sotalol (class IIb). If VT is not terminated after the aforementioned options have been exhausted, the patient receives another single shock. Catheter ablation, stellate block, and surgery are reserved for the prevention of recurrent VT. However, prolonged VT in patients who have had recent episodes of acute myocardial infarction while undergoing interventional reperfusion therapy is highly concerning. Prolonged VT may result in persistent cardiac ischemia, which can lead to in-stent restenosis, acute heart failure, and sudden cardiac death. Double sequential external synchronization (DSES) might be a potential method for the treatment of hemodynamically stable patients with refractory ventricular tachycardia storm.

The complete mechanism of DSES remains unknown. We used 2 defibrillators to provide shocks that exceeded the recommend dose of energy (measured in joules) to terminate a VT storm. DSES has clear benefits, such as termination of sustained VT and subsequent vicious cascade. Complications include chest wall burn, myocardial injury, and provoked ventricular fibrillation or cardiac arrest.

Case Presentation

A 56-year-old Asian man with underlying hypertension and type 2 diabetes presented to our emergency department (ED) with a complaint of palpitation that had persisted for the entire day. His medical history revealed that approximately 1 month prior, he had undergone drug-eluting stent implantation to the right coronary artery after a diagnosis of ST-elevation myocardial infarction. Percutaneous coronary intervention revealed 85% stenosis of the left anterior descending artery. Upon arrival at our ED, the patient was afebrile, fully conscious, and had normal blood pressure (SBP: 115 mmHg). However, he exhibited extreme tachycardia and had a heart rate of approximately 190 bpm. Nevertheless, upon arrival, the patient denied experiencing chest discomfort and had no signs of heart failure. A 12-lead electrocardiogram revealed monomorphic VT (Fig. 1).

Considering the patient's stable hemodynamic condition, we first arranged pharmacological cardioversion with amiodarone (150 mg) infusion, but it failed to normal sinus rhythm. Following this failure, we applied a continuous amiodarone infusion. Despite this pharmacological intervention, refractory VT persisted for 20 minutes, and we attempted synchronized electrical cardioversion with an initial single-dose biphasic 100-Joule (J) shock using a Philips Heartstart XL Monitor Defibrillator(Philips Medical Systems, 3000 Minuteman Road Andover, MA USA 01810 – 1099). However, the initial shock proved ineffective. Subsequently, we administered a single-dose 150-J shock and another 200-J synchronized biphasic shock, to no effect. Therefore, we attempted a double sequential external synchronization (DSES). Another 2 defibrillation pads were placed (total of 4 pads: set-1, one in the front chest and the other in the back; set-2, one below the left nipple and the other above the right nipple). Simultaneously, 150-J and 200-J synchronized biphasic shocks were given by a single emergency physician using 2 Philips Heartstart XL Monitor Defibrillators. The initial attempt failed, but a second DSES with a combined synchronized biphasic shock of 350 J restored normal sinus rhythm (Fig. 2). The patient's condition improved after DSES and he tolerated the whole procedure well without reporting discomfort, including chest pain or dyspnea. The cardiologists performed catheterization on the same day and revealed total occlusion of the left anterior descending artery. Thus, a second drug-eluting stent was implanted. The patient was discharged three days after surgery; during the patient's stay, no complications or recurrent VT events arose.

Discussion And Conclusion

Advanced cardiac life support guidelines suggest that pharmacological cardioversion be applied for the primary management of hemodynamically stable VT. However, for patients with structural heart disease, the 2017 AHA guidelines recommend electrical cardioversion (class I) over pharmacological

cardioversion (class IIa and IIb) even though several medications, such as amiodarone, procainamide, lidocaine and sotalol, can terminate VT in patients with hemodynamic stability. The 2017 AHA guidelines, in agreement with Kelson et al,[1] describe procainamide (class IIa) as being more effective than amiodarone (IIb) for this purpose. However, for intractable hemodynamically stable VT, electrical cardioversion and catheter ablation are the preferred options, though catheter ablation may not always be feasible. Therefore, in accordance with the 2017 AHA guidelines, which recommend initial single-dose cardioversion with a biphasic 100-J shock, electrical cardioversion is the most practical intervention for intractable hemodynamically stable VT. The guidelines recommend that practitioners administer shocks with incremental increases in energy (J) if the first attempt fails. Defibrillators can output a maximum of approximately 150–200 J, depending on the manufacturer. However, patients' VT may remain refractory to single-dose cardioversion at the currently recommended dose.

In 1994, Hoch DH et al[2] introduced the concept of DSED for refractory ventricular defibrillation (Vfib). DSED offers an alternative effective treatment for patients with intractable Vfib, though this is still considered an unapproved treatment according to 2020 AHA guidelines (class IIb). The application of DSED for refractory VT is not common. To date, 2 articles have discussed double sequential external cardioversion for patients with VT. In 2017, Gerstein NS et al[3] administered a combined 560-J shock to a patient to treat borderline hypotension (SBP: 91 mmHg) and VT, although both attempts failed. However, one of the defibrillators malfunctioned the next day after a dual-dose cardioversion attempt. In 2018, Sheikh H et al[4] delivered a combined 400-J shock to a patient with unstable VT and successfully restored the patient's normal sinus rhythm. Elevated cardiac enzymes were found after the cardioversion.

For patients with structural heart diseases, including ischemic heart disease, uncontrollable VT may have severe consequences, such as cardiogenic shock, acute heart failure, and eventually cardiac arrest. Given that our patient experienced a recent myocardial infarction, refractory VT might have aggravated myocardial ischemia. Therefore, we had to terminate VT immediately despite our patient's relatively stable hemodynamic condition. Because our treatment with pharmacological cardioversion and single-dose electrocardioversion failed, we used DSES, despite a lack of precedence for its efficacy.

To our knowledge, this is the first reported case of successful conversion of VT to a normal sinus rhythm using DSES. Standard pharmacological or electrical cardioversion might be unfeasible for certain groups. However, DSES may also prove valuable in terminating refractory VT in such groups. First, people with hereditary channelopathies, such as Brugada syndrome and long QT syndrome, without structure abnormalities, must be taken into consideration. Second, people with structural abnormalities (as defined by the 2015 AHA guidelines), such as coronary artery disease, ongoing acute coronary syndrome, congestive heart failure, and cardiomyopathies, are potential candidates for DSES. When treating such patients, clinicians may wish to prioritize the use of DSES.

DSES may result in elevated cardiac enzymes, which may alternatively occur as a consequence of cardiac arrhythmia itself and damaged defibrillators, according to previous reports.

However, devastating results may also occur due to lack of experience with DSES procedures. First, the mechanism behind the procedure and which patient groups would gain the greatest benefits from this intervention are not well understood. Second, due to the lack of interventions performed using this method, complications as a consequence of DSES are also not well known. Further research is necessary to determine the benefits and potential harms of this procedure.

Refractory VT or Vfib present many challenges for clinicians, especially when treating patients structural abnormalities. Devastating consequences(such as acute heart failure and cardiopulmonary failure) may occur suddenly in such patients. Terminating VT in a timely manner is our first priority, and the clinical decision of intervention solely depends on a patient's hemodynamic status. Therefore, we present our case to raise awareness that DSES could play an important role in terminating refractory VT, even in patients with a stable hemodynamic condition.

Refractory stable tachyarrythmia is a catastrophic event commonly encountered in the ED. However, when single electrical cardioversion fails, alternatives are required, one of which is DSED.

Abbreviations

VT: ventricular tachycardia

DSES: double sequential external synchronization

AHA: American Heart Association

ED: emergency department

Declarations

Ethics approval and consent to participate

This study was approval by the Institutional Review Board affiliated with Taipei Medical University (IRB#: N202006021).

Consent for publication:

Written informed consent was obtained from the patient for publication of this case report and any accompanying images. A copy of the written consent is available for review by the Editor-in-Chief of this journal.

Competing interests:

YT Chien declares that he has no conflict of interest. TY Huang declares that she has no conflict of interest.

Funding:

None

Authors' contributions:

TH interpreted the patient data and performed the histological examination. YC was a major contributor in writing the manuscript. All authors read and approved the final manuscript

Acknowledgements:

None

Availability of data and materials:

Data sharing is not applicable to this article as no datasets were generated or analysed during the current study.

References

1. Kelson K, deSouza I. Procainamide Versus Amiodarone for Stable Ventricular Tachycardia. *Acad Emerg Med*. 2019;26(9):1099- doi:10.1111/acem.13767
2. Hoch DH, Batsford WP, Greenberg SM, et al. Double sequential external shocks for refractory ventricular fibrillation. *J Am Coll Cardiol*. 1994;23(5):1141- doi:10.1016/0735-1097(94)90602-5
3. Gerstein NS, McLean AR, Stecker EC, Schulman PM. External Defibrillator Damage Associated With Attempted Synchronized Dual-Dose Cardioversion. *Ann Emerg Med*. 2018;71(1):109- doi:10.1016/j.annemergmed.2017.04.005
4. Sheikh H, Xie E, Austin E. Double sequential cardioversion for refractory ventricular tachycardia: A case report. *CJEM*. 2018;20(S2):S56- doi:10.1017/cem.2017.428

Figures

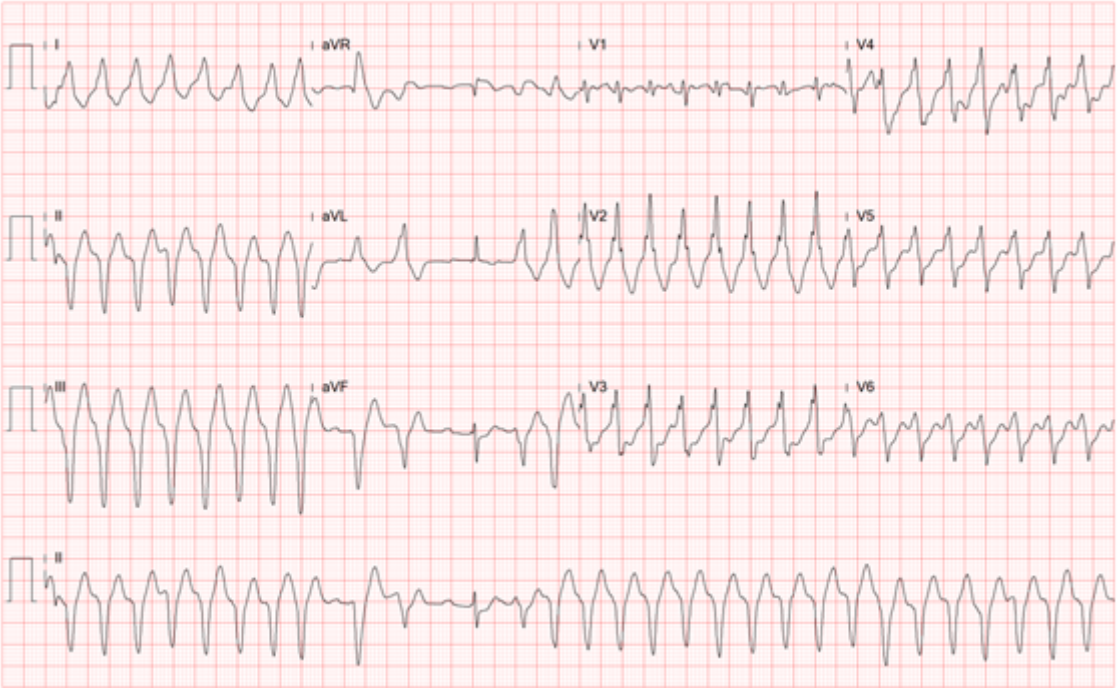

Figure 1

ECG Upon Visiting

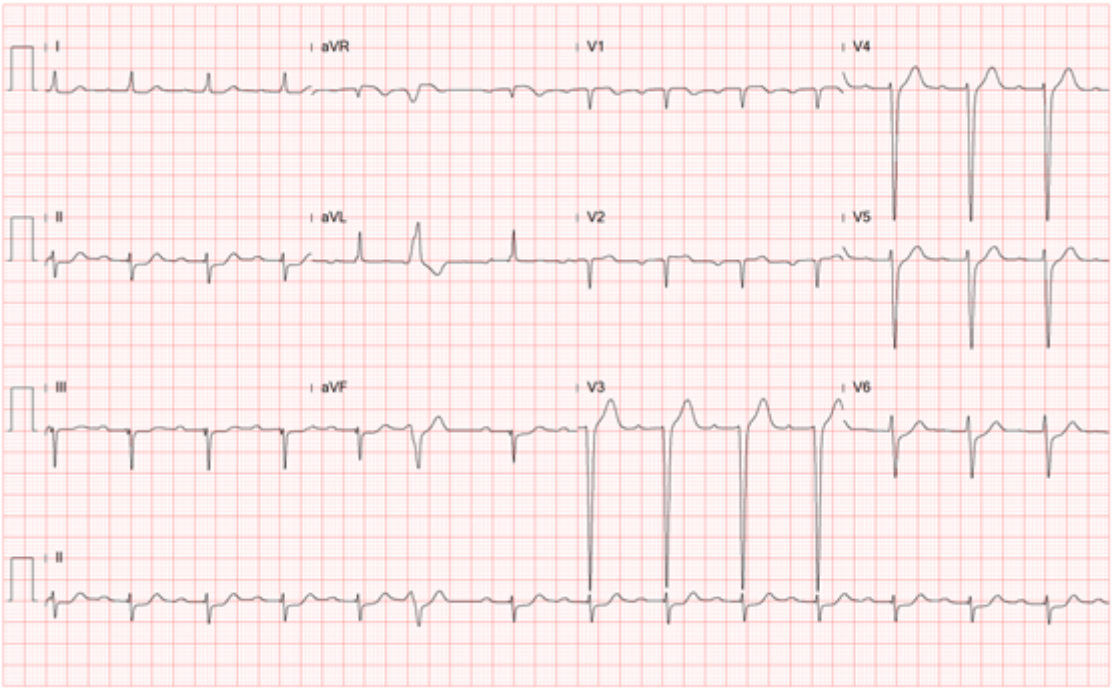

Figure 2

ECG After DSES