The staged treatment for tibial plateau fractures and the reconstruction of lateral column with autogenous iliac bone: an efficacy analysis report

Dong Li
Second Hospital of Shanxi Medical University
Xiao Liang
Second Hospital of Shanxi Medical University
Kun Xi
First Affiliated Hospital of Soochow University
Bin Zhao
Second Hospital of Shanxi Medical University
Fushan Hou (houfushan3482@163.com)
Second Hospital of Shanxi Medical University https://orcid.org/0000-0002-7546-7890

Research Article

Keywords: tibial plateau fractures, treatment, reconstruction of the lateral column, autogenous iliac bone

Posted Date: April 13th, 2021

DOI: https://doi.org/10.21203/rs.3.rs-346348/v2

Abstract

Background: Complications in treating comminuted tibial plateau fractures with extensive soft tissue damage are common. In this study, we discussed the effect of staged treatment in the reconstruction of the lateral column with autogenous iliac bone using case follow-up.

Methods: A retrospective analysis of 18 patients with comminuted tibial plateau fractures and extensive soft tissue damage from October 2016 to February 2020 who underwent staged treatment in our hospital. After the soft tissue damage repair, a large autologous iliac bone was used to reconstruct the lateral column of the tibial plateau.

Results: All 18 patients were followed up over the course of 8-40 months, with an average of 23.44 months. All patients reported zero postoperative infection, skin and soft tissue necrosis, and loosening/breakage of the internal fixation. Regular postoperative review revealed that all patients achieved complete bony union, as evidenced by X-ray film, at 6 months after operation. Knee function (HSS) scores averaged 86.72 points at 1 year after operation; 15 people with 85 points or more, 2 people with 70-84 points, and one with 68 points. The excellent rate, according to HSS was 90%.

Conclusions: Complex tibial plateau fractures with extensive soft tissue damage can be effectively remedied with a staged treatment, wherein a lateral column reconstruction is performed using a large iliac bone.

1. Background

High-energy tibial plateau fractures are generally associated with severely fractured articular surface and surrounding bone, along with extensive soft tissue damage[1]. Patients with fractured articular surface and lateral column defect are generally difficult to treat. In this report, a large iliac bone was used to reconstruct the proximal lateral column of the tibia in a staged treatment of the complex tibial plateau fracture with extensive soft tissue damage. In this retrospective study, 18 patients receiving such surgery, with excellent results, were studied. A staged treatment represents a two pronged approach: first comes the management of soft tissue (0-16 days after injury) and the second is the operation to fix the fracture (16-21 days after injury). Out of the 18 cases mentioned in this report, 10 were males and 8 were females with an age range of 22-65 years old (average of 43.06 years old), average body mass index of 24.5 kg/m2; 3 cases of poor medial soft tissue, 2 cases of poor lateral soft tissue, and 10 cases of simultaneously poor medial and lateral soft tissue. According to the Tscherne classification of soft tissue injury[2], there were 13 cases of type C2 and 5 cases of type C3 among the 18 patients. During the management of soft tissue period, 4 cases underwent calcaneal traction and 14 cases underwent external fixation. The fractures, on the other hand, were classified according to three separate classifications. The AO/OTA classification identified all fractures as C3 injuries[3]. Alternately, the Schatzker classification[4] assigned 4 cases as Schatzker type V injuries and 14 cases as Schatzker type VI injuries. Lastly, the three-column tibial plateau classification categorized all fractures as three-column

fractures.[5] The time from injury to operation in all fracture patients was between 14-21 days with an average of 16.78 days post injury. The preoperative classifications were performed by a radiologist and two orthopedic physicians based on X-rays, preoperative CT[6], and the visual soft tissue conditions. All patient statistics are summarized in Table 1.

Table 1
Descriptive statistics of patients.

Patient	Gender	Age /years old	Body Mass Index, Kg/m^2	Injury mechanism	Left/Right knee	Time from injury to surgery/day	Soft tissue damage control method	Presence of compartment syndrome	Tscheme closed soft tissue injury classification
1	male	52	21	car accident	left	16	External fixator	no	C2
2	female	50	26	car accident	left	16	External fixator	yes	C3
3	male	35	24	car accident	left	21	Calcaneal traction	yes	C3
4	male	60	30	car accident	right	20	Calcaneal traction	no	C2
5	female	22	32	fall	right	14	External fixator	no	C2
6	male	55	30	car accident	right	16	External fixator	yes	C3
7	female	30	22	extrusion	left	18	External fixator	no	C2
8	male	38	21	car accident	right	17	External fixator	no	C2
9	female	44	25	car accident	left	18	External fixator	no	C2
10	male	43	24	car accident	right	15	External fixator	no	C2
11	female	50	20	extrusion	right	20	External fixator	no	C2
12	male	27	22	car accident	right	16	External fixator	no	C2
13	male	65	24	car accident	left	14	Calcaneal traction	no	C2
14	male	28	25	car accident	left	15	External fixator	yes	C3
15	male	38	19	car accident	left	15	External fixator	no	C2
16	female	32	30	car accident	right	17	Calcaneal traction	no	C2
17	female	61	19	car accident	right	20	External fixator	no	C2
18	male	45	27	extrusion	right	14	External fixator	yes	C3

2. Methods

2.1 Pre-operation

Upon admission, all patients completed relevant examinations, had their affected limbs raised, and underwent dehydration treatment to prevent deep vein thrombosis. External fixation or traction of the calcaneal tuberosity was performed to stabilize the fracture. This allowed for soft tissue recovery by restoring fracture length and alignment. Emergency incision and decompression was instantly performed in order to prevent compartment syndrome[7], and the cross-articular external fixation was placed with the nail channel as far away as possible from the position of the second surgical incision[8]. The resulting

wound was sutured one week after the incision decompression. The internal fixation was performed within 16 days post injury after the skin swelling had subsided. In all patients, blisters appeared 24 hours after the injury, and reached a peak at 7 days after the injury. The blisters were continuously washed with a Revnauer-infused gauze, and larger blisters were suctioned with a sterile syringe. Among the 18 patients examined in this study, 5 were treated with emergency incision decompression.

2.2 Intraoperation

Either epidural anesthesia or general anesthesia was applied before the surgery. The affected limb was tied with a tourniquet. To begin the operation, a combined medial and lateral double incision was performed[9-11]. The lateral incision was initiated from the upper edge of the lateral tibial condyle and extended inwardly and downwardly to below the tibial tubercle[12]. This incision was about 15 cm long. Next, an arcuate incision was performed on the inner and posterior edge of the knee extending about 10 cm long. Care was taken to maintain a skin bridge width >8 cm between the two incisions[13]. Subsequently, the skin was cut sequentially beginning with the subcutaneous layer and continuing with the deep fascia, and the fracture ends were exposed through double incisions. The medial incision was used to fix the inner posterior and medial columns[14], and the lateral incision was used to fix the lateral columns.The surgical sequence was to first reset the posterior medial and medial cortical bone before resetting the lateral region[15]. To that end, the collapsed cortical bone was opened and lifted. Quantitative measurement of bone defects using a Kirschner wire .A horizontal cut was introduced to the collapsed articular surface at 1.0 cm below the cartilage with a wide osteotomy until it was flat and leveled with the contralateral articular surface. Next, the iliac bone measuring 3X2X1 cm was fixed to the contralateral side of the affected limb[16]. This was followed by horizontally inserting a large medial plate of the iliac bone facing the joint upward to lift the articular surface, which is equivalent to reconstructing the subchondral cortical bone of the tibial plateau.The lateral plate of the iliac bone was then removed, and the exposed cancellous bone was molded into a bone strip to tightly fill the condyle. Following this, the iliac bone column was used to vertically support the condyle, thereby reconstructing the lateral column. Cancellous bone was again used to compactly pack the surrounding space. Special attention was given to the double incisions linkage during the reduction, and the point-type reduction forceps was used to fix the medial column and lateral column as a whole. Additionally, the width of the platform was maintained as close as possible to the anatomy. On occasion when resetting was difficult, the area was examined for broken bones or meniscus jams. The posterior medial side was fixed and supported with a 3.5 system limited contact pressure steel plate[17] and a T-shaped steel plate. Alternately, the lateral side was fixed with an L-shaped locking steel plate. In case of cruciate ligament avulsion fractures, one-stage steel wire fixation was performed simultaneously. In order to prevent severe lateral column crushing, either a large amount of iliac or Kirschner needles resembling bamboo raft-like fixed support was used for firm fixation. All patients discussed in this study received autologous iliac bone grafts instead of allogeneic bone or artificial bone.

Injury to the medial and lateral collateral ligaments were treated in stages, however, the meniscus rupture was repaired by in-situ suture instantly. Tibial plateau fractures, being intra-articular fractures, were

anatomical reduced as much as possible during the operation. X-rays were taken during the operation next to a standard, with special attention given to maintaining articular surface flatness and height recovery. This study was aware that non-standard fluoroscopy can easily cause the illusion of a good reduction. Therefore, post fixation, the knee joint lateral stress test was performed to evaluate the stability of the joint before the wound was washed and drained using the internal and external incisions, the joint capsule was repaired, and the wound was closed. The operation, on average, was completed within 90 minutes of the tourniquet placement. The intraoperative surgical fixation parameters are shown in Table 2 (above), and images from a typical case (case 2) are presented in Figure 1 and Figure 2. (below).

Table 2
Fracture classification and management of patients

Patient	Inside steel plate	Outside steel plate	Autogenous iliacbone grafting	Meniscus suture	Kirschner wire indwelling	Schatzker type	Damage to collateral ligaments	Reconstruction of medial column/lateral column
1	2	1	yes	yes	no	VI	yes	lateral
2	2	1	yes	no	yes	VI	no	lateral
3	2	1	yes	yes	no	VI	no	lateral
4	2	1	yes	yes	no	VI	yes	lateral + medial
5	2	1	yes	no	yes	V	no	lateral
6	2	1	yes	yes	no	VI	no	lateral
7	2	1	yes	no	no	VI	yes	lateral
8	2	1	yes	yes	yes	VI	no	lateral
9	2	1	yes	yes	no	VI	no	lateral
10	2	1	yes	no	no	VI	yes	lateral
11	2	1	yes	no	no	V	yes	lateral
12	2	1	yes	yes	no	V	yes	lateral
13	2	1	yes	no	no	VI	no	lateral
14	2	1	yes	no	no	VI	no	lateral
15	2	1	yes	yes	no	VI	yes	lateral
16	2	1	yes	no	yes	V	yes	lateral
17	2	1	yes	no	no	VI	no	lateral
18	2	1	yes	no	no	VI	yes	lateral

Table 3
Patient recovery and complications

Patient	Follow-up time/months	Bone healing	HSS scores	Mobility (flexion and extension)	Quadriceps atrophy	Traumatic arthritis	Infection	Skin necrosis
1	40	yes	94	130°-0°	no	no	no	no
2	40	yes	90	126°-0°	no	yes	no	no
3	33	yes	98	135°-0°	no	no	no	no
4	26	yes	95	135°-0°	no	no	no	no
5	18	yes	81	120°-0°	no	no	no	no
6	19	yes	88	124°-0°	yes	no	no	no
7	27	yes	86	125°-0°	no	no	no	no
8	30	yes	85	125°-0°	no	no	no	no
9	36	yes	88	125°-0°	no	no	no	no
10	8	yes	91	126°-0°	no	no	no	no
11	21	yes	68	90°-0°	yes	no	no	no
12	44	yes	90	126°-0°	no	no	no	no
13	16	yes	83	123°-0°	yes	no	no	no
14	14	yes	90	126°-0°	no	no	no	no
15	14	yes	87	125°-0°	no	no	no	no
16	13	yes	70	93°-0°	no	yes	no	no
17	12	yes	85	125°-0°	no	no	no	no
18	11	yes	92	130°-0°	no	no	no	no

2.3 Postoperative

Antibiotic cefuroxime was routinely provided after the operation, 2 g/time, 2 times/day, NSAID Sanalgesics was administered intravenously, low-molecular-weight heparin calcium was applied for anticoagulation treatment continuously for 3 weeks post surgery, and the wound dressing was changed aseptically once every 3 days depending on exudation. On the second day after the operation, the patients were encouraged to perform ankle pump and quadriceps exercises along with knee flexion and extension exercises, under the guidance of an attending doctor. The range of active flexion and extension was 100°-0°.The stitches were removed 2 weeks after the surgery. The patients walked with crutches without weight on the affected leg within 6 weeks, and were gradually able to place weight on the affected leg after 3 months. The postoperative follow-up time was between 8-40 months, with an average time of 23.44 months. The average HSS knee score[18] was 86.72. All patients achieved complete bone healing, as evidenced by X-ray, 6 months after surgery. This study had 2 cases of traumatic osteoarthritis and 3 cases of quadriceps atrophy. The postoperative score and bone healing judgment were completed in cohort by 2 rehabilitation physicians and 1 orthopedic physician.

3. Results

All 18 patients were followed up over the course of 8-40 months, with an average of 23.44 months. All patients reported zero postoperative infection, skin and soft tissue necrosis, and loosening/breakage of the internal fixation. Regular postoperative review revealed that all patients achieved complete bony union, as evidenced by X-ray film, at 6 months after operation. Knee function (HSS) scores averaged

86.72 points at 1 year after operation; 15 people with 85 points or more, 2 people with 70-84 points, and one with 68 points. The excellent rate, according to HSS was 90%.

4. Discussion

Tibial plateau fractures resulting from high-energy injuries require a careful and extensive preoperative examination. In fact, Barei et al. reported discrepancies between CT plain scan and X-ray diagnosis[19]. Based on our report, a CT scan is essential after traction external fixation placement. It allows for a comprehensive understanding of the fracture morphology, degree of comminution, and displacement, therefore, making it critical for determining the surgical approach. A two pronged or staged approach is necessary due the extensive soft tissue damage caused by tibial plateau high-energy injuries. In the first-stage of treatment, the calcaneal traction or trans-articular external fixator placement can be applied to reduce the patient's pain and alleviate further vascular and nerve injury, thereby facilitating soft tissue management. In the second stage, internal fixation can be performed to treat the damaged bone. Skin abrasions and multiple blisters that follow high energy injuries peak around 7 days post injury and take about 16 days to heal. It is imperative that the reconstruction surgery occurs within 3 weeks of injury to avoid resetting complications.

Tibial plateau fractures with severe soft tissue damage are commonly categorized in the classification Schatzker V and Schatzker VI. Out of the 18 cases examined in this study, 14 were classified as Schatzker VI. Internal double-plate fixation enhances fracture stability. Meanwhile, the use of autologous iliac bone to reconstruct the lateral column provides a good guarantee for stability and anatomical reduction. Unlike allograft usage, autologous iliac bone grafting does not induce an immune rejection. Therefore, the tibial platform can be reconstructed safely with autologous free iliac bone. Our investigation has revealed that the iliac bone block can not only support the articular surface, but also reduce stress. After the completion of the iliac bone transplantation, the locking screw can be used to fix the iliac bone, the remaining tibial platform, and the internal fixation together to fully ensure the stability of the tibial plateau after reconstruction. Fortunately, the structure of the autogenous ilium is similar to that of the tibial plateau. The arc-shaped depression of the inner plate of the iliac bone is similar to the shape of the tibial condyle; the arc structure and bone quality of the iliac crest is similar to the edge of the tibial plateau; and the migration structure of the iliac crest to the inner plate of the ilium is similar to that of the tibial plateau edge to the tibial plateau. Therefore, the correspondence of these series of organizational structures fully coincides with the anatomical needs of the iliac reconstruction of the tibial plateau. Furthermore, the autologous large iliac bone can easily be used for height adjustment and metaphysic fixation during the operation, thereby playing a crucial role in restoring force line and maintaining stability.

Since tibial plateau fracture is an intra-articular fracture, it is essential to perform anatomical reduction of the articular surface to reduce incidences of traumatic arthritis post surgery. Multiple studies have demonstrated that the pressure distribution in the knee joint changes significantly upon a >1.5 mm collapse of the articular surface, and the local pressure increases significantly when the articular surface collapse reaches >3 mm[20]. In either of these cases, the joint varus becomes deformed and leads to

instability of the knee joint[21]. Yet another group of studies have established that the accurate reduction and strong fixation of articular cartilage can assist in the healing of the cartilage in the form of hyaline cartilage. Based on our results and that of others, the reconstruction of the tibial plateau with the iliac bone graft can successfully reduce the articular surface and the collapsed bone, and early functional exercises can be achieved with strong internal fixation. Finally, quadriceps atrophy and traumatic knee arthritis can also be reduced, periarticular tissue adhesion can be prevented, and knee function can be restored to the maximum extent using such an approach.

In summary, a complex tibial plateau fracture with extensive soft tissue damage can be successfully remedied using a staged treatment. The lateral column reconstruction using a large iliac bone can restore the lower limb force line, ensure smooth articular surface, restore platform width, and assist in the locking plate fixation.

We acknowledge that this study had some limitations; including Tscherne soft tissue classification limitations[22], small number of cases, non-diverse age population, and a short follow-up.

Abbreviations

HSS Hospital for special surgery; CT Computed Tomography

Declarations

Acknowledgements

None

Funding

None

Availability of data and materials

The datasets used and/or analysed during the current study are available from the corresponding author on reasonable request.

Declarations

Ethics approval and consent to participate. Not applicable.

Consent for publication

Written informed consent was obtained from the patient’s parent for publication of this Case report and any accompanying images.

Competing interests

The authors declare that they have no financial or other conflicts or interest in relation to this research and its publication.

References

1. Papagelopoulos P, Partsinevelos A, Themistocleous G, et al. Complications after tibia plateau fracture surgery. Injury. 2006;37:475. https://doi.org/10.1016/j.injury.2005.06.035.
2. Ibrahim DA, Swenson A, Sassoon A, et al. Classifications In Brief: The Tscherne Classification of Soft Tissue Injury. Clin Orthop Relat Res. 2017;475:560-4. https://doi.org/10.1007/s11999-016-4980-3.
3. Beebe M, Auston D, Quade J, et al. OTA Classification is Highly Predictive of Acute Compartment Syndrome Following Tibia Fracture: A Cohort of 2885 Fractures. J Orthop Trauma. 2017;31. https://doi.org/10.1097/BOT.0000000000000918.
4. Schatzker J, McBroom R, Bruce D. The tibial plateau fracture. The Toronto experience 1968-1975. Clin Orthop Relat Res. 1977;138:94. https://doi.org/doi:http://dx.doi.org/.
5. Tarng Y, Lin K. A Combined Prone and Supine Approaches for Complex Three Column Tibial Plateau Fracture with Posterolateral Articular Injury. Injury. 2019;50. https://doi.org/10.1016/j.injury.2019.09.008.
6. Van den Berg J, Struelens B, Nijs S, et al. Value of three-dimensional computed tomography reconstruction in the treatment of posterior tibial plateau fractures. Knee. 2020;27:3-8. https://doi.org/10.1016/j.knee.2019.11.001.
7. Singh K, Bible J, Mir H. Single and Dual-Incision Fasciotomy of the Lower Leg. JBJS Essent Surg Tech. 2015;5:e25. https://doi.org/10.2106/JBJS.ST.O.00007.
8. Hayek K, Parikh H, McCreary D, et al. Cost Variation in Temporizing External Fixation of Tibial Plateau Fractures. J Orthop Trauma. 2019;33 Suppl 7:S5. https://doi.org/10.1097/BOT.0000000000001620.
9. Georgiadis G. Combined anterior and posterior approaches for complex tibial plateau fractures. J Bone Joint Surg Br. 1994;76:285. https://doi.org/10.1302/0301-620X.76B2.8113294.
10. Ricci W, Rudzki JR, Borrelli J. Treatment of Complex Proximal Tibia Fractures With the Less Invasive Skeletal Stabilization System. J Orthop Trauma. 2004;18:521. https://doi.org/10.1097/00005131-200409000-00007.
11. He X, Ye P, Hu Y, et al. A posterior inverted L-shaped approach for the treatment of posterior bicondylar tibial plateau fractures. Arch Orthop Trauma Surg. 2012;133. https://doi.org/10.1007/s00402-012-1632-2.
12. Honkonen S. Indications for Surgical Treatment of Tibial Condyle Fractures. Clin Orthop Relat Res. 1994;302:199. https://doi.org/10.1097/00003086-199405000-00031.
13. Haertsch PA. The blood supply to the skin of the leg: a post-mortem investigation. Br J Plast Surg. 1981;34:470. https://doi.org/10.1016/0007-1226(81)90061-8.

14. Acklin Y, Potocnik P, Sommer C. Extended medial approach in posteromedial proximal tibia fracture dislocation. Oper Orthop Traumatol. 2014;27. https://doi.org/10.1007/s00064-014-0306-3.
15. Ryu SM, Choi CH, Yang HS, et al. Causes and treatment outcomes of revision surgery after open reduction and internal fixation of tibial plateau fractures. Int Orthop. 2019;43:1685-94. https://doi.org/10.1007/s00264-018-4080-y.
16. Huang Y, Chen C, Lin K, et al. Comparing morbidities of bone graft harvesting from the anterior iliac crest and proximal tibia: A retrospective study. J Orthop Surg Res. 2018;13. https://doi.org/10.1186/s13018-018-0820-3.
17. Lee JK, Choi WR, Lee JH, et al. Outcome of 3.5-mm Anatomical Locking Plates for the Treatment of Proximal Tibia Fractures Involving the Meta-Diaphyseal Junction. Orthopedics. 2018;41:e777-777e782. https://doi.org/10.3928/01477447-20180912-01.
18. Shen QJ, Zhang JL, Xing GS, et al. Surgical Treatment of Lateral Tibial Plateau Fractures Involving the Posterolateral Column. Orthop Surg. 2019;11:1029-38. https://doi.org/10.1111/os.12544.
19. Barei D, O'Mara T, Taitsman L, et al. Frequency and Fracture Morphology of the Posteromedial Fragment in Bicondylar Tibial Plateau Fracture Patterns. J Orthop Trauma. 2008;22:176. https://doi.org/10.1097/BOT.0b013e318169ef08.
20. Brown T, Anderson D, Nepola J, et al. Contact stress aberrations following imprecise reduction of simple tibial plateau fractures. J Orthop Res. 1988;6:851. https://doi.org/10.1002/jor.1100060609.
21. Assar S, Gandomi F, Mozafari M, et al. The effect of Total resistance exercise vs. aquatic training on self-reported knee instability, pain, and stiffness in women with knee osteoarthritis: a randomized controlled trial. BMC Sports Science, Medicine and Rehabilitation. 2020;12. https://doi.org/10.1186/s13102-020-00175-y.
22. Ovaska MT, Mäkinen TJ, Madanat R, et al. Risk factors for deep surgical site infection following operative treatment of ankle fractures. J Bone Joint Surg Am. 2013;95:348-53. https://doi.org/10.2106/JBJS.K.01672.

Figures

Figure 1

Case 2: A. Frontal X-ray of the knee joint before operation. B. CT after external fixator placement. C. A reduced-tension incision. D. Iliac bone extracted during the operation. E. A cavity caused by the collapsed lateral platform during the operation. F. Reconstruction of the lateral column by the iliac bone. G. Functional overview 1 year after the operation. H. Intraoperative fluoroscopy showing proper alignment and fixation. I. Frontal and lateral X-rays 1 year after the operation revealing a successful surgery.

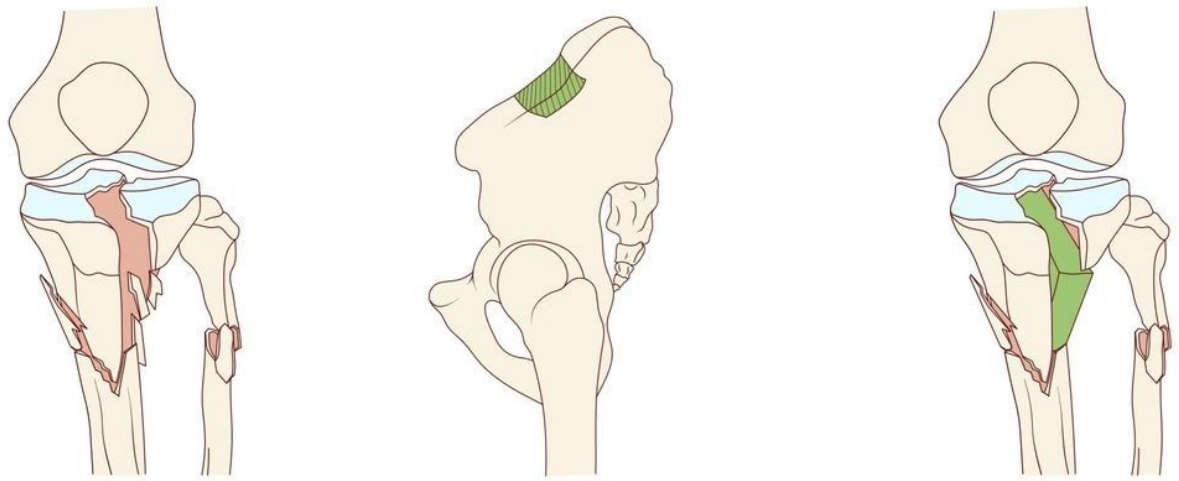

Figure 2

Schematic diagram of steps for reconstruction of lateral column with autogenous iliac bone