Clinical Study To Evaluate The Outcome Of Primary AGV Implantation In Angle Recession Glaucoma Following Blunt Ocular Trauma In Indian Eyes

Jaya Kaushik
Armed Forces Medical College
Jitendra Kumar Singh Parihar
Army Hospital Research and Referral
Ankita Singh
Armed Forces Medical College https://orcid.org/0000-0002-8136-6375
VYK Chaitanya
Armed Forces Medical College
Rakesh Shetty (dr.rakeshshetty7@gmail.com)
Armed Forces Medical College https://orcid.org/0000-0003-3338-5771
Vaibhav Kumar Jain
Sanjay Gandhi Post Graduate Institute of Medical Sciences
Vijay Mathur
Military Hospital Ambala
Aanchal Singhal
Armed Forces Medical College

Research Article

Keywords: Angle recession, Blunt trauma, Refractory Glaucoma, Hyphema, Ahmed Glaucoma Valve

Posted Date: April 5th, 2021

DOI: https://doi.org/10.21203/rs.3.rs-347699/v1

Abstract

Purpose—To Highlight The Efficacy Of Primary AGV Implantation In Angle Recession Glaucoma Following Blunt Ocular Trauma In Indian Eyes.

Design- A retrospective analytical study

Materials & Methods— This study included 52 patients of angle recession glaucoma, who presented between Mar 2006 to Feb 2016, out of which 38 patients had undergone primary AGV implantation while the rest were managed with topical anti-glaucoma medications. Preoperative data included age, sex, type & mode of injury, duration of injury, assessment of BCVA and IOP. Extent of angle recession was observed by gonioscopy. The intraocular pressure, visual acuity and number of anti-glaucoma medications were measured postoperatively. The success of this technique was analyzed by using a Kaplan-Meier cumulative survival curve.

Results—Following AGV implantation the mean IOP was significantly reduced to 8.7±2.2 at 1st day, 10.1±2.2 at 7th day, 14.2±3.4 at 3rd month, 15.6±3.7 at 1 year and 15.6±3.6 at 3rd year follow-up showing statistically significant values ($p<0.001$) at each visit. The IOP was successfully controlled at last follow up without topical treatment. Mean BCVA at 3 year post AGV was 0.41±1.5 (logMAR) which was statistically significant ($p<0.001$).The success rate by Kaplan- Meier survival curve analysis was 90% at the mean follow up duration of 29.47±3.39 months. Overall surgical complications were noted in the form of prolonged hypotony, hyphema in 7 patients (13.5%).

Conclusions—In medically uncontrolled post-traumatic angle recession glaucoma Primary AGV Implantation is a safe and effective surgical procedure with lesser complication rates providing long term IOP control in younger population .

Introduction

Ocular blunt trauma, is one of the leading causes of ocular morbidity across the globe. It can potentially be, a sight threatening condition, depending upon the enormity and magnitude of the impact leading to monocular blindness[1]. It encompasses all the closed globe injuries resulting in the ocular damage due to the force of the energy delivered as a result of trauma[2] Ocular trauma, can occur in any setting; the most common being the sports and domestic injuries, which account for nearly 65-70% of these injuries[3] . Traumatic glaucoma, consists of a multitude of ocular abnormalities following trauma, owing to various mechanisms, culminating in a common pathway of abnormally raised intraocular pressure (IOP) with associated risk of optic neuropathy[4]. It is a form of secondary glaucoma, occurring in nearly 5-10% of the injured eyes.[5,6] . It can occur instantly after sustaining the injury or after a few years or decades later.

Angle recession glaucoma, is a type of traumatic secondary open angle glaucoma; defined pathologically, as a separation between the circular and longitudinal fibres of the ciliary body muscles.

Studies have shown, that the presence of post-traumatic hyphema is associated with almost 70-100% incidence of angle recession[7–9]. The management of angle recession glaucoma, often poses a multifactorial challenge as medical therapy is often ineffective and such cases frequently require either filtering surgery or glaucoma drainage devices[10]. The introduction of valved glaucoma drainage devices, with improved safety profile, have enabed them to be employed as the primary modality of treatment for this refractory form of glaucoma. [11,12]

The aim of this study, is to evaluate the efficacy of Ahmed Glaucoma Valve (AGV), as a primary surgical intervention, in cases of angle-recession glaucoma secondary to blunt ocular trauma in Indian patients.

Materials And Methods

This retrospective, analytical study included 52 consecutive patients of angle recession glaucoma, who had presented to this tertiary hospital, between Mar 2006 to Feb 2016 with uncontrolled intraocular pressure, following blunt trauma, owing to different etiologies. The study adhered to the tenets of the Declaration of Helsinki and was approved by institutional review board of Army Hospital (Research & Referral). Of the 52 patients with traumatic glaucoma, 38 patients had undergone primary AGV (FP7) implantation by a single surgeon (J.K.S.P.) while the rest were controlled successfully with topical anti-glaucoma drugs . Preoperative data included age, sex, type & mode of injury, duration of injury to first contact by an ophthalmologist, assessment of visual acuity using Snellen's chart and converted to LogMAR units, intraocular pressure recorded by Goldmann applanation tonometer(GAT) and extent of angle recession, assessed by gonioscopy, after a quiescent period. Slit lamp examination was done to assess the severity and impact of ocular trauma. Clinical photographs were taken using anterior segment imaging system, on every visit. The number of anti-glaucoma drugs, used before and after the surgery, was taken into consideration. The duration of medical management to timing of AGV implantation was also studied. Data of post operative follow up done at regular intervals upto 3 years and serial IOP was included in the study.

Inclusion & Exclusion Criteria

The patients included in this study ranged between 18 to 42 years of age. Inclusion criteria was patients, examined between March 2006 to Feb 2016, having traumatic angle recession with uncontrolled IOP despite being on maximum anti-glaucoma medication and no lens abnormalities, cyclodialysis or synechiae. The patients who had a history of previous intraocular surgery, corneal decompensation due to any etiology or having no perception of light, were excluded from this study.

Surgical Technique

All the surgeries were performed by a single surgeon (JKSP) under peribulbar anaesthesia. Conjunctival peritomy and forniceal based flap was raised supero-temporally. A subtenon's pocket was created extending upto the equator and a 4 X 4 mm scleral tunnel was prepared by a 2.5 mm crescent blade. After priming the valve with balanced salt solution using a 30-gauze cannula, the valve plate was anchored to

sclera by 7-0 nylon sutures, 8 mm away from the limbus. The edge of the tube, was trimmed obliquely with bevel facing upward to ensure intraocular intrusion of about 2 mm. The entry into the anterior chamber was made with a 23-G needle. Tunnel was sealed by 8-0 vicryl sutures. The technique was modified by the surgeon by applying 3 compression sutures over the silicon tube, at different places, with 8-0 vicryl sutures, to minimize the possibility of extensive hypotony and choroidal effusion postoperatively. After conjunctival repositioning, sub-conjunctival antibiotics and corticosteroids were injected away from the surgical site. To prevent postoperative hypotony with shallow anterior chamber, injection sodium hyaluronate 1.4% was injected into the anterior chamber.

All patients were evaluated on the first postoperative day, 1 week, 1 month, every 3 monthly for 1 year and thereafter 6 monthly, for 3 years. A strict postoperative protocol was followed, comprising of topical Moxifloxacin plus 0.1% Dexamethasone for 06 weeks in tapering dosages. Anti-glaucoma medications, were given during the phase of raised intra ocular pressure and subsequently if required. Eye drop Atropine Sulphate 1% was prescribed to the patients for 2 weeks. At each visit patients underwent best corrected visual acuity (BCVA) evaluation, slit lamp examination to assess the corneal clarity, anterior chamber depth, bleb appearance. Anterior segment photographs were taken at every visit and IOP was measured by GAT to monitor the improvement. Fundus examination, was performed to see glaucomatous changes and macular involvement subsequent to trauma. USG B scan, OCT for RFNL & macula and ultrasound biomicroscopy for examining angle structures were performed, if indicated. Complications if any were also noted. The preoperative and post operative slit lamp pictures of the angle recession glaucoma, managed successfully with AGV implantation, are as shown in **Fig1**.

Outcome Measures

The criteria for successful outcome were assigned as (1) Absolute Success if IOP < 21 or > 8 mm Hg without anti-glaucoma medications during the period of follow up, stable visual acuity and stable visual field (2) Qualified Success if IOP <21 mm Hg with <2 anti-glaucoma medications after 1 year with stable visual acuity and fields without the need for additional glaucoma surgery. Also, visual outcome was assessed as quantitative improvement of BCVA postoperatively upto 6/12 on Snellens chart (0.3 logMar). The qualitative improvement of BCVA by 2 lines from preoperative vision, was considered as successful outcome. Patients were assessed for intraoperative and postoperative complications. Failure was defined as IOP< 8 or>21 mm Hg, with the requirement of 4 antiglaucoma medications, progressive field changes and poor visual acuity or additional glaucoma surgery.

Statistical Analysis

Data analysis was performed by using SPSS (Statistical Package for social sciences) Version 20:0. Qualitative data variables have been expressed by using Frequency and Percentage (%). Quantitative data variables have been expressed by using Mean and SD. Paired t-test was used to compare the mean IOP and BCVA (logMar) prior and after treatment with follow up till 3 years. Kaplan Meier Survival Analysis has been used to find the success with respect to mode of the injury and occurrence of

complications. Log rank test used to compare the success rate within mode of Injury and occurrence of Complications. The p-value of< 0.05 was considered as statistically significant.

Results

52 eyes of 52 patients, diagnosed as post traumatic angle recession glaucoma, were enlisted in the study, of which, 38 patients had undergone primary AGV implantation at this tertiary referral hospital from Mar 2006 till Feb 2016. The demographic profiles, visual acuity, etiology of trauma, laterality of the eye involved and ocular findings at the time of presentation are summarised in **Table 1**. In the study population there were 36 males (69.2%) and 16 females (30.8%). A total of 23 males (63.88%) and 5 (31.25%) females, had sustained sports trauma, 10(27.77%) males and 5 (31.25%) females had met with RTA whereas 3 (8.33%) males and 6 (37.5&) females had domestic injuries. In our study, the kind of sport associated with angle recession were racket games in 7 eyes (13.5 %), basketball or cricketball 7 eyes(13.5 %), fire crackers injury 5 eyes(14.9 %), golf 2 eyes (4.8%), gulli danda 3 eyes (5.8%) and boxing related injury in 1 eye (1.9%), thus making a total of 28 patients (53.8%), have various sports related blunt ocular trauma. There were 3 cases of injury following Indian sports Gulli and Danda. Mean age of patients at the time of presentation was 27.60±7.12 years. 25 patients (48.1%) belong to age group ranging between 21 to 30 years. The mean duration of the first contact with an ophthalmologist after injury was 1.23 day whereas mean duration of reporting to a tertiary eye centre following trauma was 5.75 ± 2.69 day. At the time of presentation, 38 eyes (73%) had hyphema on slit lamp examination. The hyphema was predominantly seen in 20 eyes (52.6%) subsequent to sports injuries followed by 12 eyes (31.57%) with history of RTA and 6 eyes (15.78%) who sustained domestic accidents. The period of absorption was less than 7 days in 21 eyes (55.3%) and 7 to 14 days in 17 eyes (44.7%). The mean degree of angle recession at the time of presentation was 139.04 ±57.76 degree (range 45 to 360 degree). The most common site of angle recession was superior in 32 eyes (61.5%) followed by temporal in 10 eyes(19.2%), inferior in 8 eyes (15.4%) and nasal in 2 eyes (3.8%).)(**Fig 2**). The most common site of angle affected by various mode of injury has been depicted in **Fig 3.** The extent of angle recession on gonioscopy was 180 degree in 18 eyes (34.6%), 120 degree in 18 eyes(25.0%%), 90 degree in 7 eyes (13.5%), 210 degree in 6 eyes (11.5%), 270 degree in 1 eye (1.9%) and 360 degree in 3 eyes (5.8%). The extent of angle recession in comparison to mode of injury has been depicted in **Fig 4 .**

Traumatic mydriasis, was seen in 38 eyes (83.8%) while iridodialysis was observed in 5 eyes (9.6%). The grade of uveitis as per SUN Classification was 2+ cells in 30 eyes (57.7%), 3+ cells in 19 eyes (36.5%) and 1+ in 3 eyes (5.8%). Out of 52 patients, 11 patients (21.2%) were managed medically with topical anti-glaucoma medications, 3 (5.8%) required no treatment and were kept under observation and 38 patients (73.1%) underwent primary AGV implantation after being on maximal anti-glaucoma medication for a mean period of 6 months. The mean IOP at the first presentation was 39.94±6.64 (range 30-50) mm Hg by GAT. The mean IOP after maximum topical anti-glaucoma medications was 32.7±6.1 (range 10-46)mm Hg on GAT. The mean IOP on maximum topical and systemic anti-glaucoma medications was 24.13±6.5 mm Hg (p<0.001). Following AGV implantation the mean IOP was significantly reduced to

8.7±2.2 at 1st day, 10.1±2.2 at 7th day, 14.2±3.4 at 3rd month, 15.6±3.7 at 1 year and 15.6 ± 3.6 at 3rd year follow-up showing statistically significant values (p <0.001) at each visit. (**Fig 5**). The mean duration from initial presentation to surgical intervention was 6.24±6.7 months (range 90 to 360 days). The mean duration of follow up was 29.47 ± 3.39 months. The visual acuity improved upto 6/6 on Snellen's chart (0.0 logMAR) in 14 out of 52 patients with medical treatment. In the remaining 38 eyes following AGV implantation, the mean BCVA was recorded as 0.99 ± 0.19 on 1st day and 0.90±0.20 on 7th day due to irregular astigmatism and myopic shift. Mean BCVA observed at 1st month was 0.45±0.17, at 3rd month was 0.138±0.14 and after 1 year 0.142±0.15 which shows a gradual improvement. Mean BCVA at last follow up post AGV was 0.41±1.5 which was statistically significant (p<0.001). In 8 patients, the vision gradually deteriorated over a period of follow up due to development of progressive glaucomatous changes in 2 eyes, traumatic cataract in 3 eyes, lamellar macular hole in 2 eyes and epi-retinal membrane formation in one eye. On post-op Visual field analysis, progressive glaucomatous field changes were seen in 6-7% of cases despite adequate IOP control.

A statistically significant reduction in the mean number of anti-glaucoma medications used was also observed (3.94±0.26 to 1.5±0.45, P=0.015) after primary AGV implantation in 38/52 patients at 1st year and from 3.94±0.26 to 1.20±0.25 at 3rd year follow-up. Three (7.9%) out of 38 patients were considered as surgical failures who were refractory to treatment and presented with visual field changes inspite of 4 anti-glaucoma medications being used following surgery. The success rate by Kaplan- Meier survival curve analysis was 90% at the mean follow up duration of 29.47±3.39 months. Overall surgical complications were noted in 7 patients (13.5%). 4 (7.7%) eyes experienced prolonged hypotony with shallow anterior chamber in early post operative period. The AC reformation was performed by injecting sodium hyaluronate intracamerally following which hypotony resolved within 2 weeks of appearance. Prolonged hypertony phase was recorded in 6 (15.78%) eyes during first 3 months of surgery. However, it spontaneously resolved in 2 patients. The remaining 4 patients were managed with antiglaucoma medications. Hyphema was seen in 6 (15.78%) eyes in early post-operative period which resolved spontaneously with medication. 2 (3.8%) eyes had choroidal detachment which was treated conservatively with systemic steroids and cycloplegics. No other known complication of AGV implantation like excessive capsular fibrosis, restrictive strabismus, tube erosion or infection was noted in any of the operated patients during the post -operative follow up period.

Table 1: Demographic Profile of the Patients	
Total no. of the patients	52
No. of males	36 (69.2%)
No of females	16 (30.8%)
Mean age at presentation(years)	27.60±7.12
Mode of injury	Sports (53.8%)> RTA (28.%)> Domestic (17.3%)
Laterality of eye sustaining trauma	Right eye (51.9%) > Left eye (48.1%)
Mean BCVA at presentation (logMAR)	0.898 ± 0.205
Mean IOP at presentation (mm of Hg)	42.4 ± 5.8
Site of angle recession at presentation	Superior (61.5%)>Temporal (19.2%)> Inferior (15.4%)> Nasal (3.8%)
Mean degree of angle of recession at presentation	139.04±57.76 degree (range 45 to 360 degree)
Ocular findings at presentation	Traumatic mydriasis (53.8%),Hyphema (38%), Iridodialysis (9.6%), Uveitis3+(36.5%)

Discussion

Angle recession, first described by Collins in 1892[8], from study of post-concussion enucleated eyeballs is just one, from among the myriad pathogenic mechanisms, contributing to raised IOP in the post-traumatic secondary glaucoma complex[13]. Histologically, angle recession is seen as presence of a tear between the longitudinal and circular fibers of the ciliary muscles attributable to precipitous iris root traction caused by lateral and posterior displacement of aqueous humor against the iris and angle as result of blunt trauma[3,5,9,14,15]. This may also lead to loss of tension of ciliary muscle on the scleral spur causing narrowing of the Schlemn canal. Additionally, a hyaline membrane also been proposed to grow across the trabecular meshwork leading to further decrease in aqueous outflow. On clinical examination with gonioscopy, the findings include widened ciliary body band, prominent scleral spur, and a grayish membrane encroaching the angle[13,16–18]. In most of the cases the secondary glaucoma is refractory to medical management and require surgical intervention[17]. It has been found that upto 60 % cases of ocular trauma will develop some degree of angle recession of which 5-20% cases may ultimately progress to angle recession glaucoma[18–21]. The mean duration of presentation of raised IOP may range from 1 week to many years after the initial trauma although there seems to be twin peaks in incidence of glaucoma one presenting within one year and the other presenting greater than 10 years after the initial traumatic insult[22]. Although rise in IOP in the early period 1-3 months is usually attributable to post traumatic inflammation, hyphema or lens particle associated glaucoma and usually can be managed

with medication alone, later sustained rise in IOP(> 6 months) has been attributable to trauma mediated compromise of angle structures & is refractory to medical management necessitating surgical intervention [22–24]. Various surgical modalities have been tried with mixed results; while conventional glaucoma surgeries like filtering surgeries, cyclphotodestruction are fraught with risk of potentially sight and organ threatening complication like late bleb infection[25], ocular decompression retinopathy[26] and serous retinal detachment[27]. The cyclodestructive procedures such as cyclocryotherapy has not been attempted as a primary surgical modality as it may initially decrease IOP but accompanied with increased inflammation and compromised visual outcome[28]. Modified trabeculectomy has shown limited success in angle recession glaucoma. For large angle recession (beyond 120 degree in extent) long term control of IOP was not achieved with conventional glaucoma procedure. The studies have shown that angle recession is a major risk factor for surgical failure, likely related to the younger age of patients and comorbid trauma-related eye damage. The cause of failure of trabeculectomy in young and in trauma cases has been due to recessed and distorted angle with recurrent inflammation. Failure rates of trabeculectomy are higher in angle recession compared to POAG, with 43% versus 74% success reported in one study[25]. Another study by Manners et al observed that compared with POAG the success rate of trabeculectomy is significantly lesser (74% versus 43%) with early surgical failures[29]. Ahmed glaucoma valves are gradually gaining popularity in managing refractory glaucoma due to recalcitrant uveitis with reported cumulative success rates of 92% at 2 year follow-up in post uveitis refractory glaucoma [30].

Study by Chang Kyu Lee et al observed the cumulative probability of success rate of 89% at 6 months, 81% at 1 year, 66% at 3 years, 44% at 10 years, and 26% at 15 years with AGV implantation as secondary surgical intervention after failed primary trabeculectomy[31]. The success rate for AGV implantation in post penetrating keratoplasty was 76% at 2 year follow up as observed by Parihar et al [32]. Glaucoma drainage devices, have been tried in refractory cases of angle recession glaucoma post failed trabeculectomy and laser trabeculoplasty cases and were found to have a better safety profile than other modalities[10,33,34] although data on their efficacy and safety profile as a primary intervention for proactive control of refractory rise in IOP and consequent glaucoma progression is scarce. In this study, we assessed efficacy of Ahmed Glaucoma Valve (AGV) implantation, as an initial surgical modality for treatment of refractorily raised intraocular pressure in Indian patients of angle recession glaucoma. Since Indian eyes are susceptible to early glaucomatous damage on account of smaller eyes and heavier pigmentation of trabecular meshwork, it was considered prudent that an aggressive approach be employed, hence surgical intervention was planned at relatively earlier stage with patients having history of glaucoma refractory to maximal topical medication being offered AGV implantation as early as 3 months after the initial traumatic insult.

It was observed that severity of angle recession glaucoma corresponded with degree of angle recession with persistently raised IOP being more consistently found in angle recession of more than 180 degrees. Sihota et al found out hyphema, angle recession of more than 180 degrees, displacement of lens and trabecular pigmentation to be associated with increased chances of progressing to traumatic glaucoma[22]. Clement et al reported angle recession as a major contributor for prolonged IOP

disregulation in their study with up to 100% of individuals having trauma-induced hyphema; approximately 9% developing as angle recession glaucoma[35]. In our study, hyphema was present in 73% (38/52 cases) but with varied grades. In about 80%, it was traces to grade I hyphema while 20% had grade II hyphema. Period of absorption of hyphema varied from mean of 2.25±0.95 days in trace to upto 2 week in others. 18 cases (34.6%) with 120 to 180 degree angle recession with hyphema were initially managed medically but subsequently underwent AGV implantation after 3 months of follow up when IOP became gradually uncontrolled despite on maximum medical treatment. Traumatic mydriasis was found in 73% cases (38/52 eyes) ranging from 3.5 to 6.5 mm of pupillary dilatation. 50% patient responded well and 25% continued to have mild to moderate permanent mydriasis and ectropion of pupillary sphincter.

Since most patients had a LogMAR visual acuity of less than 0.6, reliable visual field analysis could not be carried out initially although in the 81% patients with visual acuity >0.5 LogMAR didn't show any visual field abnormalities. Visual field analysis of the remaining patients on improvement of visual acuity depicted generalized visual field constriction in 2 patients especially those associated with surgical failure at 1 year. Osman et al (two cases) and Turalba et al (five cases) reported 100 % success rates in the management of traumatic glaucoma at the end of one year followup[36]. Our study was associated with 76% absolute success rate and functional success rate of 16 % giving an overall success rate of 92% at 1 year while 3 cases (7.9%) were considered as surgical failure at the end of follow up period. We report 90% success rate following primary AGV implantation by Kaplan- Meier survival curve analysis at the mean follow up duration of 29.47±3.39 months. We used Kaplan Meier Curves to analyse the success rate of surgery over the follow up duration. We found that the outcome of surgery was successful in 90% cases over a follow up period of 3 years. (**Fig 6**). There was no statistical significance between the mode of injury and the success rate of the surgery as p value is 0.085. A K-M curve has been plotted to see the correlation between the outcome of surgery with the complications encountered. Here, we see that the outcome of surgery was successful in cases who had no complications during or following the surgery and this correlation was statistically significant ($p < 0.05$). (**Fig 7**)

There were intraoperative challenges faced by the surgeon while implantation of AGV in angle recession glaucoma. Certain novel modifications were adopted by the surgeon in standard technique. Making of tunnel, three compression sutures over the tube and ideally tube placement away from angle recession site were the surgeon's novel modifications to avoid egression of fluid, to avoid intraoperative bleed, to prevent tube exposure or extrusion from anterior chamber. Also, in presence of iridodialysis of less than 45 degree and covered with upper lid margin no repair is being performed, in cases where iridodialysis involved more than one quadrant the concurrent repair was done at the time of AGV implantation. Usually improvement in visual acuity is not a goal of AGV implantation. However, we found significant improvement in mean visual acuity 0.41±1.5 at last follow up post AGV which was statistically significant ($p<0.001$). This imay have been due to absorption of hyphema, resolved uveitis and control of IOP leading to clearing of corneal oedema.

Thus , primary AGV implantation seems a viable alternative to other surgical procedures for adequate IOP control. To the best of our knowledge, this study is the largest to report the outcome of primary AGV

implantation in angle recession glaucoma following blunt trauma and no similar studies have been found in the literature to compare the results of the current study.

This study was undertaken to analyze the efficacy of Primary AGV Implantation in cases of angle recession glaucoma as a result of blunt trauma owing to various etiologies. Although, the current study has proven the successful outcome with the surgical option adopted, but still a randomized prospective study comparing the various surgical options in angle recession glaucoma would be preferred than a standalone non comparative retrospective study with a smaller sample size.

Conclusion

The surgical management of post-traumatic angle recession glaucoma is a challenging task considering the demographic profile of the patients, who are mostly young and have a recalcitrant disease course. The results of our study have significantly proven the efficacy of Primary AGV implantation in such cases with optimum control of intra ocular pressure without a further requirement of topical ANTI-GLAUCOMA MEDICATIONS. This study has also highlighted the relatively lesser complications post- surgery which are a significant cause of surgical failure and ocular morbidity when compared to other existing surgical options.

Declarations

- **Competing Interests**- The authors declare that they have no competing interests.
- **Funding Info** - No funding availed
- **Author contribution**

	Category 1			Category 2	Category 3
Author name	Conception and design of study	Data acquisition	Data analysis and/or interpretation	Drafting of manuscript and/or critical revision	Approval of final version of manuscript
Jaya Kaushik	Yes	Yes	Yes	Yes	Yes
Dr Jitendra Kumar Singh Parihar	Yes	Yes	Yes	Yes	Yes
Dr Ankita Singh	Yes	Yes	Yes	Yes	Yes
Dr Rakesh Shetty	Yes	Yes	Yes	Yes	Yes
Dr Vaibhav Kumar Jain	-	-	Yes	Yes	Yes
Dr YVK Chaitanya	-	-	Yes	Yes	Yes
Dr Vijay Mathur	-	-	Yes	Yes	Yes
Dr Aanchal Singhal	-	-	Yes	Yes	Yes

- Data Availability – The datasets used and/or analysed during the current study are available from the corresponding author on reasonable request.
- Animal Research (Ethics)- Not applicable as animals were included in this study.
- Consent to Participate (Ethics)- Informed patient consent taken. The study adhered to the tenets of the Declaration of Helsinki and was approved by institutional review board of Army Hospital (Research & Referral), Delhi.
- Consent to Publish (Ethics) : Consent for publication taken.

Financial Disclosure: None to disclose

Conflicts of Interest: Nil

References

1. Thylefors B (1992) Epidemiological patterns of ocular trauma. Aust N Z J Ophthalmol 20(2):95–98. doi:10.1111/j.1442-9071.1992.tb00718.x

2. Kuhn F, Morris R, Witherspoon CD, Heimann K, Jeffers JB, Treister G (1996) A standardized classification of ocular trauma. Ophthalmology 103(2):240–243. doi:10.1016/S0161-6420(96)30710-0
3. Canavan YM, Archer DB (1982) Anterior segment consequences of blunt ocular injury. Br J Ophthalmol 66(9):549–555. doi:10.1136/bjo.66.9.549
4. Bai HQ, Yao L, Wang DB, Jin R, Wang YX (2009) Causes and treatments of traumatic secondary glaucoma. Eur J Ophthalmol 19(2):201–206. doi:10.1177/112067210901900205
5. Stanić R, Stanić R (2001) Traumatic glaucoma. Coll Antropol 25 Suppl:101–104
6. Ashaye AO (2008) Traumatic Hyphaema: A report of 472 consecutive cases. BMC Ophthalmol 8(1):24. doi:10.1186/1471-2415-8-24
7. Girkin CA, McGwin G, Long C, Morris R, Kuhn F (2005) Glaucoma after ocular contusion: A cohort study of the United States Eye Injury Registry. J Glaucoma 14(6):470–473. doi:10.1097/01.ijg.0000185437.92803.d7
8. Blanton FM (1964) Anterior Chamber Angle Recession and Secondary Glaucoma: A Study of the Aftereffects of Traumatic Hyphemas. Arch Ophthalmol 72(1):39–43. doi:10.1001/archopht.1964.00970020041010
9. Mooney D (1973) Angle recession and secondary glaucoma. Br J Ophthalmol 57(8):608–612. doi:10.1136/bjo.57.8.608
10. Fuller JR, Bevin TH, Molteno ACB (2001) Long-term follow-up of traumatic glaucoma treated with Molteno implants. Ophthalmology 108(10):1796–1800. doi:10.1016/S0161-6420(01)00714-X
11. Parihar JKS, Vats DP, Maggon R, Mathur V, Singh A, Mishra SK. The efficacy of Ahmed glaucoma valve drainage devices in cases of adult refractory glaucoma in Indian eyes. *Indian J Ophthalmol*. 57(5):345–350. doi:10.4103/0301-4738.55068
12. Riva I, Roberti G, Katsanos A, Oddone F, Quaranta L (2017) A Review of the Ahmed Glaucoma Valve Implant and Comparison with Other Surgical Operations. Adv Ther 34(4):834–847. doi:10.1007/s12325-017-0503-1
13. Tumbocon JAJ, Latina MA (2002) Angle Recession Glaucoma. Int Ophthalmol Clin 42(3):69–78. doi:10.1097/00004397-200207000-00009
14. WOLFF SM, ZIMMERMAN LE (1962) Chronic secondary glaucoma. Associated with retrodisplacement of iris root and deepening of the anterior chamber angle secondary to contusion. Am J Ophthalmol 54:547–563
15. Herschler J (1977) Trabecular damage due to blunt anterior segment injury and its relationship to traumatic glaucoma. Trans Sect Ophthalmol Am Acad Ophthalmol Otolaryngol 83(2):239–248
16. Razeghinejad R, Lin MM, Lee D, Katz LJ, Myers JS (2020) Pathophysiology and management of glaucoma and ocular hypertension related to trauma. Surv Ophthalmol. doi:10.1016/j.survophthal.2020.02.003

17. Pilger IS, Khwarg SG (1985) Angle recession glaucoma: review and two case reports. Ann Ophthalmol 17(3):197–199
18. Salmon JF, Mermoud A, Ivey A, Swanevelder SA, Hoffman M (1994) The Detection of Post-traumatic Angle Recession by Gonioscopy in a Population-based Glaucoma Survey. Ophthalmology 101(11):1844–1850. doi:10.1016/S0161-6420(94)31091-8
19. Kaufman JH, Tolpin DW (1974) Glaucoma after traumatic angle recession. A ten year prospective study. Am J Ophthalmol 78(4):648–654. doi:10.1016/S0002-9394(14)76303-2
20. Kalamkar C, Mukherjee A (2019) Incidence, clinical profile, and short-term outcomes of post-traumatic glaucoma in pediatric eyes. doi:10.4103/ijo.IJO_655_18
21. Maity P, Kumar Bandyopadhyay S, Mukhopadhyay S, Barua N, Trainee PG, Clinical R. Incidence of angle recession after blunt trauma-A longitudinal study. *Indian J Clin Exp Ophthalmol*. 4(1):136–140. doi:10.18231/2395-1451.2018.0031
22. Sihota R, Kumar S, Gupta V et al (2008) Early predictors of traumatic glaucoma after closed globe injury: Trabecular pigmentation, widened angle recess, and higher baseline intraocular pressure. Arch Ophthalmol 126(7):921–926. doi:10.1001/archopht.126.7.921
23. Sihota R, Sood NN, Agarwal HC (1995) Traumatic glaucoma. Acta Ophthalmol Scand 73:252–254
24. Ozer PA, Yalvac IS, Satana B, Eksioglu U, Duman S (2007) Incidence and risk factors in secondary glaucomas after blunt and penetrating ocular trauma. J Glaucoma 16(8):685–690. doi:10.1097/IJG.0b013e318073bd4d
25. Mermoud A, Salmon JF, Straker C, Murray ADN (1993) Post-traumatic angle recession glaucoma: A risk factor for bleb failure after trabeculectomy. Br J Ophthalmol 77(10):631–634. doi:10.1136/bjo.77.10.631
26. Bansal A, Ramanathan U (2009) Ocular decompression retinopathy after trabeculectomy with mitomycin-C for angle recession glaucoma. Indian J Ophthalmol 57(2):153. doi:10.4103/0301-4738.45510
27. Roy AK, Padhy D (2015) Serous retinal detachment after trabeculectomy in angle recession glaucoma. GMS Ophthalmol cases 5:Doc15. doi:10.3205/oc000037
28. Mermoud A, Salmon JF, Barron A, Straker C, Murray ADN (1993) Surgical Management of Post-traumatic Angle Recession Glaucoma. Ophthalmology 100(5):634–642. doi:10.1016/S0161-6420(93)31595-2
29. Manners T, Salmon JF, Barron A, Willies C, Murray ADN (2001) Trabeculectomy with mitomycin C in the treatment of post-traumatic angle recession glaucoma. Br J Ophthalmol 85(2):159–163. doi:10.1136/bjo.85.2.159
30. Parihar JKS, Kaushik J, Jain VK, Trehan HS, Mishra A, Baranwal VK (2018) Combined Ahmed valve and phacoemulsification with intraocular lens implantation under infliximab in refractory uveitic glaucoma. Eur J Ophthalmol 28(3):294–298. doi:10.5301/ejo.5001032
31. Lee CK, Ma KT, Hong YJ, Kim CY. Long-term clinical outcomes of Ahmed valve implantation in patients with refractory glaucoma. Taylor AW, ed. *PLoS One*. 2017;12(11):e0187533.

doi:10.1371/journal.pone.0187533

32. Parihar JKS, Jain VK, Kaushik J, Mishra A (2017) Pars Plana-Modified versus Conventional Ahmed Glaucoma Valve in Patients Undergoing Penetrating Keratoplasty: A Prospective Comparative Randomized Study. Curr Eye Res 42(3):436–442. doi:10.1080/02713683.2016.1185130
33. Mills RP, Reynolds A, Emond MJ, Barlow WE, Leen MM (1996) Long-term Survival of Molteno Glaucoma Drainage Devices. Ophthalmology 103(2):299–305. doi:10.1016/S0161-6420(96)30700-8
34. Wang JC, See JLS, Chew PTK (2004) Experience with the use of Baerveldt and Ahmed glaucoma drainage implants in an Asian population. Ophthalmology 111(7):1383–1388. doi:10.1016/j.ophtha.2003.11.005
35. Goldberg I, Clement C (2011) The management of complicated glaucoma. Indian J Ophthalmol 59(7):141. doi:10.4103/0301-4738.73686
36. Yadgarov A, Liu D, Crane ES, Khouri AS (2017) Surgical outcomes of ahmed or baerveldt tube shunt implantation for medically uncontrolled traumatic Glaucoma. J Curr Glaucoma Pract 11(1):16–21. doi:10.5005/jp-journals-10008-1215

Figures

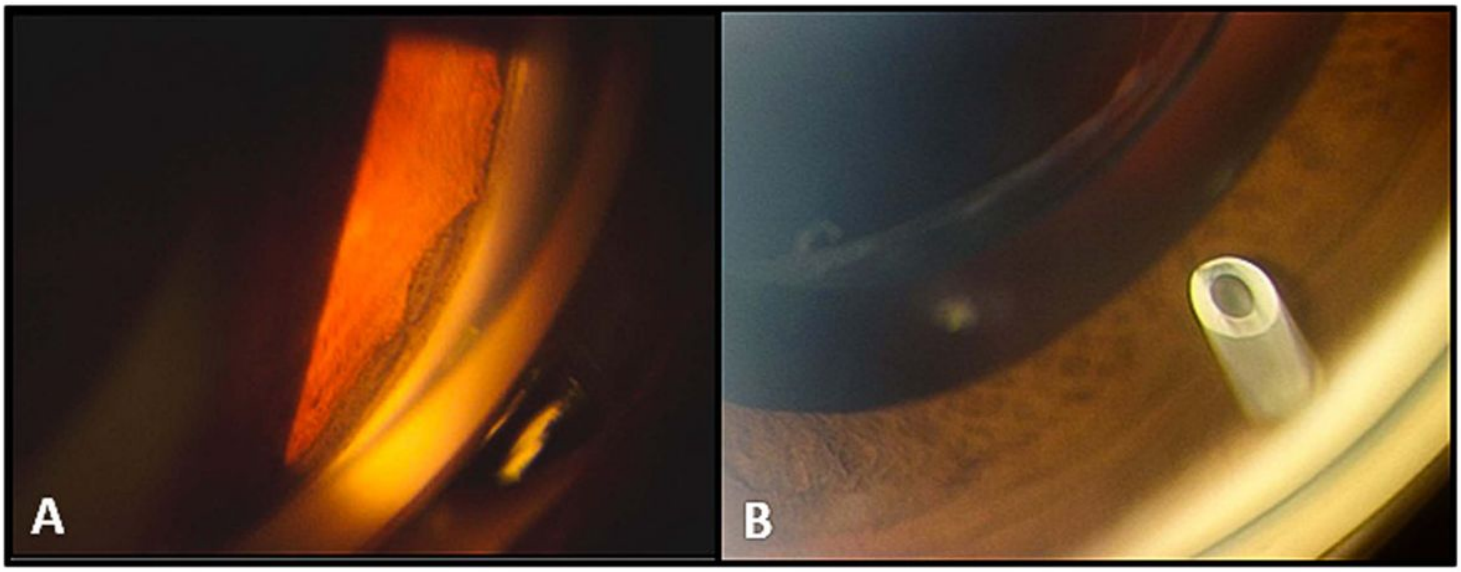

Figure 1

Pre operative slit lamp imaging showing angle recession superiorly and post operative picture depicting AGV insitu

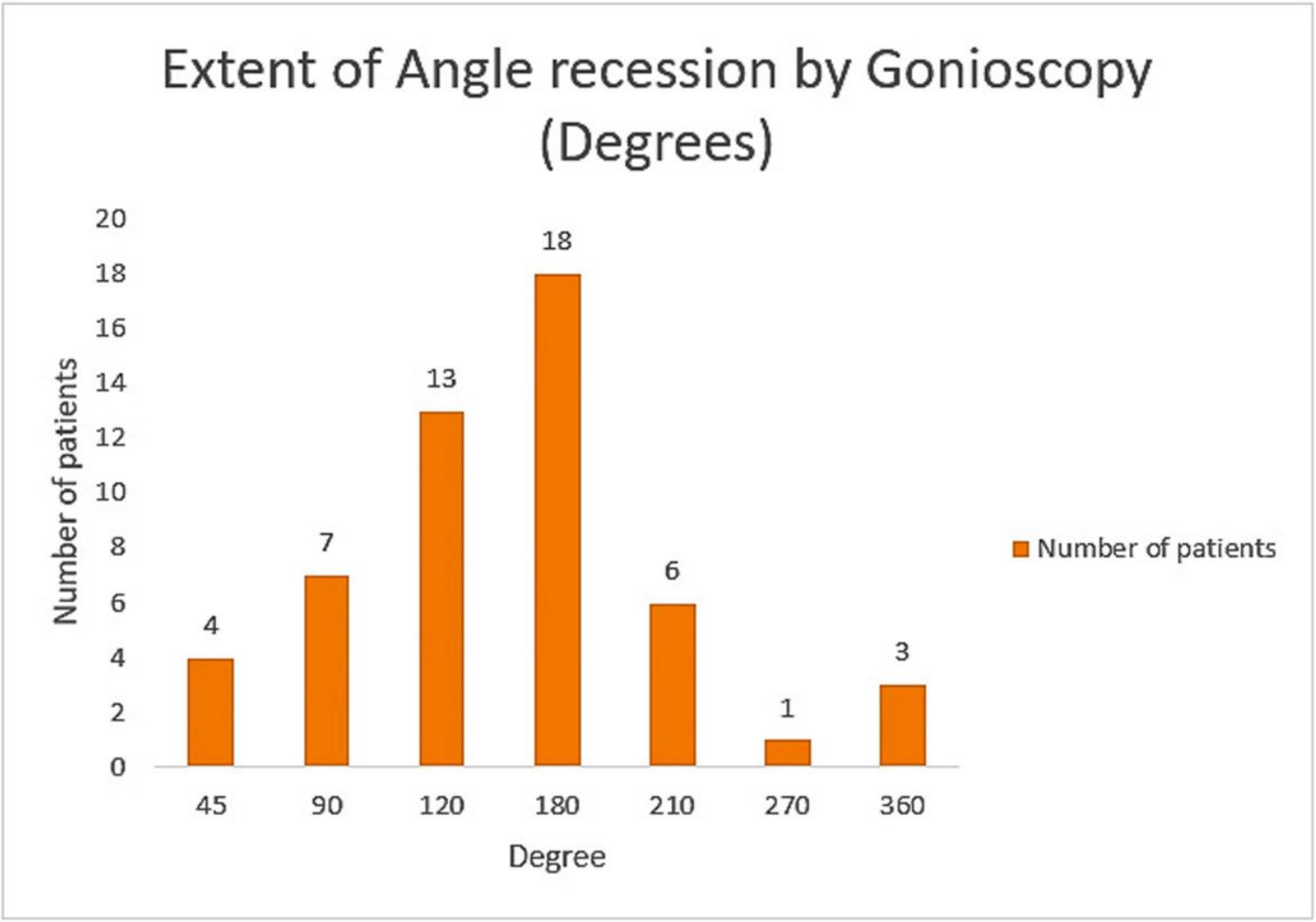

Figure 2

Graph showing the extent of angle recession on gonioscopy in patients who presented with Blunt trauma.

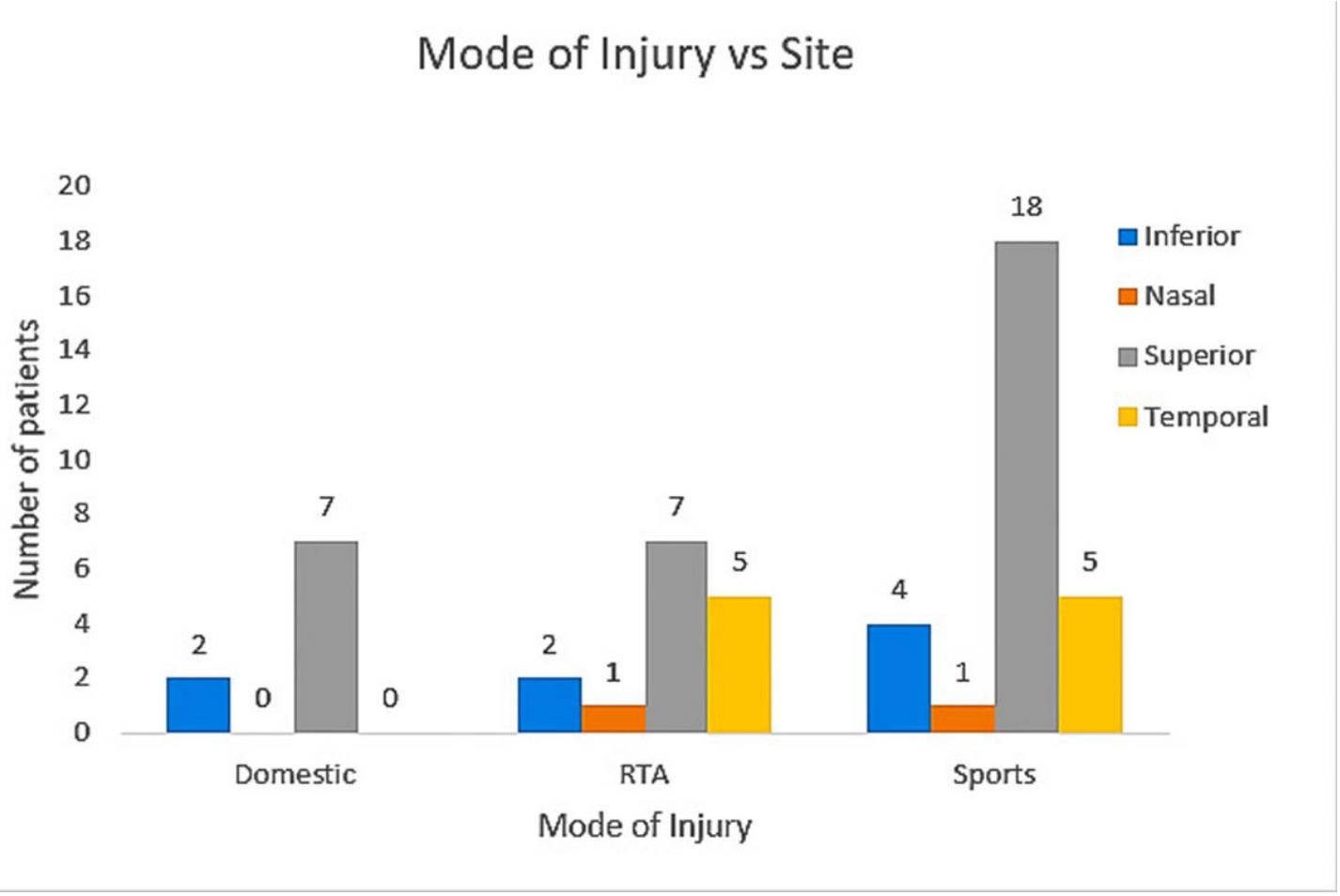

Figure 3

Graph showing the most common site of angle affected by various mode of injury.

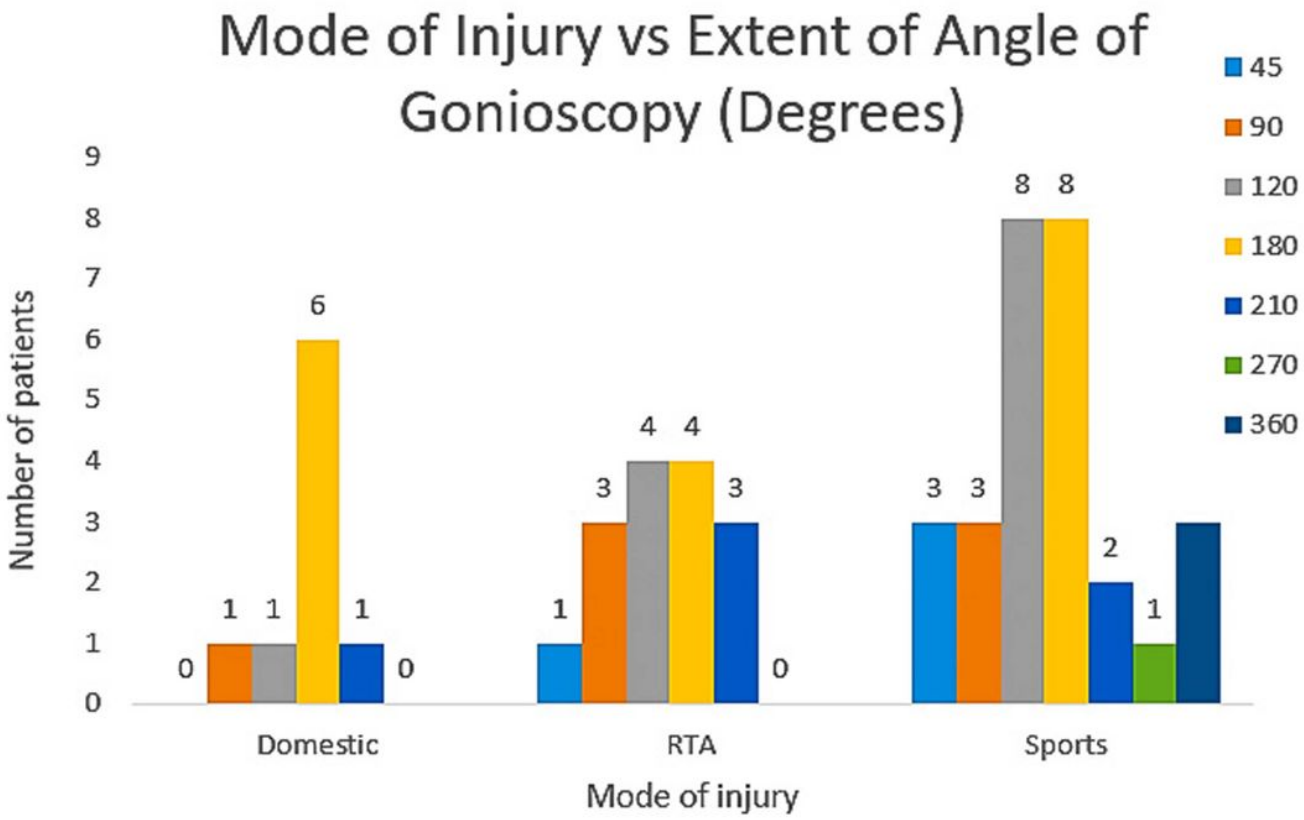

Figure 4

Graph depicting the extent of angle recession in comparison to mode of injury.

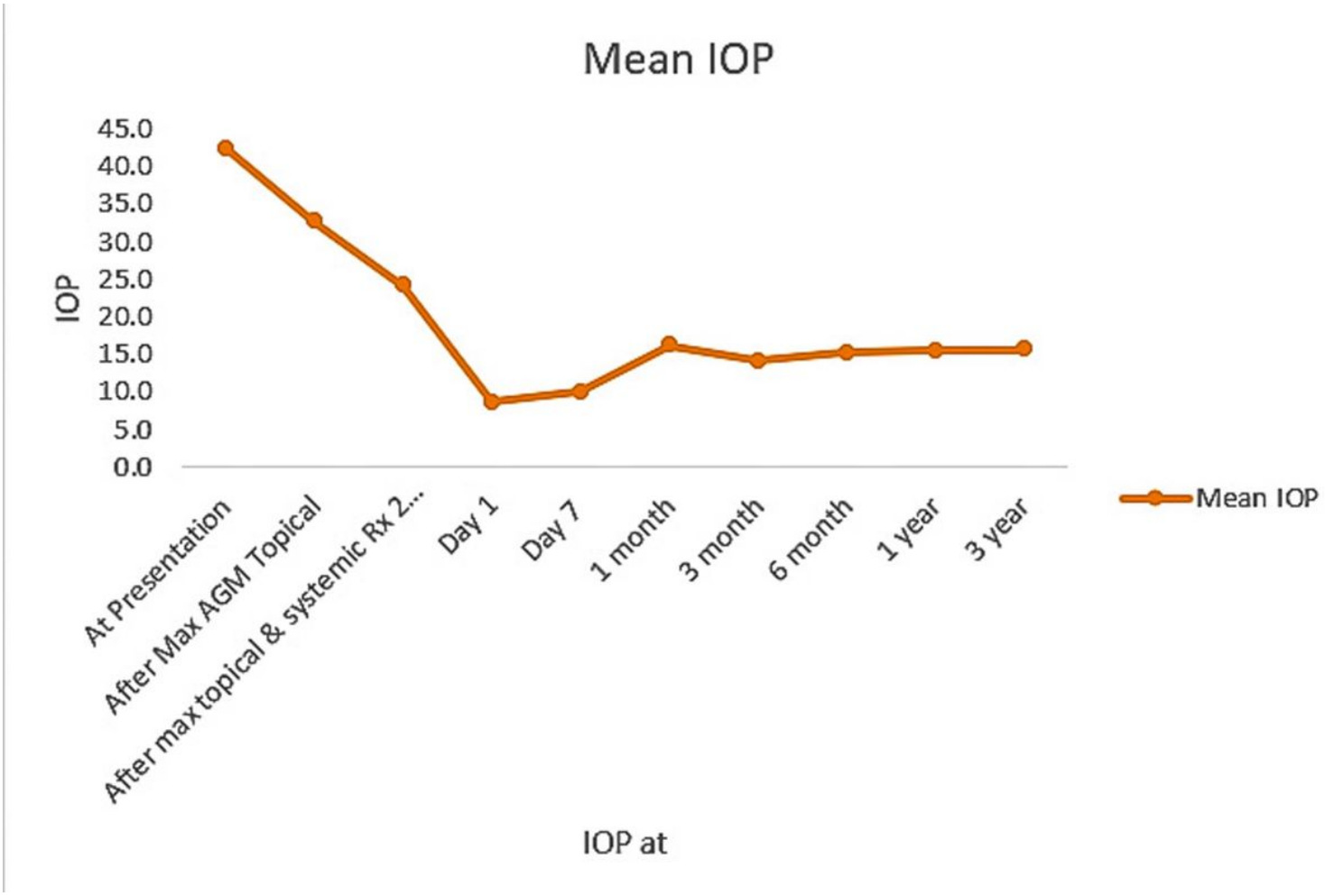

Figure 5

Mean IOP on follow up of the study population.

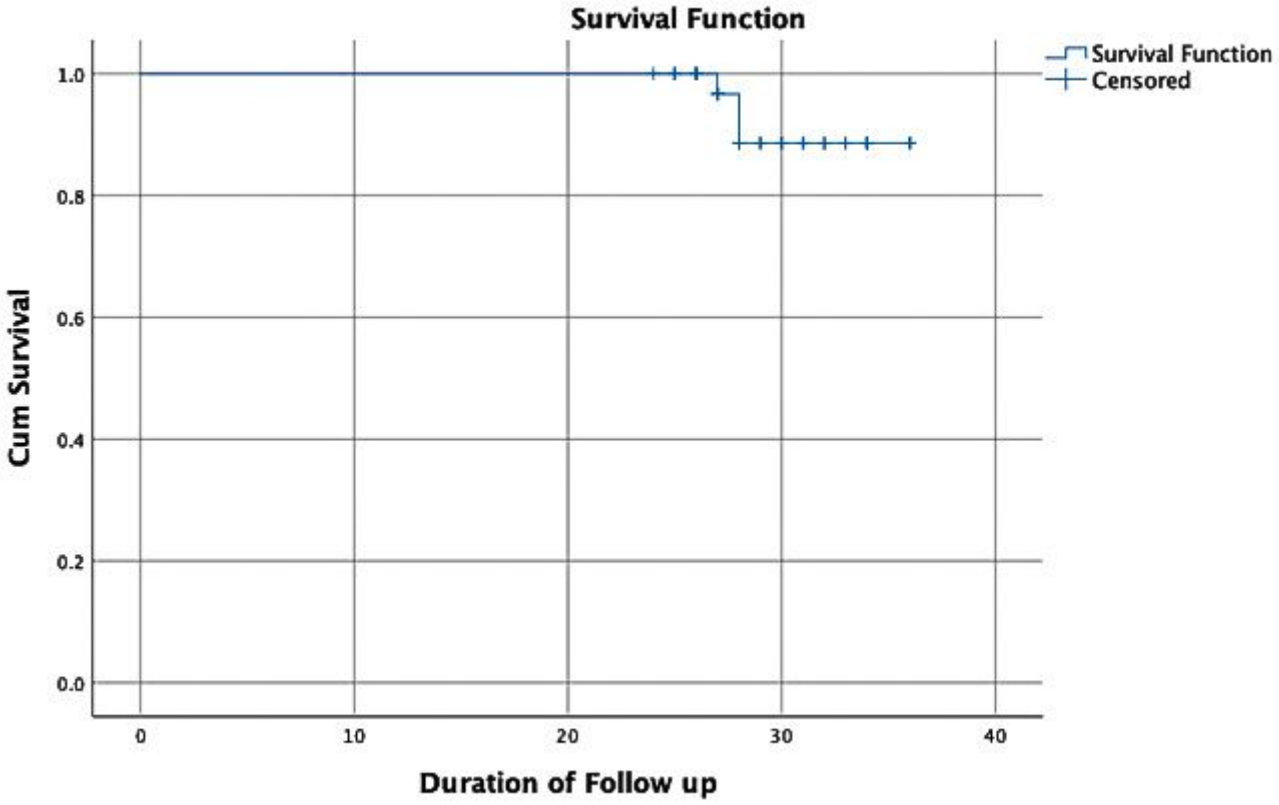

Figure 6

Kaplan -Meier Curve showing successful outcome over a follow up duration of 40 months.

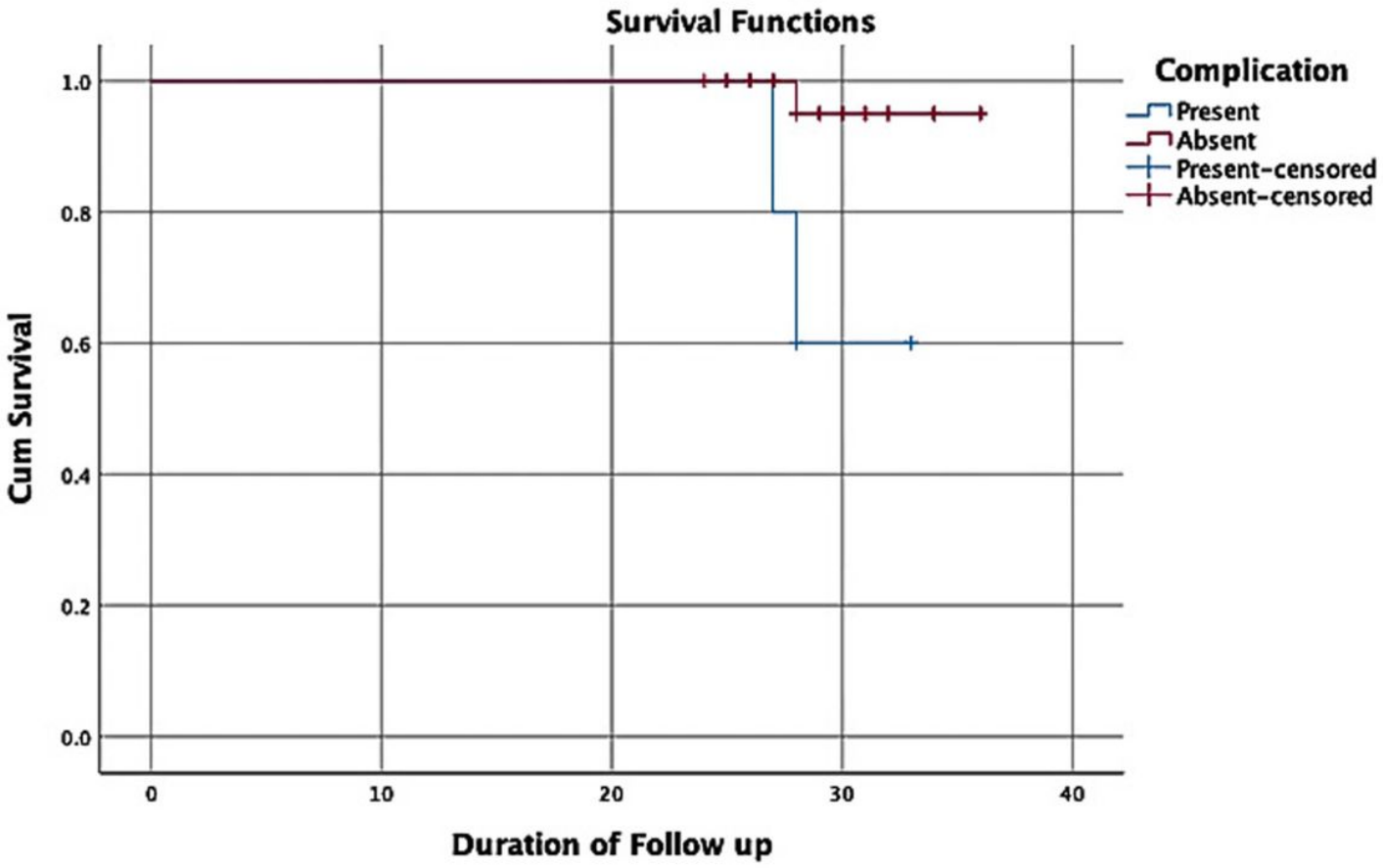

Figure 7

Kaplan-Meier Curve showing the correlation between the complications and outcome of surgery