Implantation of DDD Pacemaker in a Patient With Dextrocardia and Sick Sinus Syndrome: A Case Report

Junqian Luo
The First Affiliated Hospital of Guangdong Pharmaceutical University https://orcid.org/0000-0002-5005-220X

Zihao Zhou
The First Affiliated Hospital of Guangdong Pharmaceutical University

Kaicong Chen
The First Affiliated Hospital of Guangdong Pharmaceutical University

Junyao Lin
Chengdu Second People's Hospital

Chaogeng Cai
the Second People's Hospital of Shanwei

Zhihuan Zeng (gzzh@163.com)
The First Affiliated Hospital of Guangdong Pharmaceutical University

---

Case report

Keywords: dextrocardia, sick sinus syndrome, pacemaker implantation, active fixation leads, case report

Posted Date: March 30th, 2021

DOI: https://doi.org/10.21203/rs.3.rs-348379/v1

Abstract

Background: Dextrocardia is a congenital abnormal position of the heart in which the main part of the heart is in the right chest and the long axis of the heart points to the lower right, cases with combination of dextrocardia and sick sinus syndrome are rare.

Case presentation: A 65-year-old female patient was admitted with palpitations and dizziness for 1 week. Mirror-image Dextrocardia and sick sinus syndrome was diagnosed by electrocardiogram (ECG), echocardiography, Holter monitoring, and X-ray. The rarity of the case and the specificity of anatomy brought great challenges to our interventional treatments. Finally, we successfully implanted a DDD pacemaker into the patient.

Conclusion: For dextrocardia, using active fixation leads in both atrial and ventricular leads is easier to find the position with optimal sensing and pacing threshold, which also have a lower and more stable pacing threshold and can reduce the incidence of falling off at the same time. During operation, combine the multiple positions under fluoroscopy to confirm the leads position, which can improve the success rate of implantation.

Background

Dextrocardia refers to the congenital abnormal position of the heart in which the main part of the heart is in the right chest and the long axis of the heart points to the lower right[1−2]. It is a rare cardiac malformation that abnormal position and connection can occur in the all parts of the heart and great vessels. Dextrocardia can be divided into three types: the first is Mirror-image Dextrocardia, in which the relationship between the heart is normal, but they are in the opposite direction, usually accompanied by abdominal situs inversus, and there are few cardiovascular malformations. The incidence of congenital heart disease in these patients is between 2% and 5%[2]. The second is Dextroposition, which is not accompanied by situs inversus, only the heart is located on the right side of the chest, and the anatomical position of the left and right cardiac cavity remains unchanged, which is usually secondary to extracardiac factor (such as lung, pleura, diaphragm, etc.) that squeezes the heart to the right. The third type is Dextroversion, which means that the heart is located on the right side of the chest, but there is no situs inversus, about 90% are associated with other cardiovascular malformations[3], such as atrial septal defect, ventricular septal defect and so on[4].

The incidence of dextrocardia is about 1/10000, of which mirror-image dextrocardia accounts for about 40% [5], and dextrocardia with intracardiac malformation is about 40%~50% [6]. Due to the low incidence of dextrocardia, patients with dextrocardia with arrhythmias are not common in clinic, and cases of pacemaker implantation in these patients are even rarer. But there are also successful cases, among which dextrocardia with sick sinus syndrome and complete atrioventricular block are the main cases reported [7−11].

The patient reported in this paper is a patient with dextrocardia and sick sinus syndrome. Because of the rarity and anatomical specificity of the case, it has brought great difficulties and challenges to our dual-chamber pacemaker implantation operation. Finally, we completed the operation successfully, improved the patients' symptoms remarkably, and her quality of life improved as well.

Case Presentation

A 65-year-old female patient was admitted with palpitations and dizziness for 1 week. The patient developed palpitations and dizziness in the past 1 week, which were aggravated after the activity, and had symptoms such as amaurosis and syncope. In addition, the patient had hypertension for many years and is now taking nifedipine for treatment. There were no episode of syncope before and no similar family history. At admission, physical examination showed a blood pressure of 156/73 mmHg, heart rate 56 bpm, the point of maximal impulse was found in the right fifth intercostal space approximately 0.6 cm from the midclavicular line. Premature beats can be heard, no cardiac murmurs were auscultated. ECG examination revealed that the morphology of waves in leads avR and avL were opposite to the normal, inverted P and T waves in lead I, R wave in lead V1 to V6 decreases gradually, RV3RV4 (Fig. 1), The ECG with right-sided precordial leads and reversed limb leads showed that sinus arrest, junctional escape, ventricular premature beats, clockwise transposition (Fig. 2). Echocardiography demonstrated mirror image dextrocardia, the size of the cardiac cavities and its connection with blood vessels are normal. The chest anteroposterior X-ray showed that the heart shadow is on the right (Fig. 3). The Holter monitoring showed an average heart rate of 53 bpm, sinus block or sinus arrest (the longest RR interval of 2.20s), frequent ventricular premature beats (4607 times/24 hours, 2 times in pairs),frequent atrial premature beats (3783 times/ 24 hours), junctional escape beats,ventricular escape beats and dextrocardia.

According to the examination results and clinical symptoms, we diagnosed this patient with mirror-image dextrocardia and sick sinus syndrome, and prepared to implant a dual-chamber pacemaker for her. Before the operation, after we communicated with the patient in detail, the patient agreed to our treatment plan.

The procedure was performed in the anteroposterior view, the patient was in a supine position, the guide wire was placed successfully after the left subclavian vein was punctured under local anesthesia. Active fixation leads were used in both atrial and ventricular lead. The ventricular lead was positioned in the right ventricular apex, the pacing threshold was 0.6V, the sensitivity was 11.0mV and the impedance was 560 Ω.The atrial lead was fixed to the free wall of the right atrium, The pacing threshold was 0.5V, the sensitivity was 2.5mV, and the impedance was 620 Ω. Connected the ventricular and atrial leads with the pulse generator closely. The final position of the lead was confirmed using fluoroscopic projections (Fig. 4).

The patient had an uneventful recovery and was discharged with the symptoms were significantly improved one week later. During the 3 months follow-up, the patient was not admitted to hospital again, and she said that she did not have a repeated palpitations within 3 months.

Discussion And Conclusions

In cardiac pacemaker implantation, the commonly used leads are passive fixation lead and active fixation lead. The passive fixation lead is widely used because of its easy operation and low price. It have “tines” at the end of the lead, so that it can be embedded in the trabecular muscles acutely, after a period of time, the myocardium around it will fibrose to secure it further [12]. With the continuous development of pacing technology, the utilization rate of active fixation lead is getting higher and higher [13]. The tip of active fixation lead is a screw, which rotates out of the spiral structure during implantation and rotates into the myocardium, which can be placed anywhere in the cardiac cavity.

In this case, both the atrial and ventricular leads are active fixation leads. For the atrial leads, the passive fixation leads need to be fixed in the right atrial appendage, where the trabecular muscles are dense, however, due to the anatomical specificity of the mirror-image dextrocardia, it is difficult to reach the accurate position by using passive fixation leads, which increases the radiation exposure time of the patients, and is easy to fall off.

The active fixation leads can be fixed anywhere in the atrium, it is easier to find the position with optimal sensing and pacing threshold, and reduce the operation time, so we fix the atrial leads to the free wall of the right atrium. For a long time, many people think that this position is very thin, and it is easy to cause perforation when fixing the electrode. However, there is no significant difference in postoperative complications (such as perforation, pericardial effusion, dislodgement), pacing sensing, pacing threshold and impedance [14–15]. In addition, the use of active atrial lead fixation can reduce the incidence of dislodgement [16–17], and significantly reduce the bed rest time and duration of hospital stay of patients. Furthermore, atrial active fixation lead has a lower and more stable pacing threshold [18].

Because the anatomical specificity of the mirror-image dextrocardia, the operation during the implantation is opposite to that of a normal person, it is necessary to be fully familiar with and informed its anatomical characteristics and the trend of the blood vessels before the operation to help determine the path of lead implantation. While positioning the leads, we can combine the positive position, lateral position and oblique position under fluoroscopy, determine the position of the leads from different angles, do not push blindly and cause surgical complications. During the operation, invert the fluoroscopic image,perform the operation under the posterior anterior view[11]which is more in line with the usual operating habits, can increase the success rate of the operation, and can also reduce misoperations, which can cause vascular and cardiac injuries.

Abbreviations

ECG
electrocardiogram

Declarations

Ethics approval and consent to participate: Our article has deleted all the contents containing the patient's identity information, and written informed consent was obtained from the patient to publish their case.

Consent for publication: Not applicable.

Availability of data and materials: Not applicable.

Competing interests: The authors declare that they have no competing interests.

Funding: This work was supported by the Guangdong Provincial Innovation team Project of Colleges and Universities (No.2019KCXTD018).

Authors' contributions: JL□Junqian Luo□collected the patient's medical history, discussed the advantages of active fixation leads ,and was a major contributor in writing the manuscript. ZZ analyzed and explained the types of dextrocardia.KC stated the incidence of dextrocardia.JL (Junyao Lin) contributed significantly to analysis and manuscript preparation.All authors read and approved the final manuscript.

Acknowledgements: Not applicable.

References

1. Calcaterra G, Anderson RH, Lau KC, Shinebourne EA. Dextrocardia–value of segmental analysis in its categorisation. Br Heart J. 1979 Nov;42(5):497–507.
2. Maldjian PD, Saric M. Approach to dextrocardia in adults: review. AJR Am J Roentgenol. 2007 Jun;188(6 Suppl):S39-49; quiz S35-8..
3. Buxton AE, Morganroth J, Josephson ME, Perloff JK, Shelburne JC. Isolated dextroversion of the heart with asymmetric septal hypertrophy. Am Heart J. 1976 Dec;92(6):785–90.
4. GRANT RP. The syndrome of dextroversion of the heart. Circulation. 1958 Jul;18(1):25–36.
5. Aggarwal P, Reddy R, Yashvinder, Singh RS. Multivalvular rheumatic heart disease in a case of dextrocardia with situs inversus: an arduous surgical access. Indian J Thorac Cardiovasc Surg. 2019 Oct;35(4):584–6.
6. Raines KH, Armstrong BE. Aortic atresia with visceral situs inversus with mirror-image dextrocardia. Pediatr Cardiol. 1989 Fall;10(4):232-5.
7. Fukuda K, Onda T, Kimura Y, Miura S, Matsumori R, Masaki Y, Nishino A, Inoue K, Fujiwara Y, Sumiyoshi M. An adult case of polysplenia syndrome associated with sinus node dysfunction, dextrocardia, and systemic venous anomalies. Intern Med. 2015;54(9):1071–4.
8. Guo G, Yang L, Wu J, Sun L. Implantation of VVI pacemaker in a patient with dextrocardia, persistent left superior vena cava, and sick sinus syndrome: A case report. Med (Baltim). 2017 Feb;96(5):e6028.
9. Yao C, Wang X, Zhang J, Qiu L, Ye W, Wang C. Dextrocardia with complete AV block and the implantation of a temporary pacemaker before cesarean section: A case report. Med (Baltim). 2019 Apr;98(17):e15211.

10. Pott C, Brar R, Valderrábano M. Implant of a biventricular pacemaker in a patient with dextrocardia and persistent left superior vena cava. Pacing Clin Electrophysiol. 2006 Aug;29(8):921–2.
11. Fang Y, Jiang LC, Chen M. Successful pacemaker implantation in a patient with dextrocardia situs inversus totalis. Europace. 2009 Nov;11(11):1568–9.
12. Rajappan K. Permanent pacemaker implantation technique: part II. Heart. 2009 Feb;95(4):334–42.
13. Cano O, Osca J, Sancho-Tello MJ, Olagüe J, Castro JE, Salvador A. Failure of the active-fixation mechanism during removal of active-fixation pacing leads. Pacing Clin Electrophysiol. 2011 Oct;34(10):1217–24.
14. Jamidar H, Goli V, Reynolds DW. The right atrial free wall: an alternative pacing site. Pacing Clin Electrophysiol. 1993 May;16(5 Pt 1):959–63.
15. Witt CM, Lenz CJ, Shih HH, Ebrille E, Rosenbaum AN, Aung H, van Zyl M, Manocha KK, Deshmukh AJ, Hodge DO, Mulpuru SK, Cha YM, Espinosa RE, Asirvatham SJ, McLeod CJ. Right atrial lead fixation type and lead position are associated with significant variation in complications. J Interv Card Electrophysiol. 2016 Dec;47(3):313–9.
16. Kistler PM, Liew G, Mond HG. Long-term performance of active-fixation pacing leads: a prospective study. Pacing Clin Electrophysiol. 2006 Mar;29(3):226–30.
17. Kay GN, Anderson K, Epstein AE, Plumb VJ. Active fixation atrial leads: randomized comparison of two lead designs. Pacing Clin Electrophysiol. 1989 Aug;12(8):1355–61.
18. Hao Y, Li Y, Liao D, Yang L, Liu F. A comparative analysis of the effectiveness of active versus passive atrial lead fixation in Chinese patients with cardiac implantable electrical devices: a long term, retrospective, observational, single-center study. Curr Med Res Opin. 2017 Mar;33(3):573–8.

Figures

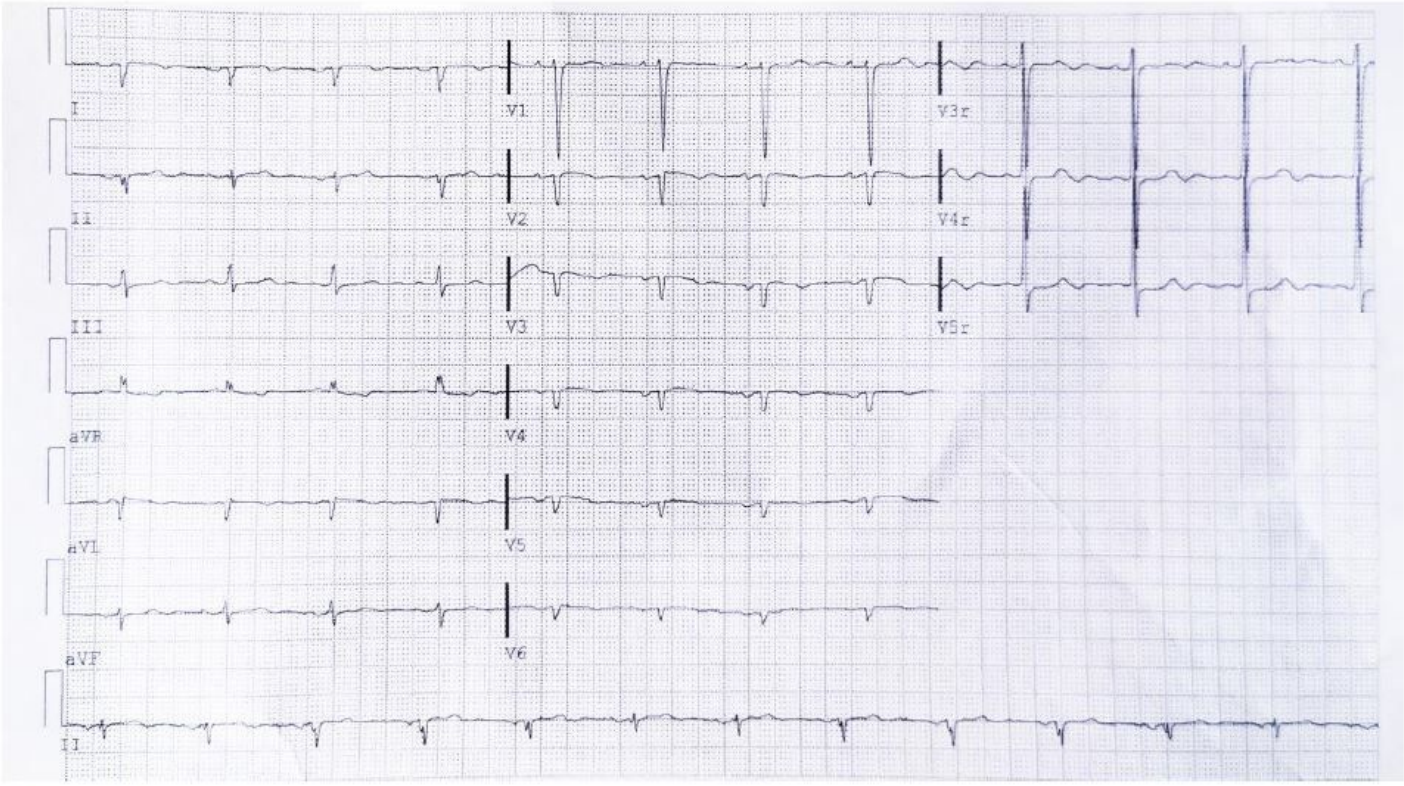

(Figure 1)

Figure 1

ECG examination revealed that the morphology of waves in leads avR and avL were opposite to the normal, inverted P and T waves in lead I, R wave in lead V1 to V6 decreases gradually, RV3RV4 (Figure 1)

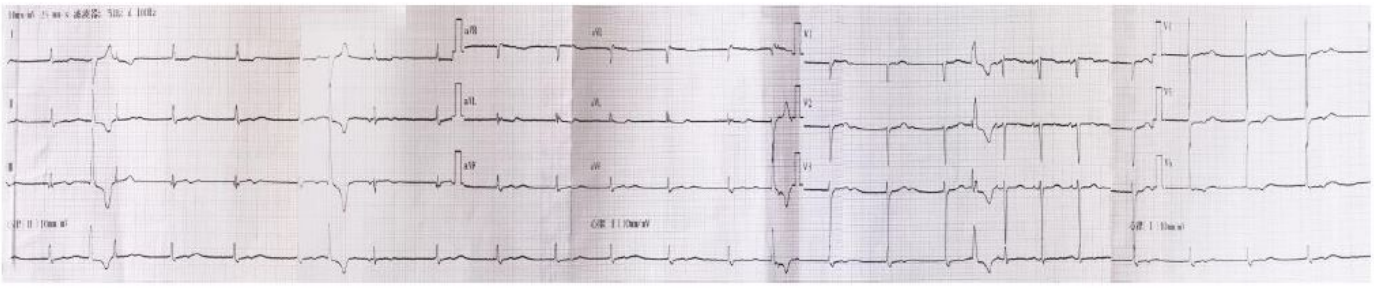

(Figure 2)

Figure 2

The ECG with right-sided precordial leads and reversed limb leads showed that sinus arrest, junctional escape, ventricular premature beats, clockwise transposition (Figure 2).

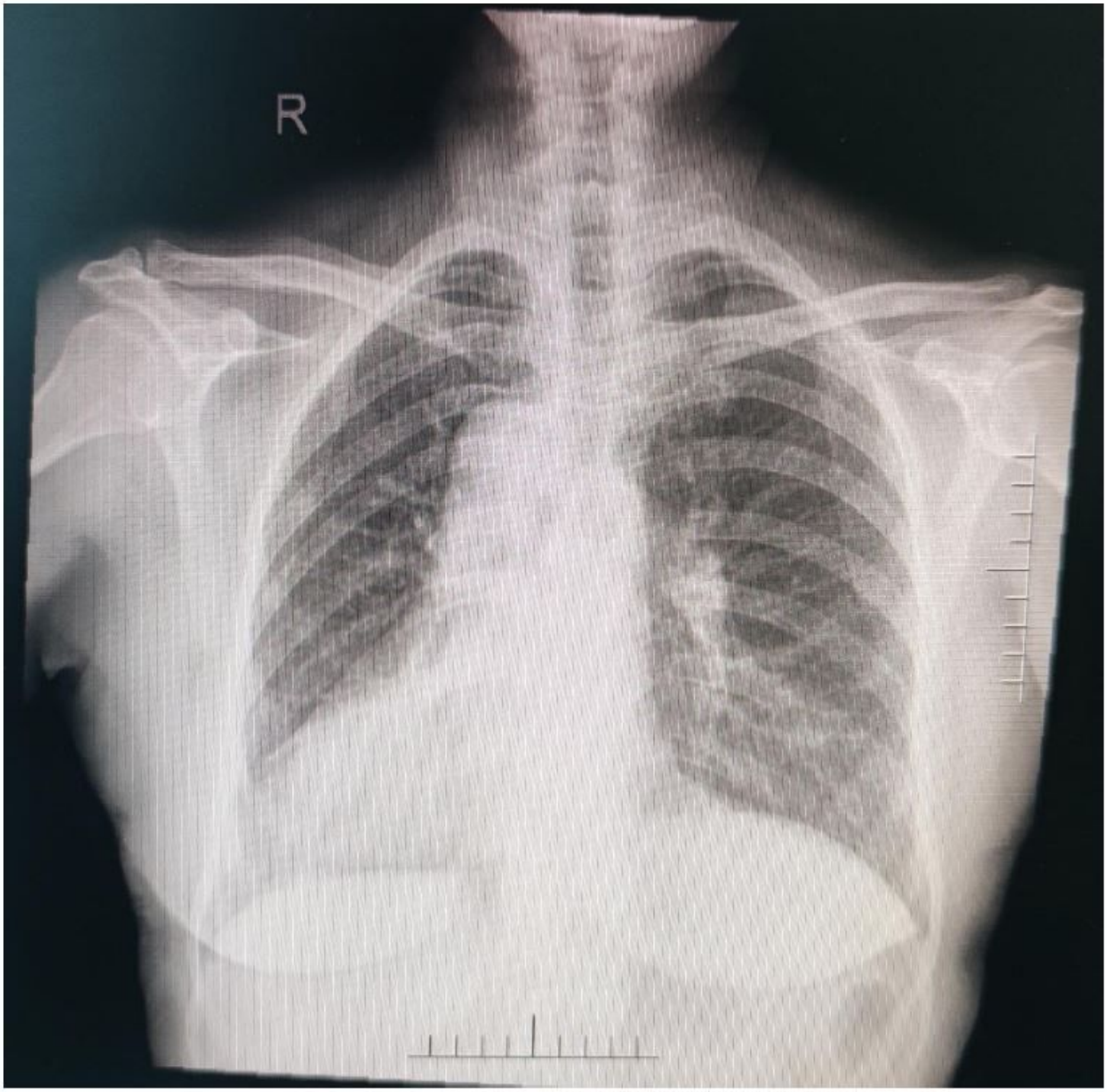

(Figure 3)

Figure 3

The chest anteroposterior X-ray showed that the heart shadow is on the right (Figure 3).

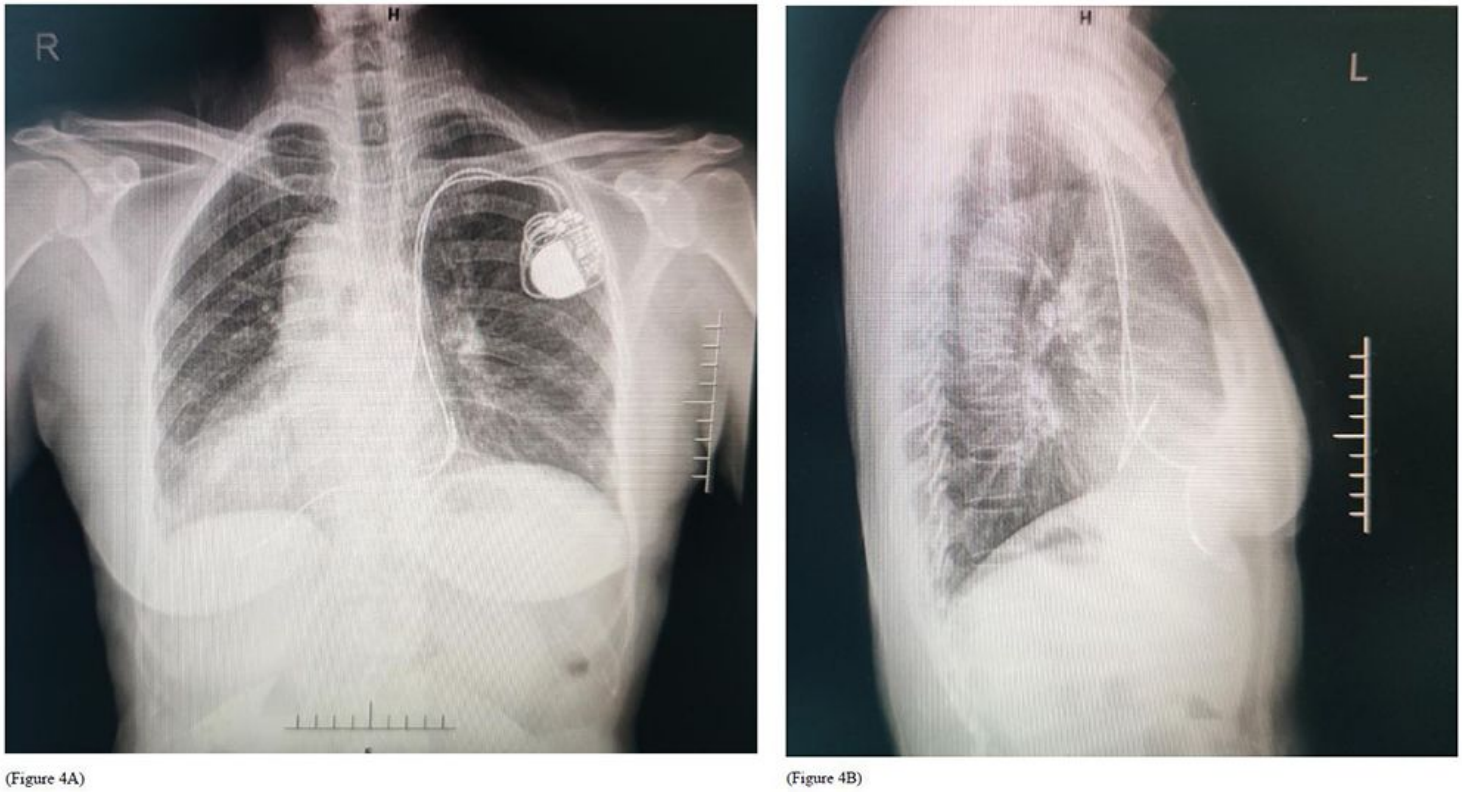

Figure 4

The final position of the lead was confirmed using fluoroscopic projections (Figure 4).

Supplementary Files

This is a list of supplementary files associated with this preprint. Click to download.

- CARChecklistEnglish.pdf