^{68}Ga-FAPI-04 vs.^{18}F-FDG in a Longitudinal Preclinical PET Imaging of Metastatic Breast Cancer

Fan Ding
Shanghai Jiao Tong University School of Medicine Affiliated Renji Hospital
Chen Huang
Shanghai University of Medicine and Health Sciences
Chenyi Liang
Shanghai Jiao Tong University School of Medicine Affiliated Renji Hospital
cheng wang
renji yi yuan jian yan ke: Shanghai Jiao Tong University School of Medicine Affiliated Renji Hospital Department of Laboratory Medicine
Jianjun Liu
Shanghai Jiao Tong University School of Medicine Affiliated Renji Hospital
Dewei Tang (acetdw@126.com)
Shanghai Jiao Tong University Medical Library: Shanghai Jiao Tong University School of Medicine
https://orcid.org/0000-0002-5427-9671

Research Article

Keywords: 68Ga-FAPI-04, fibroblast activation protein, tumor metastasis, longitudinal PET imaging

Posted Date: March 26th, 2021

DOI: https://doi.org/10.21203/rs.3.rs-348458/v1

Version of Record: A version of this preprint was published at European Journal of Nuclear Medicine and Molecular Imaging on June 28th, 2021. See the published version at https://doi.org/10.1007/s00259-021-05442-9.

Abstract

Purpose: This longitudinal study aims to evaluate the performance of 68 Ga-FAPI-04 and 18 F-FDG and to profile the dynamic process of tumor metastasis in a preclinical 4T1 breast cancer model. Although both of these two radioligands are wildly used in clinic, no study was reported on their performance in the longitudinal monitoring of tumor metastasis. Also, no correlation between the expression level of fibroblast activation protein (FAP) and the development of tumor metastasis has been elucidated previously. In this study, we evaluated the performance of 68 Ga-FAPI-04 and 18 F-FDG PET during the entire process of tumor metastasis, and their potential for the early diagnosis of tumor metastasis. We also clarified the correlation of uptakes as well as the signal-to-background (S/B) ratios between these two probes at different stages of tumor metastasis.

Methods: Forty 4T1 metastatic breast cancer murine model were established using female BALB/c mice, followed by the longitudinal imaging with 68 Ga-FAPI-04 and 18 F-FDG once a week for up to six weeks. In vitro Hematoxylin & Eosin (H&E) and immunochemistry (IHE) staining were performed to evaluate FAP expression on the metastatic lesions. Further statistical analysis was performed to evaluate the correlation of 68 Ga-FAPI-04 and 18 F-FDG uptake (%ID/cc) at different stages of the metastasis.

Results: 68 Ga-FPAI-04 holds an advantage over 18 F-FDG with higher sensitivity at the early stage of tumor metastasis. However, with the progress of tumor metastasis, uptake of 68 Ga-FAPI-04 decreases and becomes less sensitive than 18 F-FDG. There is also no direct correlation between uptake or S/B ratios of 68 Ga-FAPI-04 and 18 F-FDG during this dynamic process.

Conclusion: 68 Ga-FAPI-04 is more sensitive than 18 F-FDG in detecting the early stage of tumor metastasis, but becomes less sensitive than 18 F-FDG at the late stage of tumor metastasis. We envision this result would be meaningful for the explanation of the 18 Ga-FAPI-04 and 18 F-FDG imaging both in the future clinic and preclinic studies.

Full Text

This preprint is available for download as a PDF.

Figures

Figure 1

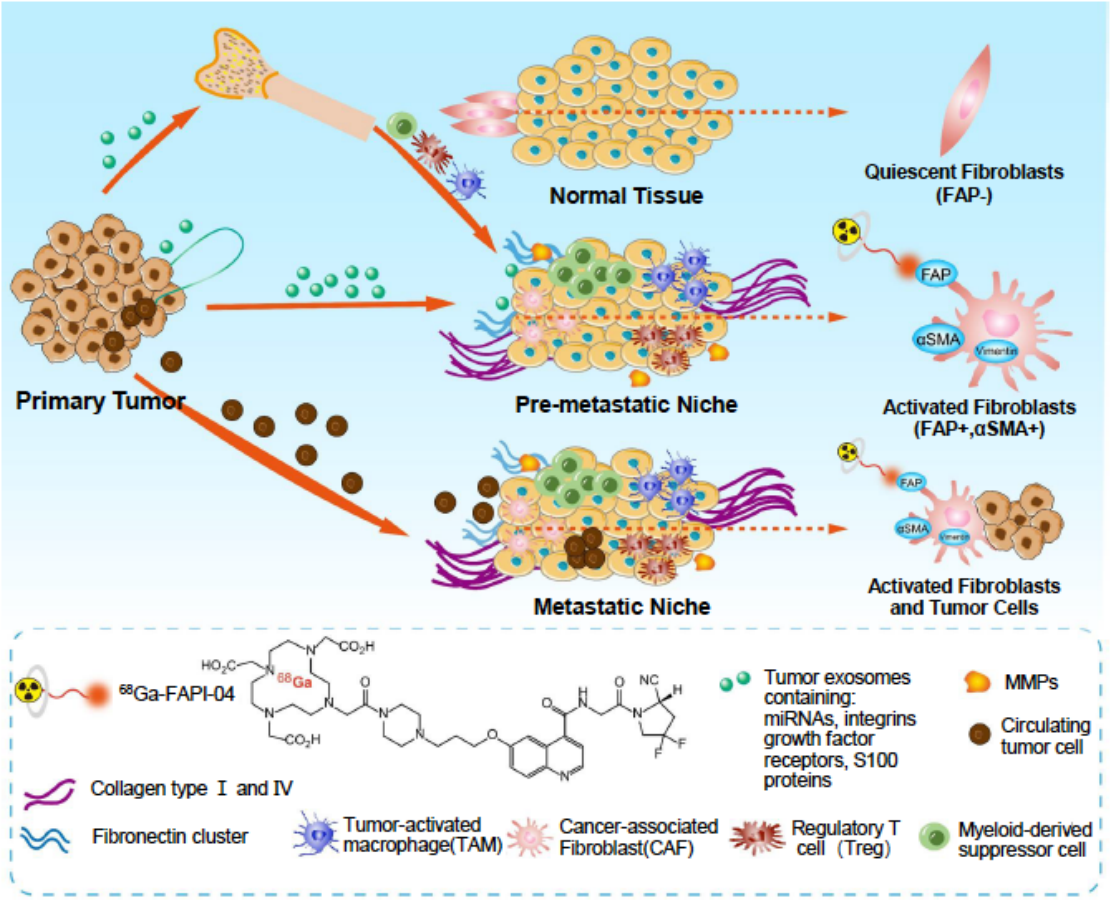

Figure 1

Cellular components involved in extracellular matrix (ECM) modifications during pre-metastatic niche formation. CAFs and FAP are crucial component for this niche formation.

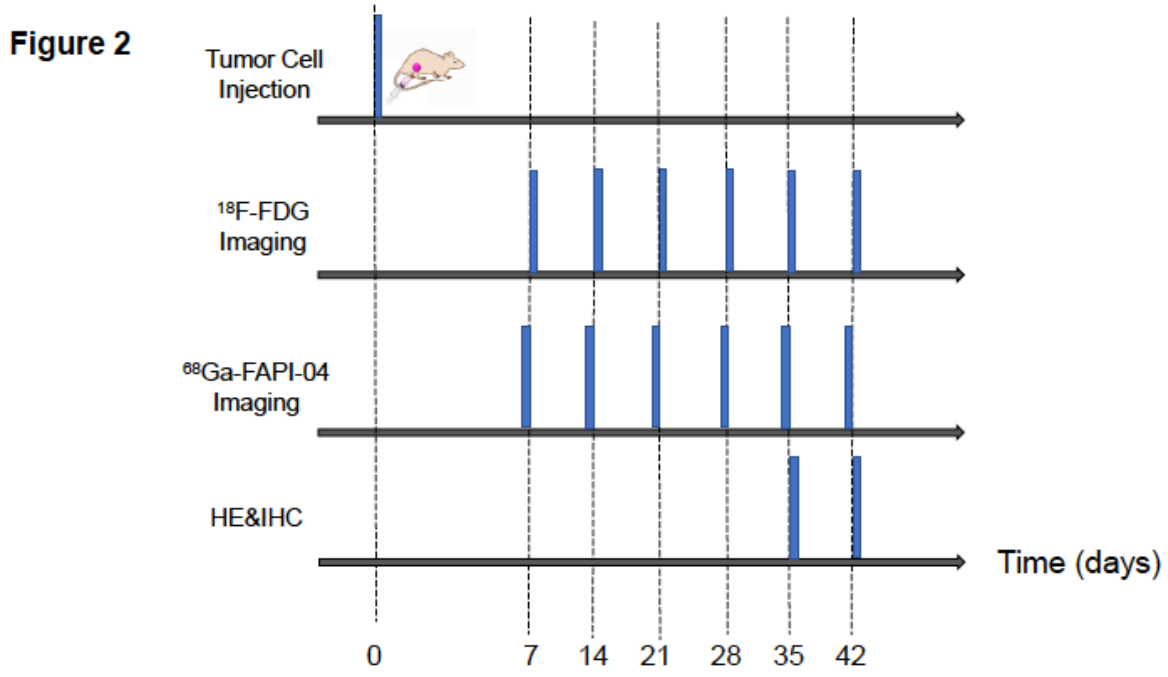

Figure 2

Time course of PET/CT scan. 68Ga-FAPI-04 imaging was performed first and then followed by 18F-FDG PET/CT scan. All mice were sacrifice and organs were collected for H&E and immunohistochemistry (IHC) staining after the dynamic scan at week 5 and week 6.

Figure 3

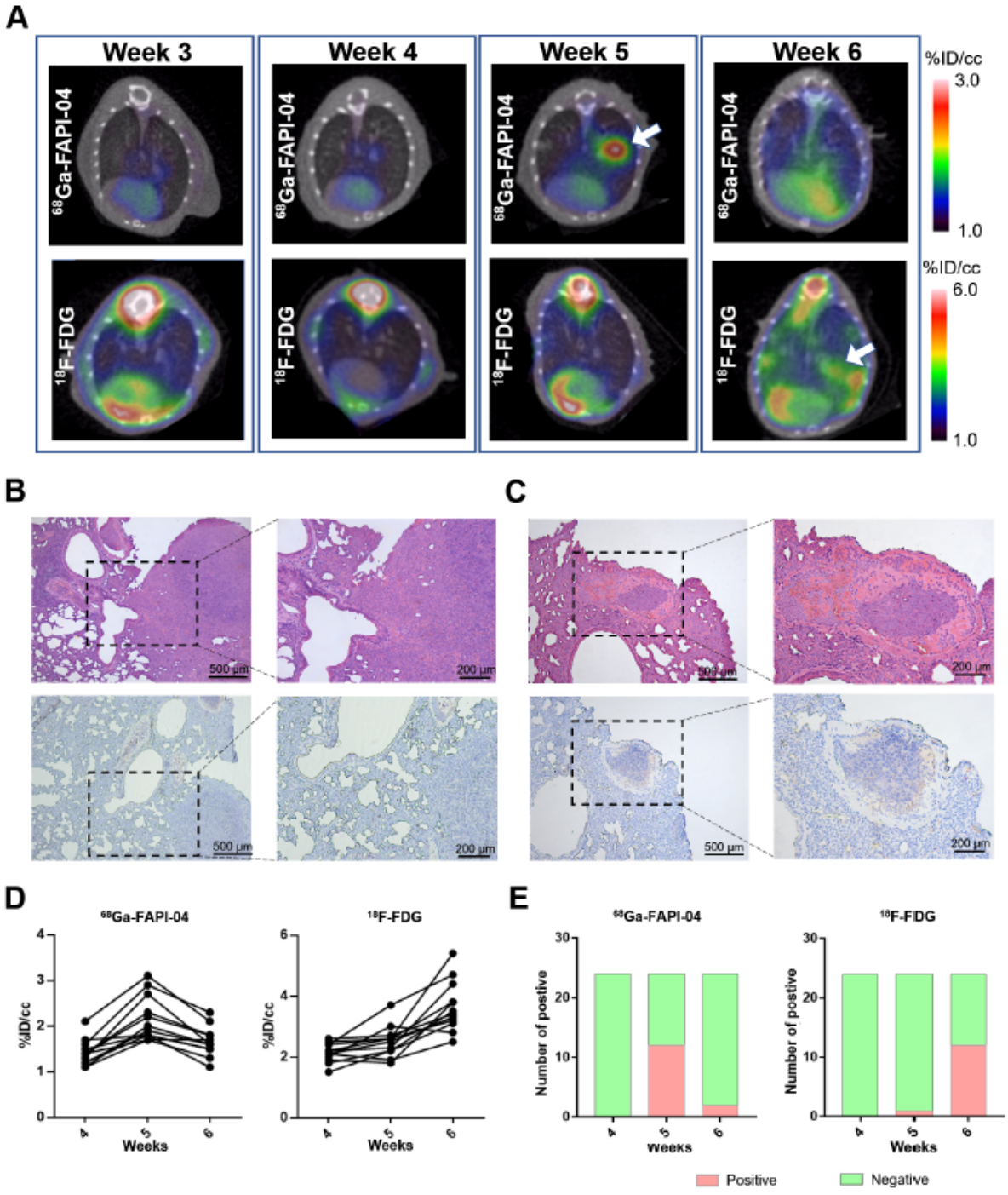

Figure 3

(A) 68Ga-FAPI-04 PET/CT image (coronal sections) from 30-min dynamic scan compared with 18F-FDG PET/CT image of 4T1 metastatic breast cancer mice at 3, 4, 5, 6 weeks after cell injection. (B) Corresponding metastatic lesions with H&E and IHC stain at week 6. (C) and metastatic lesion detected by 68Ga-FAPI-04 instead of 18F-FDG at week 5. (D) The dynamic change of ID%/cc comparison

between18F-FDG and 68Ga-FAPI-04 PET/CT in 3 to 5 weeks. (E) Assessment of positive and negative lesions (n = 12) of lung metastasis detected in 18F-FDG and 68Ga-FAPI-04 PET/CT imaging.

Figure 4

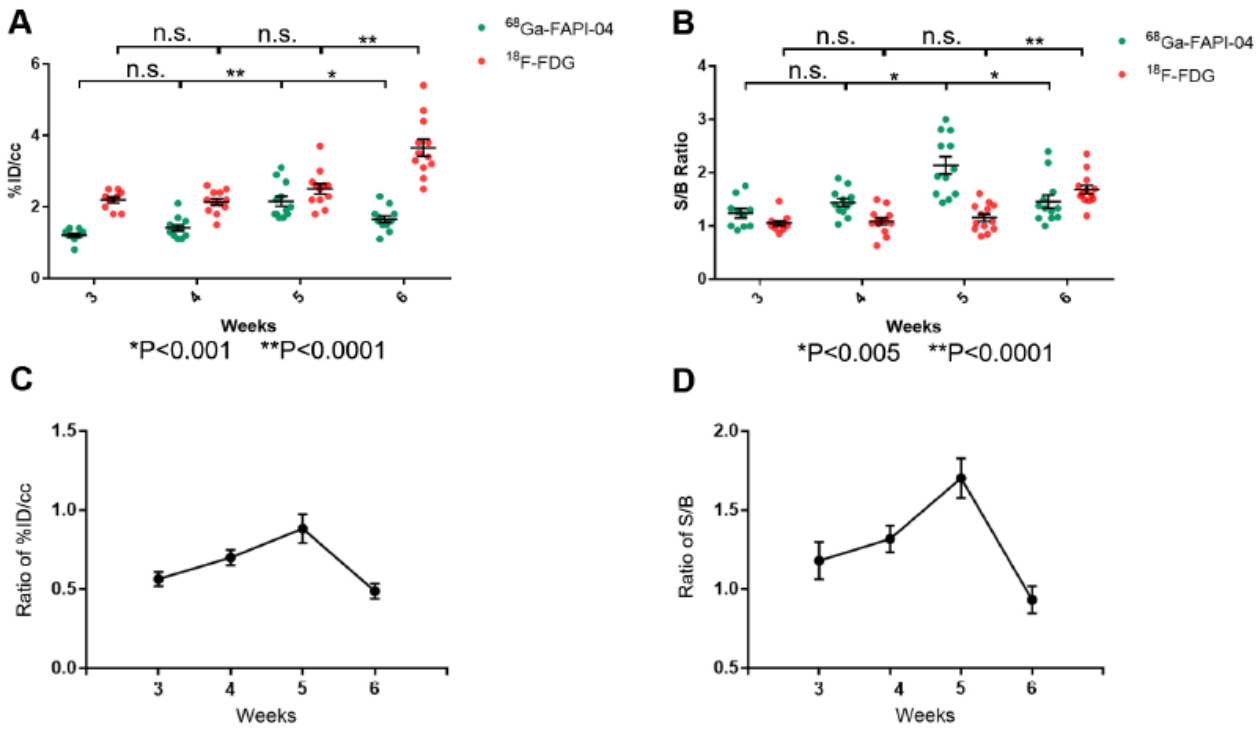

Figure 4

(A) Comparison of uptakes of 18F-FDG and 68Ga-FAPI-04 PET (%ID/cc) in the longitude study. (B) Comparison of S/B ratios of 18F-FDG and 68Ga-FAPI-04 PET in the longitude study. (C)The ratio between uptakes of 68Ga-FAPI-04 and 18F-FDG during the longitudinal study. (D) The ratio between S/B ratios of 68Ga-FAPI-04 and 18F-FDG during the longitudinal study.

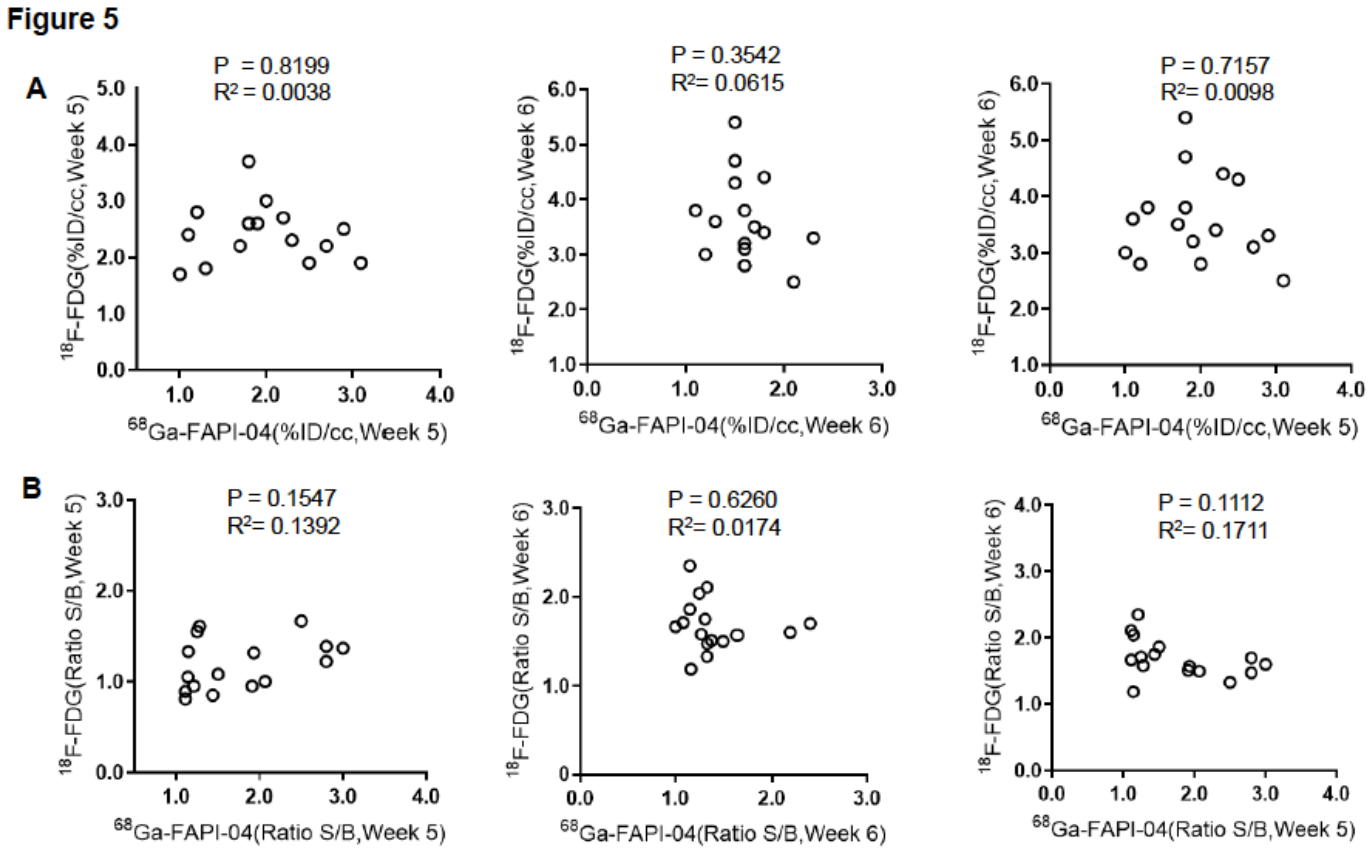

Figure 5

(A) Correlation analysis of %ID/cc of 18F-FDG and 68Ga-FAPI-04 PET/CT in different weeks; (B) Correlation analysis of S/B ratio of 18F-FDG and 68Ga-FAPI-04 PET/CT in different weeks.

Figure 6

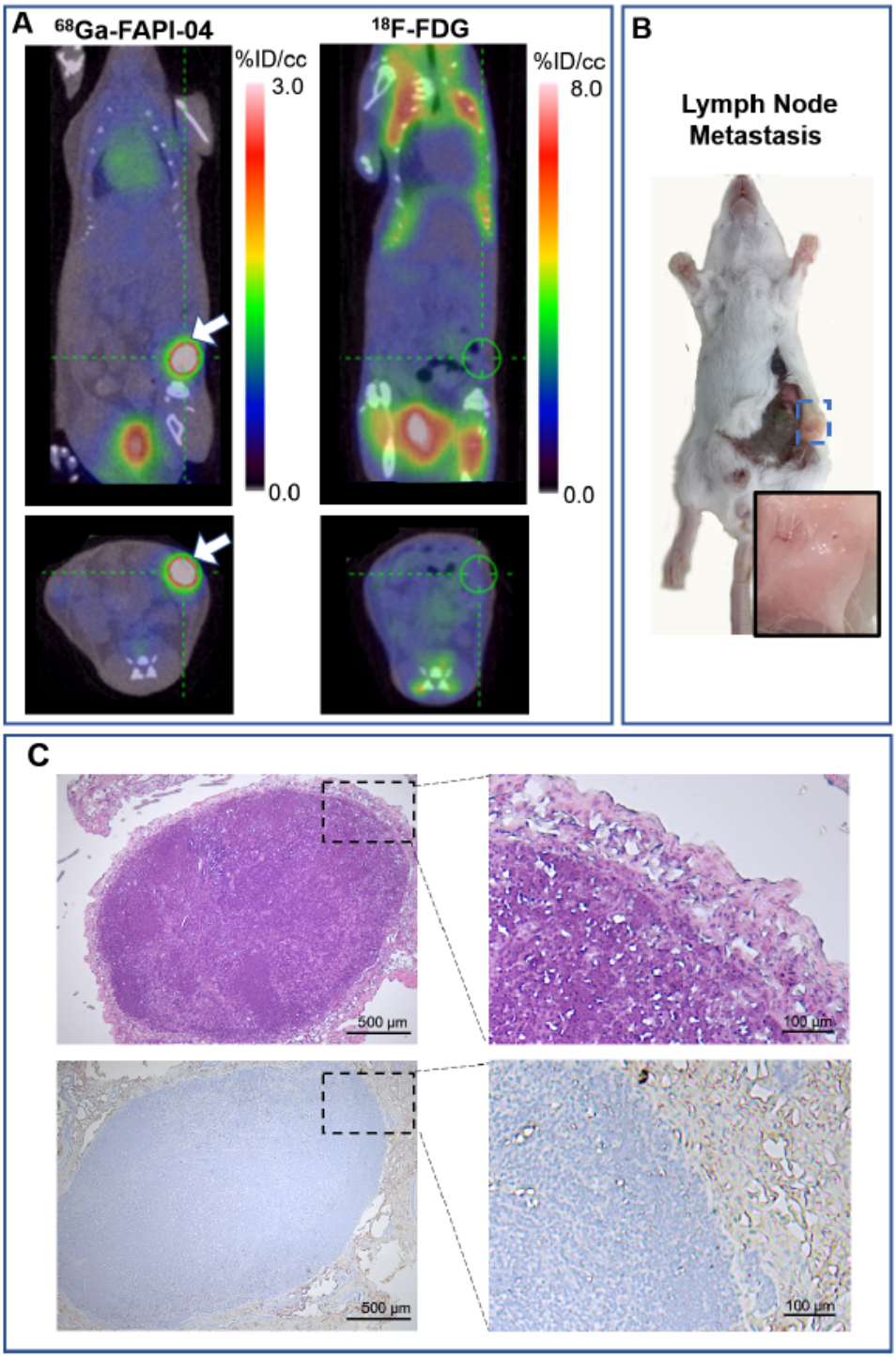

Figure 6

68Ga-FAPI-04 and 18F-FDG PET/CT image for lymph node metastasis and corresponding H&E and IHC staining.