Femtosecond Laser-Assisted Cataract Surgery in Glaucoma Patients, Case Series.

Daniela Alvarez-Ascencio (alvarezdann@gmail.com)

Asociacion para Evitar la Ceguera IAP Hospital Dr Luis Sanchez Bulnes https://orcid.org/0000-0002-9205-3649

Carolina Fernanda Prado-Larrea

Asociacion para Evitar la Ceguera IAP Hospital Dr Luis Sanchez Bulnes

Jesus Jimenez-Roman

Asociacion para Evitar la Ceguera IAP Hospital Dr Luis Sanchez Bulnes

Rafael Castañeda-Diez

Asociacion para Evitar la Ceguera IAP Hospital Dr Luis Sanchez Bulnes

---

Research article

Keywords: femtosecond laser-assisted cataract surgery, glaucoma, intraocular pressure, visual acuity, manual phacoemulsification

Posted Date: June 18th, 2020

DOI: https://doi.org/10.21203/rs.3.rs-34870/v1

Abstract

Background

We aim to describe the short-term effect of femtosecond laser-assisted cataract surgery (FLACS) in intraocular pressure (IOP), visual acuity (VA), number of hypotensive medications, and visual fields (VF) in glaucomatous eyes.

Methods

Single-center consecutive case series study included patients with a previous glaucoma diagnosis that needed cataract surgery alone or combined with incisional glaucoma procedure. IOP was measured during surgery immediately before and after pretreatment docking with an indentation tonometer. Changes in visual acuity (VA), IOP, number of medications, and VF were evaluated with a 90 day follow up.

Results

Twenty-seven eyes of 27 patients were included. Mean patient age was 70 years, 70% (n = 19) were female. Glaucoma diagnoses were: twelve patients with primary open-angle glaucoma, 13 with angle-closure glaucoma, and 2 with pseudoexfoliation glaucoma. Twenty-one patients underwent cataract surgery alone and 6 combined with an incisional glaucoma procedure (trabeculectomy or glaucoma drainage device implantation). We found no significant differences between pre-docking IOP (17.59 mmHg ± 6.25 SD) and post-docking IOP (17.23 mmHg ± 7.74 SD) p = 0.7. No surgical complications were recorded. The 90-day postoperative follow up revealed no changes from baseline regarding VF mean deviation, mean IOP, and the number of glaucoma medications decreased in both groups.

Conclusion

FLACS appears to perform well in the short-term in eyes with glaucoma undergoing cataract surgery alone or with an incisional glaucoma procedure. Comparable outcomes to manual phacoemulsification were obtained regarding IOP, VA, and postoperative period evolution.

Clinical Significance

Safety and efficacy of FLACS have not been properly studied in the glaucoma population, we present a case series with different glaucoma diagnoses who underwent FLACS alone or with an incisional glaucoma procedure.

Background

Glaucoma is the leading cause of irreversible blindness in the world. With the advent of new technologies, many different medical, laser, and surgical treatments are available. However, traditional glaucoma surgery remains the first choice of treatment for patients with refractory glaucoma and severe damage with the risk of blindness.[1] The coexistence of glaucoma and cataracts is frequent because of the age of this population group and because glaucoma medications, lasers, and surgical procedures are known to be cataractogenic. A significant number of glaucoma patients will require cataract extraction alone or a combined with a glaucoma procedure over time. [2]

In 2008, the first Femtosecond Laser-Assisted Cataract Surgery (FLACS) was performed[3] and since then its use has become widespread as a safe tool. A decrease in endothelial cell loss, a well-centered and predictable capsulorhexis, better intraocular lens (IOL) position, and less phacoemulsification energy and time requirements have been reported in FLACS in comparison to regular manual cataract surgery. [4,5,6]

The use of FLACS in glaucoma is an encouraging prospect, but very few studies on the safety of this technology in these patients are available. Many patients with glaucoma have characteristics that make cataract surgery more challenging: ocular surface disease, presence of filtering blebs or drainage devices, narrow anterior chambers, vulnerable zonules, challenging pupils, and unpredictable behavior of the anterior capsule.

During FLACS, the eye is stabilized by a suction docking system. The application of vacuum for a docking system was studied for laser in situ keratomileusis (LASIK) and it has been suggested, that it transiently raises IOP to more than 90 mmHg in non-glaucomatous eyes.[7,8] A latter *ex vivo* study suggested that femtosecond liquid docking systems create a minimal IOP rise, and this was also reported in other studies of FLACS, where only a transient mild IOP increase was shown in healthy eyes. [9,10] Recent FLACS studies comparing healthy and glaucomatous eyes show that both presented an initial IOP spike on the first day after surgery, followed by a sustained IOP reduction, that was greater and persisted longer in eyes with glaucoma.[11,12]

The superiority of FLACS compared to manual phacoemulsification cannot be determined with the evidence available today.[13] Considering the characteristics of glaucoma patients, and the added risk of IOP rising during the docking procedure in eyes with an additional vulnerability to IOP changes, we find it is important to assess the outcomes of FLACS in this population.

In the present study, we report the short-term changes of IOP during and after FLACS either alone or combined with a glaucoma incisional procedure in eyes with glaucoma.

Methods

A single-center, interventional, prospective case series study was conducted at the Glaucoma Department of a tertiary care ophthalmology center. **The study was approved by the Institutional Review Board of the hospital and followed the guidelines of the 1964 Helsinki Declaration and its later amendments.**

Patients that required cataract surgery alone or in combination with a glaucoma surgery (trabeculectomy or glaucoma drainage device (GDD)) were consecutively recruited. Inclusion criteria for FLACS alone included a diagnosis of open-angle or angle-closure glaucoma, and a vision-impairing cataract (VA < 20/40). Recruited patients with progression of glaucoma despite maximal medical therapy and intolerance to topical glaucoma medications were assigned to the FLACS + glaucoma surgery group. Patients with a history of previous ophthalmological surgery of any kind, corneal or conjunctival alterations (severe ocular surface disease, allergic conjunctivitis, chronic scarring conjunctivitis, keratoconus), with VA of Hand Motion or No Light Perception, patients that could not comply with follow up appointments were excluded.

Patients who fulfilled the inclusion criteria underwent a complete ophthalmological examination. IOP was taken preoperatively and postoperatively in every visit with a Goldmann Applanation Tonometer. Preoperative glaucoma medications used were registered and classified by class. All patients performed Humphrey 24 – 2 white-on-white VF, with the SITA-Standard algorithm and size III stimulus; Mean Deviation (MD) was recorded preoperatively and on days 30 and 90 after surgery. Changes from baseline in VF were confirmed in at least two consecutive reliable tests. VA was assessed using the Snellen chart preoperatively and in every follow-up days 1, 7, 30, and 90.

Femtosecond laser (LenSx Laser System, Alcon Laboratories, Inc.) anterior capsulotomy and lens fragmentation were completed in all patients, a contact docking interface was used. All procedures were performed by a single experienced surgeon (R.C.D.). Laser Pretreatment was performed before any other surgical step in patients with combined procedures.

Patients who underwent FLACS with a GDD implantation had an S2 Ahmed Glaucoma Valve (AGV) (New World Medical, Rancho Cucamonga CA, USA) implanted in the superotemporal quadrant, with a long scleral tunnel (4 mm) technique and no patch graft; the AGV was implanted after the FLACS was completed.

Patients who underwent FLACS with trabeculectomy had a fornix based conjunctival flap and limbal based scleral flap. The conjunctival dissection and scleral flap were performed without entering the anterior chamber, afterward, the cataract extraction and IOL implantation were carried out, and finally the trabeculectomy was completed by entering the anterior chamber and performing a 0.7 mm punch “trabeculectomy”. The scleral flap was closed using cardinal simple sutures; both scleral flap and conjunctiva were closed using 10 – 0 nylon.

During the procedure, IOP was recorded using a Schiötz indentation tonometer immediately before and after suction docking, prior administration of a topical anesthetic (tetracaine 0.5 g) with the patient in a supine position.

Data regarding VA, IOP, and VF MD were collected preoperatively and during the follow up using a computerized database (Microsoft Excel).

Results

Twenty-seven eyes of 27 patients were included, 19 women and 8 men. Mean patient age was 70 (± 9.7) years. The diagnoses included 12 patients (44.4%) with primary open-angle glaucoma, 13 with angle-closure glaucoma, and 2 with pseudoexfoliation glaucoma. Demographic data and baseline characteristics of study participants are presented in Table 1. Twenty-one patients underwent FLACS alone and 6 combined with glaucoma surgery: 2 (7.4%) with GDD, and 4 (14.8%) with trabeculectomy. No complications were recorded during the surgeries.

Mean IOP before docking was 17.59 ± 6.25 mmHg, and changed almost imperceptibly to 17.23 ± 7.74 mmHg immediately after docking. Figure 1

Mean baseline VA and best-corrected VA (BCVA) were 0.67 logMar (± 0.39) and 0.40 logMar (± 0.36) respectively; at 90 days after surgery, mean VA and BCVA were 0.45 logMar (± 0.29) and 0.24 logMar (± 0.29). Figure 2 Fig. 3

The IOP values for each patient preoperatively and during the follow-up are presented in Table 2. Patients who underwent FLACS with IOL implantation (n = 21) showed a preoperative mean IOP of 15.48 mmHg (± 2.63), and in postoperative days 1, 7, 30 and 90 mean IOPs were 17.71 mmHg (± 5.64), 13.86 mmHg (± 2.70), 13.86 mmHg (± 2.03), and 14.29 mmHg (± 2.49) respectively. Figure 4

Patients who underwent FLACS with IOL implantation combined with glaucoma surgery (n = 6) had a baseline IOP of 19.17 mmHg (± 7.7), on postoperative days 1, 7, 30 and 90, mean IOPs were 14.83 mmHg (± 8.06), 11.67 mmHg (± 4.45), 13 mmHg (± 2.5) y 13.17 mmHg (± 1.32) respectively. Figure 5

Regarding the number of topical hypotensive medications used, patients who underwent FLACS with IOL implantation alone went from 2.30 ± 0.43 to 2.00 ± 0.35 medications after surgery. Patients who underwent FLACS with IOL implantation combined with a glaucoma procedure showed a significant change from baseline (3 ± 1.09, to 0 on days 30 and 0.33 ± 0.81 on day 90 after surgery. Figure 6

Regarding VF, baseline MD (-10.72 ± 2.14dB) and post-operative MD (-10.05 ± 2.72), as well as baseline pattern standard deviation (PSD) (7.09 ± 4.31) and post-operative PSD (7.13 ± 4.45) showed no significant change. Figure 7

Table 1
Demographic data and baseline characteristics of study participants

Characteristic	Data (n = 27)
Number of patients (n)	27
Age (year)	70 ±9.7 years
Gender % (n)	
Males	29.6% (8)
Females	70.3% (19)
Glaucoma subtype % (n)	
Primary angle closure glaucoma	48.2% (13)
Primary open angle glaucoma	44.4% (12)
Pseudoexfoliation glaucoma	7.4% (2)
Baseline best corrected visual acuity (logmar), mean ± SD	0.40 ± 0.36 logMar
Baseline intraocular pressure (mmHg), mean ± SD	
FLACS + IOL	15.48 ± 2.63 mmHg
FLACS + IOL + Glaucoma surgery	19.17 ± 7.7 mmHg
Baseline number of topical glaucoma medications, mean ± SD	
FLACS + IOL	2.30 ± 0.43
FLACS + IOL + Glaucoma surgery	3 ± 1.09
Baseline visual field mean deviation (dB), mean ± SD	-10.72 ± 2.14 dB
SD standard deviation, *FLACS* Femtosecond Laser-Assisted Cataract Surgery,	

IOL Intraocular lens

Table 2
Preoperative and postoperative IOP (mmHg)

	Preoperative IOP (mmHg)	**Postoperative IOP (mmHg)**			
Case		Day 1	Day 7	Day 30	Day 90
FLACS + IOL					
1	14	14	12	14	12
2	18	30	12	12	15
3	14	26	15	12	14
4	16	14	10	11	12
5	11	18	14	13	13
6	12	22	12	15	22
7	15	15	15	14	12
8	12	11	10	11	12
9	20	20	20	20	18
10	19	30	16	16	15
11	13	18	17	12	16
12	16	14	10	16	15
13	16	18	16	16	15
14	17	23	13	13	13
15	15	12	12	13	13
16	13	12	15	14	11
17	16	13	16	14	13
18	14	18	16	13	13
19	20	15	15	14	16
20	19	13	15	14	16
21	15	16	10	14	14
FLACS + IOL + Glaucoma surgery					
1	34	8	6	16	15
2	20	16	14	15	14

	Preoperative IOP (mmHg)	Postoperative IOP (mmHg)			
3	12	22	14	14	12
4	16	24	18	13	12
5	18	16	10	10	14
6	15	3	8	10	12

Discussion

Cataract surgery is frequently performed in patients with glaucoma. To this day, the debate continues whether FLACS is equivalent or superior to manual cataract surgery. When we think about performing FLACS in patients with Glaucoma we must take into account that this procedure has the added step of suction docking during pretreatment, which has been reported in several studies to raise IOP. [10,11,12] In our study, we assess short-term IOP changes and surgical outcomes when using the femtosecond laser pretreatment in patients with different types of glaucoma undergoing cataract surgery alone or in combination with glaucoma surgery.

In our patients we found similar surgical outcomes to those published with traditional manual cataract surgery regarding IOP, VA, and VF, with the added advantage of femtosecond laser precision.[13] Suction was well tolerated in glaucomatous eyes during surgery, showing no significant mean IOP raise immediately after suction docking or up to our 90-day final follow-up. This contrasts with previous studies of FLACS performed in glaucomatous eyes. [10, 11,12,14]

In a prospective study by Darrian-Smith, 143 eyes (30% with glaucoma) were studied by measuring IOP with a rebound tonometer before and after suction docking during FLACS with Catalys Precision Laser System with Liquid Optics Interface (Abbott Medical Optics, Inc.). Their results showed a transient IOP increase from baseline that was significantly higher in glaucomatous eyes; after removal of suction the IOP levels decreased in both groups, but remained above preoperative values and were higher in eyes with glaucoma. [11]

A retrospective case series study conducted by Shah evaluated the long term IOP changes in 504 eyes, of which 278 had glaucoma, after FLACS. They reported that both control and glaucomatous eyes had an initial IOP spike, followed by a sustained reduction from baseline up to 3 years follow up, this decrease was greater and lasted longer in eyes with glaucoma than in healthy control eyes.[12]

In our study, patients who underwent FLACS with IOL implantation alone did not present an IOP elevation during surgery or in the first 30 days of follow up, instead, they showed a lower mean IOP at day 90 after surgery in comparison to baseline.

Regarding eyes who underwent FLACS with IOL implantation and glaucoma surgery, there was an IOP reduction from day 1 after surgery, that lasted up to 90 days with a 6 mmHg decrease from baseline. This group also showed a significant reduction in topical glaucoma medication requirement, which is expected in combined glaucoma surgery.

When comparing FLACS outcomes, we must consider that different femtosecond systems will have different characteristics, therefore, they are not totally comparable to one another; even in the same femtosecond system, different types of suction docking interfaces can have different outcomes in IOP changes. [14]

No complications that have been previously reported in FLACS, like incomplete capsulotomy, tears in anterior capsule or posterior capsule ruptures were recorded during any of the surgeries in our study.[15,16,17]

BCVA was significantly improved in both groups. No changes in VF were recorded, but longer follow up is necessary to evaluate the real impact of this procedure in glaucoma progression.

A small sample with a short follow-up are the main limitations of our study, which allows for a descriptive case series instead of a more thorough statistical analysis. A larger sample, with a longer follow up, along with a control group would allow an analysis that could give us more conclusive results regarding the safety and outcomes of Femtosecond Laser alone or in combination with glaucoma surgery in patients with glaucoma. To our knowledge outcomes of FLACS used in combination with glaucoma surgery had not been previously reported. The use of FLACS in eyes with previous glaucoma surgery or along with Microinvasive Glaucoma Surgery (MIGS) has not been reported and could be an interesting prospect to explore.

Conclusion

Looking at our case series results, we can conclude that FLACS alone or in combination with an incisional glaucoma procedure appears to be well tolerated in eyes with glaucoma. It could be a safe alternative to traditional manual phacoemulsification in glaucoma patients, although further research and a larger sample with a longer follow up is warranted to evaluate the long term effects of FLACS on these patients.

Abbreviations

FLACS - femtosecond laser-assisted cataract surgery

IOP - intraocular pressure

VA – visual acuity

VF – visual fields

IOL – intraocular lens

LASIK - laser in situ keratomileusis

GDD - glaucoma drainage device

MD - mean deviation

AGV - Ahmed glaucoma valve

PSD - pattern standard deviation

SD – standard deviation

MIGS – microinvasive glaucoma surgery

Declarations

The study was approved by the Institutional Review Board of Asociación Para Evitar la Ceguera en México (APEC), IAP, Mexico City, Mexico, and followed the guidelines of the 1964 Helsinki Declaration and its later amendments.

Consent for publication - Not applicable.

Ethics Approval and Consent to Participate – Written informed consent was obtained from all participants for the surgical procedure and participation in the study.

Availability of data and materials - The datasets obtaines during and/or analyzed during the current study available from the corresponding author on reasonable request.

Competing interests -"The authors declare that they have no competing interests"

Funding Support for the study: None

Authors' contributions: "RCD and CP designed this study. DA and CP collected, analyzed and interpreted all the data. RCD was the surgeon in all the reported cases. DA and CP wrote the manuscript. JJR, RCD and CP helped edit and review the manuscript and data. All authors read and approved the final manuscript."

Acknowledgements: None.

References

1. Bruce, D.S. and F.C. Allan, Combined small incision phacoemulsification and trabeculectomy. Journal of Cataract & Refractive Surgery, 1993. 19: p. 97-102.

2. Giaconi, J.A., S.K. Law, and A.L. Coleman, Pearls of Glaucoma Management, ed. Springer. 2010, New York.

3. Zoltan, N., et al., Complications of femtosecond laser-assisted cataract surgery. Journal of Cataract & Refractive Surgery, 2014. 40: p. 20-28.

4. Agarwal A, Jacob S. Current and effective advantages of femto phacoemulsification. Curr Opin Ophthalmol. 2017 Jan;28(1):49-57. Review.

5. Grewal DS, Schultz T, Basti S, Dick HB. Femtosecond laser-assisted cataract surgery–current status and future directions. Surv Ophthalmol. 2016 Mar-Apr;61(2):103-31

6. Nagy ZZ, Mastropasqua L, Knorz MC. The use of femtosecond lasers in cataract surgery: review of the published results with the LenSx system.J Refract Surg. 2014 Nov;30(11):730-40

7. Kasetsuwan N, Pangilinan RT, Moreira LL, DiMartino DS, Shah SS, Schallhorn SC, McDonnell PJ. Real time intraocular pressure and lamellar corneal flap thickness in keratomileusis. Cornea 2001; 20:41–44

8. Bissen-Miyajima H, Suzuki S, Ohashi Y, Minami K. Experimental observation of intraocular pressure changes during microkeratome suctioning in laser in situ keratomileusis. J Cataract Refract Surg 2005; 31:590–594

9. Kerr NM, Abell RG, Vote BJ, Toh T'Y. Intraocular pressure during femtosecond laser pretreatment of cataract. J Cataract Refract Surg 2013; 39:339–342

10. Baig NB, Cheng GPM, Lam JKM, Jhanji V, Chong KKL, Woo VCP, Tham CCY. Intraocular pressure profiles during femtosecond laser-assisted cataract surgery. J Cataract Refract Surg 2014; 40:1784–1789

11. Darian-Smith E., Howie A.R., Abell R.G., Kerr N., Allen P.L., Vote B.J., Toh T. Intraocular pressure during femtosecond laser pretreatment: Comparison of glaucomatous eyes and nonglaucomatous eyes. *Journal of Cataract and Refractive Surgery*, 2015; 41 (2), pp. 272-277.

12. Shah, Avni A et al. "Long-term intraocular pressure changes after femtosecond laser-assisted cataract surgery in healthy eyes and glaucomatous eyes." *Journal of cataract and refractive surgery* 45 2 (2019): 181-187.

13. Day AC1, Gore DM, Bunce C, Evans JR. Laser-assisted cataract surgery versus standard ultrasound phacoemulsification cataract surgery. Cochrane Database Syst Rev. 2016 Jul 8;7

14. Schultz T, Conrad-Hengerer I, Hengerer FH, Dick HB. Intraocular pressure variation during femtosecond laser-assisted cataract surgery using a fluid-filled interface. J Cataract Refract Surg 2013; 39:22–27

15. Vazquez-Ferreiro P, et al. Intraoperative complications of phacoemulsification in pseudoexfoliation: Metaanalysis. J Cataract Refract Surg. 2016 Nov;42(11):1666-1675.
16. Taravella MJ, et al. Femtosecond laser-assisted cataract surgery in complex cases. J Cataract Refract Surg. 2016 Jun;42(6):813-6
17. Küchle M, et al. Anterior chamber depth and complications during cataract surgery in eyes with pseudoexfoliation syndrome. Am J Ophthalmol. 2000 Mar;129(3):281-5.
18. Avni A. Shah, MD, Jeanie Ling, MD, Niraj R. Nathan, MD, Ashton J. Kalhorn, BS, Qingxia Chen, Ph.D., Jeffrey A. Kammer, MD, Leonard K. Seibold, MD

Figures

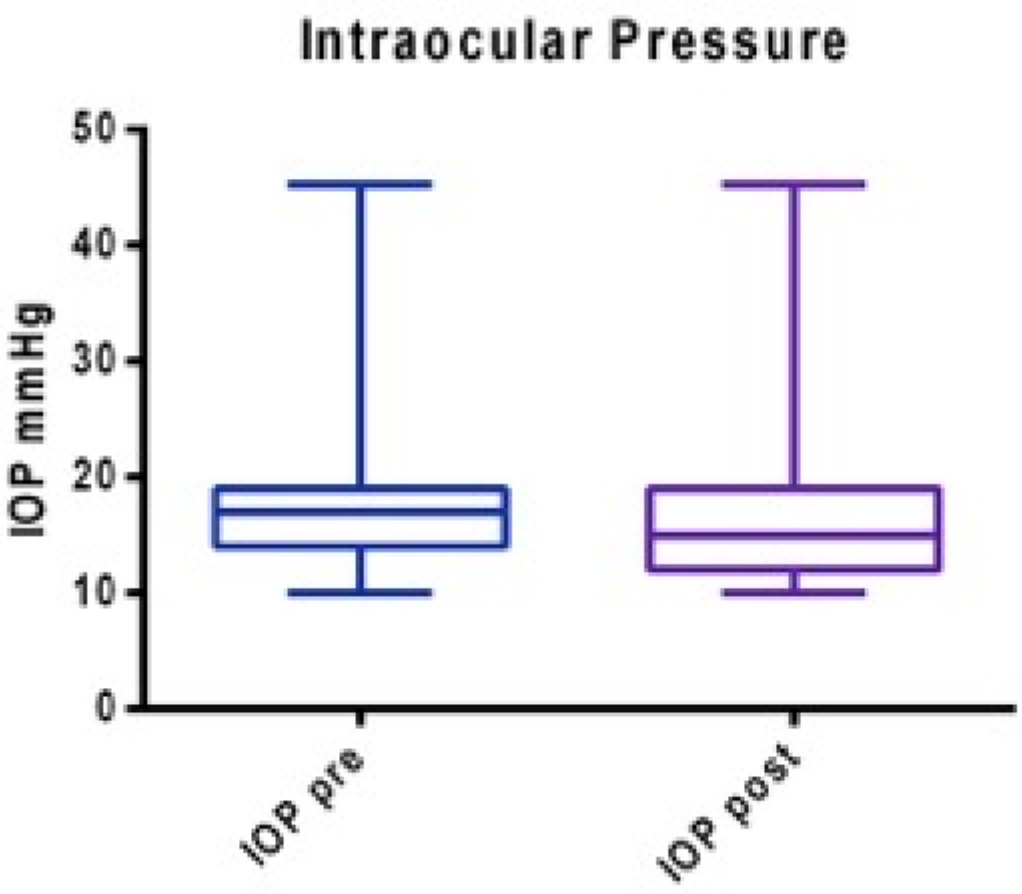

Figure 1

Mean IOP pre-docking and post-docking

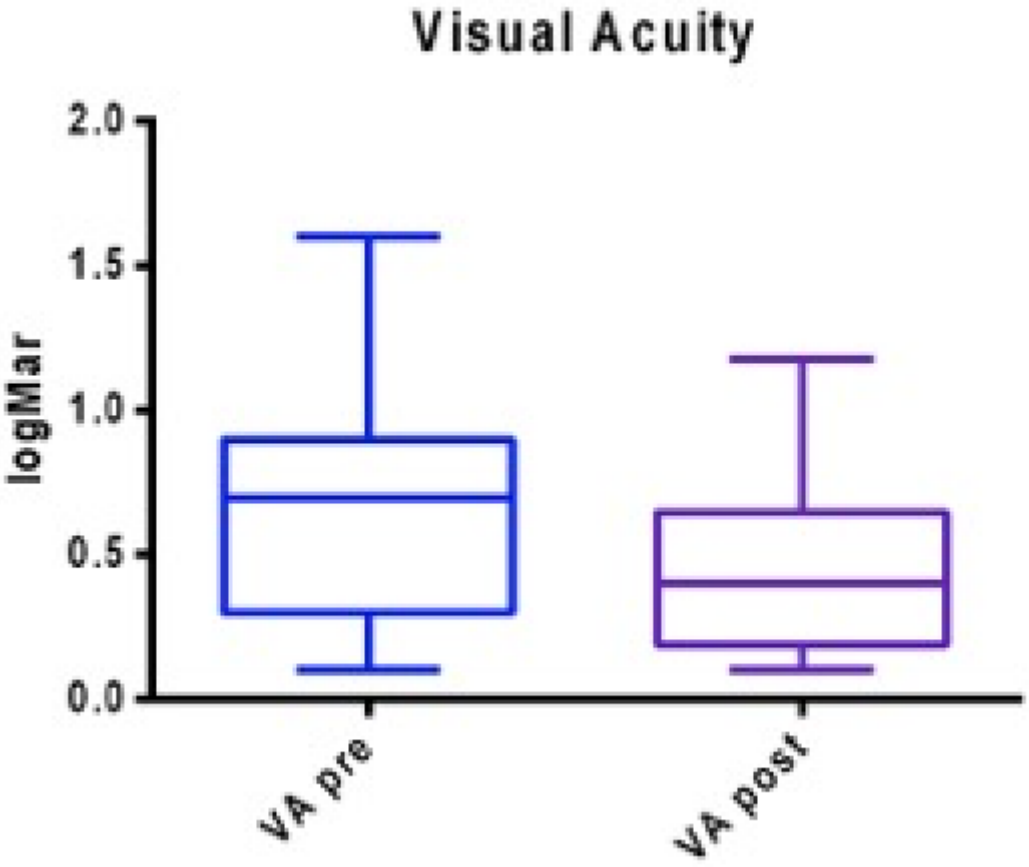

Figure 2

VA before and after surgery in both groups

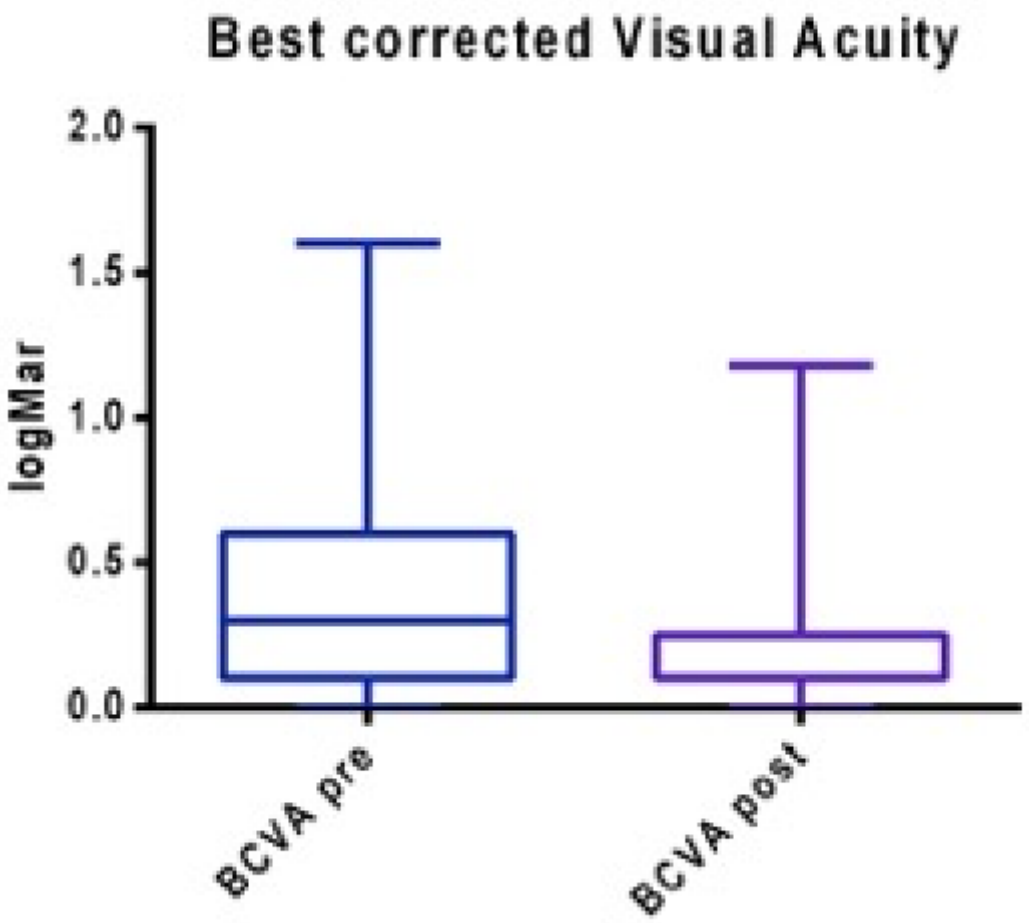

Figure 3

BCVA before and after surgery in both groups

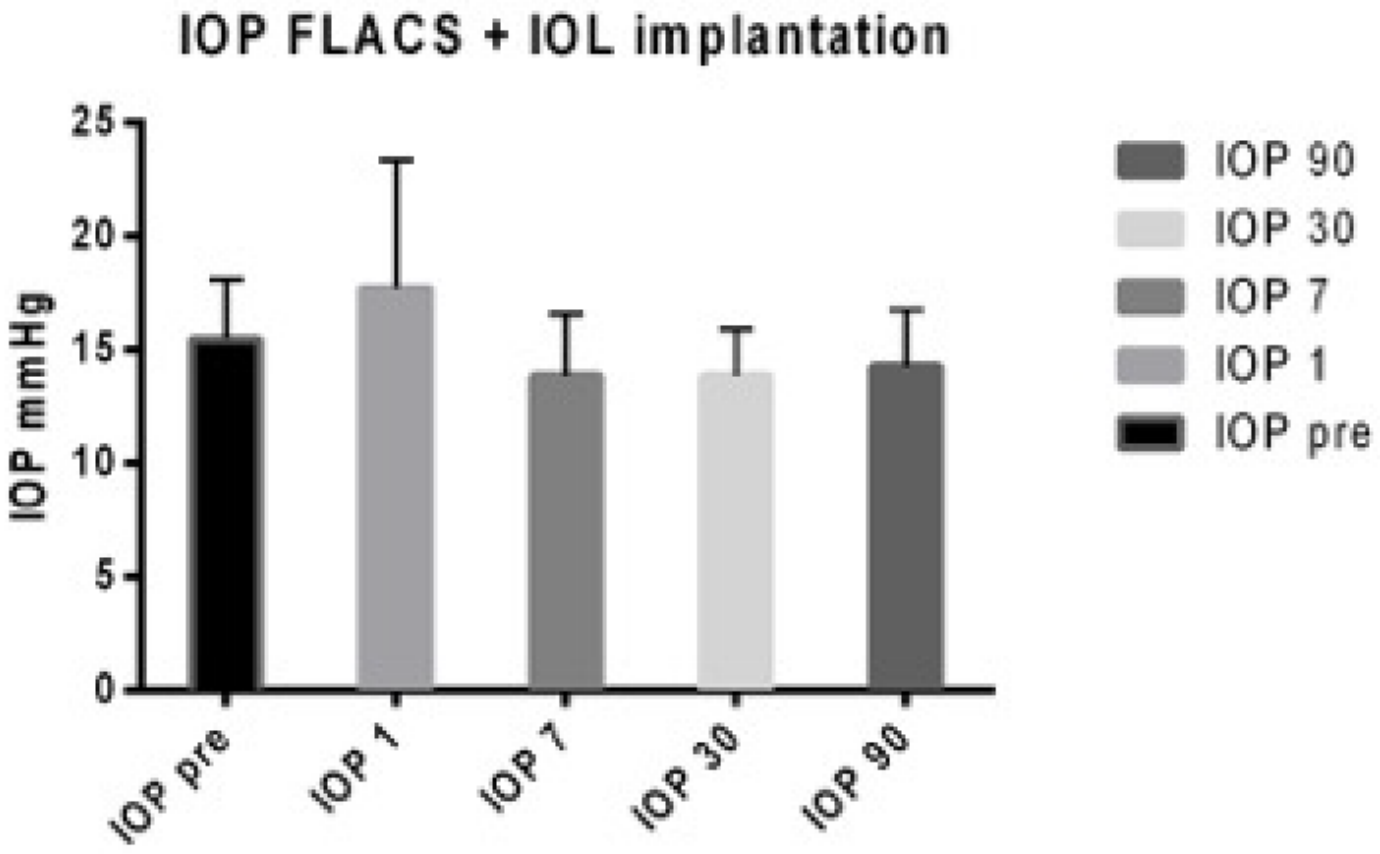

Figure 4

IOP in FLACS + IOL implantation alone before surgery and at days 1, 7, 30, and 90

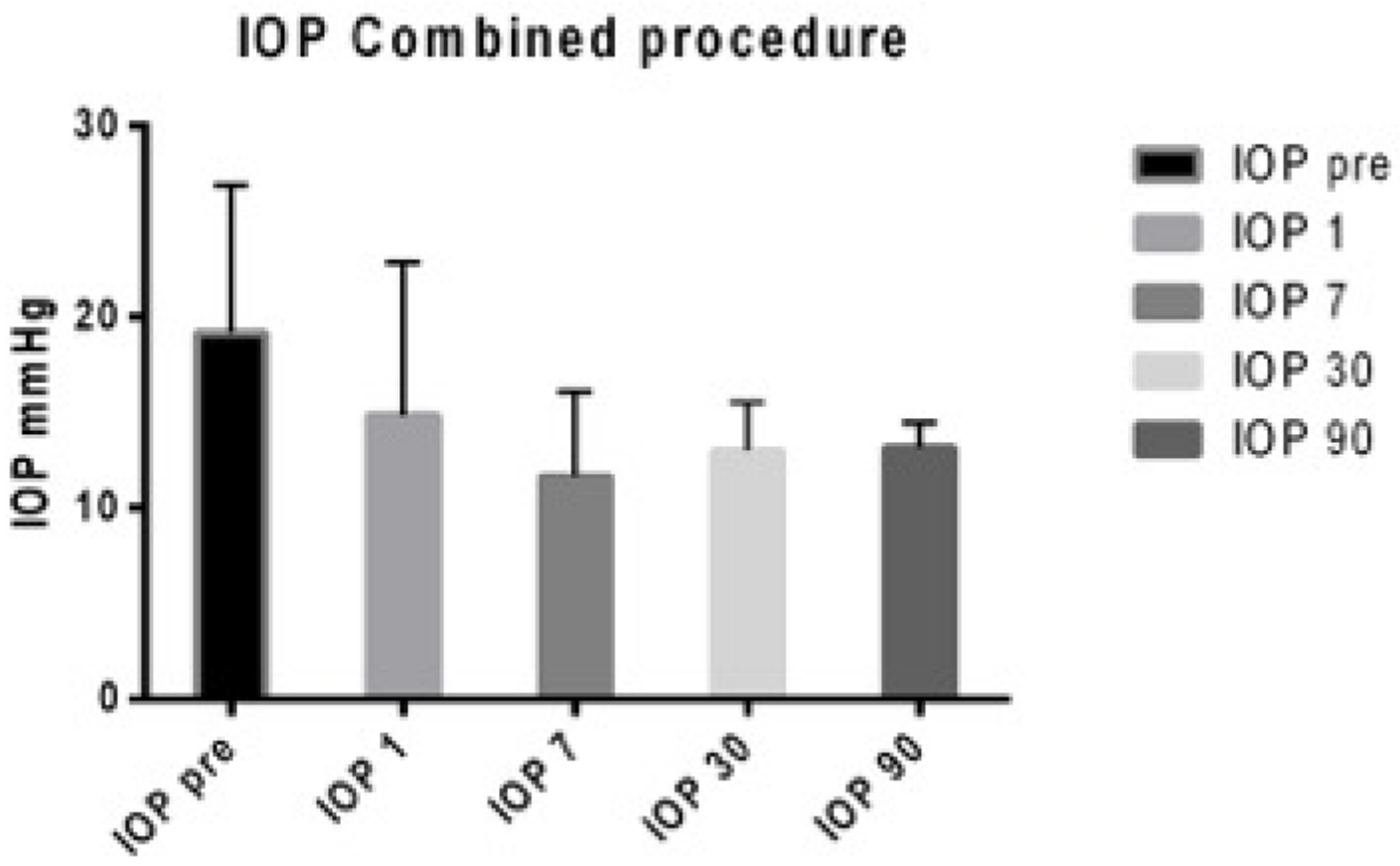

Figure 5

IOP in the combined procedure before surgery and at days 1, 7, 30, and 90

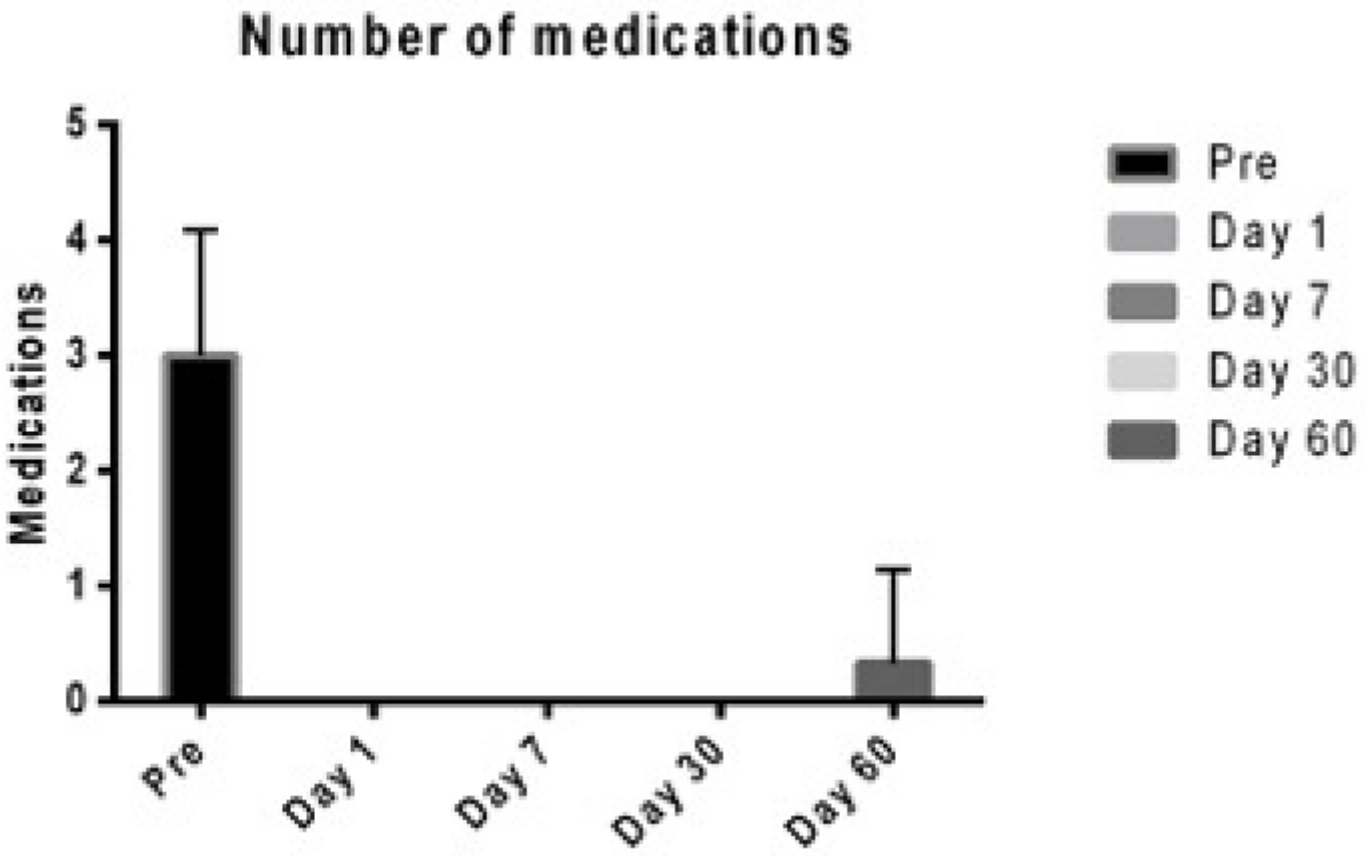

Figure 6

Number of medications in patients who underwent combined FLACS + glaucoma procedure

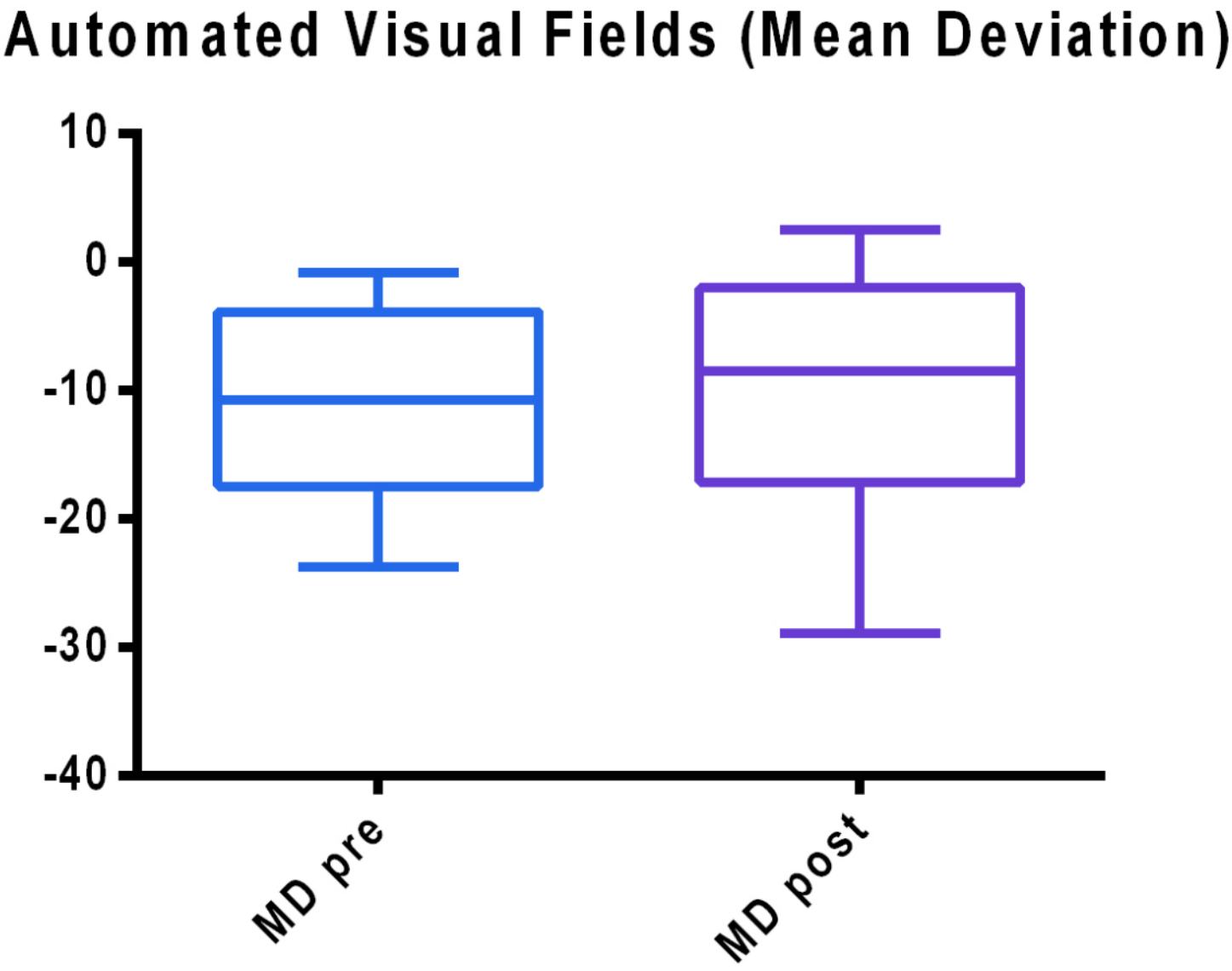

Figure 7

Visual Fields Mean Deviation before and after surgery in both groups