# Application of a new percutaneous multi-function pedicle locator in minimally invasive spine surgery

**Xiaojian Liu**
Jinzhou Medical University

**Hairun Liu**
Jinzhou Central Hospital

**Yushan Wang** ( Jean_2020@126.com )
Jinzhou Central Hospital

**Research Article**

**Keywords:** a new percutaneous multi-function pedicle locator, minimally invasive surgery, spine, pedicle screw placement, radiation exposure

**Posted Date:** March 31st, 2021

**DOI:** https://doi.org/10.21203/rs.3.rs-355366/v1

# Abstract

A new percutaneous multi-function pedicle locator was designed to be used for personalized three-dimensional positioning of a pedicle in minimally invasive spine surgery without computer-assisted navigation technology. This article instructed the method and advantages of using a new percutaneous multi-function pedicle locator in minimally invasive surgery of the spine. Based on the position of a pedicles suggested by CT and X-ray images of a patient, 6 lines and 2 distances were used to determine the puncture point of a pedicle screw, while 2 angles were used to determine the inserting direction of a pedicle guide needle from the patient's body surface. The result of application of the locator was roughly compared with that of the conventional freehand technique. The potential benefits of using the locator included enhancing surgical accuracy, reducing the operation time, mitigating the harmful intra-operative radiation exposure, saving the costs and shortening the learning curve of young orthopedists. It was hoped that more doctors and patients will benefit from it.


# Introduction

In recent years, with the vigorous development of spinal endoscopy, the conventional open spinal surgery has been gradually replaced by minimally invasive surgery, and percutaneous fixation and fusion has been a trend [1,2]. The accurate positioning of the pedicle is crucial in both conventional open approach and minimally invasive spinal surgery[3]. The angle of the pedicle can change due to the extroversion angle of the pedicle, the head or tail tilting, and even possible lateral curvature and rotation caused by serious degeneration, which may lead to difficulties in the accuracy of pedicle screw placement. This is why spinal surgery usually requires two-dimensional (2D) fluoroscopy assistance, and it is still not easy for the experienced orthopedic surgeons to ensure that screws can be placed accurately[4]. Many of the problems in spinal surgery occur in the process of pedicle screw misplacement[5]. Nowadays the accuracy of pedicle screw placement can be obtained with navigated robotic assistance[2,3]. But the navigated robotic assistance is too expensive to be widely used so far. To date, however, the individualized placement of pedicle screws based on the precise measurement of CT images has not yet been reported to be guided by specialized three-dimensional location instrument in minimally invasive spinal surgery.

In this study, a simple and practical instrument has been designed for minimally invasive surgery of the spine. It could provide a great help to improve the accuracy of screw placement or establishing channels in pedicle, shorten significantly the operation time, lower radiation exposure. In addition, it reduced the surgery cost. Moreover, it would be helpful for young orthopedists to shorten their learning curve by using this locator in most spinal surgery. The clinical application of the percutaneous multi-function pedicle locator has proven that it achieved the design goals.

# Materials And Methods

# The basic principles of designing percutaneous multi-function pedicle locator

The pedicle approach requires inserting percutaneously a guide needle into the pedicle in minimally invasive spinal surgery. But the percutaneous puncture point is not the vertical projection point of the pedicle on the skin. Because each pedicle has extroversion angle and head tilt or tail tilt angle, the puncture point on skin should be on the lateral side and head or tail side of the pedicle projection point on the skin. However, there are individual differences in the angles of each pedicle of spine, especially the angles of the head or tail tilting often vary with the curvature of the spine, and the sacral spine has the largest difference. So determining the appropriate point on skin to puncture and keeping the correct direction of guide needle along the pedicle during insertion are the crucial difficulties of the operation, which can be solved by pre-calculation on imaging materials and application of the percutaneous multi-function pedicle locator in surgery.

# The general introduction of locator

The structure of percutaneous multi-function pedicle locator was showed in Fig. 1A and Fig. 1B. It has been approved (https://www.cnpat.com.cn/, No. ZL201720026683.7) by China's national patent (Fig. 1C). Based on the anatomical features of the pedicle, the locator was designed to set two angles discretionarily. The locator was manufactured by Beijing Fule Technology Development Co., Ltd. China. It could be produced as a sterile disposable medical device. The informed consent about application of locator in minimally invasive spine surgery was obtained from all subjects. The approval from the Ethics Committee in Jinzhou Central Hospital of Liaoning Province was obtained in this study. All the methods are performed according to relevant institutional guidelines and regulations.

# Method for application of locator in pedicle approach

The method (pedicle approach) was applicable to percutaneous pedicle screw surgery, including spine fracture, spine fusion) and percutaneous vertebroplasty (PVP) or percutanouskyphoplasty (PKP). This type of operation requires the establishment of a "bone channel" through the pedicle to enter the vertebral body. A "bony channel" which enters the vertebral body through the pedicle has to be established parallelly to the upper and lower endplates of vertebral body. It is not interfered by the factors such as changes of body posture, patient size, spinal degeneration. It only depends on the individual differences of each vertebral body and the purpose of operation. Therefore, the same reference plane must be selected for different vertebral bodies in order to accurately establish a bony channel. Usually, the patient is in the prone position in spine surgery, so that the horizontal plane was selected as the reference plane. Applying the locator, it was very important to make sure the base of locator parallel to the ground (A level instrument was used to ensure that the locator base was level in our surgery). Then the vertical line of the locator base plane was considered as the reference to set the head and tail tilting angles.

*1. Determination of parameters based on X-ray and CT images before operation* The method of 622-1 means that one point (The percutaneous puncture point) was determined by 6 lines, 2 angles and 2 distances.

There were 4 lines based on images, including the linea mediana posterior (M*l*) and the pedicle channel line (PC*l*) in cross-sectional CT image through pedicles (Fig. 2A), the line through the needle entry point on pedicle (PU*l*) which paralleled with the upper edge of vertebral body (terminal plate of vertebral body) and a horizontal line that passed through the needle entry point on pedicle (H*l*). Both PU*l* and H*l* were in lateral X-ray image (Fig. 2B).

*The other 2 lines* were marked on the body surface of the patient, including the linea mediana posterior (**ML**, both M*l* and ML are in the sagittal aspect of the body) and the horizontal line (**HL**, it was same as H*l* in lateral X-ray image) through the projections of bilateral pedicles on the body surface (It was marked with the assistance of X-ray fluoroscopy) (Fig. 2C).

The 2 angles included the extroversion angle of a pedicle (named by Angle α) which was the included angle between M*l* and PC*l* through the pedicle in CT image (Fig. 2A) and the head or tail tilting angle (named by Angle β) which was the included angle between PU*l* and H*l* in lateral X-ray image (Fig. 2B).

The 2 distances were side opening distance (SD) and the head or tail tilting distance (H/TD). SD in CT image was the distance from the point where the line M*l* passed through skin to the point where the line PC*l* passed through skin. While on the patient's body surface, SD was the distance from the percutaneous puncture point to the line ML (Fig. 2A). H/TD in X-ray image was the distance from the point where the line PU*l* passed through skin to the point where the line H*l* passed through skin While on the patient's body surface, H/TD was the distance from the percutaneous puncture point to the line HL, Fig. 2B).

The percutaneous puncture point "P" on the patient's body surface can be determined by the above-mentioned "lines" and "distances" (Fig. 2D). The Angle α and β were

# 2. The steps of using locator

After measurement of the above-mentioned "lines", "angles" and "distances", the steps of using locator in a surgery were as the followings.

*. Posture* Prone position was adopted. Lateral position could be adopted for special needs.

*. Mark the lines* ML *and HL on the patient's body surface* The line HL was marked with the aid of X-ray fluoroscopy.

*. Mark the percutaneous puncture point "P" on the patient's body surface according to SD (the side opening distance) and H/TD (the head or tail tilting distance)* Mark a dashed line(L) that was parallel to ML and SD cm away from ML, then mark a point (The percutaneous puncture point "P") above HL on the

line L to make it HD cm away from HL(If the pedicle was tilting to head) or mark it below HL on the line L to make it TD cm away from HL (If the pedicle was tilting to tail, Fig. 2D)

Graph **a** showing Line M*l* and PC*l*, distance SD and angle α in cross–section CT image; Graph **b** showing Line PU*l* and H*l*, distance H/TD and angle β in lateral X-ray image. Graph **c** showing Line ML and HL on body surface showed by a X-ray image. Graph **d** showing Line ML and HL, distance SD and H/TD and point P on body surface. Graph **e** showing Angle α and β showed on the two scale dials of locator. Graph **f** showing the locator in use. M*l* and ML = linea mediana posterior; PC*l* = pedicle channel line; PU*l* = needle entry point on pedicle; H*l* and HL = horizontal line; SD = side opening distance; H/TD = head or tail tilting distance; Angle α = extroversion angle; Angle β = head or tail tilting angle; P = percutaneous puncture point.

*. Set the angles on the locator* Adjust the hands position of the dials to Angle α and Angle β respectively (Fig. 2E), and place the locator horizontally on the back of patient by adjusting the screws at the bottom of locator with the aid of a level instrument and make the longitudinal axis of locator overlap or parallel to ML.

*. Placement of pedicle guide needle* Place a guide sleeve into the locator, and align the distal end of sleeve to the percutaneous puncture point “P” on the body surface of patient. Then put a guide needle into the sleeve, and insert percutaneously the guide needle into the dorsal bony cortex of the pedicle (Fig. 2F).

*. The steps from  to  were repeated until all pedicle guide needles were placed.*

*. Confirm the accuracy of pedicle guide needles placement* Take a positive and lateral of X-ray fluoroscopy to check whether all pedicle guide needles were placed accurately. If some guide needles are found to be unsatisfactory, correct them.

*. Continue to perform the remaining operation.*

*Precautions in use of locator*

1. 1. ML and HL must be marked accurately on the body surface of patient.
2. 2. The longitudinal axis of locator must overlap or be parallel to ML.
3. 3. The locator can’t be tilted left or right in use.
4. 4. If the patient has a scoliosis or rotation, the camber angle can be adjusted appropriately, so that the guide needles of different segments are kept in a longitudinal line.

# Statistical analysis

Statistical analyses were performed using SPSS. The numerical data are presented as mean and standard deviation.

## Results And The Representative Cases

In Jinzhou Central Hospital from May to December 2018, the locator was used in 9 cases of spinal fracture, 2 cases of spinal fusion, and 15 cases of vertebral body forming. The average patient age was 64.42 ± 11.16 years old (from 39 to 85), and 53.85% (14/26) were female. The average body mass index was 24.7 ± 3.5 kg/$m^2$. In the initial stage of use, due to the substandard mark and a big error of the locator position, the position of the guide needles needed to be readjusted in individual cases. Finally, all guide needles were accurately placed into the pedicles. In the above-mentioned minimally invasive surgeries of the spine, it took 3.04 ± 1.54 min to place each guide needle into the pedicle by using locator, and required 2D fluoroscopy 1.42 ± 0.58 times to make sure the right position of all guide needles. The positioning time without the locator was generally 10 ~ 35 min for each guide needle without a navigated robotic assistance, and 2D fluoroscopy was required 2 ~ 8 times for positioning each guide needle. Figure 3 and Fig. 4 showed the representative cases of using locator.

## Discussion

Many problems such as muscle damage, blood loss and post-operative pain in conventional open has prompted the need for innovation and allowed the development of minimally invasive spine surgery. With the rapid development of modern medicine and actual needs, minimally invasive surgery has gradually occupied a dominant position in many spinal surgeries. Originally, screws were placed via the conventional freehand technique and 2D fluoroscopy, which presents the risk of misplacement and excessive radiation exposure. The application of navigation and robotic systems in minimally invasive spine surgery has significantly increased the accuracy of pedicle screw placement and reduced the radiation exposure of doctor team and patients [6]. However, the extremely expensive computer-assisted navigation technology is unaffordable for a great number of hospitals and many patients. Moreover, these systems may fail under certain unexpected circumstances.

In the current study, the structure of the percutaneous multi-function pedicle locator was simple. It could be mass-produced as a sterile disposable medical device by the manufacturer and was only used outside the patient's body, with very low cost and much safety. The design of the locator was based on the position of the pedicles suggested by the routine preoperative CT and X-ray images of a patient. Several lines, two distances and two angles were used ingeniously to determine the puncture position and inserting direction of a pedicle guide needle from the patient's body surface, in which the operation was not complicated. Results suggested that the application of the percutaneous multi-function pedicle locator in minimally invasive spinal surgery could greatly reduce the difficulty of placing guide needle and increase accuracy. Different from the freehand operation in minimally invasive spine surgery, it was able to allow confirming the placement of all the pedicle guide needles with X-ray fluoroscopy in an operation at one time, which greatly shortened the operation time and mitigated much of the harmful radiation exposure to which the patient, surgeons, and ancillary operating room staff were subjected. Additionally, it markedly saved the cost of operation compared with navigated robot-assisted guidance. Therefore, it is easy to carry out minimally invasive spinal surgery using this locator in various hospitals. Moreover,

using locator could shorten the learning curve for young orthopedists to position precisely pedicle in minimally invasive spinal surgery.

In addition, our locator was also applicable to intervertebral foramen microscopic surgery (Process articular superior approach), however, the method was slightly different.

In order to ensure the accuracy of pedicle positioning by using the locator in minimally invasive spine surgery, several precautions mentioned in the method were very important. As long as the lines, angles and distances required for pedicle positioning and the position of locator are accurate, a guide needle can be placed accurately into the pedicle. Among them, keeping the accuracy of the position of the locator in use is the most problem. Because the back body surface of the patient on the operating bed is not necessarily level, it is necessary to adjust the level of the locator in use with the help of a level instrument.

The disadvantage of the design of our locator was that there was no a level instrument in the structure of locator, that was why an additional level instrument was required to ensure the accuracy of a reference plane to the locator. Therefore, we imagine designing a locator with a level instrument on the current basis to make the operation easier and more convenient.

In brief, the percutaneous multi-function pedicle locator has been proven to achieve the original goal of design, that was, the orthopedic surgeons are able to quickly and safely complete personalized three-dimensional positioning of the pedicle in minimally invasive spine surgery without computer-assisted navigation technology. It is hoped that the orthopedic surgeons can perform minimally invasive spine surgery with the help of our locator when there is no expensive computer-assisted navigation system.

# Declarations

**Authors' contributions:** YW conceived of the project and designed the locator. YW and HL applied the locator in surgery. XL performed statistical analysis and prepared figures. XL and YW interpreted the results. XL drafted and revised the manuscript. All authors read and approved the final manuscript.

**Acknowledgements:** Not applicable.

**Competing Interests**: The authors declare that they have no conflicts of interest.

**Consent for publication:** All authors approved the final draft. No other consents are necessary for this study.

**Data Statement:** All data generated or analyzed during this study are included in this published article.

**Funding:** There was no funding for this study.

# References

1 Peng, H. *et al.* Minimally invasive spine surgery decreases postoperative pain and inflammation for patients with lumbar spinal stenosis. *Exp Ther Med* **18**, 3032-3036, doi:10.3892/etm.2019.7917 (2019).

2 Vardiman, A. B. *et al.* Pedicle screw accuracy in clinical utilization of minimally invasive navigated robot-assisted spine surgery. *J Robot Surg*, doi:10.1007/s11701-019-00994-3 (2019).

3 Wallace, D. J., Vardiman, A. B., Booher, G. A., Crawford, N. R. & Riggleman, J. R. Navigated robotic assistance improves pedicle screw accuracy in minimally invasive surgery of the lumbosacral spine: 600 pedicle screws in a single institution. *The international journal of medical robotics + computer assisted surgery : MRCAS*, e2054, doi:10.1002/rcs.2054 (2019).

4 Ghasem, A., Sharma, A., Greif, D. N., Alam, M. & Maaieh, M. A. The Arrival of Robotics in Spine Surgery: A Review of the Literature. *Spine (Phila Pa 1976)* **43**, 1670-1677, doi:10.1097/brs.0000000000002695 (2018).

5 Gautschi, O. P., Schatlo, B., Schaller, K. & Tessitore, E. Clinically relevant complications related to pedicle screw placement in thoracolumbar surgery and their management: a literature review of 35,630 pedicle screws. *Neurosurgical Focus* **31**, doi:10.3171/2011.7.focus11168 (2011).

6 Vaishnav, A. S., Othman, Y. A., Virk, S. S., Gang, C. H. & Qureshi, S. A. Current state of minimally invasive spine surgery. *J Spine Surg* **5**, S2-S10, doi:10.21037/jss.2019.05.02 (2019).

# Figures


**Figure 1**

Percutaneous multifunctional pedicle locator. Areas indicated by an arrow are the base parts of locator, and areas indicated by an dotted arrow is the longitudinal axis of the base part; c Graph showing the patent certificate of locator.

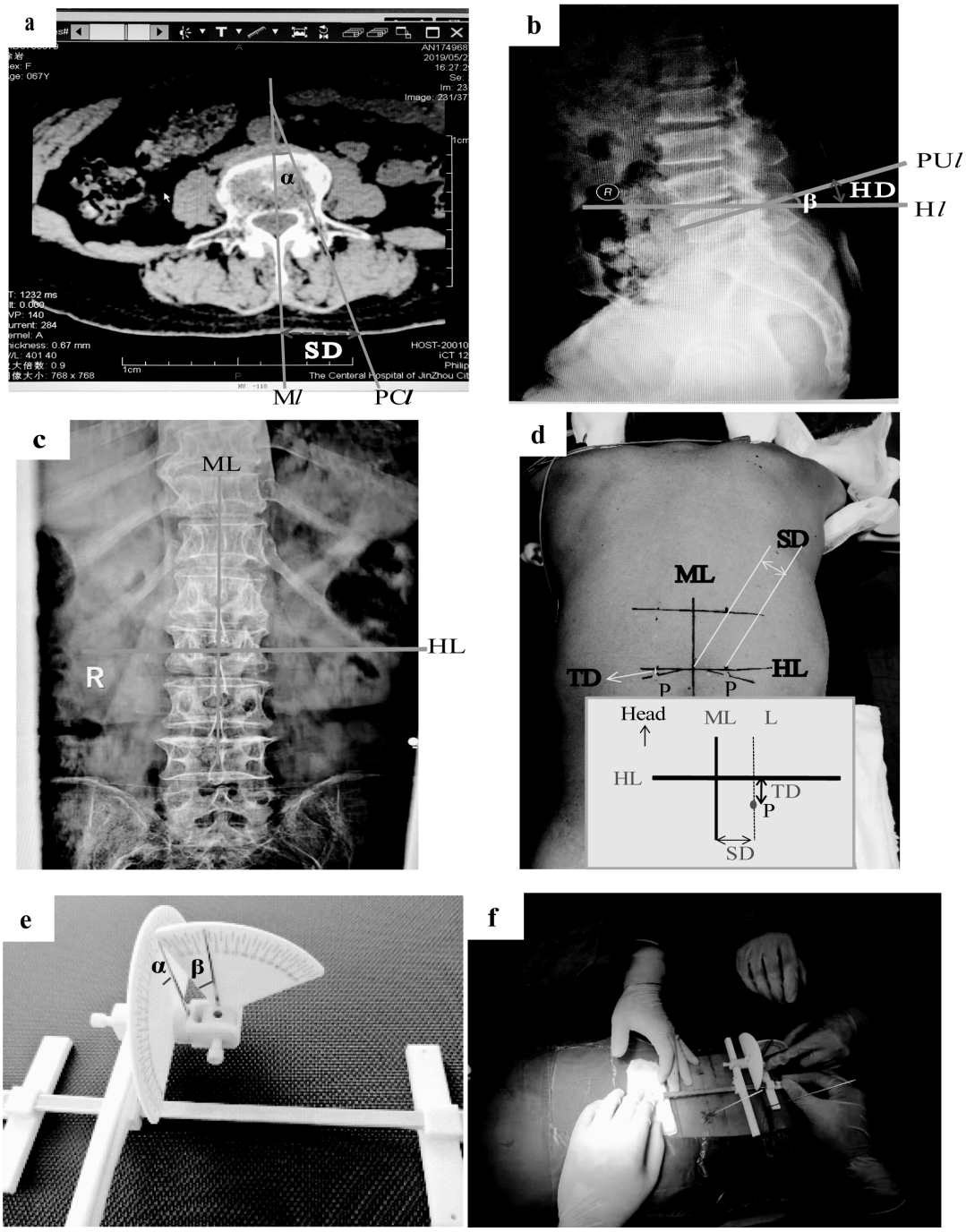


## Figure 2

Four Lines, two distances and two angles for application of locator in pedicle approach.

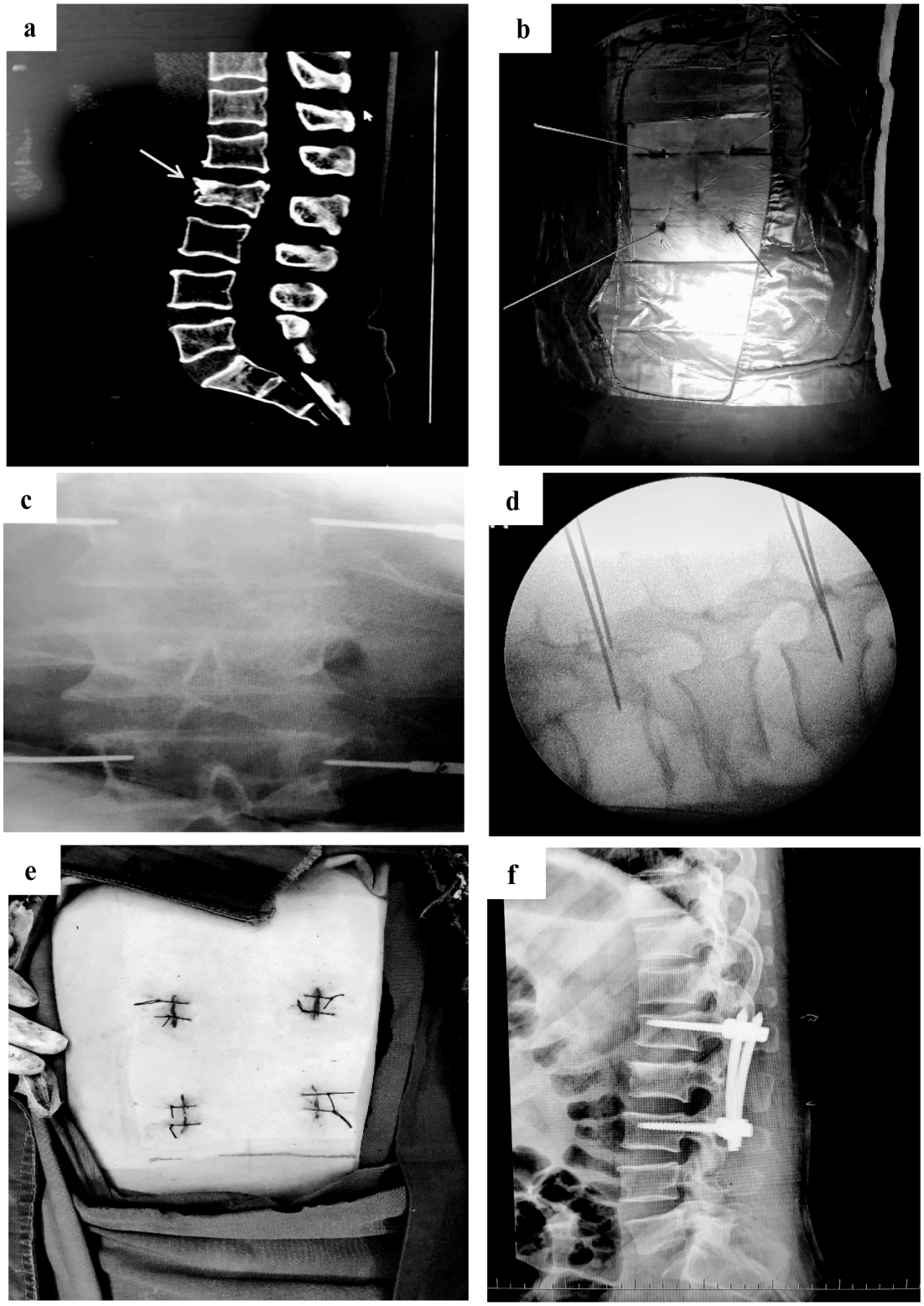


## Figure 3

Reduction of lumbar 2 vertebral compression fracture with percutaneous pedicle screw internal fixation by using locator. Graph a showing a CT image of lumbar 2 vertebral compression fracture. Graph b showing that Kirschner guide needles were inserted into the pedicles of both sides of the lumbar 1 and 3 guided by the locator. Graphs of c and d show that the accuracy of pedicle guide needle placement was

confirmed by 2D fluoroscopy. Graph e showing the closed incisions. Graph f showing DR image of postoperative review.

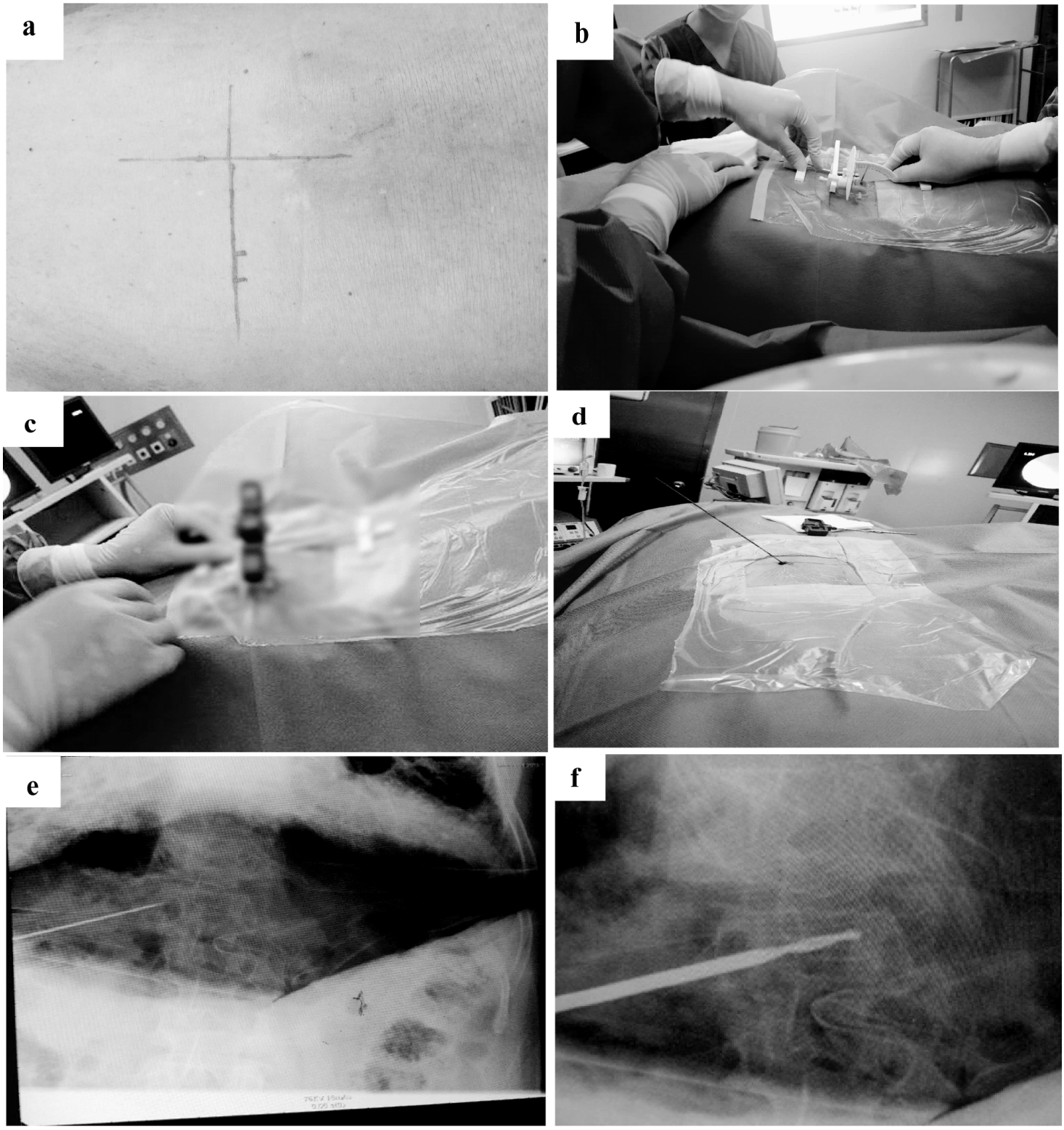


**Figure 4**

Percutaneous kyphoplasty by using the locator. Graph a showing the patient was in the prone position. ML, HL and the percutaneous puncture point “P” were marked according to the data measured in the images before the operation. Graph b showing that the locator was placed parallelly to ML after adjusting

the positions of the hands on dials at the angles according to the preoperative measurement of extraversion angle α and tail tilting angles β. Graphs of c and d show that a working sleeve was placed in the locator, making the distal end of the sleeve aligning with the puncture point “P”, then a guide needle was inserted along the sleeve till the pedicle bone puncture point and planted into the pedicle. Graph e showing that the position of guide needle was confirmed by 2D fluoroscopy. Graph f showing that a saccule was placed through the working channel and the fractured vertebral body was expanded with an appropriate pressure. Then bone cement was filled in the vertebral body.