# Coronavirus Disease 2019 (COVID-19) in Italy: Double reading of chest CT examination

**Reginelli Alfonso**
Universita degli Studi della Campania Luigi Vanvitelli

**Grassi Roberto** ( roberto.grassi@unicampania.it )
Universita degli Studi della Campania Luigi Vanvitelli

**Feragalli Beatrice**
Universita degli Studi Gabriele d'Annunzio Chieti e Pescara

**Belfiore Maria Paola**
Universita degli Studi della Campania Luigi Vanvitelli

**Montanelli Alessandro**
Azienda Socio Sanitaria Territoriale Bergamo Est

**Patelli Gianluigi**
Azienda Socio Sanitaria Territoriale Bergamo Est

**La Porta Michelearcangelo**
Ospedale Policlinico San Martino

**Urraro Fabrizio**
Universita degli Studi della Campania Luigi Vanvitelli

**Roberta Fusco**
Istituto Nazionale Tumori IRCCS Fondazione Pascale

**Granata Vincenza**
Istituto Nazionale Tumori IRCCS Fondazione Pascale

**Petrillo Antonella**
Istituto Nazionale Tumori IRCCS Fondazione Pascale

**Giacobbe Giuliana**
Universita degli Studi della Campania Luigi Vanvitelli

**Russo Gaetano Maria**
Universita degli Studi della Campania Luigi Vanvitelli

**Sacco Palmino**
Azienda Ospedaliera Universitaria Senese

**Grassi Roberta**
Universita degli Studi della Campania Luigi Vanvitelli

**Cappabianca Salvatore**
Universita degli Studi della Campania Luigi Vanvitelli

**Research article**

**Keywords:** COVID-19, Chest CT, structured report, double reading, radiological signs

**Posted Date:** June 26th, 2020

**DOI:** https://doi.org/10.21203/rs.3.rs-36750/v1

# Abstract

OBJECTIVE

To assess the performance of the second reading of chest Compute Tomography (CT) examinations by expert radiologists in patients with discordance between the reverse transcription real-time fluorescence polymerase chain reaction (RT-PCR) test for COVID-19 viral pneumonia and the first CT report.

MATERIALS AND METHODS.

Three hundred seventy-heigth patients were included in this retrospective study (121 women and 257 men; 71 years of median age - range, 29–93 years) subjected to RT-PCR test for suspicious COVID-19 infection. All patients were subjected to CT examination in order to evaluate the pulmonary disease involvement by COVID-19. CT images were reviewed first by two radiologists who identified COVID-19 typical CT patterns and then reanalyzed by anoter two radiologists using a CT structured report for COVID-19 diagnosis.

RESULTS.

The median temporal window between RT-PCRs execution and CT scan was 0 days with a range of [-9, 11] days. RT-PCR test was resulted positive in 328/378 (86.8%). Discordance between RT-PCR and CT findings for viral pneumonia was revealed in 60 cases. The second reading changed the CT diagnosis in 16/60 (26.7%) cases contributing to increase the concordance with the RT-PCR. Among these 60 cases, 8 were false negative with positive RT-PCR, and 36 were false positive with negative RT-PCR. Sensitivity, specificity, positive predictive value and negative predictive value of CT were respectively of 97.3%, 53.8%, 89.0%, and 88.4%.

CONCLUSION.

Double reading of CT could increase the diagnostic confidence of radiological interpretation in COVID-19 patients. Using expert second readers could reduce the rate of discrepant cases between RT-PCR results and CT diagnosis for COVID-19 viral pneumonia.


# Introduction

Coronavirus disease (COVID-19) is an infectious disease caused by a newly discovered coronavirus. Coronaviruses are a large family of viruses transmitting between animals and people that cause illness ranging from the common cold to more severe diseases such as Middle East respiratory syndrome (MERS-CoV) and severe acute respiratory syndrome (SARS-CoV). COVID-19 actully continues its spread throughout the world [1–2].

The COVID-19 diagnosis is established using reverse transcription real-time fluorescence polymerase chain reaction (RT-PCR) test performed on the respiratory tract or blood specimens. RT-PCR test is the

most reliable test for COVID-19 infection also if several study evidenciated the high false positives rate of this test and a sensitivity of 60–70% [2].

Recent results have revealed the efficiency of some imaging methods, including chest radiographs (X-rays) and chest computed tomography (CT) scans, in the management of COVID-19 disease. Both chest X-ray and CT can evaluate the polmonuray involvement by abnormality that could be linked to the COVID-19 infection. However, several radiological societies do not recommend chest X-ray or CT for the screening or diagnosis of COVID-19 [3–6].

Chest X-ray examination, although not offering highly specific findings, provides a first overview of the patients, especially in the emergency room, and can direct the differential diagnosis towards other infection that determine pulmonary parenchymal involvement, other than COVID-19 infection [8]. Typical radiological pattern on chest X-ray was patchy or diffuse asymmetric airspace opacities. [7–8]. Radiologists cannot make a safe diagnosis of COVID-19 disease based on chest X-ray alone. Bandirali et al. [7] in their study on 170 patients evidentiated that on 100/170 X-rays there were pulmonary abnormalities highly suspicious for COVID-19 pneumonia.

CT examination was used to evaluate the grade and the extension of the viral pneumonia by COVID-19 [9–10]. Radiologists focus on main CT findings (ground-glass opacity, consolidation) and lesion distribution (bilateral, multilobar). Bilateral distribution of ground-glass opacities (GGOs), with or without consolidation, in peripheral lungs was reported as a characteristic feature of COVID-19 [9–11]. However, CT can share some similar imaging features between COVID-19 and other types of pneumonia, making differentiation difficult [12–18].

The aim of this study was to assess the performance of the second reading of chest CT using a structured report in patients with discordance between RT-PCR test and the first CT diagnosis for COVID-19 viral infection.

## Materials And Methods

# Patient Characteristics

“Bergamo Est” Institutional Review Institute (IRB) approved the study and renounced the written informed consent for this retrospective study, considering the ongoing epidemic emergency, which assessed the unidentified data and did not involve risks potential for patients.

Three hundred seventy-heigth patients were included in this retrospective study (121 women and 257 men; 71 years of median age - range, 29–93 years) subjected to RT-PCR test for suspicious COVID-19 infection, between February 23, 2020, and March 5, 2020. The virus investigation for COVID-19 diagnosis was performed by the current gold standard test in the clinical laboratory of ASST Bergamo Est (Seriate, Italy).

Patient characteristics were illustrated in Table 1.

Table 1
Demographic Characteristics and CT diagnosis of 378 Patients with confirmed Coronavirus Disease (COVID-19) at RT-PCR test

| **Age (y)** | **Positive for COVID-19** | | **Negative for COVID-19** | | **p value** |
|---|---|---|---|---|---|
| Median | 70.0 | | 77.5 | | > 0.05 |
| Range | 29–93 | | 32–89 | | |
| | **Tot** | **%** | **Tot** | **%** | **p value** |
| **Sex, no. (%) of patients** | | | | | |
| Male | 226 | 68.9 | 31 | 62.0 | **0,01** |
| Female | 102 | 31.9 | 29 | 58.0 | |
| **CT diagnosis** | | | | | |
| Positive | 292 | 97.3 | 36 | 46.2 | **<<0.001** |
| Negative | 8 | 2.7 | 42 | 53.8 | |
| **Cases with concordance between RT-PCR and CT diagnosis** | | | | | |
| Median value of Temporal Windows between RT-PCR and CT execution | 0 | | 0 | | > 0.05 |
| Range of Temporal Windows between RT-PCR and CT execution | -9–11 | | -1–4 | | |
| **Cases with discordance between RT-PCR and CT diagnosis** | | | | | |
| Median value of Temporal Windows between RT-PCR and CT execution | 0 | | 0 | | > 0.05 |
| Range of Temporal Windows between RT-PCR and CT execution | -2–4 | | -8–4 | | |
| **CT Findings** | | | | | |
| Presence of GGOs with consolidation | 2 | | 12 | | **> 0.05** |
| Presence of GGOs without consolidation | 6 | | 20 | | |
| Presence of consolidation without GGOs | 1 | | 4 | | |

Note. p value was evaluated for continuous variable by Mann Whitney test and by Chi square test with Yates correction for categorical ones. The p values reported in bold were considered significant.

# CT Technique and analysis

A Chest CT scan was performed at the time of patient admission in the hospital using two CT scanners (CT 128 slice Ingenuity of Philips, Amsterdam - Netherlands, and CT 128 slice Optima 660 of GE Healthcare, Chicago, Illinois, United States). Table 2 reports the Chest CT protocol parameters for both scanners.

Table 2
CT findings considered for assignment of the diagnostic confidence level.

| Diagnostic confidence level | CT characteristics |
|---|---|
| high diagnostic confidence level | bilateral multifocal GGO with predominantly peripheral distribution associated or not with septal thickening (crazy paving) and/or consolidations; multifocal GGO of rounded morphology associated or not with crazy paving and/or consolidations; multifocal GGO associated with findings of organizing pneumonia. |
| intermediate diagnostic confidence level | GGO with diffuse distribution associated or not with crazy paving and/or consolidations; bilateral multifocal GGO and/or consolidations without a prevalent peripheral distribution and without rounded morphology; unilateral GGO with or without consolidation |
| low diagnostic confidence level | isolated small areas of GGO and/or consolidations with non-rounded morphology were included in the low confidence level |
| Negative for COVID-19 | cases without the described alterations and with one or more of the following alterations were considered indicative of other diagnosis: isolated lobar or segmental consolidations, presence of solid or caveated nodules, presence of micro-nodules (centro-lobular micro-nodules and “tree in bud” pattern), smooth thickening of the interlobular septa with pleural effusion |

Every chest CT examination was evaluated first by two double-blind radiologists with 10 and 7 years’ experience of chest CT (A.M. and G.P. in the midst of the pandemic), respectively. Radiologists observed, blinded to RT-PCR results, the main CT findings suggestive for COVID-19 disease: localization and distribution of GGO and consolidations, crazy paving pattern, presence of nodules.

RT-PCR results were compared to CT report, and other two radiologist blinded each other (B.F. and A. R.) reanalyzed the cases with discordance between CT diagnosis and RT-PCT test using a structured report for COVID-19 disease defined by Italian Society of Medical Radiology and Interventional Radiology (SIRM, Milan, Italy) in collaboration with the Exprivia Healtcare company (Bari, Italy) [19]. In the second reading, the radiologists, in addition to reviewing the CT, expressed a diagnostic confidence rating on a scale of 1 to 3 (low, medium, high). Table 2 reports the CT findings considered for assignment of the diagnostic confidence level.

# Statistical Analysis

Continuous data were expressed with median value and range while categorical ones are reported as counts and percentages. Mann Whitney test and Chi-square test was was used to verify differences

respectively between groups of continuous variables and between percentage values among groups.

Weighted κ values were used to evaluate inter-reader agreement of the confidence scale. κ coefficients in the range of 0.81-1.0 indicated excellent agreement; those in the range of 0.61–0.80, substantial agreement; those in the range of 0.41–0.60, moderate agreement; those in the range of 0.21–0.40, fair agreement; and those in the range of 0.00-0.20, poor agreement.

P-value < 0.05 was considered significant. Statistical analysis was effected using the Statistics Toolbox of Matlab R2007a (The Math-Works Inc., Natick, MA, United States).

# Results

The median temporal window between RT-PCRs execution and CT scan was 0 days with a range of [-9, 11] days. 335/378 (88.6%) cases subjected to the RT-PCR and CT scan in a temporal window of ± 1.0 days. 35/378 (9.3%) patients repeated the RT-PCR test: among these 35 cases, 29/35 (82.9%) resulted negative at first RT-PCR test were then resulted positive at the second test.

Discordance between RT-PCR test and CT findings was revealed in 60 cases (see Fig. 1). The discordant cases were prevalently negative at RT-PCR 43/60 (71.7%). Of these 60 cases, a second RT-PCR testing was required for 12 (20%) patients.

The second CT reading, using the structured report, changed the CT diagnosis in 16/60 (26.7%) cases contributing to increase the concordance with the RT-PCR test: 7 cases resulted negative for viral pneumonia while 9 cases resulted positives for viral pneumonia. Among these 60 cases, 15 had negative CT diagnosis for COVID-19, while 45 had a positive diagnosis at CT for viral pneumonia: 8/15 were false negatives with positive RT-PCR, and 36/45 were false positives with negative RT-PCR. Sensitivity, specificity, positive predictive value and negative predictive value of CT were respectively of 97.3%, 53.8%, 89.0%, and 88.4%.

The diagnostic confidence grade (CDG), in the 45 cases with suspicious CT for COVID-19 infection, was in 14/45 (31.1%) equal to 2 and in 31/45 (68.9%) equal to 3. The diagnostic confidence grade (CDG), in the 15 cases with negative CT diagnosis for COVID-19 was in 4/15 (26.7%) equal to 1 while for remant 14 cases the described alterations were considered indicative of other diagnosis.

Inter-reader agreement of diagnostic confidence between the radiologists ranged from substantial to excellent (k range, 0.66–0.94).

The main CT findings, among 45/60 patients with suspicious CT for COVID-19 infection, were GGOs (40/45, 88.9%) with distribution multifocal and diffuse in 21/40 (52.5%) cases, multifocal/patching in 13/40 (32.5%) (Figs. 2 and 3) and monofocal in 6/40 (Fig. 4) (15.0%). In 10/45 (22.2%) cases was verified crazy paving pattern (Fig. 5). Often the disease was peripheral (13/45, 42.2%). Consolidations were present in 19/45 (33.3%) cases.

# Discussion And Conclusions

Several studies from China have reported that on chest CT can be releved souspicious radiological signs for COVID-19 viral infection notwithstanding RT-PCR test was resulted negative [10]. When present, the findings of COVID-19 on CT (notably peripheral ground-glass opacities) are sensitive but not specific for coronavirus; other pneumonias resemble COVID-19, particularly viral and Pneumocystis jirovecii pneumonia, cryptogenic organizing pneumonia, and acute lung injury from drug toxicity, hypersensitivity, and autoimmune diseases, to name a few pathologies. Moreover, CT can be normal in early illness, and after each potentially infected patient is scanned, the machine must be completely disinfected. Therefore, CT is not recommended for COVID-19 screening. Although, neither chest CT scans nor X-rays are currently recommended to diagnose COVID-19, CT is used in patients with acute respiratory symptoms to assess the lungs disease involvement [3–6].

In this manuscript, we assessed the performance of the second reading of chest CT using a structured report in patients with discordant findings between RT-PCR test and the first CT diagnosis for COVID-19 viral pneumonia. We reported in a sample of 378 patients with suspicious COVID-19 infection, discordance between RT-PCR and CT findings in 60/378 (15.9%) cases.

The second reading, and then the use of a structured report for COVID-19 diagnosis, changed the CT diagnosis in 16/60 (26.7%) cases contributing to increase the concordance with the RT-PCR. Among these 60 cases, we reported 8 false negatives with positive RT-PCR and 36 false positives with negative RT-PCR. Therefore, despite the sensitivity and the positive predictive value were high in our population with high pretest disease probability, the specificity was low (53.8%) linked to the question that CT radiological patterns for COVID-19 were similar to those of other infections. The main CT findings, among 45/60 patients with suspicious CT diagnosis for COVID-19 viral pneumonia, were GGOs with distribution multifocal and diffuse or multifocal/patching.

Our findings were in accordance with other results reported in the literature. Sensitivities and specificities values of chest CT examination in the identification of COVID-19 viral infection was vary variable: from 60–98% and from 25–53%, respectively [20–24]. This variability could be linked to the studies retrospective nature. Moreover, althout chest CT demonstrated an high positive predictive value (92%) to identify COVID-19 disease, the reported negative predictive was low (42%) [21]. Ai et al. [24] testified that the chest CT sensitivity in souspicious COVID-19 patients was 97% considering positive RT-PCR test. Considering all cases with negative RT-PCR test, 308/413 (75%) of patients had positive chest CT findings. These findings suggest that CT may not be an adequate screening method in early phases of the COVID-19 disease.

The main limitation of the present study is the nature retrospective and monocentric of the study. Moreover, the study was conducted on a population with a high pretest probability of COVID-19 infection.

In conclusion, double reading of CT could increase the diagnostic confidence of radiological interpretation in COVID-19 patients in a pandemic area. Using second readers and a structured report for

COVID-19 diagnosis could reduce the rate of discrepant cases between RT-PCR result and CT diagnosis for COVID-19 viral pneumonia.

# Declarations

*Institutional review board statement*: “Bergamo Est” Institutional Review Institute (IRB) approved the study

and renounced the written informed consent for this retrospective study, considering the ongoing epidemic emergency, which assessed the unidentified data and did not involve risks potential for patients.

*Consent for publication*: Consent for publication was received.

*Competing interests:* The authors declare that they have no competing interests.

*Funding*: No funding.

*Authors' contributions*: All authors equally contributed at the investigations and to the writing of the

manuscript.

*Availability of data and materials*: No additional data are available.

# References

1. World Health Organization website. Middle East respiratory syndrome coronavirus (MERS-CoV). . Accessed March 21, 2020.
2. World Health Organization website. Naming the coronavirus disease (COVID-2019) and the virus that causes it. . Accessed March 21, 2020.
3. ACR Recommendations for the Use of Chest Radiography and Computed Tomography (CT) for Suspected COVID-19 Infection. American College of Radiology, 11. Mar. 2020, ACR. https://www.acr.org/Advocacy-and-Economics/ACR-Position-Statements/Recommendations-for-Chest-Radiography-and-CT-for-Suspected-COVID19-Infection. Accessed March 21, 2020.
4. COVID-19 Updates. Ranzcr.com. 2020. https://www.ranzcr.com/our-work/coronavirus. Accessed March 21, 2020.
5. RCR position on the role of CT in patients suspected with COVID-19 infection | The Royal College of Radiologists. Rcr.ac.uk. 2020. https://www.rcr.ac.uk/college/coronavirus-covid-19-what-rcr-doing/rcr-position-role-ct-patients-suspected-covid-19. Accessed March 21, 2020.
6. Canadian Society of Thoracic Radiology and Canadian Association of Radiologists’ Statement on COVID – 19 - CAR - Canadian Association of Radiologists". CAR - Canadian Association of Radiologists. 2020. https://car.ca/news/canadian-society-of-thoracic-radiology-and-canadian-association-of-radiologists-statement-on-covid-19/. Accessed March 21, 2020.

7. Bandirali M, Sconfienza LM, Serra R, Brembilla R, Albano D, Pregliasco FE, Messina C. Chest X-ray findings in asymptomatic and minimally symptomatic quarantined patients in Codogno, Italy. Radiology Mar 27 2020 https://doi.org/10.1148/radiol.2020201102.
8. See KC, Ong V, Tan YL, Sahagun J, Taculod J. Chest radiography versus lung ultrasound for identification of acute respiratory distress syndrome: A retrospective observational study. Crit Care. 2018;22(1):1–9.
9. Zu ZY, Jiang MD, Xu PP, et al. Coronavirus Disease 2019 (COVID-19): A Perspective from China. Radiology. 2020;200490. doi:10.1148/radiol.2020200490.
10. Kanne JP, Little BP, Chung JH, Elicker BM, Ketai LH. Essentials for radiologists on COVID-19: An update- scientific expert panel. Radiology. 2020;200527. doi:10.1148/radiol.2020200527.
11. 10.1148/radiol.2020200490
Disease. 2019 (COVID-19): A Perspective from China. Radiology 2020; https://doi.org/10.1148/radiol.2020200490.
12. Huang C, Wang Y, Li X, Ren L, Zhao J, Hu Y, Zhang L, Fan G, Xu J, Gu X, Cheng Z, Yu T, Xia J, Wei Y, Wu W, Xie X, Yin W, Li H, Liu M, Xiao Y, Gao H, Guo L, Xie J, Wang G, Jiang R, Gao Z, Jin Q, Wang J, Cao B. Clinical features of patients infected with 2019 novel coronavirus in Wuhan, China. Lancet. 2020 Feb;15(10223):497–506. 395(.
13. Lei J, Li J, Li X, Qi X. CT imaging of the 2019 novel coronavirus (2019-nCoV) pneumonia. Radiology 2020 Jan 31.
14. Giovagnoni A. Facing the COVID-19 emergency: we can and we do. Radiol Med. 2020 Apr;125(4):337–8.
15. Agostini A, Floridi C, Borgheresi A, Badaloni M, Esposto Pirani P, Terilli F, Ottaviani L, Giovagnoni A. Proposal of a low-dose, long-pitch, dual-source chest CT protocol on third-generation dual-source CT using a tin filter for spectral shaping at 100 kVp for CoronaVirus Disease 2019 (COVID-19) patients: a feasibility study. Radiol Med. 2020 Apr;125(4):365–73.
16. Mahmud Mossa-Basha CC, Meltzer DC, Kim MJ, Tuite KP, Kolli. Bien Soo Tan. Radiology Department Preparedness for COVID-19: Radiology Scientific Expert Panel. Radiology. 2020. doi:10.1148/radiol.2020200988.
17. Chung M, Bernheim A, Mei X, Zhang N, Huang M, Zeng X, Cui J, Xu W, Yang Y, Fayad ZA, Jacobi A, Li K, Li S, Shan H. CT Imaging Features of 2019 Novel Coronavirus (2019-nCoV). Radiology. 2020 Apr;295(1):202–7.
18. Wang D, Hu B, Hu C, Zhu F, Liu X, Zhang J, Wang B, Xiang H, Cheng Z, Xiong Y, Zhao Y, Li Y, Wang X, Peng Z. Clinical Characteristics of 138 Hospitalized Patients With 2019 Novel Coronavirus-Infected Pneumonia in Wuhan, China. JAMA. 2020 Feb 7. doi:10.1001/jama.2020.1585.
19. https://.
20. Ng LFP, Hiscox JA. Coronaviruses in animals and humans. (2020) BMJ (Clinical research ed.). 368: m634.

21. Shi H, Han X, Jiang N, Cao Y, Alwalid O, Gu J, Fan Y, Zheng C. Radiological findings from 81 patients with COVID-19 pneumonia in Wuhan, China: a descriptive study. Lancet Infect Dis. 2020 Feb 24. pii: S1473-3099(20)30086-4.
22. Lee EYP, Ng MY, Khong PL. COVID-19 pneumonia: what has CT taught us? Lancet Infect Dis. 2020 Feb 24. pii: S1473-3099(20)30134-1.
23. Wang M, Cao R, Zhang L, Yang X, Liu J, Xu M, Shi Z, Hu Z, Zhong W, Xiao G. Remdesivir and chloroquine effectively inhibit the recently emerged novel coronavirus (2019-nCoV) in vitro. Cell Res. 2020 Mar;30(3):269–71.
24. Ai T, Yang Z, Hou H, Zhan C, Chen C, Lv W, Tao Q, Sun Z, Xia L. Correlation of Chest CT and RT-PCR Testing in Coronavirus Disease 2019 (COVID-19) in China: A Report of 1014 Cases. Radiology. 2020 Feb;26:200642. doi:10.1148/radiol.2020200642.

# Figures

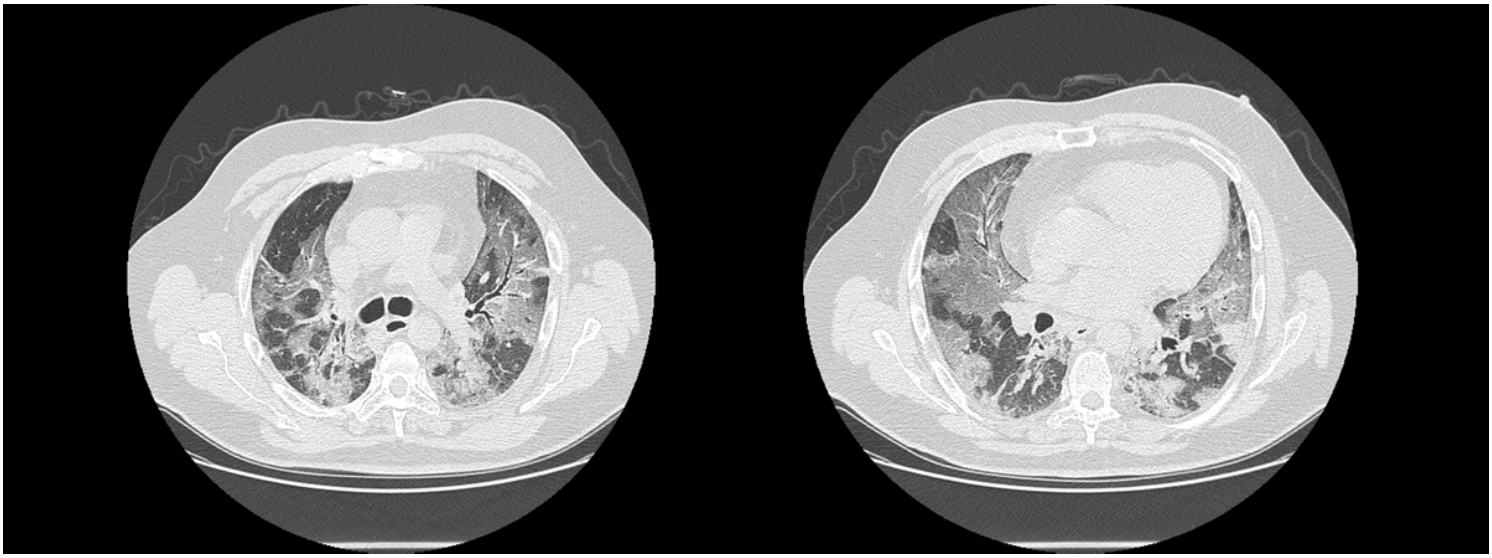

**Figure 1**

The CT images show a typical aspect of bilateral extended crazy paving characterized by GGO with septal thickening, patchy distribution and aerial bronchogram.

**Figure 2**

CT examination of a patient with positive RT-PCR test for COVID-19 infection. The same CT shows a single localization of GGO in the right lower lobe with a rounded morphology.

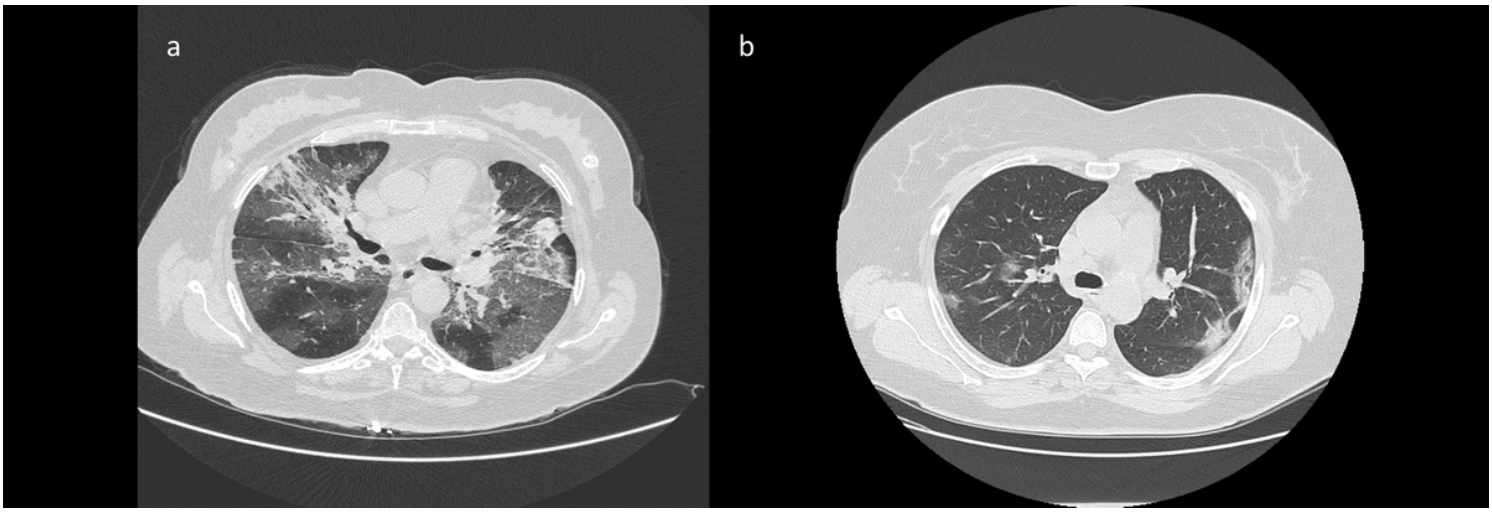


**Figure 3**

Patients with positive RT-PCR test for COVID-19 infection. The CT exams detected areas of GGO and parenchymal consolidation with multifocal diffuse (a) or predominantly peripheral distribution (b).

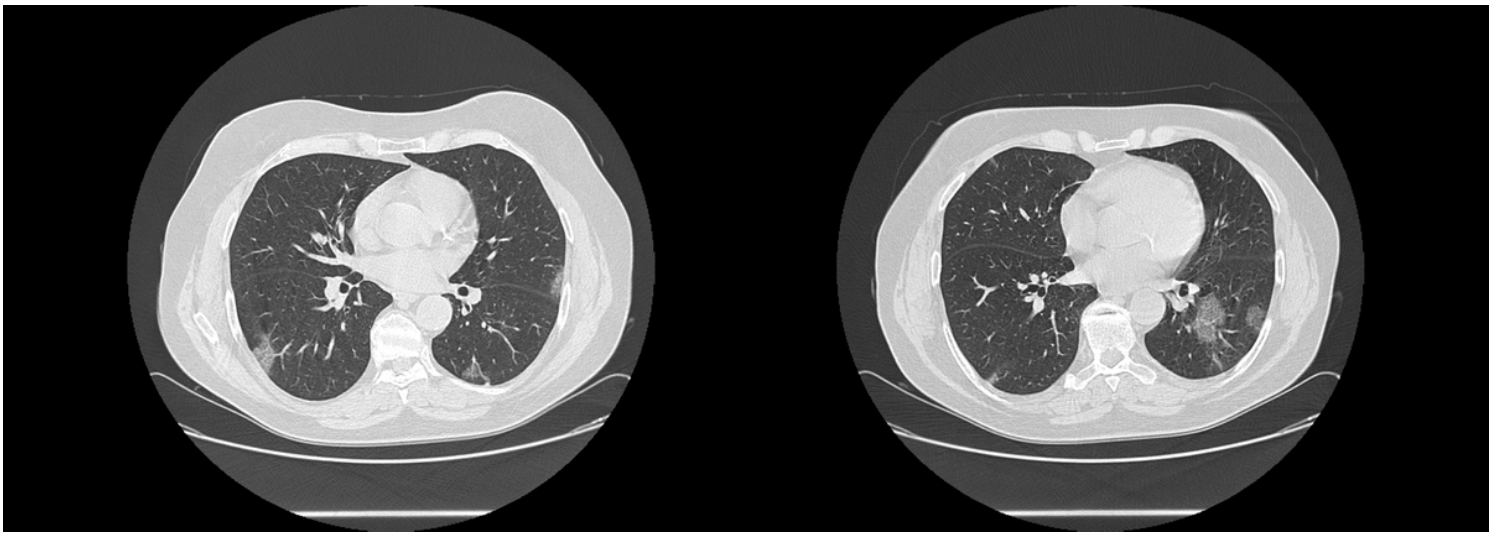

**Figure 4**

CT examination of a patient with clinical suspicion of COVID-19 infection and negative RT-PCR test. The CT images show the presence of GGO areas with typical roundish morphology and a predominantly peripheral distribution, suspect picture for COVID-19 infection. The second RT-PCR test showed positive results

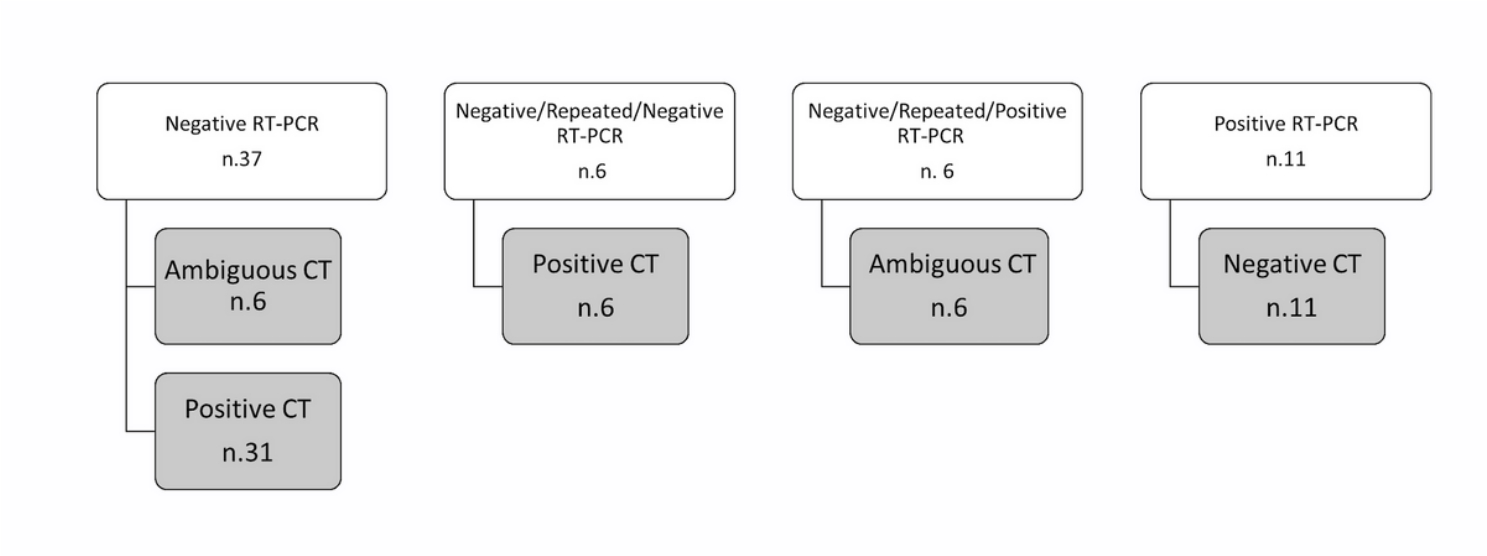


**Figure 5**

Schematic diagram of patients with discordant findings between RT-PCR test and CT

# Supplementary Files

This is a list of supplementary files associated with this preprint. Click to download.

- coverletterDoublereading.docx