Thirty patients with one-stage hip arthroplasty and multiple drilling decompression for bilateral osteonecrosis of the femoral head:outcomes at two-year follow up

Lu Ding
The First Hospital of Jilin University
Yu-Hang Gao
The First Hospital of Jili University
Shi Zhang
The First Hospital of Jilin University
Yi-Fan Huang
The First Hospital of Jilin University
Jian-Guo Liu
The First Hospital of Jilin University
Xin Qi (qixindoc@163.com)
The First Hospital of Jilin University, Jilin University https://orcid.org/0000-0002-5280-6845

Research article

Keywords: osteonecrosis of the femoral head, postoperative satisfaction, total hip arthroplasty, multiple drilling decompression

Posted Date: August 15th, 2019

DOI: https://doi.org/10.21203/rs.2.12958/v1

Abstract

Background: To investigate the postoperative outcome of decompresed hip following contralateral replacement in patients with bilateral osteonecrosis of the femoral head (ONFH). M ethods: This study retrospectively reviewed 30 patients with bilateral ONFH who underwent one-stage total hip arthroplasty (THA) and multiple drilling decompression from February 2014 to February 2016. For all patients, alendronate was prescribed. Postoperative Harris Hip Scores (HHSs), Oxford Hip Scores (OHSs), Self-Administered Patient Satisfaction (SAPS), hip internal and external rotation angles, and the time of one-leg standing were evaluated. All patients were followed up for an average of 30.33 months (ranged from 8 months to 48 months). Results: Twenty-four patients had no progression or collapse on radiographic evaluation within 2 years postoperatively. The following scores of the decompressed sides were significantly lower than those of the replaced sides: HHSs (mean: 96.5 versus 98.25, $P < 0.05$), SAPS (mean: 96.35 versus 99.48, $P < 0.001$), internal rotation (mean: 27.58° versus 30.50°, $P < 0.05$), and the time of single-leg standing (mean: 24.17 s versus 31.83 s, $P < 0.05$). There was no significant difference in OHSs and external rotation between the sides. The remaining 6 patients underwent two-stage THA on the decompressed sides within 2 years. Four of them underwent THA for severe pain and femoral head collapse. The other 2 patients showed no progression on radiographic evaluation but complained of an uncomfortable feeling in the joint. Conclusions: One-stage THA and multiple drilling decompression are effective surgical procedures for bilateral ONFH at different stages. However, a few patients with no progression on radiographic evaluation may require two-stage THA on the decompressed sides because of more pain, poorer internal rotation, and weaker gluteal muscle strength when compared with the replaced sides.

Keywords: osteonecrosis of the femoral head, postoperative satisfaction, total hip arthroplasty, multiple drilling decompression

Background

Osteonecrosis of the femoral head (ONFH) is a devastating disease that has become an increasing worldwide health problem. Although multiple theories have been proposed, no one pathophysiologic mechanism has been identified as the etiology for the development of ONFH, but the basic mechanism involves impaired circulation within a specific area that ultimately becomes necrotic [1]. The natural history of untreated asymptomatic ONFH has a high prevalence of progression to symptomatic disease and femoral head collapse [2]. Various nonoperative treatment regimens and joint-preserving procedures are indicated in the treatment of precollapse disease: nonoperative treatment includes oral medication and improved diet, physical therapy, and various combinations of non-surgical treatments; joint-preserving procedures include core decompression, femoral osteotomy, nonvascularized or vascularized bone-grafting, and stem cells [1]. Among them, core decompression of the hip is one of the most commonly performed surgical procedures that can successfully alleviate the progress of the disease and, at least, delay the patient’s need for total hip arthroplasty (THA) [3]. Multiple drilling decompression is safer and less invasive than single coring, and there is no statistically significant difference in outcome or

the complication rate between both procedures [4]. Once femoral head collapse is present, THA is the only effective treatment that can provide excellent outcomes at greater than 10 years of follow-up [1].

Most patients with nontraumatic ONFH have bilateral involvement [5]. For patients with bilateral involvement who have a collapsed femoral head on one side and precollapsed on the other side, one-stage THA is usually performed for the collapsed side, and joint-preserving surgery is performed for the uncollapsed side; this strategy has been proven to be a cost-effective method that does not increase perioperative morbidity [6]. Recently, Zeng et al reported good short-term to medium-term outcomes with one-sided hip-preserving and concurrent contralateral THA for the treatment of bilateral ONFH in different stages. Therefore, they suggested that the uncollapsed hip can achieve biological stability and sufficient blood supply through hip-preserving surgery and obtain long-term repair of the necrotic bone as well as early non-weight-bearing function training, which is possible since the whole body weight load is distributed to the hip that underwent one-stage THA [7]. However, in Zeng's study, the hip-preserving surgery was core decompression followed by tight impaction bone grafting combined with non-vascularized fibular allografting, which was a more complicated and costly procedure than multiple drilling decompression.

It is unknown whether bilateral ONFH patients with different stages can benefit from one-stage THA and multiple drilling decompression and how the replaced side affects the decompressed side. Therefore, this study aimed to review a series of patients with bilateral ONFH who received one-stage THA and multiple drilling decompression, and we evaluated postoperative Harris Hip Scores (HHSs), Oxford Hip Scores (OHSs), Self-Administered Patient Satisfaction (SAPS), hip internal and external rotation angles, and the time of single-leg standing.

Methods

We retrospectively analyzed 30 patients with bilateral ONFH who received one-stage THA and multiple drilling decompression from February 2014 to February 2016, and all patients were followed up for an average of 30.33 months (ranged from 8 months to 48 months) postoperatively; this study included 21 men and 9 women, aged 35-65 (average 49.67) years. The factors associated with ONFH were alcohol abuse in 17 patients, steroid use in 9 patients, and idiopathic causes in 4 patients. Hips, the sides were not collapse, with a preoperative diagnosis of ARCO stage II the Kerboul combined necrotic angle rom 200° to 240° received multiple drilling decompression[8]. The contralateral hips with preoperative diagnoses of ARCO stages III or IV underwent THA. All the decompressed hip joints were treated with a 3-mm Kirschner wire for decompression of the porous core [9]. All the hips on the replacement side received uncemented hip prostheses, all of which were primary replacements performed via the posterior lateral approach. Subsequently, the patient's position was changed to supine position for decompression of the contralateral hip. All procedures were performed by the same senior surgeon. For all patients, alendronate was prescribed, and they were treated with the same perioperative management.

The survival rates of patients with decompressed sides within 2 years were measured based on both radiographic progression and using two-stage THA as the endpoint. Data between the two sides included HHSs, OHSs, and SAPS. Lower limb mobility and the standing time on a single foot were compared.

Statistical methods

All data were analyzed statistically. The Kolmogorov-Smirnov test was used to evaluate the normality of the groups' data distribution, and the Levene test was used to assess the homogeneity of variance. Paired sample t-tests were applied to normally distributed values. Data with a non-Gaussian distribution were analyzed by using the Wilcoxon signed-rank test. Kaplan-Meier survivorship analyses was used to assess the Two-year survival of decompressed sides. The level of significance was set at $P<0.05$. All statistical analyses were performed using SPSS Statistics 19 (IBM Corp., Armonk, NY, USA).

Results

Among the 30 patients, postoperative evaluations showed that the replacement hip prosthesis was well-positioned and demonstrated good bone ingrowth, with no case of postoperative dislocation, infection, periprosthetic fracture, deep vein thrombosis, and other complications. On the decompressed side, the femoral head did not progress or collapse and was well repaired in 24 patients. If THA was used as the endpoint on the decompression side, the survival rate of decompressed sides within 2 years was 80% in these one-stage THA and multiple drilling decompression (Figure 1). If the progression of necrosis or severe pain was used as the endpoint, the success rate of decompression surgery in our study would be 86.7% (Figure 2). The typical case images are shown in Figure 3.

Data of the 24 patients who underwent successful decompression surgery are shown in Table 1. The HHS of the decompressed hip joint was lower than that of the replacement side (mean: 96.50±5.50 versus 98.25±5.25, $P<0.05$). When comparing the postoperative HHS sub-module, the pain module score of the decompression side had a significantly lower value than that of the replacement side (mean: 4.33±1.93 versus 43.00±1.77, $P<0.001$), while the difference in the HHS functional module score was not statistically significant between the two sides (mean: 55.17±1.61 and 55.25±1.03, respectively, $P>0.05$). There was no significant difference in the postoperative OHS score between the decompression and replacement sides (mean: 46.83±1.66 versus 47.42±1.41, $P>0.05$). The postoperative SAPS of the decompressed side was significantly lower than that of the replacement side (mean: 96.35±3.65 versus 99.48±5.73, $P<0.01$). Compared with the replacement side, the internal rotation of the decompression side hip joint was lower (mean: 27.58±12.58° versus 30.50±9.50°, $P<0.05$), while the external rotation angle was not significantly different (mean: 39.67±5.10° and 42.00±3.46°, respectively, $P>0.05$). The patient's single-foot standing time was shorter on the decompression side than on the replacement side (mean: 24.17±26.83 s versus 31.83±18.17 s, $P<0.05$).

The remaining 6 patients underwent two-stage THA on the decompression side. Of those, 4 underwent THA for severe pain and femoral head collapse (steroid use in 3 patients who underwent THA surgery at 1 year, 11 months, and 8 months after decompression, and idiopathic causes in 1 patient who underwent

two-stage THA at 14 months postoperatively). The other 2 patients showed no significant disease progression on radiographic evaluation but complained of an uncomfortable feeling of the joint (alcohol abuse in 1 patient who underwent two-stage THA at 1 year postoperatively, and idiopathic causes in 1 patient who underwent two-stage THA at 1.5 years postoperatively). Data of the 6 patients with failed decompression surgery are shown in Tables 2 and 3.

Discussion

There are three clinical endpoints for decompression surgery: severe pain, radiographic progression to collapse, and THA [10]. If THA is used as the endpoint on the decompression side, the survival rate of multiple drilling decompression was 80% (Figure 1), which was similar to the results of previous studies [11, 12]. Therefore, it can be suggested that one-stage THA and multiple drilling decompression were effective for patients with bilateral ONFH at different stages. And decompressed side can obtain early non-weight-bearing function training, which benefits from distributing the whole body weight load to the hip of one-stage THA [7]. If the progression of necrosis or severe pain is used as the endpoint, the success rate of decompression surgery in our study would be 86.7% (Figure 2). Two of the 6 patients who underwent THA re-operation had no significant progression of joint disease in the decompressed hip and no severe pain. However, the patients felt discomfort, slight pain on the decompression side, or had function that was not as good as that of the hip joint on the replacement side. This is a problem should be mentioned. This may become an important factor affecting the success rate of head preservation surgery.

We compared HHS and OHS on the decompressed and replaced sides, and found no significant difference in OHS between the two sides. However, for HHS, the difference between the two sides was statistically significant. We analyzed HHS according to the module analysis and found that the pain module score of the decompressed side was lower than that of the replaced side; however, the functional module score was not significantly different. These results indicated that most patients still had slight pain after decompression. Liu et al showed that patients who underwent femoral head decompression had significantly improved pain symptoms; the postoperative visual analog scale score was about 3 points in their study, which was considered mild pain [13], and this result is similar to ours. The main causes of pain before femoral head collapse are intraosseous pressure[14], bone marrow edema, accumulation of microfractures, disruption of mechanical loading, articular cartilage injuries ranging from various stages of chondromalacia to chondral flaps to loose bodies and fraying or tearing[15]. Femoral head decompression can relieve bone marrow edema, but decompression does not address other intraarticular changes. THA is an open surgery that involves the removal of the femoral head and pain caused by these mechanical changes, which fundamentally resolves the intraarticular injuries and replaces the friction interface. This causes marked pain relief of the hip joint on the replaced side postoperatively. The decompressed side had less pain symptoms before surgery, which was not markedly relieved postoperatively. Thus, the patient’s expectation was not met, resulting in lower postoperative satisfaction.

For the patient's hip mobility, we focused on the difference between the internal and external rotations of the decompression and replacement sides. Early symptoms of ONFH are often pain and the limitation of internal rotation [16]. Decompression surgery does not interfere with structures of the hip joint. Thus, postoperative inflammation of the hip joint still exists, and even progresses further. The preoperative internal rotation activity of the hip joint is limited and is not significantly improved by surgery. In THA, the hip joint is thoroughly cleaned and loosened, and the hip joint activity is improved. Moreover, there is more preoperative activity on the replaced side than on the decompressed side, so the improvement of the hip joint activity on the replaced side is more notable. In this study, the degree of internal rotation of the hip was better on the replaced side than on the decompressed side. Therefore, we believe that this limitation in the internal rotation of the hip joint postoperatively affected the postoperative satisfaction.

We also performed a bilateral one-leg standing test to compare the time of standing on one side. In this study, compared with the replaced side, the decompressed side had a shorter standing time. When standing on one leg, the gluteal muscles (gluteus maximus, gluteus medius, and gluteus maximus) are the main supports [17]. When the strength of the gluteal muscles is insufficient on one side of the patient, their supportive ability is poor, thus reducing the standing time on one foot. It was suggested that when the hip undergoes decompression, the affected limb should not undergo weight bearing for at least 3 months. Thereafter, weight bearing should be restored based on the recovery process. However, the replacement side can resume weight bearing after surgery. The limbs on the decompression side will have different degrees of gluteal muscle atrophy, which may cause hip joint fatigue and soreness in advance due to the insufficient strength of the gluteal muscle on the decompression side. The patient's satisfaction with the surgical outcome is then reduced.

Psychological factors also have important effects on the postoperative satisfaction of patients [18]. Patients may have residual discomfort or partial dysfunction after decompression. In this study, patients still felt hip discomfort on the decompressed side when comparing their two hips at the same time. As a result, the postoperative patient satisfaction was lower for the decompressed side than for the replacement side. With the continuous improvement of living standards, patients have increasing requirements for quality of life. Although the postoperative function of the decompression side can fully meet the functional needs of the hip joint in patients' daily lives, the residual mild pain or partial dysfunction after surgery occasionally makes the patient feel uncomfortable, making some patients prefer THA over decompression.

This study has some limitations. First, the sample size of this study was relatively small, and further investigation is needed using larger samples. Second, in the study, only postoperative pain and some functions in the patients were compared. The factors we studied were too simple. Whether other factors also affect patient satisfaction with decompression surgery requires further study.

Conclusions

One-stage THA and multiple drilling decompression are effective surgical procedures for bilateral ONFH at different stages. However, a few patients with no progression on radiographic evaluation may require two-stage THA on the decompressed sides, and this may be due to more pain, poorer internal rotation, and weaker gluteal muscle strength when compared with the replaced sides.

Abbreviations

THA: total hip arthroplasty; ONFH: osteonecrosis of femoral head; HHSs: Harris Hip Scores; OHSs: Oxford Hip Scores; SAPS: Self-Administered Patient Satisfaction

Declarations

Ethical approval and consent to participate

All procedures performed in the study were in accordance with the ethical standards of the ethics committee of The First Hospital of Jilin University and national research committee and conformed to the 1964 Helsinki declaration and its subsequent amendments.

The requirement for written informed consent was waived off owing to the retrospective nature of the study.

Consent for publication

Consent to publish was attained from the study participants.

Availability of data and materials

The datasets used and/or analysed during the current study are available from the corresponding author on reasonable request.

Competing interests

The authors declare that they have no conflict of interest.

Funding

This study was funded by the Natural Science Funding of Jilin province (Grant number: 20170414020GH) for providing support of design

Authors contributions

Every author participated in a particular role in this study. LD had the role in research design, analysis and interpretation of data and writing of manuscript. YHG participated in a particular role in editing of

manuscript. SZ and YFH had the role in acquisition of data. JGL provided facilities. XQ took responsibility for the integrity of the work as a whole, from inception to published work and acquisition of funding.

Acknowledgements

We extend sincere gratitude to the staff of the Department of Orthopaedic Surgery for their assistance during this study.

References

1. Mont MA, Cherian JJ, Sierra RJ, Jones LC, Lieberman JR. Nontraumatic Osteonecrosis of the Femoral Head: Where Do We Stand Today? A Ten-Year Update. J Bone Joint Surg Am. 2015. 97(19): 1604-27.
2. Mont MA, Zywiel MG, Marker DR, McGrath MS, Delanois RE. The natural history of untreated asymptomatic osteonecrosis of the femoral head: a systematic literature review. *J Bone Joint Surg Am*. 2010;92:2165-2170.
3. Lieberman JR. Core decompression for osteonecrosis of the hip. *Clin Orthop Relat Res*. 2004;29-33.
4. Al OA. Multiple drilling compared with standard core decompression for avascular necrosis of the femoral head in sickle cell disease patients. Arch Orthop Trauma Surg. 2013. 133(5): 609-13.
5. Lee MS, Chang YH, Chao EK, Shih CH. Conditions before collapse of the contralateral hip in osteonecrosis of the femoral head. *Chang Gung Med J*. 2002;25:228-237.
6. Shih LY, Wong YC, Shih HN. One-stage hip arthroplasty and bone grafting for bilateral femoral head osteonecrosis. *Clin Orthop Relat Res*. 2009;467:1522-1528.
7. Zeng Y, Qi X, Feng W, Li J, Li F, Zeng J, Yi C, Chen J. One-sided hip-preserving and concurrent contralateral total hip arthroplasty for the treatment of bilateral osteonecrosis of the femoral head in different stages: short-medium term outcomes. *BMC Musculoskelet Disord*. 2015;16:133.
8. Kerboul M, Thomine J, Postel M, Merle d'Aubigné R: **The conservative surgical treatment of idiopathic aseptic necrosis of the femoral head**. *J Bone Joint Surg Br*. 1974; 56(2): 291-296.
9. Li J, Li ZL, Zhang H, Su XZ, Wang KT, Yang YM. Long-term Outcome of Multiple Small-diameter Drilling Decompression Combined with Hip Arthroscopy versus Drilling Alone for Early Avascular Necrosis of the Femoral Head. *Chin Med J (Engl)*. 2017;130:1435-1440.
10. Iorio R, Healy WL, Abramowitz AJ, Pfeifer BA. Clinical outcome and survivorship analysis of core decompression for early osteonecrosis of the femoral head. J Arthroplasty. 1998. 13(1): 34-41.
11. Mont MA, Ragland PS, Etienne G. Core decompression of the femoral head for osteonecrosis using percutaneous multiple small-diameter drilling. *Clin Orthop Relat Res*. 2004;131-138.
12. Song WS, Yoo JJ, Kim YM, Kim HJ. Results of multiple drilling compared with those of conventional methods of core decompression. *Clin Orthop Relat Res*. 2007;454:139-146.
13. Liu Y, Liu S, Su X. Core decompression and implantation of bone marrow mononuclear cells with porous hydroxylapatite composite filler for the treatment of osteonecrosis of the femoral head. *Arch*

Orthop Trauma Surg. 2013;133:125-133.

14. Ficat RP: **Idiopathic bone necrosis of the femoral head. Early diagnosis and treatment**. *J Bone Joint Surg Br*. 1985; 67(1): 3-9.
15. McCarthy J, Puri L, Barsoum W, Lee JA, Laker M, Cooke P: **Articular cartilage changes in avascular necrosis: an arthroscopic evaluation**. *Clin Orthop Relat Res*. 2003; (406): 64-70.
16. Zhao DW, Hu YC. Chinese experts' consensus on the diagnosis and treatment of osteonecrosis of the femoral head in adults. *Orthop Surg*. 2012;4:125-130.
17. Torry MR, Schenker ML, Martin HD, Hogoboom D, Philippon MJ. Neuromuscular hip biomechanics and pathology in the athlete. *Clin Sports Med*. 2006;25:179-197, vii.
18. Specht K, Kjaersgaard-Andersen P, Kehlet H, Wedderkopp N, Pedersen BD. High patient satisfaction in 445 patients who underwent fast-track hip or knee replacement. Acta Orthop. 2015. 86(6): 702-7.

Tables

Table 1. Outcome Parameters of 24 patients with successful decompression surgery.

	Decompression side	Replacement side	P
atisfaction score(SD)	96.35(3.65)	99.48(5.73)	0.000*
arris score(SD)	96.50(5.50)	98.25(5.25)	0.030*
arris score , pain(SD)	41.33(1.93)	43.00(1.77)	0.003*
arris score□function(SD)	55.17(1.61)	55.25(1.03)	0.832
HS score(SD)	46.83(1.66)	47.42(1.41)	0.196
ıternal rotation angle(SD)	27.58°(2.58°)	30.50°(9.50°)	0.035*
xternal rotation angle□SD□	39.67(5.10)	42.00(3.46□	0.070
tanding time of one foot□SD□	24.17s(12.32s)	31.83s(13.68s)	0.047*

*P<0.05 was significant differen

Table 2. Outcome Parameters of 2 patients with no progression of imaging of femoral head necrosis

	Decompression side□`X□	Replacement side□`X□
rris score	97.0	100.0
rris score , pain	42.0	44.0
rris score□function	55.0	56.0
IS score	47.0	48.0
ernal rotation angle	32.0°	40.5°
ternal rotation angle	40.0°	45.5°
nding time of one foot	17.5s	20.0s

Table 3. Outcome Parameters of 4 patients with femoral head collapse

	Decompression side□`X□	Replacement side□`X□
rris score	33.5	98.5
rris score , pain	7.5	43.0
rris score□function	26.0	55.5
S score	25.5	47.3
ernal rotation angle	10.0°	36.0°
ernal rotation angle	12.5°	43.0°
nding time of one foot	6.3s	32.3s

Figures

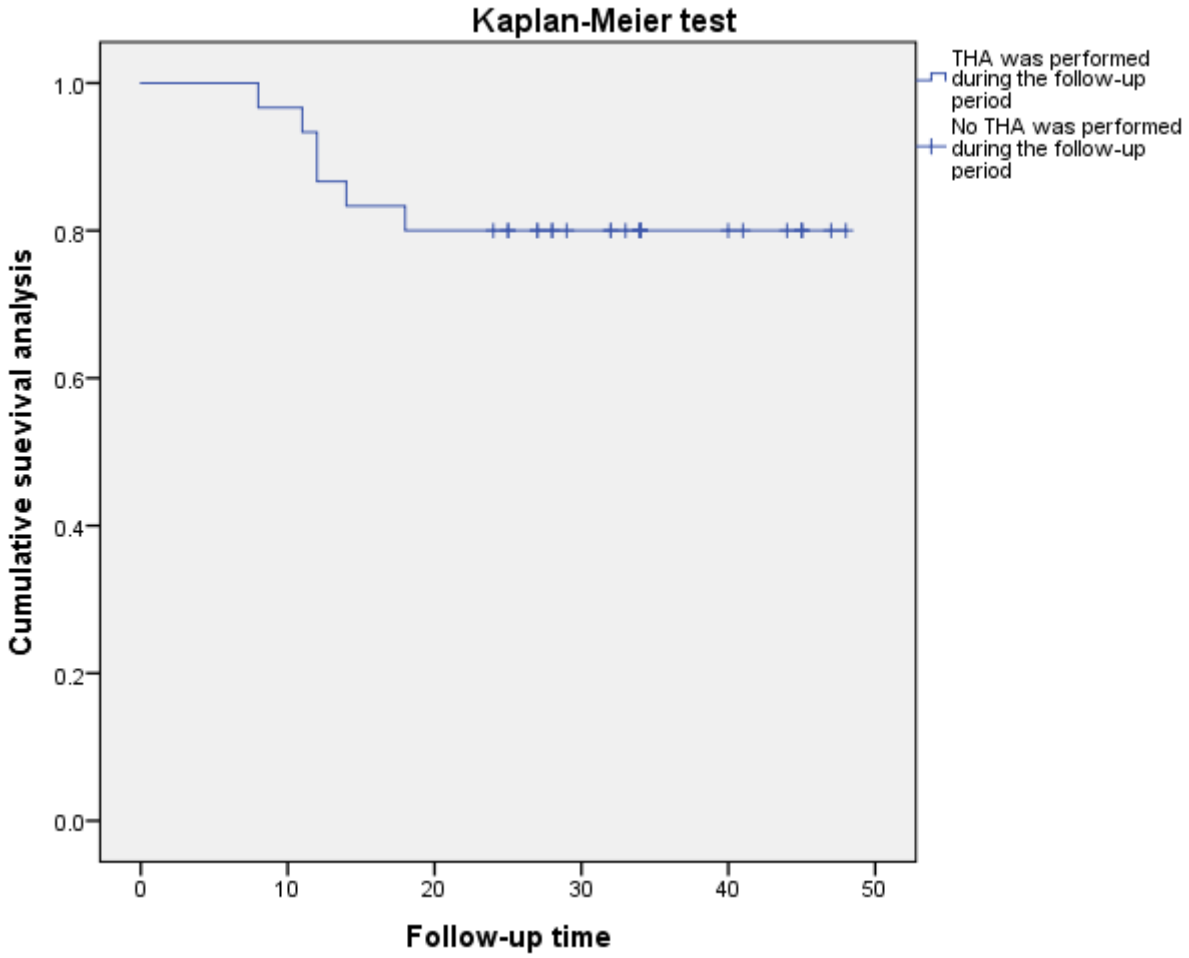

Figure 1

Kaplan-Meier survivorship analyses when THA was used as the endpoint. The survival rate of decompressed sides within 2 years was 80% in these one-stage THA and multiple drilling decompression when THA was used as the endpoint on the decompression side.

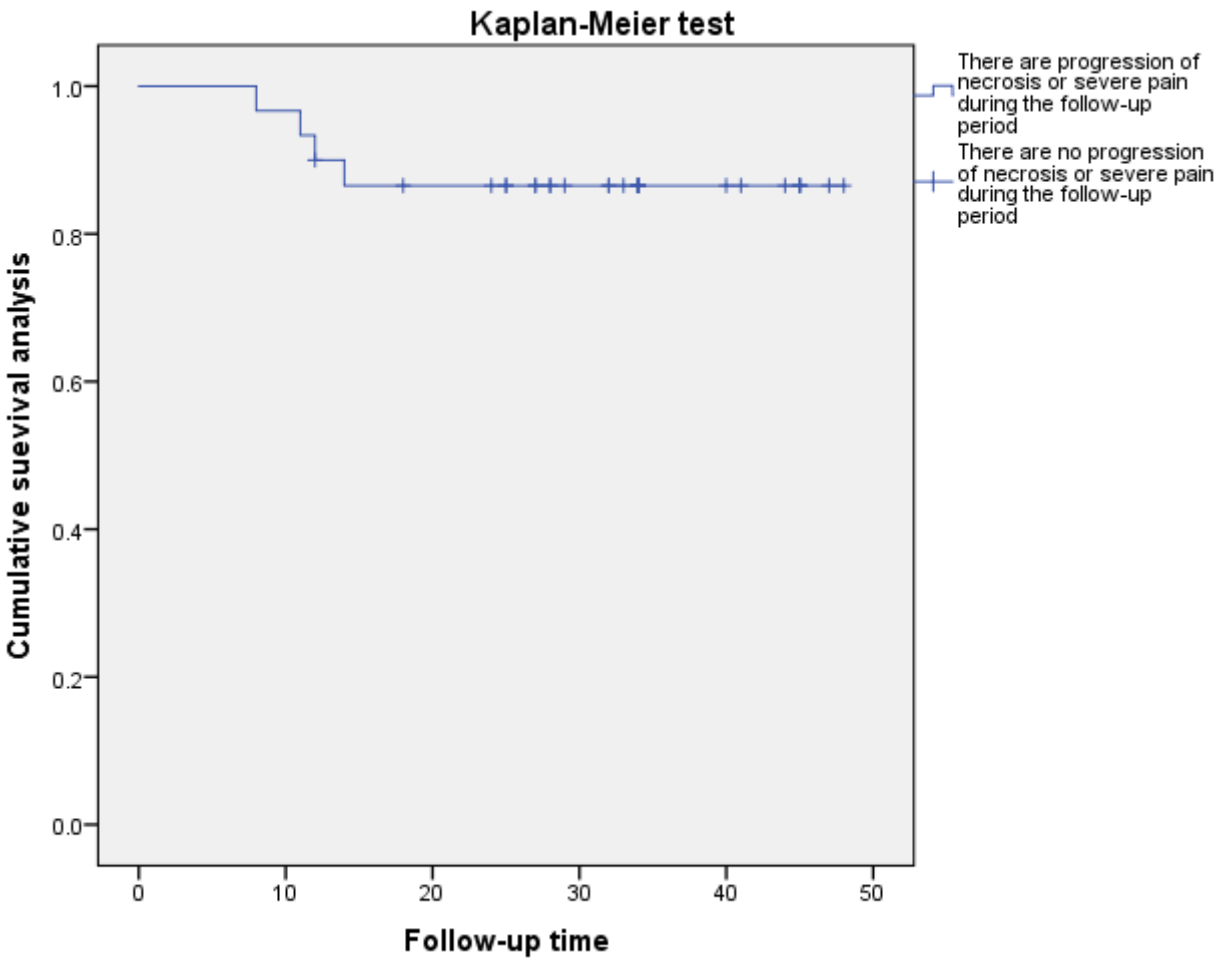

Figure 2

Kaplan-Meier survivorship analyses when the progression of necrosis or severe pain was used as the endpoint. The survival rate of decompression surgery in our study would be 86.7% when the progression of necrosis or severe pain was used as the endpoint

Figure 3

X-ray films of preoperative and after operation. A is the radiograph of the pelvis of the patient. It can be seen that the left femoral head has collapsed and the right femoral head is completely smooth. B is the patient's frog-leg lateral views. The combined necrotic angle = a (119.2°)+b (99.1°). C and D are the hip magnetic nucleus of the patient before surgery. In the figure, bilateral femoral head necrosis can be observed, and the left femoral head necrosis range is large. E and F were reviewed X-ray films 1 year after surgery. It can be seen that the shape of the femoral head on the decompression side (right side) is intact and smooth, and the condition has not progressed further. The bone ingrowth along the needle channel can be observed (white arrow indication). And the replacement side (left side), the hip prosthesis is in good position and the bone is ingrowth.