A Simple and Effective Guide Device for Femoral Neck Fracture Fixed With Cannulated Screw Fixation

bufang Ren (rbfdlh123@163.com)
the second hospital of shanxi medical university

quanping ma
department ,the second hospital of shanxi medical university

jian gao
department of orthopedics,the second hospital of shanxi medical university

xin lv
department of orthopedics ,the second hopital of shanxi medical university

Research article

Keywords: femoral neck fracture, guide, screw

Posted Date: June 29th, 2020

DOI: https://doi.org/10.21203/rs.3.rs-37005/v1

Abstract

Background: Accurate placement of cannulated screws is the key to stable fixation of the femoral neck fracture. A simple guide device was developed to improve the accuracy of screw placement.

Methods: 40 synthetic femoral bones were divided into conventional technique group and the experimental group. Three Kirschner wire were inserted into the femoral neck fracture by conventional technique or by the simple guide device. The operative time, total drilling times and fluoroscopic frequency were evaluated.

Results: By using the guide device, the fluoroscopy and operation time of the experimental group were shorter that of the conventional method. The total drilling times with the simple guide device were significantly lower than the conventional technique group.

Conclusions: The use of this guide device can make screw fixation for femoral neck fracture easier. This is helpful for an inexperienced hand.

Background

Femoral neck fracture is a common hip fracture in orthopedics. Internal fixation is preferred for femoral neck fracture in young people and non-displaced femoral neck fracture in elderly people with good physical condition[1,2] Cannulated screws has been the common one among several implants which have been used for femoral neck fracture[3,4,5]. Placing three cannulated screws in parallel with the inverted triangle can provide better biomechanical stability [6]. However, it is not easy for the surgeons to place screws at the right position. Accurately to insert screws accounts for a significant proportion of the total fluoroscopy and operative time.

In this study, the authors designed a simple and effective guide device for femoral neck fracture cannulated screw fixation to make the fixation easier. The purpose of this study was to demonstrate the effectiveness of the guide device

Method

Structure of the device

The guide consists of two components: Aiming component and regulating and fixation component (Fig1). Aiming component (Fig1B) which was a 45-degree V-shaped structure, welded by a rod and a sleeve (Fig1B). The sleeve allows the Kirschner wire to pass through. Regulating and fixation component (Fig1A): a stainless steel buckle is welded to a small steel plate. Buckle has a hole, through which rod of aiming component pass and fixed by locking knob. The rod can be rotated in the hole to adjust the angle of anteversion.

40 synthetic femoral bone were obtained from (Osborne Technology Co, Ltd, Hangzhou, China). The specimen was covered with sponges to simulate the soft tissue compartment and divided into conventional technique group and the experimental group.

In the conventional technique group, a guidewire was placed along the anterior femoral neck as a reference. The first Kirschner wire was inserted to femoral neck manually. Fluoroscopic imaging was performed and once it was in the inferocentra part of femoral neck, use a parallel guide to place the posterosuperior and anterosuperior Kirschner wire.

In the experimental group, the guide device was fixed on the lateral side of the proximal femur and insert the Kirschner wire through the sleeve onto the lateral femur cortex (Fig2). Anteroposterior and lateral fluoroscopic images were acquired. The trajectory of the Kirschner wire in the femoral neck is judged according to the extension of image of Kirschner wire on the c-arm fluoroscope (Fig3A,3B). The Kirschner wire was drilled into the femoral neck when it was in the right posion(Fig3C,D). The parallel guide is used to insert the other two Kirschner wire(Fig4).

Statistical Analysis

This was carried out using SPSS18.0 software (SPSS Inc., Chicago Illiosi) using chi-squared testing. The level of significance was set as a p-value<0.05.

Result

The results are presented in Table 1. The operative time and total drilling times with the simple guide device were significantly lower than the operation with the conventional technique (p 0.05). The fluoroscopic frequency was also significantly lower in the operation with the new drill guide (p 0.001). Time statistically extremely significant decrease in radiation

Table 1: comparison of results in the two groups

Result	Experimental group	Conventional group	P
Operation Time (min)	24.8 ± 9.1	40.3 ± 7.6	0.04
Fluoroscopy Frequency(number)	27.5 ± 9.6	46.7 ± 8.4	<0.001
Total drilling times	4.5 ±0.6	17.9 ± 5.2	<0.001

Discussion

Closed reduction and internal fixation have become the standard methods for the treatment of femoral neck fractures in patients 60 years of age or younger. Fixation with three parallel cannulated screws placed in an inverted triangle configuration, is a common method for femoral neck fracture[7]. If

complication didn't occur, the patient can resume normal activities. The inverted triangle is effective in reducing the rate of nonunion and implant failure[8]. However, accurate screw placement necessitates high requirement for the surgeon and requires more fluoroscopic and operative time. So, we developed this simple and effective guide device to make the fixation with screw easier.

The conventional method of screw placement for femoral neck fractures is mainly performed by surgeons with experience under fluoroscopic monitoring. During the internal fixation of femoral neck fracture with closed reduction, the femoral neck is not exposed and the desired position is not easily obtained due to the lack of necessary reference during the placement of the first guide needle, which often requires multiple drilling for success. Multiple drilling not only resulted in prolonged operation time, increased tissue damage, and increased doctor-patient exposure time to the X-ray radiation, but also resulted in unstable fracture fixation due to more or less osteoporosis in the femoral neck of most patients[9].

By using the guide device, the fluoroscopy and operation time of the experimental group were shorter that of the conventional method. The most important thing is to successfully insert the guide wire in the femoral neck at one time. The femoral cortex is not drilled frequently.

The guide device is easy to operate. It works like inserting the spiral blade in the proximal femoral nail anti-rotation system. When The regulating device is fixed on the lateral side of the thigh between the anterior and posterior femur cortex, the sleeve is at a 45degree angle to the lateral cortex in the anteroposterior view. The angle of anteversion can be adjusted by rotating the rod in steel buckle. Anteroposterior and lateral fluoroscopic images were acquired. The trajectory of the Kirschner wire in the femoral neck is judged according to the extension of image of Kirschner wire on the c-arm fluoroscope. Once the Kirschner wire is in right place, the Kirschner wire was drilled into the femoral neck. The first Kirschner wire was successfully inserted into the femoral neck at one time. Then the other two Kirschner wire were drilled by the parallel aiming device.

Other researchers have developed guides to accurately place Kirschner wires. Yin et al. demonstrated a novel guidewire aiming device to improve the accuracy of guidewire Insertion[10]. However, the operation was complicated. The navigation systems could improve accuracy[11,12,13], but the higher costs of the special instruments and increased radiation and operative time limited their clinical use[14].

In conclusion, this guide device can significantly improve the accuracy of injection, reduce tissue damage, shorten the operation time and reduce the amount of X-ray radiation, and has less dependence on the operator's experience. The use of this guide can make percutaneous compression hollow screw fixation for femoral neck fracture easier.

We believe this guide device can help to promote screw fixation technique in third world countries. This is helpful for an inexperienced hand.

Abbreviations

Not applicable

Declarations

Acknowledgements

Not applicable

Authors' contributions

Not applicable

Funding

Not applicable

Availability of data and materials

The datasets used and analyzed during the current study are available from the corresponding author on reasonable request

Ethics approval and consent to participate

The study was approved by the Institutional Review Board/Ethics Committee of the second Hospital of Shanxi Medical University .The study was conducted according to the ethical principles stated in the Declaration of Helsinki

Consent for publication

The participants declare that they agree to publish the data described in the manuscript.

Competing interests

The authors declare that they have no competing interests.

Author details

Department of Orthopedics, The second Hospital of Shanxi Medical University, 382 Wuyi Road, Taiyuan, Shanxi province, 030001, China.

References

1. Davidovitch RI, Jordan CJ, Egol KA, Vrahas MS.Challenges in the treatment of femoral neck fractures in the nonelderly adult. J Trauma.2010;68(1): 236–242.

2. Bernstein J, Ahn J. In brief: fractures in brief: femoral neck fractures. Clin Orthop Relat Res.2010;468(6): 1713–1715.

3. Seyfettinoglu F, Ersan O, Kovalak E, Duygun F, Ozsar B, Ates Y. Fixation of femoral neck fractures with three screws: results and complications. Acta Orthop Traumatol Turc. 2011 45(1): 6–13

4 Huang HK, Su YP, Chen CM, Chiu FY, Liu CL. Displaced femoral neck fractures in young adults treated with closed reduction and internal fixation. Orthopedics2010;.33(12): 873.

5.Haidukewych GJ, Rothwell WS, Jacofsky DJ ,Torchia ME,Berry D. Operative treatment of femoral neck fractures in patients between the ages of fifteen and fifty years. J Bone Joint Surg Am. 2004;86-A(8): 1711–1716.

6.Selvan VT, Oakley MJ, Rangan A, Al-Lami MK. Optimum configuration of cannulated hip screws for the fixation of intracapsular hip fractures: a biomechanical study. Injury. 2004;35:136–141.

7.Li JT, Wang ML, Zhou JF, Han L, Zhang H, Li C, Li L ,Hao M. Optimum Configuration of Cannulated Compression Screws for the Fixation of Unstable Femoral Neck Fractures: Finite Element Analysis Evaluation.Biomed Res Int. 2018;9;1-10.

8.Yang JJ, Lin LC, Chao KH, Chuang SY, Wu CC, Yeh TT, Lian YT. Risk factors for nonunion in patients with intracapsular femoral neck fractures treated with three cannulated screws placed in either a triangle or an inverted triangle configuration. J Bone Joint Surg Am. 2013;95(1):61-69.

9.Mei J, Liu S, Jia GY, Cui XL, Jiang C, Ou Y. Finite element analysis of the effect of cannulated screw placement and drilling frequency on femoral neck fracture fixation.Injury. 2014;45(12):2045-2050.

10.Yin WJ, Xu HT, Hu T, An ZQ, Zhang CQ, Sheng JG. A novel guidewire aiming device to improve the accuracy of guidewire insertion in femoral neck fracture surgery using cannulated screw fixation. Med Sci Monit. 2016;16;22:2893-2899.

11.Liebergall M, Ben-David D, Weil Y, Peyser A, Mosheiff R. Computerized navigation for the internal fixation of femoral neck fractures. J Bone Joint Surg Am.2006;88:1748–1754.

12.Kendoff D, Hüfner T, Citak M, Geerling J, Maier C, Wesemeier F,Krettek C. Implementation of a new navigated parallel drill guide for femoral neck fractures. Comput Aided Surg. 2006;11:317–321.

13.Kendoff D, Hüfner T, Citak M, Maier C, Wesemeier F, Pearle A, Krettek C. A new parallel drill guide for navigating femoral neck screw placement. Development and evaluation. Unfallchirurg. 2006;109:875–880.

14.Muller MC, Belei P, Pennekamp PH, Kabir K, Wirtz DC, Burger C, Weber O. Three-dimensional computer-assisted navigation for the placement of cannulated hip screws. A pilot study. Int Orthop.2012;36(7)1463-1469.

Figures



Figure 1

Picture of the guide device. (A) regulating and fixation component: A stainless steel buckle which has a hole(2) and locking knob (3)is welded to a small steel plate(1). B) aiming component was a 45-degree V-shaped structure, which was is welded by a rod (5)and a sleeve(4). (C) the whole picture of the guide device.

Figure 2

The guide device was fixed on the surface of the skin. The first Kirschner wire through the sleeve was inserted onto the surface of femur.

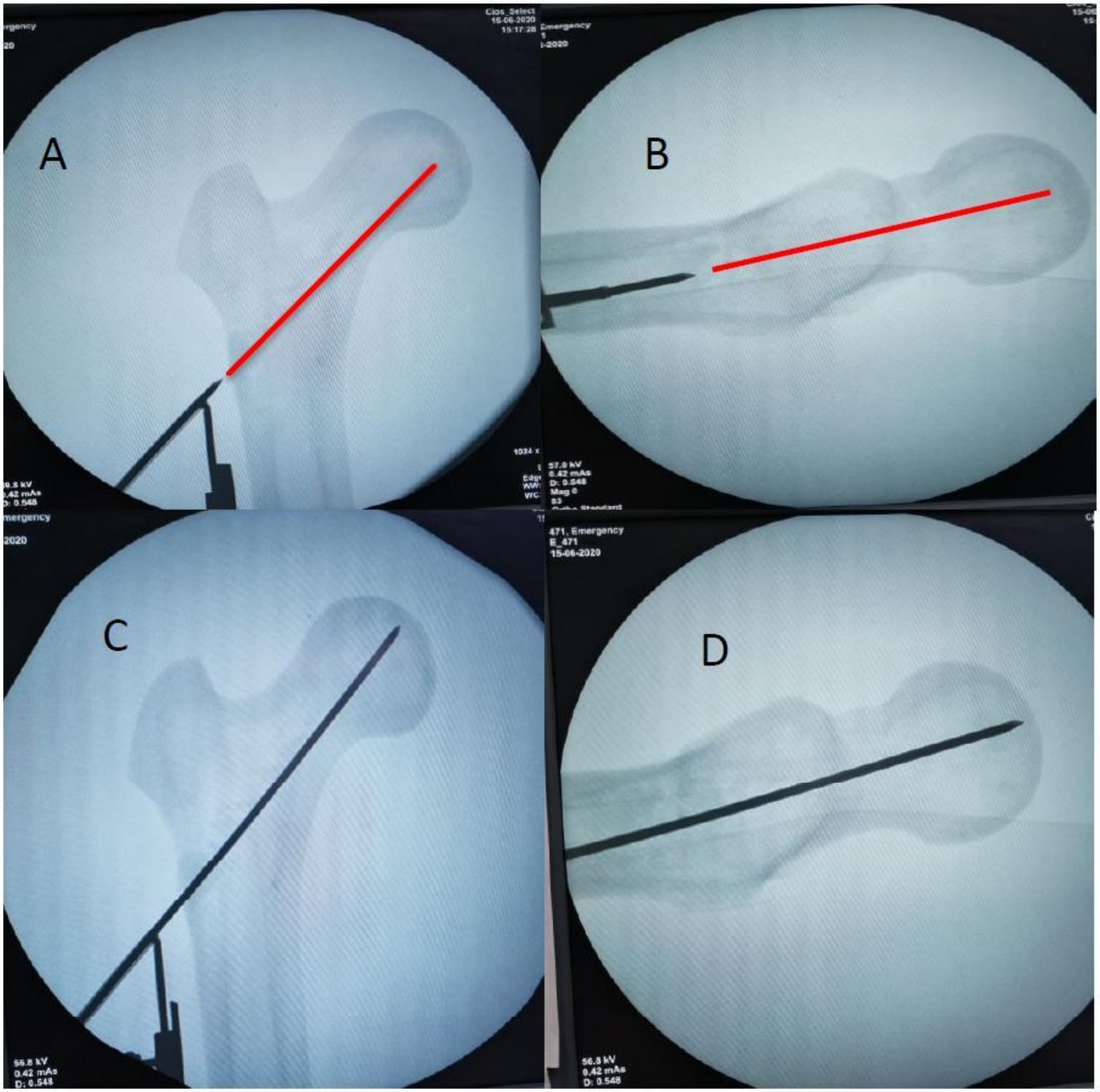

Figure 3

Insertion of the first Kirschner wire: Anteroposterior(A) and lateral (B)fluoroscopic images were acquired. The trajectory of the Kirschner wire(the red line in the A,B) in the femoral neck is judged according to the extension of image of Kirschner wire on the c-arm fluoroscope. The Kirschner wire was drilled into the femoral neck(C,D).

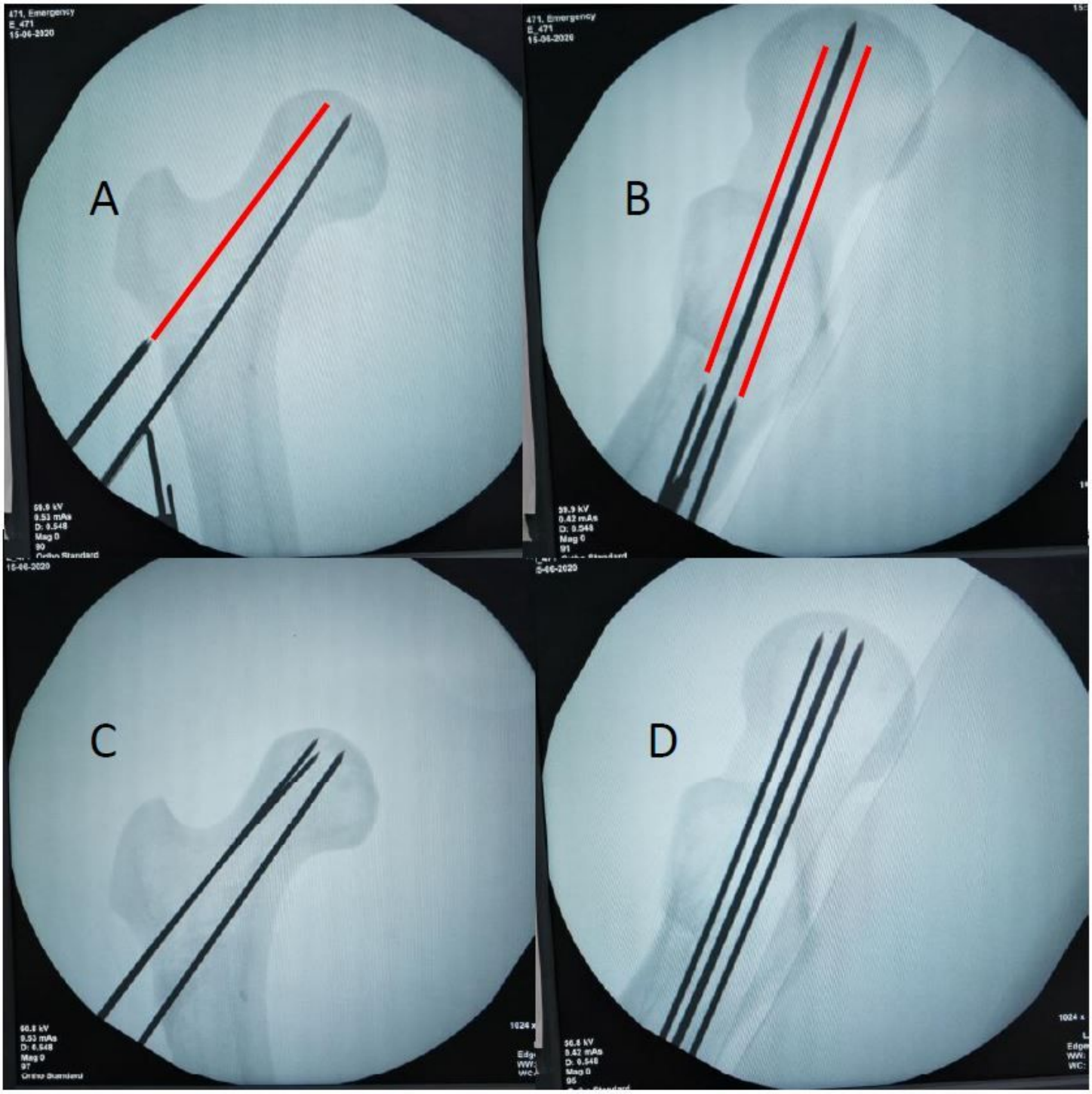

Figure 4

Insertion of the other two Kirschner wire using parallel guide: Anteroposterior(A) and lateral (B)fluoroscopic images were acquired. The trajectory of the other two Kirschner wires (the red line in the A,B) in the femoral neck is judged according to the extension of image of Kirschner wire on the c-arm fluoroscope. The Kirschner wires were drilled into the femoral neck(C,D).