Zadek osteotomy for the treatment of Haglund's Syndrome

Weixin Zheng
Honghui Hospital, Xi'an Jiaotong University
Junhua Du
Xi'An Medical University
Jingqi Liang
Honghui Hospital, Xi'an Jiaotong University
Yan Zhang
Honghui Hospital, Xi'an Jiaotong University
Xiaojun Liang
Honghui Hospital, Xi'an Jiaotong University
Hongmou Zhao (zhmfootankle@163.com)

Study protocol

Keywords: Zadek's osteotomy, Haglund's syndrome, Chauveaux-Liet angle

Posted Date: June 23rd, 2020

DOI: https://doi.org/10.21203/rs.3.rs-37115/v1

Abstract

Background

Although several treatment options described in paper, Haglund's Syndrome (HS) is a challenging common lower extremity disorder. This study reported the clinical outcomes of Zadek osteotomy (ZO) for the treatment of HS.

Methods

This retrospective study included 19 patients who underwent ZO from January 2016 to June 2018. Patients were evaluated using the American Orthopedic Foot Ankle Society ankle-hindfoot scale (AOFAS), Visual Analogue Scale (VAS), ankle range of motion (AROM), and Chauveaux-Liet (CL) angle preoperatively and at final follow-up visit (16.3 ± 4.2) months. Postoperative complications of patients were also recorded.

Results

The ZO exhibited a significant improvement (P 0.05) in preoperative to postoperative AOFAS (from 53.2 ± 5.4 to 86.4 ± 6.5), VAS (from 6.3 ± 2.1 to 0.9 ± 1.2) scores and CL angle (from 18.2 ± 1.3 to 9.4 ± 2.1) degrees, the dorsiflexion of AROM (DAROM) (from 23.4 ± 2.3 to 29.4 ± 1.2) degrees. The planter flexion of AROM (PAROM) (from 32.5 ± 3.5 to 33.2 ± 3.4) degrees (P 0.05). One postoperative complication was observed: a case of hardware pain in healthy patient. The overall rate of satisfaction after surgery was (94.7%).

Conclusions

ZO is effective and safe procedure for the treatment of HS. This method can be a good option for those patients of HS.

Background

In 1928, Patrick Haglund described the Haglund deformity firstly[1]. This deformity refers to an enlargement of the posterolateral heel, which can cause posterior heel pain. This symptom is referred to as Haglund's syndrome (HS), which includes insertional Achilles tendinopathy (IAT)[2, 3]. The patient with HS often has a red, irritated, painful heel. And they often complain the enlargement of the posterior heel, which make it more difficult to footwear or sport. HS is a common disease. There are many conservative treatment options to treat it, which contains rest, activity modification, ice, or footwear modification[3]. When these treatment for more than 6 months has failed, surgical options will be considered[4]. Common

surgical methods, including haglund deformity debridement, endoscopic calcaneoplasty, and Zadek osteotomy (ZO)[3, 5, 6].

In 1939, Zadek described the ZO option for the treatment of HS firstly[7]. It was later modified by Keck and Kelly in 1965[8]. ZO is a dorsal closing wedge calcaneal osteotomy that allows the tuberosity of Haglund deformity to be brought forward. This operation can change the calcaneus' anatomical length and elevate the distal insertion point of the AT[9]. The aim of this operation as the removal of the underlying bony prominence, which can reduce the impingement between the Achilles tendon (AT) and the posterior calcaneal tuberosity[10]. Keck and Kelly proved that ZO was an effective treatment for HS[8]. And Miller reported a good results in 16 patients of HS with that ZO option[11]. However, Myerson did not agree with osteotomy routinely because of increased morbidity compared with a posterosuperior prominence resection (PPR)[12]. But some patients still complain some degree of pain after PPR[13]. Therefore, another operation is required for better outcomes. However, few studies have reported the use of ZO to treat HS, especially in Asia.

This retrospective study aims to evaluate the effectiveness of the ZO for the treatment of HS.

Patients And Methods

Records of 25 patients with HS who underwent ZO from January 2016 to June 2018 at the Department of Foot and Ankle Surgery, Honghui Hospital, Xi'an Jiaotong University (Xi'an, China) were reviewed. Informed consent was obtained from all study subjects. All procedures were performed by 1 foot and ankle orthopaedic surgeon. A minimum follow-up of 1 year after surgery was required for all patients. Inclusion criteria were patients

Specific inclusion and exclusion criteria were determined for selected patients. Inclusion criteria were patients over 18 years of age, at least 6 months of documented failed conservative treatment, and no prior foot and ankle surgery. Exclusion criteria were patients of HS with AT rupture, diabetes mellitus with or without neuropathic joint destruction, and local infection. Four patients were excluded according to the criteria, and another 2 patients were lost to follow-up. Therefore, 19 cases (19 feet) were included in the current study. The average age at the time of the operation was 48.6 ± 7.3 (range, 31–71) years. The mean follow-up time was 16.3 ± 4.2(range, 13–37) months. Data regarding age, gender, operative side, body mass index (BMI), smoking, and follow-up duration were collected.

Operative Technique

Patients was placed in the lateral position on the operating table. All patients received spinal or epidural anesthesia. A thigh tourniquet with 280 mmHg pressure was applied. Surgical procedures were performed using a full-thickness lateral approach (Fig. 1A). Through a lateral skin incision, the calcaneus was exposed. And then, through the design of pre-operation, closing wedge osteotomy was performed

(Fig. 1B). According to the preoperative lateral radiograph of the calcaneus, the design of pre-operation taking into account the angle, width of the wedge, and orientation. When the osteotomy was completed with a shorter blade, the calcaneus was fixed with full threaded cannulated screws under the guidance of 2 K-wires (Fig. 1C). When fixation was finished, using a C-arm device to reconfirm the position of the screws. Then, using a 2 – 0 absorbable suture to repair subcutaneous tissue, and using a 3 – 0 nonabsorbable suture to close the skin.

Postoperative Management

All patients were not allowed to walk for two weeks. All patients were allowed to perform passive motions of the ankle. Skin sutures were removed 2 weeks after surgery. At 8 weeks postoperatively, partial weight bearing was allowed in the removable walker boot. Patients were allowed full weight bearing at 3 months postoperatively.

Clinical And Radiographic Evaluations

Functional evaluations, pain assessments, evaluation of ankle joint, and anatomy changes were collected. Results of the functional evaluations, pain assessments and evaluation of ankle joint performed preoperatively and postoperatively (last follow up visit) were included to determine the Foot Ankle Society ankle-hindfoot scale (AOFAS)[14], Visual Analogue Scale (VAS)[15], and ankle range of motion (AROM). Results of anatomy changes included changes in the Chauveaux-Liet (CL) angle[3] (Fig. 2).

Statistical analysis

All data were analyzed statistically using SPSS (version 22.0; IBM, Chicago, IL). Paired t-tests were used to compare the outcomes measures (AOFAS, VAS, ROM and CL angle) recorded before surgery and at last follow-up visit. All values assessed were expressed as the mean ± standard deviation (SD). Statistical significance was defined at $P<0.05$.

Results

All patients were followed-up for a minimum of 1 year. No patient presented with infection, nonunion or skin necrosis after the surgery. One patient complained pain on the lateral foot within the first 2 months after the operation, but he had resolution at the 6-month follow-up visit. At the last follow-up, the AOFAS scores increased from 53.2 ± 5.4 (range, 20–57) preoperatively, to 86.4 ± 6.5 (range, 68–100) points postoperatively ($P<0.01$). The VAS scores decreased from 6.3 ± 2.1 preoperatively to 0.9 ± 1.2 points postoperatively ($P<0.01$). The dorsiflexion of AROM (DAROM) increased from 23.4 ± 2.3 preoperatively to 29.4 ± 1.2 points postoperatively ($P<0.01$). The planter flexion of AROM (PAROM) from32.5 ± 3.5 preoperatively to 33.2 ± 3.4 points postoperatively (P 0.05) (Fig. 3). The CL angle decreased from 18.2 ±

1.3 preoperatively to 9.4 ± 2.1 degrees postoperatively (P<0.01) (Table 1). The overall rate of satisfaction after surgery was (94.7%).

Table 1
Comparison of clinical indicators between pre- and postoperatively

Scale	AOFAS score	VAS score	DAROM	PAROM	CL angle
Preoperatively	53.2 ± 5.4	6.3 ± 2.1	23.4 ± 2.3	32.5 ± 3.5	18.2 ± 1.3
Postoperatively	86.4 ± 6.5	0.9 ± 1.2	29.4 ± 1.2	33.2 ± 3.4	9.4 ± 2.1
P value	0.000	0.000	0.000	0.536	0.000

Discussion

In our study, the AOFAS, VAS, DAROM, and CL angle was significantly improved at the final follow-up (P 0.01). The ZO showed significant function improvement and pain relief, and no patient were found with infection or nonunion. In another study found that the ZO showed significant pain relief compared to other surgical procedures[16]. And in study of Maynou[17], the ZO was also reported has an excellent results.

Haglund deformity is common, which is an abnormality of the posterosuperior part of the calcaneus[2]. Because the enlargement of the posterolateral heel is near the insertion of the AT, the soft tissue and tendon are compressed during ankle motion[18]. This symptom is referred to as HS. This impingement of ankle motion is considered the main reason of HS[19]. Treatment should start off with conservative ways, such as activity modification, ice, or footwear modification. When conservative treatments fail, surgical treatment is required to remove the impingement. However, the posterosuperior prominence resection of tradition cannot solve the impingement between the calcaneus and the insertion of the AT. But the dorsal closing wedge calcaneal osteotomy can remove this impingement. Therefore, the ZO is not only no need for additional resection of the Haglund deformity, but also helpful to relief pain of the impingement.

Previous studies showed the good clinical result with ZO for HS[17]. But it is not to be noted from 1939 article of Zadek to 1965 study of Keck and Kelly, because of the high rate of postoperative complications[3]. However, the latest researches show that complications after calcaneal osteotomy is rare, and no significant difference has been found between traditional open operation and minimally invasive approach[20, 21]. In study of Andrea[22] and Zilu Ge[10], they found the ZO had a excellent clinical results for HS. And nonunion after ZO was not found for all patients. The mechanism of ZO is likely to elevate the insertion of the AT, and the orientation of the AT was changed. These biomechanical changes can reduce tendon stress and delay the progress of HS and eliminate risk factors[3]. In our study, the CL angle decreased from 18.2 ± 1.3 preoperatively to 9.4 ± 2.1 degrees postoperatively. The changes of the CL angle could prove it.

In this study, we firstly researched the changes of the AROM preoperatively and postoperatively. The ZO showed significant improved in the AOFAS, VAS, DAROM, and CL angle. However, we found that the PAROM is not significant changed after surgery. The changes of ROM were different. We thought that the main reason has to do with the AT. The AROM is affected by the AT, especially the PAROM. The changes of postoperative DAROM could also prove the advantage of ZO in biomechanical changes. The good clinical results may be attributable to the advantage of ZO.

This study comes with several limitations. This is retrospective design, the small sample size, and the short follow-up. Despite these limitations, and for all we know, this study firstly researched the changes of CL angle and the ROM about ZO. And this study suggests that the ZO is an effective technique for the surgical option of HS.

Conclusion

This study researched the clinical outcomes of ZO for the treatment of HS. The ZO resulted in better functional and biomechanical improvement during short-term follow-up. This method can be a good option for HS.

Abbreviations

Haglund's Syndrome: HS; Zadek osteotomy: ZO; AOFAS: American Orthopedic Foot Ankle Society ankle-hindfoot scale; VAS: Visual Analogue Scale; AROM: ankle range of motion; CL: Chauveaux-Liet; DAROM: The dorsiflexion of AROM; PAROM: The planter flexion of AROM.

Declarations

Availability of data and materials

All data and materials regarding the study are available from the corresponding author.

Ethics approval and consent to participate

This study was approved by the Clinical Academic Committee of the Honghui Hospital, Xi'an Jiaotong University and conducted in compliance with the Helsinki Declaration. Written consent was acquired for all patients.

Consent for publication

Not applicable.

Competing interests

The authors declare that they have no competing interests.

Funding

None.

Authors' contributions

ZWX designed the study, analysed the data, and wrote the manuscript. DJH, LJQ, and ZY collected the data and helped write the manuscript. ZHM and LXJ contributed to research design and revision of the manuscript. All authors read and approved the final manuscript.

Acknowledgements

Not applicable.

References

1. Chan AP, Chan TY: **Methanol as an unlisted ingredient in supposedly alcohol-based hand rub can pose serious health risk**. *International journal of environmental research and public health* 2018, **15**(7):1440.
2. Ashurst JV, Nappe TM: **Methanol toxicity**. 2019.
3. Ahmed F, Khan NU, Ali N, Feroze A: **Methanol poisoning: 27 years experience at a tertiary care hospital**. 2017.
4. Holt NR, Nickson CP: **Severe methanol poisoning with neurological sequelae: implications for diagnosis and management**. *Intern Med J* 2018, **48**(3):335-339.
5. Beauchamp G, Valento M, Kim J: **Toxic alcohol ingestion: prompt recognition and management in the emergency department [digest]**. *Emergency medicine practice* 2016, **18**(9 Suppl Points & Pearls):S1-S2.
6. Eghbali H, Mostafazadeh B, Ghorbani M, Behnoush B: **Neurologic Complications of Methanol Poisoning: A Clinicoepidemiological Report from Poisoning Treatment Centers in Tehran, Iran**. *Asia Pacific Journal of Medical Toxicology* 2015, **4**(1):47-50.
7. Zamani N, Rafizadeh A, Hassanian-Moghaddam H, Akhavan-Tavakoli A, Ghorbani-Samin M, Akhgari M, Shariati S: **Evaluation of methanol content of illegal beverages using GC and an easier modified Chromotropic acid method; a cross sectional study**. *Substance Abuse Treatment, Prevention, and Policy* 2019, **14**(1):56.
8. Jaff Z, McIntyre WF, Yazdan-Ashoori P, Baranchuk A: **Impact of methanol intoxication on the human electrocardiogram**. *Cardiol J* 2014, **21**(2):170-175.

9. Sanaei-Zadeh H, Emamhadi M, Farajidana H, Zamani N, Amirfarhangi A: **ECG as mortality predictor in methanol poisoning**. *Arh Hig Rada Toksikol* 2013, **64**:265-271.
10. Derval N, Shah A, Jaïs P: **Definition of early repolarization: a tug of war**. In.: Am Heart Assoc; 2011.
11. Sieira J, Brugada P: **The definition of the Brugada syndrome**. *European heart journal* 2017, **38**(40):3029-3034.
12. Pavri BB, Siu H, Andrikopoulou E, Ho R, DeCaro M: **T Wave Slopes: A novel method for assessment OF repolarization dispersion from surface ECGS with prolonged QT as compared to normal ECGS**. *Journal of the American College of Cardiology* 2014, **63**(12 Supplement):A1638.
13. Maruyama M, Kobayashi Y, Kodani E, Hirayama Y, Atarashi H, Katoh T, Takano T: **Osborn waves: history and significance**. *Indian pacing and electrophysiology journal* 2004, **4**(1):33.
14. Supreeth R, Francis J: **Fragmented QRS–its significance**. *Indian Pacing and Electrophysiology Journal* 2020, **20**(1):27-32.
15. Naraqi S, Dethlefs R, Slobodniuk R, Sairere J: **An outbreak of acute methyl alcohol intoxication**. *Australian and New Zealand journal of medicine* 1979, **9**(1):65-68.
16. Aghababaeian H, Araghi Ahvazi L, Ostadtaghizadeh A: **The methanol poisoning outbreaks in Iran 2018**. *Alcohol and alcoholism* 2019, **54**(2):128-130.
17. Chung J-Y, Ho C-H, Chen Y-C, Chen J-H, Lin H-J, Wang J-J, Hsu C-C, Huang C-C: **Association between acute methanol poisoning and subsequent mortality: a nationwide study in Taiwan**. *BMC public health* 2018, **18**(1):985.
18. Hovda KE, Hunderi OH, TAFJORD AB, Dunlop O, Rudberg N, Jacobsen D: **Methanol outbreak in Norway 2002–2004: epidemiology, clinical features and prognostic signs**. *Journal of internal medicine* 2005, **258**(2):181-190.
19. Chow E, Khosla A, Berman L: **Methanol Induced ST Elevation and Brain Death**. In: *D46 CRITICAL CARE CASE REPORTS: TOXICOLOGY AND POISONINGS.* edn.: American Thoracic Society; 2018: A6926-A6926.
20. Berenson GS, Srinivasan SR, Bao W, Newman WP, Tracy RE, Wattigney WA: **Association between multiple cardiovascular risk factors and atherosclerosis in children and young adults**. *New England journal of medicine* 1998, **338**(23):1650-1656.
21. Kimmoun A, Novy E, Auchet T, Ducrocq N, Levy B: **Hemodynamic consequences of severe lactic acidosis in shock states: from bench to bedside**. *Critical Care* 2016, **19**(1):175.
22. Crimi E, Taccone FS, Infante T, Scolletta S, Crudele V, Napoli C: **Effects of intracellular acidosis on endothelial function: an overview**. *Journal of critical care* 2012, **27**(2):108-118.
23. Celotto A, Capellini V, Baldo C, Dalio M, Rodrigues A, Évora PRB: **Effects of acid-base imbalance on vascular reactivity**. *Brazilian Journal of Medical and Biological Research* 2008, **41**(6):439-445.
24. Paasma R, Hovda KE, Tikkerberi A, Jacobsen D: **Methanol mass poisoning in Estonia: outbreak in 154 patients**. *Clinical toxicology* 2007, **45**(2):152-157.

25. Zakharov S, Pelclova D, Urban P, Navratil T, Diblik P, Kuthan P, Hubacek JA, Miovsky M, Klempir J, Vaneckova M: **Czech mass methanol outbreak 2012: epidemiology, challenges and clinical features**. *Clinical toxicology* 2014, **52**(10):1013-1024.
26. Issa Z, Miller JM, Zipes DP: **Clinical Arrhythmology and Electrophysiology: A Companion to Braunwald's Heart Disease E-Book: Expert Consult: Online and Print**: Elsevier Health Sciences; 2012.
27. Johnson JN, Ackerman MJ: **QTc: how long is too long?** *British journal of sports medicine* 2009, **43**(9):657-662.
28. Vernooy K, Delhaas T, Cremer OL, Di Diego JM, Oliva A, Timmermans C, Volders PG, Prinzen FW, Crijns HJ, Antzelevitch C: **Electrocardiographic changes predicting sudden death in propofol-related infusion syndrome**. *Heart Rhythm* 2006, **3**(2):131-137.
29. Weiner JB, Haddad EV, Raj SR: **Recovery Following Propofol-Associated Brugada Electrocardiogram**. *Pacing and Clinical Electrophysiology* 2010, **33**(4):e39-e42.

Figures

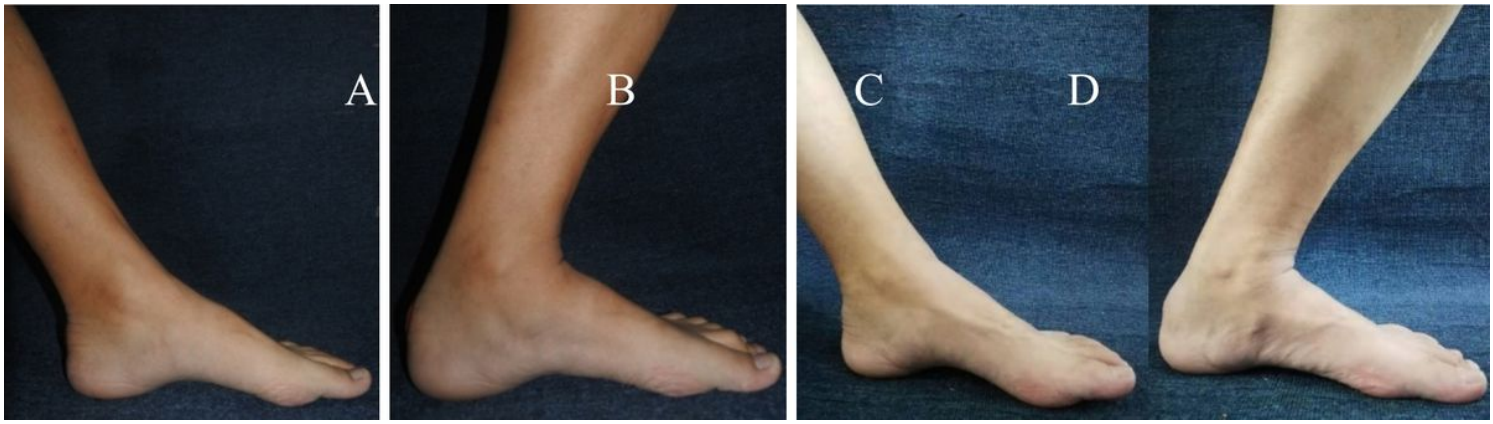

Figure 1

Preoperative and postoperative ankle range of motion. A The preoperative planter flexion of AROM. B The preoperative dorsiflexion of AROM. C The postoperative planter flexion of AROM. D The postoperative dorsiflexion of AROM.

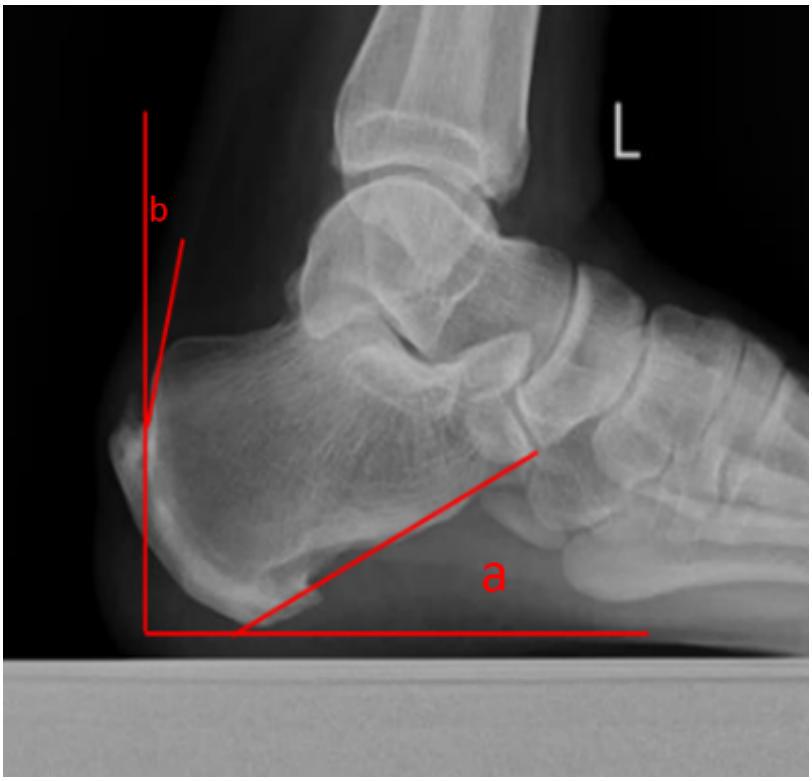

Figure 2

Chauveaux–Liet (CL) angle for Haglund's deformity: the difference between the angle of verticalization (a) and morphologic angle (b) of the calcaneus (CL angle = a - b). Angle a is the calcaneal pitch angle or angle of verticalization of calcaneus described as the intersection of the baseline tangent to the anterior tubercle and the medial tuberosity with the horizontal surface. The angle b is formed between the vertical line tangent to the most posterior point of greater tuberosity and the straight line joining this point to the apex of the posterosuperior crest.

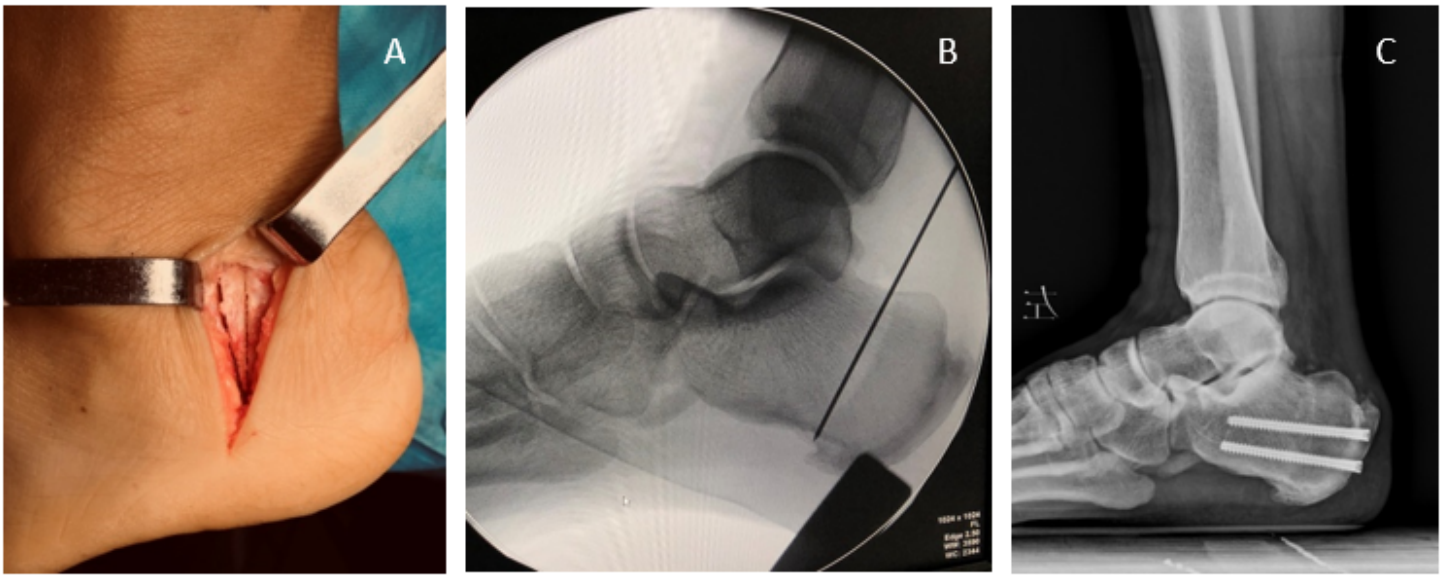

Figure 3

A Surgical incision. B Cut line of the calcaneus. C Two full threaded cannulated screws used for fixation