Refined tumescent liposuction-curettage with pruning in small incisions for treatment of axillary bromhidrosis

Cai-Yun Li
Zhejiang University School of Medicine First Affiliated Hospital
Xiao-Feng Wang
Zhejiang University School of Medicine Sir Run Run Shaw Hospital
Hai-ying Zhou
Zhejiang University School of Medicine First Affiliated Hospital
Qing-Qing Fang
Zhejiang University School of Medicine Sir Run Run Shaw Hospital
Weiqiang Tan (tanweixxxx@zju.edu.cn)

Research article

Keywords: Axillary bromhidrosis, liposuction, curettage, pruning

Posted Date: June 25th, 2020

DOI: https://doi.org/10.21203/rs.3.rs-37316/v1

Version of Record: A version of this preprint was published at Dermatologic Therapy on January 1st, 2021. See the published version at https://doi.org/10.1111/dth.14690.

Abstract

Background

Axillary bromhidrosis is widespread social problem in our society. Various modalities have been developed for destruction or removal of the apocrine sweat glands to eliminate the malodor. But conventional surgical treatments often result in high complication rate and frequent recurrence. In the study, we evaluate the effect of refined tumescent liposuction-curettage with pruning in small incisions in the treatment of axillary bromhidrosis.

Methods

From July of 2013 to April of 2019, 110 patients (75 women and 35 men) with axillary bromhidrosis were treated by refined tumescent liposuction-curettage with pruning. The results of malodor elimination were evaluated by both the patients and doctors as very satisfied (excellent), satisfied (good), some satisfied (fair), and not satisfied (poor). Postoperative complications, including dehiscence, infection, wound contracture, cyst, subcutaneous hydrops, haematoma or seroma were evaluated as well. Preoperative and postoperative histological examinations of axillary tissue were performed in 2 patients.

Results

Among subjective evaluation of the 110 patients, 33 (30.0%) were graded as very satisfed results, 70 (63.6%) were satisfied, and 7 (6.4%) was some satisfied. The objective evaluation showed 43 (39.1%) were graded as excellent results and all the others were good. No serious complications were happened except three showed slightly local subcutaneous hydrops and haematoma. Histologic examinations showed the apocrine glands significant decreased or destroyed after surgery.

Conclusion

Refined tumescent liposuction-curettage with pruning in small incisions is an effective method for treatment of axillary bromhidrosis.

Background

Axillary bromhidrosis can be characterized as a combination of wet earwax, hyperhidrosis and bromhidrosis (1, 2). Due to the abnormal smell of bromhidrosis, the sufferers have to bear the burden of spirit, and the severe ones have to bear the sense of inferiority. With the increasing intercommunication of human beings in society, the psychological and social problems of the special people group have become more and more prominent.

Generally, axillary bromhidrosis is believed to be caused by the abnormal function of the large sweat glands, which is mainly manifested as the increased number, increased size and high secretion of the large sweat glands in the patients with bromhidrosis compared with normal people (3). Most of the patients have family histories and it was considered as an autosomal dominant inheritance disease in one report (4). Recently, scientists also found that it's closely associated with the human *ABCC11* gene (5).

Various treatment modalities have been developed for axillary bromhidrosis, but the effect of nonsurgical treatment such as topical deodorants, perfumes, antiperspirants, iontophoresis as well as anticholinergic agents are temporary and limited (6, 7). Surgical processes, including *en bloc* excision of tissue, superficial or ultrasonic liposuction, subcutaneous shaving, laser ablation, local injection of botulinum toxin A or ethanol, have been performed (8). Surgical methods seem to be the relative satisfactory treatment, but sometimes they are accompanied by complications such as wound dehiscence, infection, hematoma or seroma, skin flap necrosis and obvious scar formation. Besides, the long recovery period perhaps lead to a prolonged restriction in arm movement (8, 9).

Recently, patients who look for ideal treatment require not only a high successful surgical rate, but also faster recovery as well as fewer complications. The aim of this study is to evaluate the effectiveness and safety of the refined tumescent liposuction-curettage with pruning in small incisions for treatment of axillary bromhidrosis.

Methods

Patients

From July of 2013 to April of 2019, 110 patients (75 female patients and 35 male patients; age range, 16–38 years; average age, 20.2 years) or 220 axillae (two axillae in one patient) underwent refined tumescent liposuction-curettage with pruning for treatment of axillary bromhidrosis at the author's medical center. All patients signed informed consents. Among the 110 patients, 80 patients had family history, 9 patients were recurrent cases after CO2 laser treatment, 7 patients had been treated by Botulinum Toxin A,and 6 patients had residual malodor after armpit skin resection. The duration of axillary bromhidrosis in all the patients was more than 3.0 years. The mean follow-up period was 10.2 months, ranging from 3 to 16 months.

Surgical Procedures

The patient was placed in a supine position with the arms abducted approximately to 110°. Axillary hair was shaved before the surgery, and an average of 0.5 cm outlines beyond the bilateral axillary hair lines were marked (For the patients with large areas of axillary hair, the surgical range were closely followed by the armpit hairs margin marker; for the patients with small and sparse axillary hair, the range was appropriately expanded by 1–2 cm). One small incisions point (about 5 mm) was marked at the middle of the lower marked lines, and the other was marked on the brachial pole (For the patients with large areas, another small incisions point would be marked in the middle, Fig. 1). The tumescent solution, composed of 500 mL of normal saline, 15 mL of 5% sodium bicarbonate, 10 mL of 2% lidocaine, 0.5 mL of 1:1000 epinephrine, was used for local anesthesia. According to the size of axilla, about 200 to 400 mL of the

solution was injected in each side with 20-gauge spinal needle (Fig. 2). This process not only reduces intraoperative hemorrhage, but also makes the original depressed axillary region expanded and easy to dissection as well.

Two or three small stab incisions were made at the marked points. Firstly, a cuspidal liposuction-curettage cannula was inserted through the incisions, and was inserted in multiple tunnels of the subcutaneous tissue. Secondly, a blunt liposuction-curettage cannula was used for curettage and suction of the subcutaneous tissue (the maximum negative pressure is 0.9 mpa), making the completely separation above the superficial fascia (Video 1). Through this process, most of the large sweat glands and subcutaneous adipose tissues were suction out. Then, the eye scissors with the elbow facing down (the left index finger was used to assist the pressure and feel the thickness of the skin) were inserted through the small incision; the large sweat glands and the subcutaneous adipose tissues were pruned by the middle of the scissor blade; and the excised tissues were extracted from the small incisions (Fig. 3). After trimming, the skin flap thickness could be checked by moving the blunt liposuction-curettage cannula back and forth under the skin: Video2 showed the uniform skin thickness in the surgical area and it was significantly thinner than that shown in Video1. If the patient has a large surgical area, add another small incision on the lower skin area for easy pruning. After the pruning, rinse and suction several times with the normal saline for extraction of the residual sweat glands and broken fat tissues. At the end of the process, the surgical area skin became the full-thickness skin (about 1 mm), which was noticeably thinner after pruning (Fig. 4).

Aureomycin eye ointment was applied to the operative area, and cotton ball bag was applied under the armpit in the sitting position (Fig. 5). The patients were advised to wear elastic clothing special for armpit odor to cover the wound and restrict the shoulder joint (no more than 90 degrees upward), and the upper limb was not allowed to bear heavy weight (Fig. 6). The total procedure takes about 90 to 120 min. After 10–14 days, the suture can be unpacked and removed, and the dressing does not need to be replaced during this period except obvious hematoma which need to be treated as soon as possible.

Assessment

The clinical efficacy was graded by the patient (subjective evaluation: very satisfied, satisfied, some satisfied and not satisfied). We also adapted a grading system to obtain a subjective assessment of the postoperative results. The scoring system was set according to the method of Park et al [10], with a few changes. Patients were asked to bare the axilla during examination in a closed examination room, and the grade of odor was evaluated by two doctors and one nurse or a family member. There were four levels. From grade 0 to grade 3, they were considered respectively as the excellent, good, fair, poor results. The evaluation criteria are as follows:

Grade 0: the axilla did not give off any malodor under any circumstances.

Grade 1: the axilla gave off a slight malodor (detected only by himself, with in 20 cm) only after performing strenuous activities (e.g., exercise, hard walking, etc.).

Grade 2: the axilla gave off a strong malodor after performing daily activities, but the malodor could not be detected from the body at a distance of 1.5 m.

Grade 3: Not only did the rubbed gauze from the armpit give off a strong malodor, but prominent malodor could be detected easily from the body at a distance of 1.5 m.

Besides, Postoperative complications, including dehiscence, infection, wound contracture, cyst, subcutaneous hydrops, haematoma or seroma were evaluated as well. Preoperative and postoperative histological examinations of axillary tissue were performed in 2 patients to identify the elimination and destruction of sweat glands. The axillary specimen was obtained by 4-mm punch biopsy at the centre of axilla.

Results

From July 2013 to April 2019, 110 patients with axillary bromhidrosis have undergone refined tumescent liposuction-curettage with pruning in Department of Plastic Surgery, The First Affiliated Hospital, Zhejiang University School of Medicine. The follow-up evaluation started 3 months after the surgery, ranging from 3 to 16 months and the mean follow-up period was 10.2 months. According to the subjective evaluations of 110 patients, 103 patients (93.6%) thought they got very satisfied or satisfied results, which means the malodor could only be smelled when closed to the armpit after sweating (Fig. 7). As for our objective evaluation, 39.1% of the patients got Grade 0, and other 60.9% were Grade 1 (Table 1). Patients have malodor higher than grade 2 could be considered for operation, while patients who become grade 0 or grade 1 means that they have been cured (10). Thus, among 110 patients, the cure rate of this operation was 100%, and there was no reccurence in this study.

Table 1
The objective evaluation

No. of Axillae (%)	
Grade 0: excellent	43 (39.1)
Grade 1: good	67 (60.9)
Grade 2: Fair	0 (0.0)
Grade 3: poor	0(0.0)

During the convalescence, there was no need for multiple dressing changes after surgery. Only three patients came up with some complication,as their axillaes showed subcutaneous hydrops and haematoma after the operation. Thus, we dealt with these issues by opening the bandage and changing the dressing in time. They still had excellent results afterwards. In other patients, the postoperative underarm scar was not obvious, the shoulder joints were not limited in activity, and the armpit hair was significantly less than before(Figure 8,9). No other postoperative complications, like dehiscence, infection, wound contracture, cyst happened in all the patients (Table 2).

Table 2
The evaluation of complications

Complications	No. of Axillae (%)
Wound dehiscence	0 (0.0)
Wound infection	0 (0.0)
Scar contracture	0 (0.0)
Local cyst	0 (0.0)
Subcutaneous hydrops	1 (0.4)
haematoma or seroma	2 (0.8)

In gross observation, we found that the large sweat glands in the central region of the axilla were obviously dense and large, especially the severe patients. The degrees of malodor were irrelevant with the size, density, thickness or range of armpit hair. The preoperative histological examination showed larger size and numbers of apocrine glands (Fig. 10). The apocrine sweat glands were granular, 0.1 cm to 0.2 cm in diameter, and they were clearly distinct from surrounding tissues. The secretory part was adjacent to the subcutaneous fat layer of the dermis. It was also found to be located between the dermal reticular layer and the axillary superficial fascia, which formed a tough and complete membranous structure at the top close to the dermal reticular layer. However, the postoperative tissue obviously showed the removal of subcutaneous tissue. There were less apocrine and eccrine glands, and the sweat glands were severely destructed (Fig. 11).

Discussion

Although it is not a serious disease, axillary bromidrosis can be significantly disturbing when it gives off the malodor, which causes psychological distress and social embarrassment. The main cause of offensive odor is the interaction of the apocrine sweat glands with microorganisms (11). Apocrine sweat secretion is no foul-smelling when it just reaches the surface. However, after a few hours, it gives off the malodor as fatty acids liberate by local bacterial flora, including lipophilic and large colony diphtheroids (11). Thus, it has been believed that destruction or remove of the apocrine sweat glands by surgical modalities could eradicate this problem.

The treatment of *en bloc* excision of the local skin and subcutaneous tissue has already been abnegated, because it always accompanied the obvious scar formation and partial functional disorder (12). Then, based on the knowledge that most glands are localized in the subcutaneous tissue, selective local surgical excision of the apocrine sweat glands without skin excision has been performed. However, previous methods such as carbon dioxide laser treatment (13), subcutaneous shaving (14), upper thoracic sympathectomy (15) have various complications including wound infection, hematoma or seroma, skin flap necrosis, noticeable scar and incomplete removal of sweat glands. Thus, some modified methods combining some special instruments such as special shaving or razor instruments, ultrasonic liposuction

have been used (10). Nowadays, local injection of botulinum toxin A or ethanol for treating axillary bromhidrosis also has been introduced, which might be new therapeutic approachs for patients (16, 17). But the long-term effect still needs to be further investigated.

A recent review with a meta-analysis (18) which includes forty studies published before February 2016 demonstrated that surgical modality was the most effective treatment for axillary bromhidrosis. Among the surgical modalities, liposuction was identified as the most effective method, with the lowest number of associated complications. Besides, combining the curettage treatment was an ideal option for lowering recurrence rate in surgery and liposuction treatments, which supports our option of surgical methods. We applied tumescent liposuction-curettage modality, and in order to ensure the remove of sweat glands, we used pruning through small incisions.

Here we listed previous reports which also chose liposuction and curettage for the treatment of axillary bromhidrosis (Table 3). In 1998, Ou et al. (19) first reported 20 patients involved in this procedure with the mean follow-up time of 14 months. Among them, 90% of patients got good results, but with 20% complications and one minor wound infection. After that, other doctors also reported their results with this treatment. We can see in the table that most doctors chose only liposuction and curettage. Most of the patients did get good results, but the complication rate was still high. In 2011, Li et al. (20) described that the application of liposuction with subcutaneous pruning could not only get good results, but also with low complications. But the study only involved 28 patients. Our surgical process added pruning after liposuction and curettage, which could ensure the complete removal of sweat glands as well as the low complication rate.

Gross observation showed that the distribution range of large sweat glands was basically the same as that of axillary hairs. The range over axillary hairs 0.5 cm was rare. Thus, we chose an average of 0.5 cm outlines beyond the bilateral axillary hair lines to mark the surgical area. Then the local tumescent anesthesia not only reduces intraoperative hemorrhage, but also causes the previously sunken axillary region to swell, ensuring the insertion of suction needle without damaging the deep tissue. Histological examinations of preoperative tissues showed numerous and large apocrine glands while after the operation, the specimen showed significant decrease in subcutaneous tissue. That’s because we finally used the eye scissors to prune the subcutaneous skin, apart from liposuction and curettage.

Conclusions

Refined tumescent liposuction-curettage with pruning in small incisions had excellent patient satisfaction, high successful rate, few complications, and low recurrence rate. We therefore recommend the refined tumescent liposuction-curettage with pruning in small incisions as an ideal surgical method for axillary bromhidrosis.

Abbreviations

Not applicable.

Declarations

Ethics approval and consent to participate

The study protocols were approved by the Medical Ethics Committee of the First Affiliated Hospital, Zhejiang University School of Medicine, and the written informed consents also have also been obtained from the study participants.

Consent for publication

Written informed consent was obtained from the patient for publication of clinical details and clinical images. Upon request, a copy of the consent form is available for review by the Editor of this journal.

Availability of data and materials

The dataset supporting the conclusions of this article is included with the article.

Competing interests

The authors declared no potential conflicts of interest with respect to the

research, authorship, and publication of this article.

Funding

This work was supported by grants from National Natural Science Foundation of China (No. 81671918, and 81700365), National Key Research Program of China (2016YFC1101004) and Zhejiang Provincial Medical and Healthy Science Foundation of China (No. 2018KY874). The funding bodies had no role in the design of the study; in collection, analysis, and interpretation of data; and in drafting the manuscript.

Author contributions: WQ T designed the study, CY L and XF W performed data collection, analyzed the results, QQ F and HY Z drafted the manuscript. The authors have read and approved the final manuscript.

Acknowledgements

Not applicable.

References

1. Mao G-Y, Yang S-L, Zheng J-H. Cause of Axillary Bromidrosis. Plastic and Reconstructive Surgery. 2009;123(2):81e-2e.
2. Morioka D, Ohkubo F, Amikura Y. Clinical features of axillary osmidrosis: a retrospective chart review of 723 Japanese patients. The Journal of dermatology. 2013;40(5):384-8.
3. Mao G-Y, Yang S-L, Zheng J-H. Etiology and management of axillary bromidrosis: a brief review. International Journal of Dermatology. 2008;47(10):1063-8.

4. Hurley HJ. Diseases of the eccrine sweat glands. Dermatology. 1992:1514-37.
5. Ren Y, Liu W, Chen J, Wang J, Wang K, Zhou J, et al. A missense variant of the ABCC11 gene is associated with Axillary Osmidrosis susceptibility and clinical phenotypes in the Chinese Han Population. Scientific reports. 2017;7:46335.
6. Bechara FG, Sand M, Hoffmann K. Tumescent liposuction with dermal curettage for treatment of axillary osmidrosis and hyperhidrosis. Dermatologic Surgery. 2007;33(1):125-.
7. Seo SH, Jang BS, Oh CK, Kwon KS, Kim MB. Tumescent superficial liposuction with curettage for treatment of axillary bromhidrosis. Journal of the European Academy of Dermatology and Venereology. 2008;22(1):30-5.
8. Han JH, Kim J-K, Yoon KC, Shin HW. Versajet-Assisted Hydraulic Epilation Through Small Incisions for Axillary Osmidrosis. Aesthetic Plastic Surgery. 2018;42(3):617-24.
9. Shi Z, Yan X, Ye X. Modified Tumescent Superficial Suction with Curettage Treatment for Axillary Bromidrosis: Clinical Experience of 280 Cases. Aesthetic Plastic Surgery. 2014;38(1):151-5.
10. Park YJ, Shin MS. What is the best method for treating osmidrosis? Annals of Plastic Surgery. 2001;47(3):303-9.
11. Leyden JJ, McGinley KJ, Holzle E, Labows JN, Kligman AM. The microbiology of the human axilla and its relationship to axillary odor. Journal of Investigative Dermatology. 1981;77(5):413-6.
12. Fan YM, Wu ZH, Li SF, Chen QX. Axillary osmidrosis treated by partial removal of the skin and subcutaneous tissue en bloc and apocrine gland subcision. International Journal of Dermatology. 2001;40(11):714-6.
13. Park JH, Cha SH, Park SD. Carbon dioxide laser treatment vs subcutaneous resection of axillary osmidrosis. Dermatologic Surgery. 1997;23(4):247-51.
14. Wu W-H. Ablation of Apocrine Glands With the Use of a Suction-Assisted Cartilage Shaver for Treatment of Axillary Osmidrosis An Analysis of 156 Cases. Annals of Plastic Surgery. 2009;62(3):278-83.
15. Kao TH, Pan HC, Sun MH, Chang CS, Yang DY, Wang YC. Upper thoracic sympathectomy for axillary osmidrosis or bromidrosis. Journal of Clinical Neuroscience. 2004;11(7):719-22.
16. Xie A, Nie L, Tan Q. Local injection of botulinum toxin A: An alternative therapy for axillary osmidrosis. Journal of Dermatology. 2014;41(2):153-6.
17. Han X, Li F. Percutaneous ethanol injection for the treatment of axillary osmidrosis. Clinical and Experimental Dermatology. 2013;38(5):484-8.
18. Shin JY, Roh S-G, Lee N-H, Yang K-M. Osmidrosis Treatment Approaches A Systematic Review and Meta-Analysis. Annals of Plastic Surgery. 2017;78(3):354-9.
19. Ou LF, Yan RS, Chen IC, Tang YW. Treatment of axillary bromhidrosis with superficial liposuction. Plast Reconstr Surg. 1998;102(5):1479-85.
20. Li Y, Li W, Lv X, Li X. A refined minimally invasive procedure for radical treatment of axillary osmidrosis: combined tumescent liposuction with subcutaneous pruning through a small incision. Journal of plastic, reconstructive & aesthetic surgery : JPRAS. 2012;65(11):e320-1.

Tables

Table 3: Compare with other liposuction and curettage modalities

Author (year)	Operative methods	No. of patients	Results (%)			follow-up period (mean months)	Complications (%)
			good	fair	poor		
Ou et al.[21] (1998)	Superficial liposuction and subdermal scraping	20	90	5	5	6 to 27 (14)	20
Tsai et al.[23] (2001)	Liposuction and curettage	10	80	20	0	No mention	-
Lee et al.[24] (2006)	Liposuction and curettage	25	98	3	0	3 to 19 (10.7)	8
Kim et al.[25] (2008)	suction and curettage	65	92.3	4.6	3.1	6 to 17 (10.4)	10.7
Seo et al.[26] (2008)	Liposuction and curettage	43	72.1	18.6	9.3	3 to 54 (15.8)	10.7
Li et al.[22] (2011)	Liposuction with subcutaneous pruning	28	100	0	0	6 to 24 (12.8)	1.7
Shi et al.[27] (2014)	Suction with Curettage	280	93.2	6.8	0	5 to 35 (15.5)	6.4
Current study	liposuction-curettage with pruning	110	88.2	11.8	0	3 to 16 (10.2)	0.8

Figures

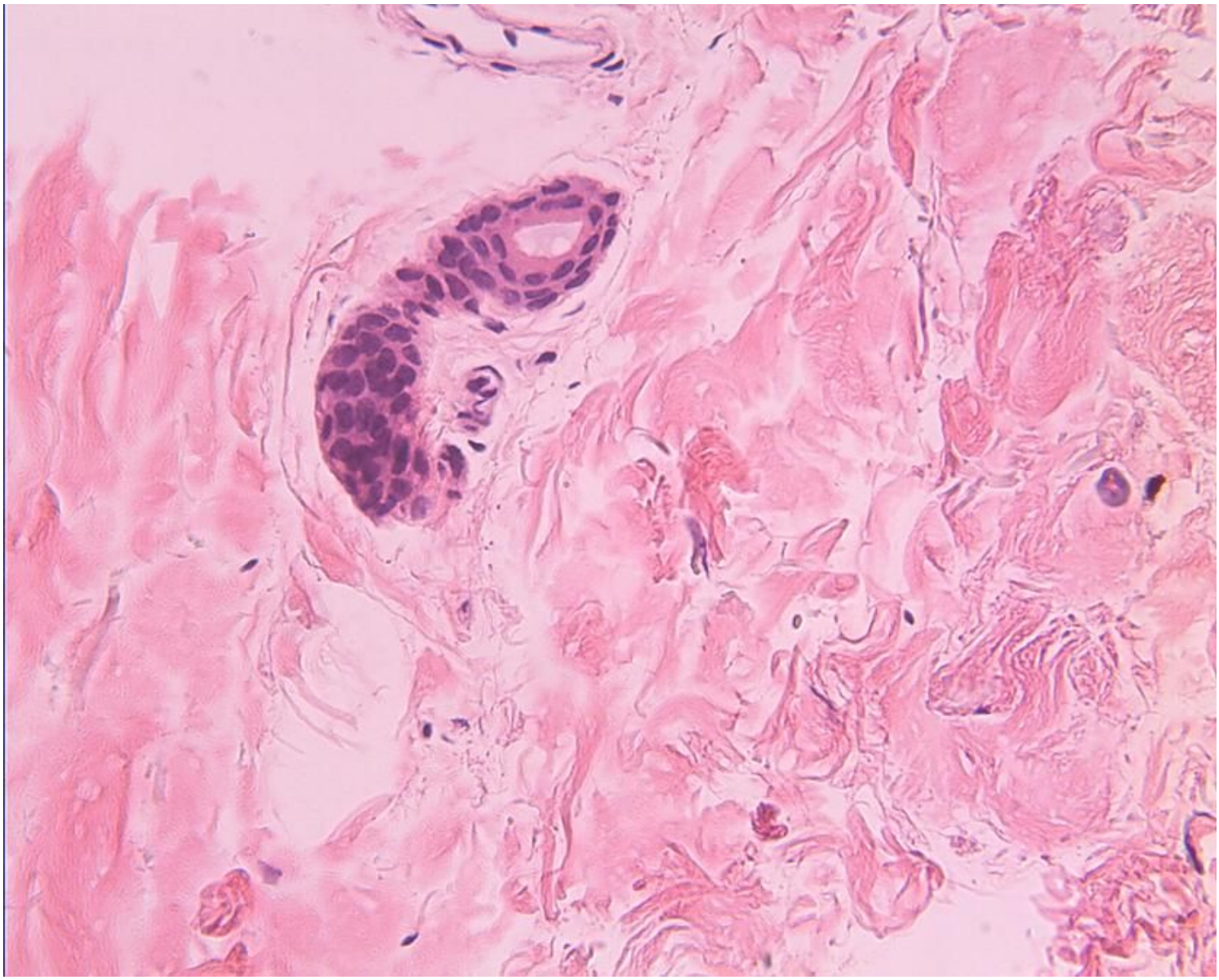

Figure 1

The postoperative histological specimen in cross-section view (H&E stain, ×400).

Figure 2

The preoperative histological findings in cross-section view (H&E stain, ×400).

Figure 3

A 23-year-old man who underwent the refined tumescent liposuction-curettage with pruning in small incisions. (A) Preoperative photo of left armpit. (B) Postoperative photo of twelve months after surgery. (C) Postoperative photo of fourteen months after surgery.

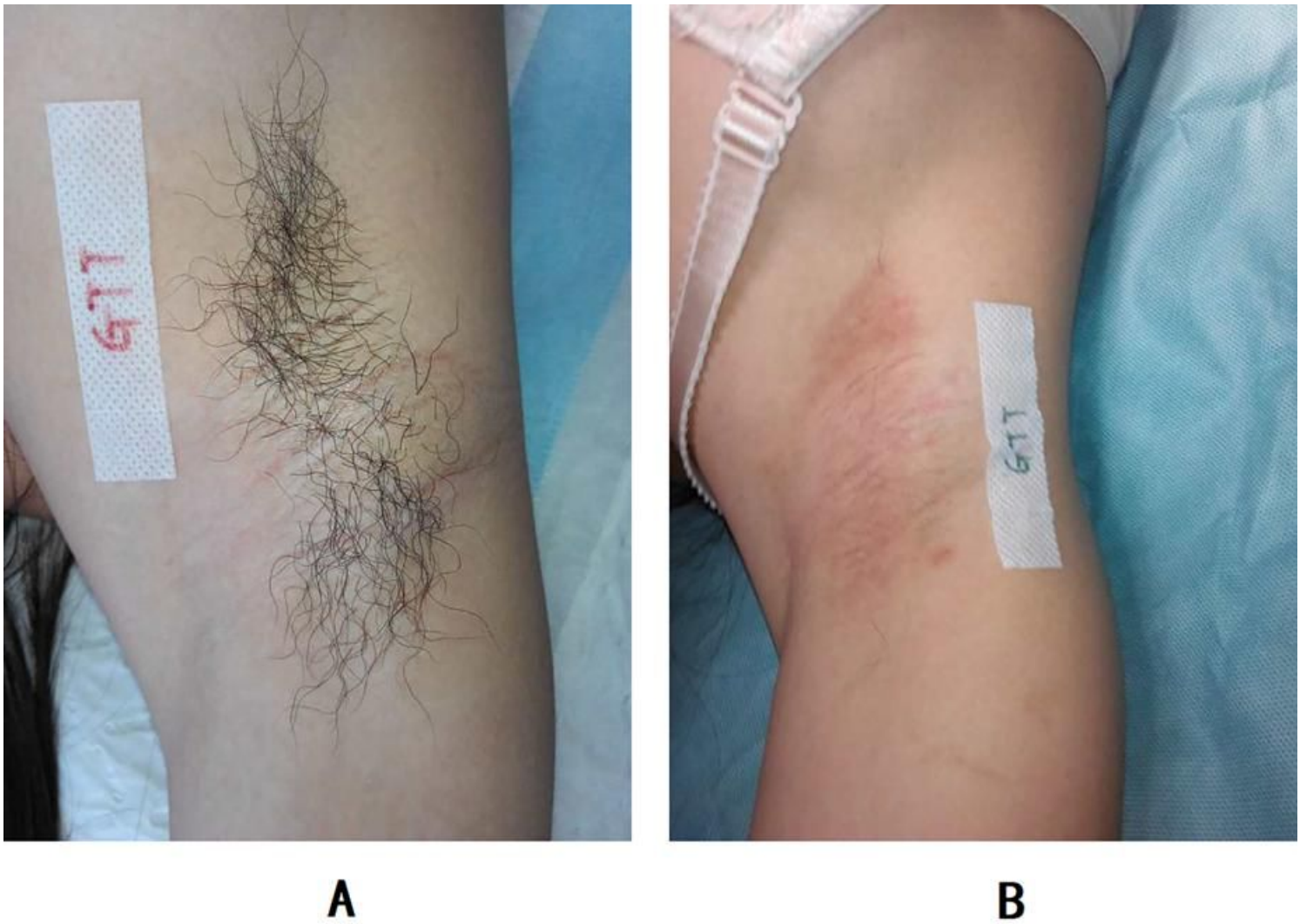

Figure 4

A 28-year-old woman who underwent the refined tumescent liposuction-curettage with pruning in small incisions. (A) Preoperative photo of left armpit. (B) Postoperative photo of six months after surgery.

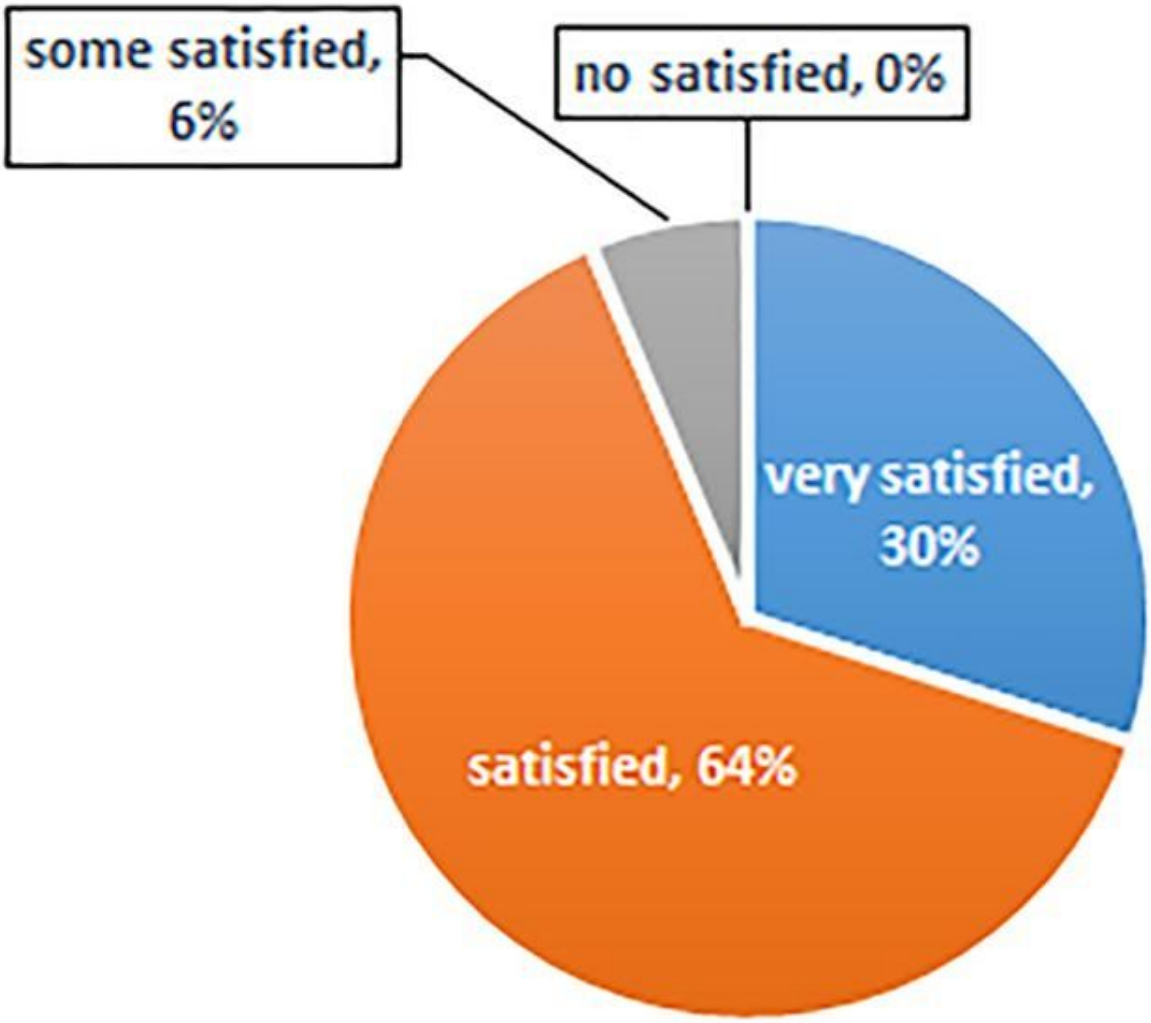

Figure 5

the subjective evaluations of 110 patients.

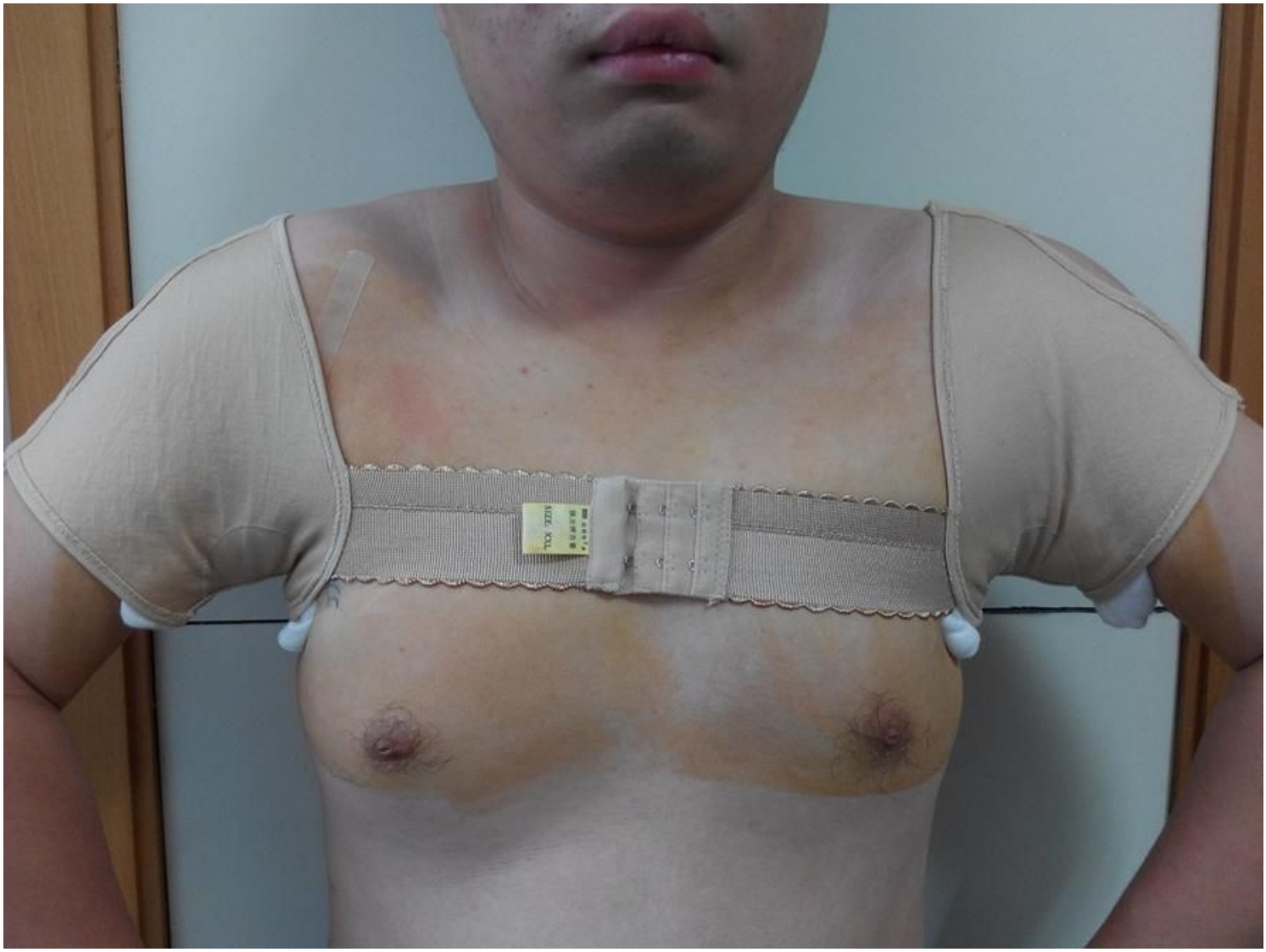

Figure 6

The patients wearing special elastic clothing to cover the wound.

Figure 7

Cotton ball bag was applied under the armpit in the sitting position.

Figure 8

The surgical area skin became the full-thickness skin (about 1 mm).

Figure 9

The eye scissors with the elbow facing down (the left index finger was used to assist the pressure and feel the thickness) were inserted through the small incision for pruning.

Figure 10

The solution was injected in each side for local anesthesia.

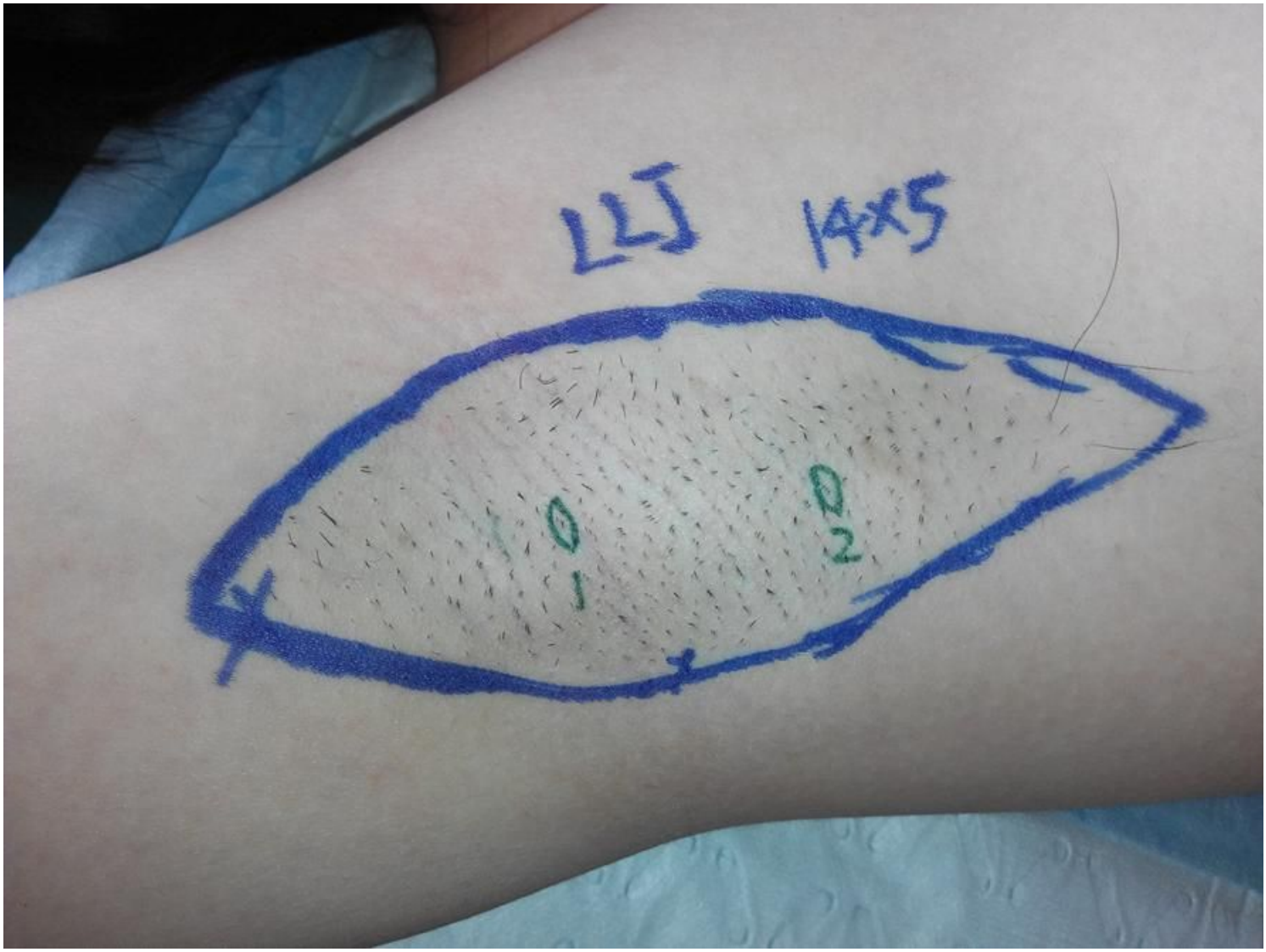

Figure 11

The axillary hair lines was marked after the axillary hair was shaved.

Supplementary Files

This is a list of supplementary files associated with this preprint. Click to download.

- renamed6d66a.3gp
- renamed2ff8b.mp4