Comparison of Clinical Outcomes Between Cephalomedullary Nails and Dynamic Hip Screws for Basicervical Proximal Femoral Fractures

Zhen Jian
Shanghai Pudong Hospital
Tao Lv
Shanghai Pudong Hospital
Rongguang Ao
Shanghai Pudong Hospital
Xinhua Jiang
Shanghai Pudong Hospital
Jianhua Zhou
Shanghai Pudong Hospital
Baoqing Yu (jianzhen21@126.com)
Shanghai Pudong Hospital

Research article

Keywords: Basicervical fractures, cephalomedullary nails, dynamic hip screws, Harris hip score

Posted Date: July 24th, 2020

DOI: https://doi.org/10.21203/rs.3.rs-37367/v1

Abstract

Background Basicervical proximal femoral fractures have greater biomechanical instability and higher incidence of implant-related complications than other types of proximal femoral fractures. The present retrospective study was performed to find a proper fixation treating basicervical proximal femoral fractures by a comparation of clinical outcomes between cephalomedullary nails and dynamic hip screws, and introduce our experience in surgical tricks and perioperative management.

Methods Between January 2015 and December 2018, 821 patients aged 60 years or older suffering from a proximal femoral fracture and receive internal fixation surgery were reviewed. 25 patients of basicervical femoral fractures were included in the study according to inclusion and exclusion criteria. 7 patients were treated with a DHS, 18 with the CMN. Relevant operational data and clinical evaluation were collected.

Results Reduction qualities of 6 patients were good (85.7%), 1 were acceptable (14.3%) in DHS Group and 14 of the 18 patients were good (77.8%), 4 were acceptable (22.2%) in CMN Group. The mean TAD in DHS Group of was 17.4 mm while 20.3 mm in CMN Group. Bone union had been achieved 19.9 weeks in DHS Group and 17.8 weeks in CMN Group. The mean Harris score at the final follow up was 83.9, 84.4 respectively in DHS and CMN Group with no significant difference.

Conclusions DHS was not inferior for the treatment of basicervical proximal femoral fractures compared to CMNs with blade type or two integrated screw type. When applied properly, both CMNs with blade type or two integrated screw type and DHS can achieve satisfied prognosis. Our unique experiences included anatomic reduction during surgery, anti-osteoporosis treatment and prolonged weight-bearing time.

Background

Proximal femoral fractures are common seen in clinic which is estimated to exceed 6.3 mn per year worldwide by 2050 [1, 2] and are commonly encountered among the elderly with high morbidity and mortality. With longer life expectancy increases, elderly patient always suffers osteopenia or even osteoporosis, resulting in reduced bone strength[3, 4]. Additionally, elder patients often accompany cardiovascular diseases, metabolic disease, lung diseases, and liver diseases. All can lead to a higher risk of fracture and postoperative complications[3–5].

Proximal femoral fractures are evenly divided into intertrochanteric and femoral neck fractures, and approximately 1.8–4.5% involves basicervical area[6–8]. As a special type of femoral neck fracture, the definition of basicervical proximal femoral fractures remains debates. According to anatomic location of the fracture, Parker[9] defines it as a fracture in which the fracture line runs along the anterior inferior attachment of hip joint capsule while Blair[10] as the fracture line moves through the junction region between the femoral neck and the intertrochanter. Based on X-ray images, Watson et al[11] defined the basicervical fractures more precisely as a 2-part fracture occurring at the base of femoral neck that was medial to the intertrochanteric line and exiting above the lesser trochanter but is more lateral than a

classic transcervical fracture. Basicervical proximal femoral fractures were specially included with 31B3 in AO fracture classification system[12].Due to the special location, it represents an intermediate type between intracapsular and extracapsular proximal femoral fractures.

These injuries often require operative management given the pain and functional limitations they cause for the elder patients. However, the basicervical fractures have greater inherent biomechanical instability and higher risk of implant-related complications than the classic intertrochanteric and femoral neck fractures. Several studies also have reported conflicting outcomes with different fixation methods of basicervical fractures. Biometrical studies have proved cephalomedullary nails (CMN) are able to sustain more cycles of loading and a higher absolute load than dynamic hip screw (DHS) systems[13]. Therefore, the advances in CMN theoretically can lead to better postoperative outcomes compared with DHS when treating unstable proximal fractures[14, 12]. In 2016, however, Watson[11] reported an incredible failure rate of 55% (6 of 11 patients) with intramedullary nails in the treatment of basicervical fractures.

The study summarized our treatment experience in 25 patients of basicervical fractures treated with DHS or CMN in our institution. One objective of this case series was to find a proper fixation treating basicervical proximal femoral fractures. As most study mainly focus on choices of fixations devices, little has been paid to reductions quality and perioperative management in elderly patients. Therefore, another objective of this study was to introduce our experience in surgical tricks and perioperative management.

Methods

Institutional review board approval and patients' informed consent were obtained for this retrospective study.

We reviewed radiographs and medical records of 821 patients aged 60 years or older suffering from a proximal femoral fracture and receive internal fixation surgery between January 2015 and December 2018 at Shanghai Pudong Hospital. Patients were included in our study if radiographs showed a basicervical peritrochanteric fracture of the proximal part of the femur, defined as a 2-part fracture at the base of the femoral neck that was medial to the intertrochanteric line and exited above the lesser trochanter but was more lateral than a classic transcervical fracture [11]. Fractures in which the lesser trochanter was a separate fragment or the fracture line exited distal to the lesser trochanter or out the lateral cortex of the greater trochanter were excluded. The X-ray films were reviewed by one trauma surgeon from the department of orthopedics and a professional radiology doctor to identify basicervical proximal femoral fractures. These 32 basicervical fractures patients meeting the requirement were further confirmed by CT examination. There were 7 patients excluded in which 2 patients without CT image and 5 involved with greater or lesser trochanter fracture (Fig. 1).

Reduction quality was assessed with the criteria proposed by Baumgaertner et-al[15] according to immediate postoperative fluoroscopic images, which were graded as good (< 5 varus/valgus and/or anteversion/retroversion), acceptable (5–10), or poor (> 10). The tip-apex distance (TAD) was measured on intraoperative fluoroscopic images. TAD is the sum of the distance in millimeters from the tip of the

lag screw to the apex of the femoral head as measured on an anteroposterior radiograph and that distance on a lateral radiograph after correction for magnification[16].

Postoperatively, anti-osteoporosis treatment was recommended to all patients. Those patients treated with CMN (Fig. 2, 3) were allowed immediate sitting as tolerated, and partial weight-bearing was indicated between the 7rd and the 14th postoperative days depending on the degree of reduction, systemic conditions, and pain. In patients treated with DHS (Fig. 4), active leg exercises on-bed were encouraged as tolerated, and partial weight-bearing was allowed 4 to 6 weeks after surgery.

Medical record including follow-up record and postoperative radiographs of patients included in the study series were reviewed by a senior-level resident. The function of the hip joint was evaluated by the modified Harris Hip Score postoperatively.

Statistical analysis

All continuous data are expressed as means and standard deviations. For statistical analysis, Student's t-test and Analysis of variance (ANOVA) was used for continuous data while Pearson's Chi-squared test and Fisher's exact test was used for categorical data. All statistical analyses were conducted using SPSS v15.0 (SPSS Inc., Chicago, IL, USA). Statistical significance was considered at $p < 0.05$.

Results

25 patients were included in the study. The choice of implant was based on surgeon’s preference. The followed-up period were 35.4 months and 30.8 months respectively in DHS and CMN Group.7 patients were treated with a DHS (4 females, mean age = 72.0 years), 18 with the CMN (6 with PFNA and 12 with INTERTAN, 11 females, mean age = 71.5 years). There was no statistic difference in age or sex distribution between two groups (Table 1).

Table 1
General Conditions

Variable	DHS Group	CMN Group	p Value
Patient Number	7	18	-
Sex Male/Female	3/4	7/11	1.0
Age (y)	72.0 ± 9.0(63–88)	72.2 ± 7.6(61–92)	0.951
Follow-up (mo)	35.4 ± 15.7(16–60)	30.8 ± 9.9(13–48)	0.381

According to immediate postoperative radiographs, the reduction qualities of 6 of the 7 patients were good (85.7%), 1 were acceptable (14.3%) in DHS Group and 14 of the 18 patients were good (77.8%), 4 were acceptable (22.2%) in CMN Group. The mean TAD in DHS Group of was 17.4 mm (range, 14–21 mm) while 20.3 mm (range, 16–23 mm) in CMN Group (Table 2).

Table 2
Clinical Conditions

Variable	DHS Group	CMN Group	p Value
TAD(mm)	17.4 ± 2.5(14–21)	20.3 ± 1.9(16–23)	0.005
Union period (w)	19.9 ± 4.1(17–29)	17.8 ± 2.3(12–22)	0.131
Harris hip score	83.9 ± 9.1(71–97)	84.4 ± 7.8(68–98)	0.873

Radiographic fracture union had been achieved 19.9 weeks (range, 17–29 weeks) in DHS Group and 17.8 weeks (range, 12–22 weeks) in CMN Group (Table 2). The mean Harris score at the final follow up was 83.9 (range, 71–97), 84.4 (range, 68–98) respectively in DHS and CMN Group with no difference (Table 2).

One patient treated with Intertan sustained reoperation due to excessive varus collapse and finally cut-out of lag screw although an acceptable reduction quality (5–10 valgus) was achieved during the surgery. Slight persistent pain occurred in 1 patient in CMN Group, possibly due to prominent PFNA, but the patients could still walk with the help of a cane, and there was no need for implant removal. The patient in DHS Group with acceptable reduction quality sustained excessive displacement who refuse to accept second surgery.

Discussion

Basicervical proximal femoral fracture is a special type of fracture located in the intermediate border of intracapsular and extracapsular fracture. As a result, they have varying definitions in the literature[10, 11, 17]. Due to its greater biomechanical instability and higher surgery failure rates, it's of significant importance to get proper diagnosis. Watson[11] defined the basicervical fractures more strictly based on X-Ray as occurring at the base of the femoral neck and exiting above the lesser trochanter but was more lateral than a classic transcervical fracture. To our knowledge, there's no prior study to use CT to further precise basicervical fracture. In our study, 5 of all suspect basicervical fracture was excluded and turned out to be intertrochanter fracture by CT scan (Fig. 1). In diagnosis, X-ray alone is not accurate enough for the diagnose of basicervical fracture. As a periarticular fracture, CT scan is highly recommended to confirm the integrity of the greater and lesser trochanters with the shaft. As a result, the prevalence of basicervical proximal fracture treated with internal fixation in our organization was 3.0% (25/821).

The primary factors that predispose a patient with internal fixation to poor prognosis include highly unstable fracture, inadequate reductions, improper fixation chosen and poor rehabilitation strategy[17, 18]. In addition, low bone density is an independent risk factor when treating with internal fixation[19]. Watson[11] reported the failure rate of CMN was 54.5% (6/11) and suggested that CMN may be inadequate for fixation of 2-part basicervical fractures. Different CMNs they used in the study produced less effective compression between fractures which may be one reason of high failure rate. Additionally, low bone density might be an ignored factor as the patients included were older than most studied (the

average age in the failure group was 75 years old). Anti-osteoporosis treatment was also recommended to the patients after surgery in our study.

Basicervical hip fractures are reported with high failure rates after the treatment with osteosynthesis[1, 11]. As femoral neck fracture, basicervical fracture is closer to intertrochanter with large pauwel's angle that demonstrates high shear force when bearing weight. It has even greater biomechanical instability than intertrochanteric fractures[20]. Kuokkanen[21] reported that the use of multiple screws was not recommended in the treatment of basicervical fracture. When treated as an extracapsular fracture, both biomechanical and clinical studies have revealed better stability and clinical outcome[14, 13, 10, 12]. It can be treated with DHS or CMN. In a biomechanical study of different internal fixation techniques, Blair[10] noticed that the lateral position of the basicervical fracture line minimized the support of fixation provided from the lateral cortex. As a result, basicervical fracture has more collapse and failure than intertrochanteric fracture.

Certainly, there is considerable debate regarding the optimal surgical fixation of basicervical fractures[11, 14, 8]. Biomedical studies have shown CMNs could provide an increased load to failure and great anti-rotation properties[13]. The fault tolerance of CMNs insertion is relatively high with minimal invasive to the soft tissue and relative stability of reduction that are bonded to decrease operational duration, surgical trauma, and the inability of the implant to survive until fracture union[8]. However, in our study, the patient treated with Intertan sustained reoperation due to excessive varus collapse and finally cut-out of lag screw although an acceptable reduction quality (5–10 valgus) was achieved during the surgery. As fracture reduction is a significant component in the prognosis of uneventful fracture healing, efforts should be devoted to improvements in reduction. Reduction in valgus and positive buttress alignment would have a positive effect on postoperative fracture stability. Positive buttress is hard to get in basicervical proximal femoral fracture due to dilemmatic area of the fracture. Anatomic reduction may be the key to resist the shear force. Therefore, the reduction criteria for hip fractures described by Fogagnolo is not fit for basicervical fractures which allows 20 degree of angulation in lateral view [22]. The criteria of reduction of basicervical fracture should be even stricter than that provided by Baumgaertner[15]. The insertion process of internal fixation may cause further displacement of the fracture, so the maintenance of the fracture alignment and timely fluoroscopy during the operation are necessary.

Our study showed there was no significant difference in function recovery and complication rate between two group. The result also consists with the study by Kim et al[8] who compared the effects of DHS and CMN on the treatment of basicervical fractures. They proved that CMN with blade type or two integrated screw type could drastically reduce the failure rates in the osteosynthesis of basicervical hip fractures. PFNA was designed to improve angular and rotational stability with the blade type lag screw while InterTAN nail provides rotational stability and immediate intraoperative linear compression with two integrated interlocking lag and compression screws. Inserting the PFNA blade can also compact the cancellous bone and provide additional stability[12]. As for unstable proximal femeral frature, PFNA and InterTAN nail are effective CMN options[23, 24]. TAD value of CMN is considered a key indicator to predict postoperative cut-out complications. Patients with a TAD < 25 mm were less likely to encounter screw cut-

outs complication[24]. In our study and average TAD was 20.3 mm and associated with fewer failures than previous studies.

The DHS has long been considered the “gold standard” for operative fixation of peritrochanteric fractures[25] until the advances in CMN were reported[14, 22, 25]. However, current study showed DHS was still effective and possessed unique advantages treating basicervical hip fractures. Better reduction could be obtained as the distal fragment was retracted laterally using a bone hook or a Hohmann retractor after traction of the fractured bone. Then one or two k-wire was inserted to contral rotation of the proximal fragment and maintain the reduction fixation during the fixtion. The K-wire could also be used as guide pin of the derotation screw. The additional derotation screw could improve strength and rotational control of DHS in a biomedical study[26] although ambivalent results have been reported by Imren[13]. As basicervical fractures in the elder population treated with osteosynthesis resulted to high rates of surgical complications, revision surgery is also an importance factor when choosing initial treatment. In cases of failure, conversion hip arthroplasty can be a favorite treatment option. Bercik et-al[27] compared outcomes of conversion total hip arthroplastys for femoral neck fractures initially fixed with DHS versus cephalomedullary nails and reported CMNs were difficult to remove and their removal can result in complications during conversion arthroplasty. Thus, it would prolong operative time and increase blood loss for patients and even cause persistent hip pain after conventional surgery in the CMN group[27, 28].

The goal of fracture treatment is always early functional rehabilitation. However, due to shear stress at the basicervical site, load commitment may affect the healing of the fracture and increase postoperative complications. We prolonged the time to weight-bear after surgery but encourage active leg exercises on-bed. That maybe another reason of less complication rate of our study.

There are several unavoidable limitations in our study. First, our study was designed retrospectively with the small number of patients. More date with multiple trauma centers may make our conclusion more convincing. Second, various factors were proposed but could not be further analyzed in this study. Reduction quality and BMD are two important factors influencing the prognosis, but we couldn’t get a conclusion whether they play a role in the complications due to limited data and small sample size. However, we will design more rigorous prospective clinical studies to analysis factors of one certain device to further investigate the root cause of difficulty of treating basicervical fractures.

Conclusion

This study showed DHS was not inferior for the treatment of basicervical proximal femoral fractures compared to CMNs with blade type or two integrated screw type. When applied properly, both CMNs with blade type or two integrated screw type and DHS can achieve satisfied prognosis. Our unique experiences included anatomic reduction during surgery, anti-osteoporosis treatment and prolonged weight-bearing time.

Abbreviations

DHS
dynamic hip screw; CMN:cephalomedullary nails; TAD:tip-apex distance; ANOVA:Analysis of variance

Declarations

Ethics approval and consent to participate

This study was reviewed and approved by the Institutional Review Board of Shanghai Pudong Hospital (Approval No.2016005). The study was conducted in compliance with the ethical principles originating in or derived from the Declaration of Helsinki and in compliance with Good Clinical Practice Guidelines. All patients provided signed informed consent.

Consent for publication

Written consent to publish the content of this report along with the accompanying images was obtained from all patients.

Availability of data and materials

The datasets used and analyzed during the study are available from the corresponding author on reasonable request.

Competing interests

The authors declare that they have no competing interests.

Funding

This work was supported by the Natural Science Foundation of China (Project no. 81971753), Program for Medical Key Department of Shanghai (Grant No. ZK2019C01), The Outstanding Clinical Discipline Project of Shanghai Pudong (Grant No. PWYgy2018-09), The fund of Key Disciplines Group Construction Project of Pudong Health Bureau of Shanghai (Grant No. PWZxq2017-11), Program for Outstanding Leader of Shanghai (Grant No. 046).

Authors’ contributions

ZJ, TL and BY conceived and designed the experiments. RA XJ and JZ analyzed the data. ZJ and TL wrote the paper. All authors read and approved the final manuscript.

Acknowledgments

We thank LetPub (www.letpub.com) for providing linguistic assistance during the preparation of this manuscript.

References

1. Sogaard AJ, Holvik K, Meyer HE, Tell GS, Gjesdal CG, Emaus N, Grimnes G, Schei B, Forsmo S, Omsland TK (2016) Continued decline in hip fracture incidence in Norway: a NOREPOS study. Osteoporos Int 27 (7):2217-2222. doi:10.1007/s00198-016-3516-8
2. Wang ZH, Li KN, Lan H, Wang XD (2019) A Comparative Study of Intramedullary Nail Strengthened with Auxiliary Locking Plate or Steel Wire in the Treatment of Unstable Trochanteric Fracture of Femur. Orthop Surg. doi:10.1111/os.12595
3. Meinberg EG, Agel J, Roberts CS, Karam MD, Kellam JF (2018) Fracture and Dislocation Classification Compendium-2018. J Orthop Trauma 32 Suppl 1:S1-s170. doi:10.1097/bot.0000000000001063
4. Broderick JM, Bruce-Brand R, Stanley E, Mulhall KJ (2013) Osteoporotic hip fractures: the burden of fixation failure. ScientificWorldJournal 2013:515197. doi:10.1155/2013/515197
5. Swart E, Makhni EC, Macaulay W, Rosenwasser MP, Bozic KJ (2014) Cost-effectiveness analysis of fixation options for intertrochanteric hip fractures. J Bone Joint Surg Am 96 (19):1612-1620. doi:10.2106/jbjs.M.00603
6. Saarenpaa I, Partanen J, Jalovaara P (2002) Basicervical fracture–a rare type of hip fracture. Arch Orthop Trauma Surg 122 (2):69-72. doi:10.1007/s004020100306
7. Chen CY, Chiu FY, Chen CM, Huang CK, Chen WM, Chen TH (2008) Surgical treatment of basicervical fractures of femur–a prospective evaluation of 269 patients. J Trauma 64 (2):427-429. doi:10.1097/01.ta.0000239255.47280.6f
8. Kim JT, Ha YC, Park CH, Yoo JI, Kim TY (2019) Single screw type of lag screw results higher reoperation rate in the osteosynthesis of basicervical hip fracture. J Orthop Sci. doi:10.1016/j.jos.2019.02.010
9. Mallick A, Parker MJ (2004) Basal fractures of the femoral neck: intra- or extra-capsular. Injury 35 (10):989-993. doi:10.1016/j.injury.2003.10.019
10. Blair B, Koval KJ, Kummer F, Zuckerman JD (1994) Basicervical fractures of the proximal femur. A biomechanical study of 3 internal fixation techniques. Clin Orthop Relat Res (306):256-263
11. Watson ST, Schaller TM, Tanner SL, Adams JD, Jeray KJ (2016) Outcomes of Low-Energy Basicervical Proximal Femoral Fractures Treated with Cephalomedullary Fixation. J Bone Joint Surg Am 98 (13):1097-1102. doi:10.2106/jbjs.15.01093
12. Wang Q, Gu XH, Li X, Wu JH, Ju YF, Huang WJ, Wang QG (2019) Management of Low-Energy Basicervical Proximal Femoral Fractures by Proximal Femoral Nail Anti-Rotation. Orthop Surg 11 (6):1173-1179. doi:10.1111/os.12579
13. Imren Y, Gurkan V, Bilsel K, Desteli EE, Tuna M, Gurcan C, Tuncay I, Sen C (2015) Biomechanical comparison of dynamic hip screw, proximal femoral nail, cannulated screw, and monoaxial external fixation in the treatment of basicervical femoral neck fractures. Acta Chir Orthop Traumatol Cech 82 (2):140-144

14. Hu SJ, Yu GR, Zhang SM (2013) Surgical treatment of basicervical intertrochanteric fractures of the proximal femur with cephalomeduallary hip nails. Orthop Surg 5 (2):124-129. doi:10.1111/os.12038
15. Baumgaertner MR, Curtin SL, Lindskog DM (1998) Intramedullary versus extramedullary fixation for the treatment of intertrochanteric hip fractures. Clin Orthop Relat Res (348):87-94
16. Baumgaertner MR, Curtin SL, Lindskog DM, Keggi JM (1995) The value of the tip-apex distance in predicting failure of fixation of peritrochanteric fractures of the hip. J Bone Joint Surg Am 77 (7):1058-1064. doi:10.2106/00004623-199507000-00012
17. Kweon SH, Lee SH, Kook SH, Choi YC (2017) Outcomes of Cephalomedullary Nailing in Basicervical Fracture. Hip Pelvis 29 (4):270-276. doi:10.5371/hp.2017.29.4.270
18. Bojan AJ, Beimel C, Taglang G, Collin D, Ekholm C, Jönsson A (2013) Critical factors in cut-out complication after Gamma Nail treatment of proximal femoral fractures. BMC Musculoskelet Disord 14:1-1. doi:10.1186/1471-2474-14-1
19. Tyagi V, Akinbo O (2017) Conversion Total Hip Arthroplasty After Failed Basicervical Hip Fracture Fixation: A Case Report and Review of Literature. Iowa Orthop J 37:29-34
20. Su BW, Heyworth BE, Protopsaltis TS, Lipton CB, Sinicropi SM, Chapman CB, Kuremsky MA, Rosenwasser MP (2006) Basicervical versus intertrochanteric fractures: an analysis of radiographic and functional outcomes. Orthopedics 29 (10):919-925. doi:10.3928/01477447-20061001-04
21. Kuokkanen HO (1991) Treatment options for basicervical fractures of the femoral neck. A clinical follow-up. Acta Orthop Belg 57 (2):162-168
22. Fogagnolo F, Kfuri M, Jr., Paccola CA (2004) Intramedullary fixation of pertrochanteric hip fractures with the short AO-ASIF proximal femoral nail. Arch Orthop Trauma Surg 124 (1):31-37. doi:10.1007/s00402-003-0586-9
23. Nherera L, Trueman P, Horner A, Watson T, Johnstone AJ (2018) Comparison of a twin interlocking derotation and compression screw cephalomedullary nail (InterTAN) with a single screw derotation cephalomedullary nail (proximal femoral nail antirotation): a systematic review and meta-analysis for intertrochanteric fractures. J Orthop Surg Res 13 (1):46-46. doi:10.1186/s13018-018-0749-6
24. Gavaskar AS, Tummala NC, Srinivasan P, Gopalan H, Karthik B, S S (2018) Helical Blade or the Integrated Lag Screws: A Matched Pair Analysis of 100 Patients With Unstable Trochanteric Fractures. Journal of orthopaedic trauma 32 (6):274-277. doi:10.1097/BOT.0000000000001145
25. Zhou W, Xia T, Liu Y, Cao F, Liu M, Liu J, Mi B, Hu L, Xiong Y, Liu G (2019) Comparative study of sacroiliac screw placement guided by 3D-printed template technology and X-ray fluoroscopy. Arch Orthop Trauma Surg:10.1007/s00402-00019-03207-00406. doi:10.1007/s00402-019-03207-6
26. Johnson J, Deren M, Chambers A, Cassidy D, Koruprolu S, Born C (2019) Biomechanical Analysis of Fixation Devices for Basicervical Femoral Neck Fractures. J Am Acad Orthop Surg 27 (1):e41-e48. doi:10.5435/JAAOS-D-17-00155
27. Bercik MJ, Miller AG, Muffly M, Parvizi J, Orozco F, Ong A (2012) Conversion total hip arthroplasty: a reason not to use cephalomedullary nails. J Arthroplasty 27 (8 Suppl):117-121. doi:10.1016/j.arth.2012.04.009

28. Hesse B, Gachter A (2004) Complications following the treatment of trochanteric fractures with the gamma nail. Arch Orthop Trauma Surg 124 (10):692-698. doi:10.1007/s00402-004-0744-8

Figures

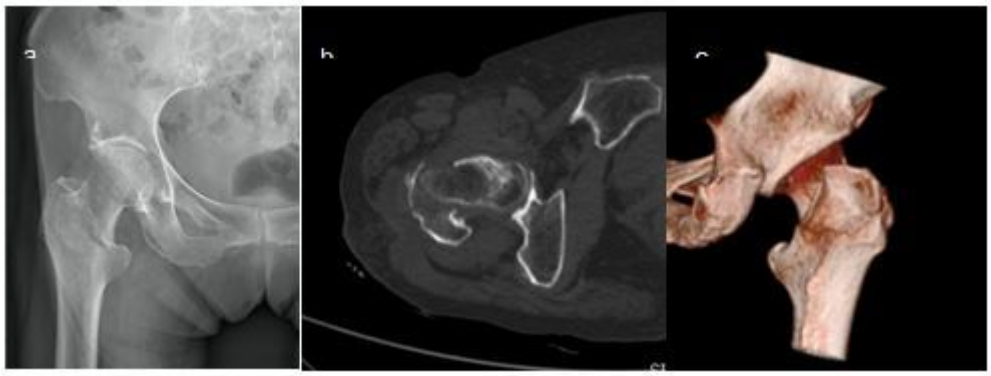

Figure 1

one patient of proximal femoral fracture. a, preoperational anteroposterior radiograph showed basicervical fracture. b, greater trochanter fracture involved was found in CT scan image. c, more fracture details were showed by 3-D reconstruction.

Figure 2

one 74-year-old female patient of basicervical proximal femoral fracture. a, preoperational anteroposterior radiograph. b, anteroposterior radiograph of the patient acquired after open reduction and internal fixation with the InterTan. c, anteroposterior radiograph showed bone union of the patient acquired 3 months after surgery.

Figure 3

one 81-year-old female patient of basicervical proximal femoral fracture. a, preoperational anteroposterior radiographs. b, anteroposterior radiograph of the patient acquired after open reduction and internal fixation with the PFNA. c, anteroposterior radiograph of the patient acquired 19 months after surgery.

Figure 4

one 63-year-old male patient of basicervical proximal femoral fracture. a, preoperational anteroposterior radiograph. b, anteroposterior radiograph of the patient acquired after open reduction and internal fixation with the DHS. c, bone union showed in anteroposterior radiograph of the patient acquired 14 months after surgery.