Transjugular Intrahepatic Portosystemic Shunt In COVID-19 Patient: A Case Report

Daniel Simões de Oliveira
Rede D`Or São Paulo

José Ragide Jamal Rímoli
Rede D`Or São Paulo

Leonardo Guedes Moreira Valle
Rede D`Or São Paulo

Bárbara Burza Benini
Rede D`Or São Paulo

Luiz Tenório de Brito Siqueira (siqueiraluiz85@gmail.com)
Rede D`Or São Paulo

Case Report

Keywords: Transjugular intrahepatic portosystemic shunt (TIPS), SARS-CoV-2 (COVID-19), Orotracheal intubation (OTI)

Posted Date: June 23rd, 2020

DOI: https://doi.org/10.21203/rs.3.rs-37542/v1

Abstract

Transjugular intrahepatic portosystemic shunt (TIPS) should be considered in all liver transplant candidates, besides being a life-saving procedure in bleeding from esophageal or gastric varices. In this case, we describe the management of a patient with diagnosis of coronavirus (COVID-19) with variceal bleeding in an emergency situation with worsening of pulmonary function.

Case Report

A 57-year-old male diabetic and alcoholic cirrhotic patient, on transplant list, entered the emergency room with general malaise and dyspnea. After exams collection on admission, leukocytosis and increased C-reactive protein were identified, and antibiotic therapy was started with Piperacillin plus Tazobactam. The patient developed renal dysfunction with hyperkalaemia and acidosis, in addition to hyponatremia, being referred to the intensive care unit with fluctuating level of consciousness, with massive ascites, worsening of ventilatory patterns, but hemodynamically stable. He evolved with the need for orotracheal intubation (OTI) after 5 days of the admission, and the diagnosis of coronavirus (COVID-19) was confirmed, in addition to acute deep vein thrombosis, requiring anticoagulant therapy.

The general condition worsened, with the patient presenting upper gastrointestinal bleeding 7 days after the OTI, requiring transfusion of red blood cells and cryoprecipitate, in addition to the introduction of vasoactive drugs. Terlipressin was started and referred for angiotomography with gastric and esophageal varices of large caliber being identified, and endoscopy band ligation. The patient showed improvement in ventilatory patterns, but continued to have subsequent bleeding with a drop in hematocrit to 24%. In spite of endoscopy treatment, TIPS was indicated to control recurrence of upper digestive bleeding. Liver function was consistent with Child C 10, MELD 30, bilirubin was 3,1mg/dl, platelets 30.000/mm3, INR 2,4 and Albumin 2,1 mg/dl.

Before and after the procedure, all recommended safety and secutiry measures by World Health Organization (WHO) have been adopted.
For the interventional radiologist, the mandatory individual equipment consists of use of appropriate PPE for standard, contact and airborne precautions. N95 or PFF2 standard masks or equivalent, and gowns, gloves, eye protection, aprons and shoes covers. These control measures described are important to minimize intra-institutional spread of SARS-CoV-2 and COVID-19, and should not be underestimated (1).

Standard TIPS access has started from the right internal jugular vein, guided by Ultrasound and fluoroscopy, followed by the 12F introducer implant. Right hepatic vein was catheterized through a MP catheter and a portogram was performed. The access of right portal vein branch was performed with RUPS-100 (Figure 1), followed by catheterization with hydrophilic guidewire and introduction of pigtail catheter to measure the stent and a pre-dilatation of the transhepatic path. IVC pressure was 17 mmHg, and indirect portal vein pressure measured 38 mmHg.

Stent implantation was performed with VIATORR 10mm x 8cm (Gore), followed by dilatation of the TIPS stent with Mustang 10mm balloon (Boston Scientific). A post-venoplasty portogram (Figure 2) showed improvement in IVC pressure (29 mmHg), and direct portal vein pressure (21 mmHg). The portosystemic gradient was 21 mmHg and drop to 8 mmHg.

There were no immediate complications with the procedure. At 2-weeks follow-up, the patient reported no symptoms of portal hypertension, including no further episodes of bleeding, and achieved a significant improvement in lung function, resulting in extubation, as well as in computed tomographic pattern (Figure 3).

Discussion

Faced with the SARS COV-2 pandemic, new dilemmas have arisen in medical practice, including in interventional radiology (2,3,4). Discussions about the indications and the timming for medical procedures have surfaced with the current pandemic. In this case, the patient had alcoholic cirroshis, presenting hemorragic bleeding with severe hemodynamic repercussions, and most of all, with a poor respiratory condition due to coronavirus infecction (mechanical ventilation and unfavorable evolution).

In a multidisciplinary discussion, TIPS was chosen as the therapy to control the digestive bleeding, in view of the lack of endoscopic control. Several factors were listed at the discussion: potentially fatal acute hemorrhagic condition; severe respiratory condition; current knowledge of the new coronavirus pathology; patient at list of transplant with potential evolution of to final cure; suitable conditions of intensive care for patient and the local population (5).

Until now, there are no reports linking the occurrence of hemorrhagic events in patients infected with the coronavirus, the probable etiology for bleeding being secondary to liver disease itself. Recent reports describe that coronavirus infection causes laboratory alterations such as leukocytosis, thrombocytopenia, enlargement of prothrombin time (PT), activated partial thromboplastin time thromin-antithrombin complex (APTT), fibrin-degradation products an D-dimers and clinically manifesting as disseminated intravascular coagulopathy, events also seen in other viral infections including human immunodeficiency (HIV), Ebola, Zika and Chikungunya viruses (3).

Among the main established TIPS indications, the following stand out: refractory ascites, varicose bleeding refractory to endoscopic treatment and prevention of bleeding secondary to varicose veins (6,7). In the scope of refractory variceal bleeding, endoscopic therapy aims at a portal gradient level less than 12 mmHg, associated with the searching of systemic shunts, which were not present in the case (6,8).

It is not uncommon in the practice of interventional radiology, especially in acute cases, to perform TIPS in patients with associated pulmonary conditions, however due to coronavirus infection, especially with unfavorable evolution, is a novelty.

There was a successful attempt to resolve the patient's hemorrhagic condition. However, we do not have sufficient knowledge of the new virus, as well as its systemic implications and possible particular interactions with interventional radiology procedures.

Conclusion

There were multiple discussions about the review of indications and appropriate moments for carrying out the procedures. There is a need to customize each case and procedure, assessing their needs and possible repercussions. However, acute and potentially fatal clinical conditions are present as little altered and fundamentals indications. There is even a need to policing in order to avoid sub-indication, respecting the communit context and moment at pandemic situation.

Declarations

Compliance with Ethical Standards

Funding: This study was not supported by any funding.

Conflict of Interest: The authors declare that they have no conflict of interest.

Ethical Approval: All procedures performed in studies involving human participants were in accordance with the ethical standards of the institutional and/or national research committee and with the 1964 Helsinki declaration and its later amendments or comparable ethical standards.

Informed Consent: Informed consent was obtained from all individual participants included in the study.

Consent for Publication: Consent for publication was obtained for every individual person's data included in the study

References

1. Ierardi, A.M., Wood, B.J., Gaudino, C. *et al.*How to Handle a COVID-19 Patient in the Angiographic Suite. *Cardiovasc Intervent Radiol* **43,** 820–826 (2020). https://doi.org/10.1007/s00270-020-02476-8

2. Eur Heart J Acute Cardiovasc Care.2020 Apr 29:2048872620922788. doi: 10.1177/2048872620922788.

3. MMW Fortschr Med.2020 May;162(9):40-45. doi: 10.1007/s15006-020-0475-y.

4. Nejm, March 23 2020, Fair Allocation of Source Medical Resources in the Time of Covid-19 DOI: 10.1056/NEJMsb2005114

5. Bikdeli, Behnood, et al. "COVID-19 and thrombotic or thromboembolic disease: implications for prevention, antithrombotic therapy, and follow-up." *Journal of the American College of*

Cardiology(2020).

6. Quality Improvement Guidelines for Transjugular Intrahepatic Portosystemic Shunts Sean R. Dariushnia, MDa, 2016.

7. Garcia-Pagan JC, Caca K, Bureau C, et al. Early use of TIPS in patients with cirrhosis and variceal bleeding. N Engl J Med 2010; 362: 2370–2379.

8. Khan S, Tudur Smith C, Williamson P, Sutton R. Portosystemic shunts versus endoscopic therapy for variceal rebleeding in patients with cirrhosis. Cochrane Database Syst Rev 2006: CD000553.

Figures

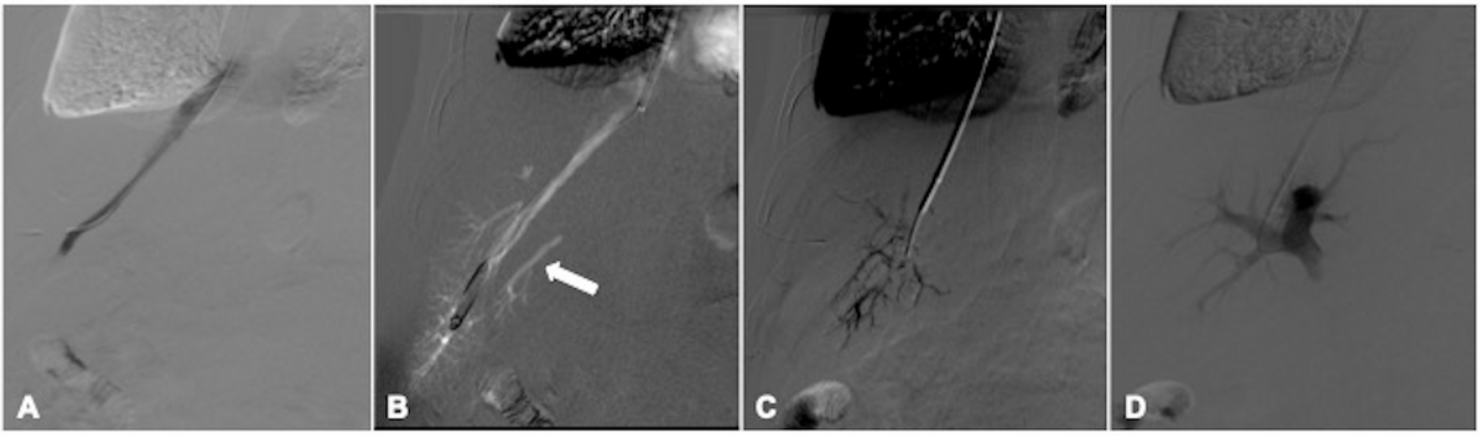

Figure 1

A 57-year-old male diabetic and alcoholic cirrhotic patient, on transplant list, with diagnosis of coronavirus (COVID-19), presented with variceal bleeding. Right hepatic vein was catheterized through a MP catheter (A) and a portogram was performed (B), being visualized the target portal branch (arrow). The access of right portal vein branch was performed with RUPS-100 (C), followed by catheterization with hydrophilic guidewire (D).

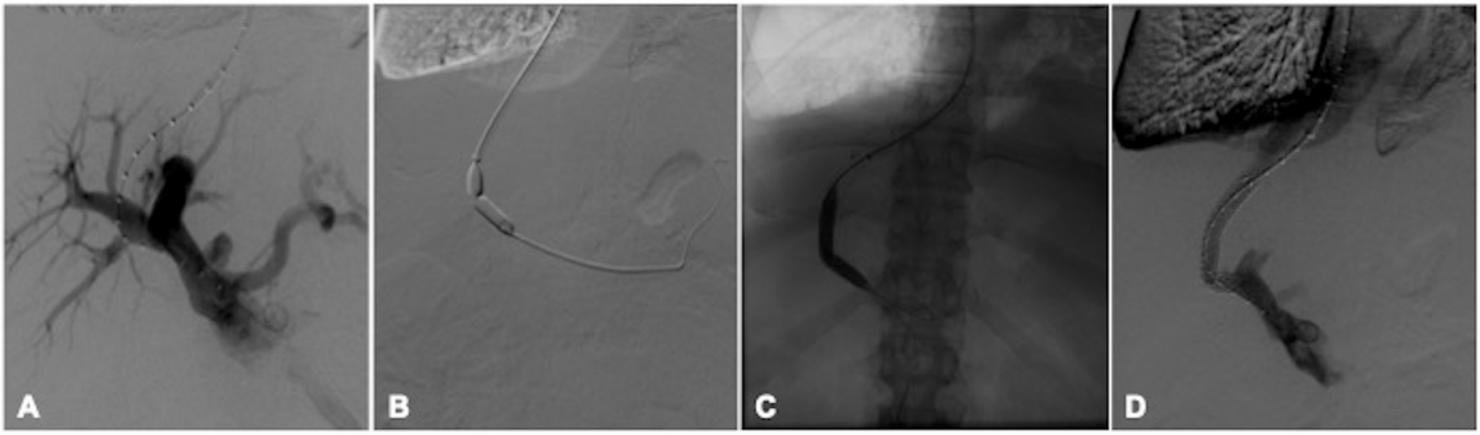

Figure 2

A 57-year-old male diabetic and alcoholic cirrhotic patient, on transplant list, with diagnosis of coronavirus (COVID-19), presented with variceal bleeding. Introduction of pigtail catheter to measure the stent (A) and a pre-dilatation of the transhepatic path (B). Stent implantation was performed, followed by dilatation of the TIPS stent with X mm balloons (C). Post-venoplasty showed improvement in portosystemic gradient (D).Figure 2. A 57-year-old male diabetic and alcoholic cirrhotic patient, on transplant list, with diagnosis of coronavirus (COVID-19), presented with variceal bleeding. Introduction of pigtail catheter to measure the stent (A) and a pre-dilatation of the transhepatic path (B). Stent implantation was performed, followed by dilatation of the TIPS stent with X mm balloons (C). Post-venoplasty showed improvement in portosystemic gradient (D).

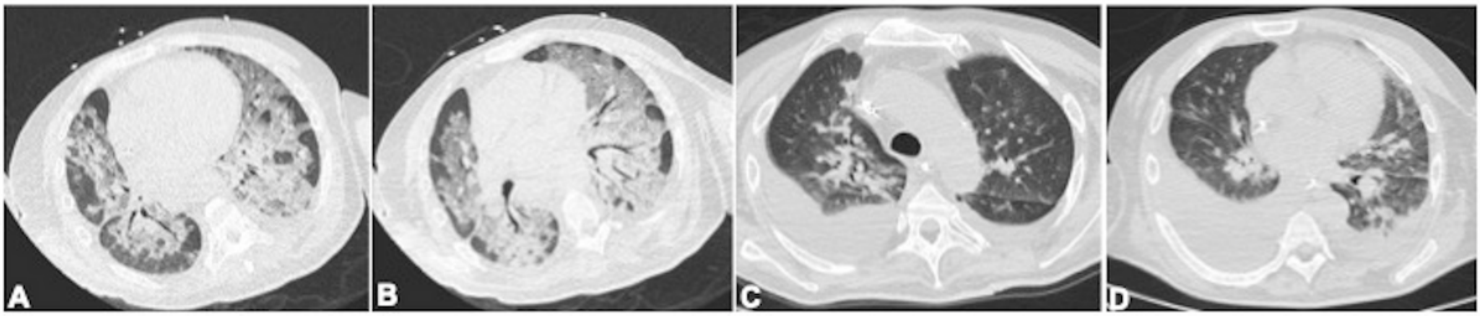

Figure 3

A 57-year-old male diabetic and alcoholic cirrhotic patient, on transplant list, with diagnosis of coronavirus (COVID-19), presented with variceal bleeding. Pre-TIPS Computed Tomography demonstrating a pattern of severe involvement of the lung parenchyma compatible with COVID-19, presenting opaque opacifications in bilateral ground glass diffuse (A,B). Post-TIPS Computed Tomography after two weeks demonstrating decreasing of lung involvment, with less ground glass opacifications, but bilateral pleural effusion (C,D)