Improved Prognosis for Recurrent Epithelial Ovarian Cancer By early Diagnosis and ^{125}I Seeds Implantation During Suboptimal Secondary Cytoreductive Surgery: A Case Report and Literature Review

lin xiao (1258210371@qq.com)
the first affiliated hospital of chongqing medical university https://orcid.org/0000-0003-2240-8659

Junying Tang
the first affiliated hospital of chongqing medical university

Wenbo Li
the first affiliated hospital of chongqing medical university

Xuexun Xu
the first affiliated hospital of chongqing medical university

Hao Zhang
the first affiliated hospital of chongqing medical university

---

Case report

Keywords: Recurrent epithelial ovarian cancer, Secondary cytoreductive surgery, 125I seeds implantation

Posted Date: July 2nd, 2020

DOI: https://doi.org/10.21203/rs.3.rs-38148/v1

Version of Record: A version of this preprint was published at Journal of Ovarian Research on November 30th, 2020. See the published version at https://doi.org/10.1186/s13048-020-00744-2.

Abstract

Background: Epithelial ovarian cancer (EOC) has the worst prognosis in all of gynecologic malignant tumors because of its high recurrence and eventually chemo-resistance. Early diagnosis of recurrence is crucial to avoid diffuse dissemination. Traditional treatment failure in recurrent ovarian cancer remains a challenge for clinicians. On the other hand, ^{125}I brachytherapy has been accepted as a useful treatment for multiple advanced cancers in recent years. However, its success in advanced epithelial ovarian cancer is limited. Here we report a case of recurrent ovarian cancer who had been early diagnosis of isolated recurrence and successfully treated with ^{125}I seeds implantation during suboptimal cytoreductive surgery.

Case presentation: A 59-year-old woman presented with recurrent epithelial ovarian cancer who have had a medical history of ovarian cancer stage IIIB and an R0 resection had been achieved before presented in our hospital. She underwent suboptimal secondary cytoreductive surgery after four cycles of chemotherapy with little effectiveness and severe chemotherapy-related side effects. Approximately 70% of the cancer-bulk was resected during surgery. For residual lesion which fixed around the right ureter and right external iliac vessel, ^{125}I seeds implantation was performed. Postoperatively, the patient was treated with two cycles of combination chemotherapy with paclitaxel and carboplatin. The patient was free of disease at 26 months' follow-up period.

Conclusion: In recurrent EOC patients with unresectable isolated lesion, salvage ^{125}I seeds implantation are feasible and may contribute to survival.

Background

In all of the gynecologic malignant tumors, epithelial ovarian cancer (EOC) has the worst prognosis. The 5-year survival rate of 36% in stage III and 17% in stage IV[1] is depressing. The low survival rate of advanced EOC is mainly due to its high recurrence rate and eventually the emergence of diffuse dissemination and chemo-resistance.

The treatments for recurrent EOC include secondary cytoreductive surgery, chemotherapy, targeted therapy, immunotherapy, radiotherapy, and so on. Unfortunately, the effectiveness remains poor. As a result, additional and alternative therapeutic strategies to improve outcomes are urgently needed.

In the last decade, ^{125}I brachytherapy has been accepted as a useful and minimally invasive treatment for many advanced cancers with significant efficacy. However, success in ovarian cancer is little and limited at present.

Here we present a case of recurrent EOC successfully early diagnosed and treated with ^{125}I seeds implantation during suboptimal cytoreductive surgery. We felt the report of the patient would be of highly interest.

Case Presentation

A 59-year-old female patient with a medical history of ovarian cancer presented in our hospital (the first affiliated hospital of Chongqing Medical university, Gynecological Oncology Unit) in December 2017. The patient had been submitted to cytoreductive surgery nearly two years before. At that time, she complained of lower abdominal pain and bilateral pelvic mass with elevated serum CA125 level of 778.1 u□ml and HE4 level of 609 pmol□L. A primary cytoreductive surgery with removal of total hysterectomy with bilateral adnexectomy, omentectomy, pelvic and para-aortic lymph node dissection and other visible disease was performed. At that moment, an R0 resection was achieved. According to surgery and histopathological examination, the surgical-pathologic staging was medium to poorly differentiated epithelial serous ovarian adenocarcinoma IIIB (FIGO, 2014). Postoperatively, the patient was submitted to six cycles of adjuvant platinum- and taxane-based chemotherapy. The follow-up revealed no recurrent manifestation for nearly the next two years. The lowest value of CA-125 was 6.2u/ml during the period of chemotherapy and follow-up period.

Nearly two years later after primary surgery, the patient developed slight elevated serum CA125 with the value of 21.7 u/ml and HE4 73 pmol/L, both of which still in the normal range. However, the Positron Emission Tomography-Computed Tomography (PET-CT) (Fig. 1) showed a locoregional recurrence of about 3-4cm in diameter mass located at right pelvic cavity with mild hydronephrosis.

Firstly, the patient chose chemotherapy due to fear of surgery complication. Considering of platinum sensitive, she was submitted to four cycles of adjuvant platinum- and taxane-based chemotherapy. However, the effectiveness was not good according to the magnetic resonance imaging (MRI) (Fig. 2) and CA125 level. At the same time, the chemotherapy-related side effects were severe.

After a discussion of multidisciplinary treatment and informed consent of the patient, secondary surgery was performed in April 2018, by a combined approach with gynecology, gastrointestinal surgery, and nuclear medicine.

Intraoperatively, the presence of the isolated recurrence around the right ureter and right external iliac vessel was confirmed. Part of the tumor was densely adherent and invaded to small intestine. To avoid major bleeding, partial tumor resection with 10 cm part of ileum resection and side-to-side ileoileostomy was performed. Approximately 70% of the cancer-bulk was resected during surgery. For residual lesion which fixed around the right ureter and right external iliac vessel, ^{125}I seeds implantation was performed. 18 G implantation needles were inserted directly into the target lesions avoiding puncture of large blood vessels and nearby ureter, a turntable gun was then used to place ^{125}I seeds into recurrent tumors. Then seeds were released 0.5-1cm apart upon withdrawing the needles.

The postoperative course was uneventful and the patient was discharged in the seventh postoperative day.

Histopathological results confirmed the recurrence with malignant cells that invaded the small intestine with negative resection margins.

Postoperatively, the patient was submitted to two cycles of adjuvant platinum-based chemotherapy. At more than two years of follow-up, the patient is free of any local or distant recurrent disease. The range of CA-125 level during follow-up was below 10u/ml. Postoperative MRI and computed tomography (CT) were performed as Fig. 2

Discussion

Epithelial ovarian cancer (EOC) always remains the most lethal gynecologic malignancy, guideline-recommended treatments for advanced ovarian cancer is primary debulking surgery followed by platinum-based chemotherapy. However, relapse would almost occur. Conventional treatment for recurrent EOC is chemotherapy and/or cytoreduction. Despite nowadays some targeted agents available in ovarian cancer including PARP inhibitors, Anti-angiogenic agents, immunotherapies, the patients would eventually die of chemo-resistance.

The role of secondary cytoreductive surgery in recurrent ovarian cancer is yet controversial. For platinum-sensitive recurrent ovarian cancer, secondary cytoreductive surgery increases post-recurrence survival[2]. However, Coleman RL et al. randomly assigned patients with recurrent ovarian cancer with platinum-sensitive. They concluded secondary surgical cytoreduction followed by chemotherapy did not result in longer overall survival than chemotherapy alone[3]. The postoperative residual tumor mass is the most relevant clinical prognostic factor. Indication to Secondary cytoreductive surgery should be individualized. Complete cytoreduction improve the prognosis in the setting of recurrence[4]. Early diagnosis of recurrence maybe the key of the possibility and necessity of surgery.

One particularity of our case is early diagnosis of recurrence. Regular follow-up and early diagnosis of recurrence is of great importance for EOC after primary therapy. If the recurrence is isolated, there maybe has chance of secondary cytoreductive surgery and relatively good prognosis. Unfortunately, cases presenting isolated recurrences are uncommon since most cases are exhibiting disseminated lesions at the time of diagnosis. The rigorous surveillance of patients after initial treatment is a challenging question in clinical practice. We think the suspicion of recurrence should be considered once the serum CA125 levels elevated to more than 15 U/ml or two times of its lowest level. In this case report, PET-CT discovered metastatic loci in early-stage even if the serum tumor marker remains in normal range. Highly alertness of recurrence in the follow-up of Epithelial Ovarian Cancer patients is important. With the help of high quality of image, clinicians could properly monitor patients, distinguishing relapse patterns and preform correct management.[5]

Unfortunately, most of the recurrent lesions were near or adhered by surrounded important organs such as ureter, vagina, cyst, intestine or rectum. Sometimes tumors could not be removed because their removal would cause severe functional disability or life-threatening bleeding. Since reported by

Brunschwig in 1948[6], the pelvic exenteration (PE) has become an important method to treat pelvic malignancies. However, such management of cancer has remained controversial because of its severe functional disability or heavy hemorrhage especially when the tumor fixed to the pelvic sidewall. New treatment strategies for unremovable lesion in Secondary cytoreductive surgery for recurrent ovarian cancer are needed.

Another particularity and advantage of our case is partially tumor resection with salvage ^{125}I brachytherapy which did not interfere with the functional outcome of the patient and received good effects.

For EOC, radiotherapy is not a routinely therapy. In recent years, studies have reported favorable outcomes in patients with recurrent epithelial ovarian cancer (EOC) treated with SBRT or IFRT [7, 8]. Early in 1991,Iodine-125 interstitial implants as salvage therapy for recurrent gynecologic malignancies including one ovarian carcinoma has been reported[9]. As one kind of the radiotherapy, ^{125}I brachytherapy has several advantages when compared to the other kinds of radiotherapy. Its benefit is boosted by natural increases in local dose. ^{125}I seed local treatment can reduce the tumor burden, relieve local symptoms and improve quality of life of patients. Now ^{125}I brachytherapy has increasingly been used for other sites of disease, such as central nervous system, head and neck tumors, lung, hepatic and pancreatic cancer and so on. Efficacy and safety of iodine-125 radioactive seeds brachytherapy has been approved[10, 11].

In 1999, there has been American Brachytherapy Society (ABS) recommendations for the clinical quality assurance and guidelines of permanent prostate brachytherapy with 125I[12]. In 2018, Chinses expert consensus statement on computed tomography-guided ^{125}I radioactive seeds permanent interstitial brachytherapy has been developed[13].

In radiotherapy-naive patients with unresectable isolated recurrent gynecologic malignancies, ^{125}I implants are feasible and may possibly contribute to survival[14]. Unlikely as cervical carcinoma or endometrial carcinoma, radiotherapy is not usually been used in patients with ovarian epithelium cancer. As a result, ^{125}I brachytherapy is a hopeful therapy for recurrent EOC.

The success of ^{125}I brachytherapy is dependent on and the size of tumors and the accurate placement of radioactive seeds[15]. Usually, all the ^{125}I seeds implantation was performed with CT or ultrasound guidance. In our case, ^{125}I seed implanted directly under the vision of operation. On the one hand, tumor burden is reduced by surgery; on the other hand, ^{125}I implantation is more accurate and safer. Combination of surgery and ^{125}I seed implantation did not interfere with the functional outcome of the patient and received good effects.

Conclusion

We hope that this case report, demonstrating prolonged survival by early diagnosis of recurrence and ^{125}I implantation during suboptimal secondary cytoreductive surgery with little cost, will serve to strengthen alertness of recurrence in the follow-up of EOC patients and interest in the ^{125}I brachytherapy of unremovable recurrent EOC.

Declarations

Declarations

Ethics approval and consent to participate

This paper was approved by the Ethics Committee of the institutional review board (IRB) of Chongqing Medical University. and a signed informed consent has been obtained from the patient.

Consent for publication

Written informed consent was obtained from the patient for the publication of this case report and any accompanying images. A copy of the written consent is available for review by the Editor-in-Chief of this journal.

Availability of data and materials

The data used or analyzed are all included in this published article.

Competing interests

The authors declare that they have no competing interests.

Funding

We have no commercial or financial incentives associated with the publication of this article.

Authors' contributions

Junying Tang, Lin Xiao and Xuexun Xu performed surgery on the patient. Wenbo Li performed ^{125}I seed implantation. Lin Xiao drafted the manuscript. Junying Tang, Lin Xiao and Hao Zhang conceived of the study and participated in its design and coordination. All authors have read and approved the final manuscript.

Acknowledgements

Not applicable.

References

1. Baldwin LA, Huang B, Miller RW, Tucker T, Goodrich ST, Podzielinski I, DeSimone CP, Ueland FR, van Nagell JR, Seamon LG. Ten-year relative survival for epithelial ovarian cancer. Obstet Gynecol. 2012;120(3):612–8.
2. Marchetti C, Rosati A, Scaletta G, Pietragalla A, Arcieri M, Ergasti R, Palluzzi E, Scambia G, Fagotti A. Secondary cytoreductive surgery in platinum-sensitive recurrent ovarian cancer before olaparib maintenance: Still getting any benefit? A case-control study. Gynecol Oncol. 2019;155(3):400–5.
3. Coleman RL, Spirtos NM, Enserro D, Herzog TJ, Sabbatini P, Armstrong DK, Kim JW, Park SY, Kim BG, Nam JH, Fujiwara K, Walker JL, Casey AC, Alvarez Secord A, Rubin S, Chan JK, DiSilvestro P, Davidson SA, Cohn DE, Tewari KS, Basen-Engquist K, Huang HQ, Brady MF, Mannel RS. Secondary Surgical Cytoreduction for Recurrent Ovarian Cancer. N Engl J Med. 2019;381(20):1929–39.
4. Sehouli J, Grabowski JP. Surgery in recurrent ovarian cancer. Cancer. 2019;125(Suppl *24*):4598–601.
5. Manganaro L, Gigli S, Antonelli A, Saldari M, Tomao F, Marchetti C, Anastasi E, Laghi A. Imaging strategy in recurrent ovarian cancer: a practical review. Abdom Radiol (NY). 2019;44(3):1091–102.
6. Brunschwig A. Complete excision of pelvic viscera for advanced carcinoma; a one-stage abdominoperineal operation with end colostomy and bilateral ureteral implantation into the colon above the colostomy. Cancer. 1948;1(2):177–83.
7. Macchia G, Lazzari R, Colombo N, Laliscia C, Capelli G, D'Agostino GR, Deodato F, Maranzano E, Ippolito E, Ronchi S, Paiar F, Scorsetti M, Cilla S, Ingargiola R, Huscher A, Cerrotta AM, Fodor A, Vicenzi L, Russo D, Borghesi S, Perrucci E, Pignata S, Aristei C, Morganti AG, Scambia G, Valentini V, Jereczek-Fossa BA, Ferrandina G, Large A, Multicenter, Retrospective Study on Efficacy and Safety Of Stereotactic Body Radiotherapy (SBRT) in Oligometastatic Ovarian Cancer (MITO RT1 Study): A Collaboration of MITO, AIRO GYN, and Groups MaNGO. *Oncologist* 2019.
8. Chang JS, Kim SW, Kim YJ, Kim JY, Park SY, Kim JH, Jang TK, Kim YB. Involved-field radiation therapy for recurrent ovarian cancer: Results of a multi-institutional prospective phase II trial. Gynecol Oncol. 2018;151(1):39–45.
9. Sharma SK, Forgione H, Isaacs JH. Iodine-125 interstitial implants as salvage therapy for recurrent gynecologic malignancies. Cancer. 1991;67(10):2467–71.
10. Lu J, Huang W, Wang Z, Gong J, Ding X, Chen Z, Xia N, Yang N, Wu Z, Wang C, Chen J. The safety and efficacy of interstitial (125)I seed implantation brachytherapy for metastatic epidural spinal cord compression. J Cancer Res Ther. 2018;14(7):1549–55.
11. Zhang W, Li J, Li R, Zhang Y, Han M, Ma W. Efficacy and safety of iodine-125 radioactive seeds brachytherapy for advanced non-small cell lung cancer-A meta-analysis. Brachytherapy.

2018;17(2):439–48.
12. Nag S, Beyer D, Friedland J, Grimm P, Nath R. American Brachytherapy Society (ABS) recommendations for transperineal permanent brachytherapy of prostate cancer. Int J Radiat Oncol Biol Phys. 1999;44(4):789–99.
13. Wang J, Chai S, Zheng G, Jiang Y, Ji Z, Guo F, Zhuang H, Zhang K. Expert consensus statement on computed tomography-guided (125)I radioactive seeds permanent interstitial brachytherapy. J Cancer Res Ther. 2018;14(1):12–7.
14. Monk BJ, Tewari KS, Puthawala AA, Syed AM, Haugen JA, Burger RA. Treatment of recurrent gynecologic malignancies with iodine-125 permanent interstitial irradiation. Int J Radiat Oncol Biol Phys. 2002;52(3):806–15.
15. Goudreau SH, Joseph JP, Seiler SJ. Preoperative Radioactive Seed Localization for Nonpalpable Breast Lesions: Technique, Pitfalls, and Solutions. Radiographics. 2015;35(5):1319–34.

Figures

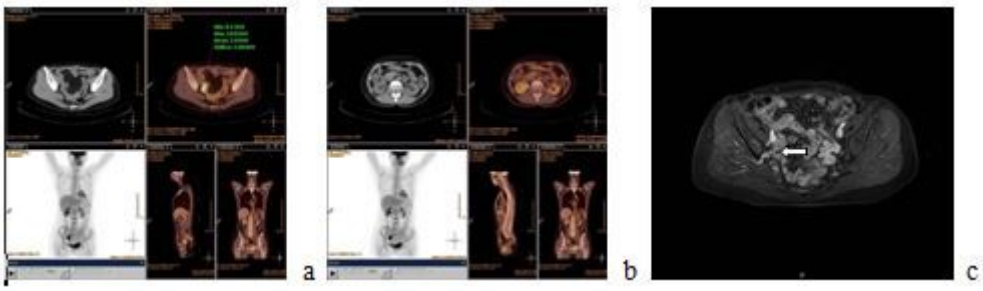

Figure 1

Recurrent lesion: a. PET-CT lesion recurred from ovarian cancer at right pelvic cavity b. Mild hydronephrosis c. MRI lesion recurred from ovarian cancer after four cycles of chemotherapy

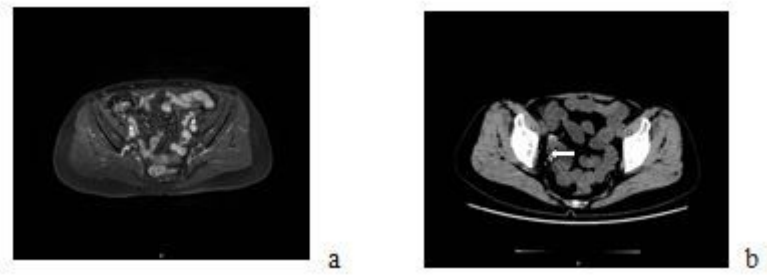

Figure 2

Postoperative image in June 2019: a. MRI showed no obvious local lesion. b. CT showed tumor disappeared, with only radioactive seeds remaining.