Gotfried reduction and cannulated screws fixation in the treatment of femoral neck fracture in young adults

Kai Huang (air33214@163.com)
Changzhou City Fourth People's Hospital https://orcid.org/0000-0002-6886-1830

Xiaohui Fang
Changzhou City Fourth People's Hospital

Guijun Li
Changzhou City Fourth People's Hospital Department of Orthopedic

Jiajun Yue
Changzhou City Fourth People's Hospital Department of Intensive Care Unit

Research article

Keywords: femoral neck fracture, internal fixation, Gotfried reduction, positive buttress, negative buttress

Posted Date: July 14th, 2020

DOI: https://doi.org/10.21203/rs.3.rs-38299/v1

Version of Record: A version of this preprint was published on November 7th, 2020. See the published version at https://doi.org/10.1186/s13018-020-02039-0.

Abstract

Background: Although many available surgical procedures for displaced femoral neck fractures in young patients, there are still many challenges to achieve satisfactory results. The incidence of avascular necrosis and nonunion rates remain relatively high despite the progress in our understanding and surgical technique. The purpose of this study was to evaluate the clinical efficacy of gotfried reduction and cannulated screw fixation in the treatment of femoral neck fracture for young adults.

Methods: A retrospective analysis was made on 67 cases from May 2013 to March 2019. They were divided into three groups according to the first postoperative anteroposterior view of hip X-ray: Anatomic reduction (group A), Gotfried positive buttress reduction (group B), and Gotfried negative buttress reduction (group C). The incidence of avascular osteonecrosis of the femoral head (AVN) and the Harris scores of hip joints were compared in three groups at the last follow-up.

Results: There were 21 cases (mean age,49.7 ± 11.6) in group A, 24 cases (mean age, 48.6 ± 11.3) in group B, 22 cases (mean age,48.3 ± 12.4) in group C. No significant difference in general preoperative demographics (P>0.05).The incidence of avascular necrosis of femoral head in Group A, B, and C was 19.05%,20.83%, and 22.73 %, respectively, showing no significant difference between groups(P=0.156). The mean Harris hip scores at the final follow-up for groups A (85.6±6.7)and B (84.5±6.2) were significantly higher than group C (74.3±8.3), and the difference was statistically significant(P=0.043).

Conclusions: Gotfried positive buttress reduction and fixation for femoral neck fracture may lead to similar clinical results with anatomic reduction, but much better than Gotfried negative buttress reduction. For the patients of femoral neck fracture with severe displacement and difficulty in reduction, it is not necessary to pursue anatomical reduction.Achieving positive valgus reduction can also obtain satisfactory clinical results, and should try to avoid negative buttress.

Introduction

Displaced femoral neck fractures are usually accompanied by higher complications, such as femoral head necrosis, fracture nonunion, femoral neck shortening, etc. These complications are the leading cause of re-operating [1–5].In elder patients, the preferred treatment for a displaced femoral neck fracture is hemiarthroplasty or total hip replacement (THR) in the majority of cases. However, younger patients with femoral neck fractures are a particular clinical research group. Different from elderly patients, premature hip replacement may increase the risk of revision rate [6–10]. Therefore, reduction of the fracture, rigid fixation until the fracture heals, and retention of the hip joint are the main goals of treatment.

The quality of reduction has been considered to be one of the most significant factors of successful treatment. Meanwhile, anatomic reduction can promote fracture healing and avoid complications. However, in 2013, Gotfried et al. Proposed the concept of "non-anatomical reduction of femoral neck d, the clinical results were satisfactory.

The primary purpose of this study was to analyze the data of 67 patients with femoral neck fractures using the Gotfried reduction method and intern fixation retrospectively and to evaluate the clinical efficacy report as follows.

Patients And Methods

Inclusion and exclusion criteria

Inclusion criteria: 1. All patients with age of ≤ 65 years, who were diagnosed with femoral neck fracture based on both imaging and Physical examination. 2. The procedure was gotfried closed reduction and internal fixation with cannulated cancellous screws. 3. Patients had no hip dysplasia neither arthritis before the injury. 4. All cases had at least one year of complete follow-up data

Exclusion criteria: 1. Pathological fractures, acetabular injuries, preexisting ipsilateral hip diseases, or femoral head fracture. 2. Multiple-trauma patients 3. Traumatic Brain Injury and Glasgow score < 14. 4. Patients with severe Cognitive Impairment and mental illness.

The Institutional Ethics Committee approved the present study of our hospital. All patients were included in the study after signing the informed consent.

The General Information

A total of 67 patients who finally met the inclusion criteria and had complete follow-up data were divided into three groups according to the first Imaging results after surgery. Group A was the anatomical reduction group, Group B was the Gotfried positive buttress reduction group, and group c was Gotfried negative buttress reduction group. There were 21 patients in group A, 12 males, and 9 females; the average age was 49.7 ± 11.6 years; the average follow-up time was 22.4 ± 10.7 months; Garden classification of fractures: 7 cases of type I, 5 cases of type II, 4 cases of type III, and 5 cases of type IV; 24 cases in group B, 14 cases of male and 10 cases of the female; the average age was 48.6 ± 11.3 years; the average follow-up time was 22.1 ± 11.2; Garden classification of fractures: 8 cases of type I, 6 cases of type □, 5 cases of type □, and 5 cases of type IV; 22 cases of group C, 13 cases of male, and 9 cases of the female; mean age was 48.3 ± 12.4 years; mean follow-up time was 22.8 ± 11.6; Garden classification of fracture: 4 cases of type I, 7 cases of type□,5 cases of type III, and 6 cases of type IV.

Surgical Procedures

All fractures underwent gotfried closed reduction and internal fixation with cannulated cancellous screws. The patient was placed on an orthopedic traction bed after anesthesia, and the perineum was protected against the traction site. The lower limb traction was performed on the operative side: lower limb

abduction and knee flexion, hip flexion on the contralateral side for convenient fluoroscopy during operation.

Gotfried closed reduction technology could be divided into three different steps as follows: 1. Gradually increased traction is applied in 2 directions: first, lateral: using a towel that was wrapped around the upper tight and second longitudinal: on the leg utilizing fracture table. 2. Reduction—while under traction in both directions, the lower limb is brought into adduction and internal rotation. Usually, about 45 degrees adduction is required. The third stage, not presented in the drawing: reconstruction—while in adduction and internal rotation, the release of longitudinal and lateral traction.

Percutaneous cannulated screw fixation: Insert a threaded guide needle in front of the femoral neck to determine the anteversion angle under fluoroscopy. Insert the guide needle at the position of the trochanter slightly above the centerline of the femur. The direction is parallel to the first positioning needle, guide-pin is drilled into place along the medial cortex of the femoral neck and head to within 5 mm of subchondral bone; Measure the length of each cannulated screw and screw in the corresponding length of the cannulated screw. The C-arm confirms the quality of fracture reduction and the screws' position to prevent the screw from penetrating the hip joint.

Postoperative Management

Intravenous prophylactic antibiotics (Cefazolin 2.0 g) were routinely administered 30 minutes preoperatively. All patients were kept in absolute bed rest for 3 days and mobilized with crutches without weight-bearing on the seventh postoperative day on the affected side. The patients received partial weight-bearing exercises with crutches after 8 weeks, and usual weight-bearing activities after 12 weeks. These patients had a positive compression ultrasound for deep-vein thrombosis and received anticoagulant therapy on the next day after the operation.

Evaluation criterion and observation index

1. Follow-up data: The follow-up duration was measured from the time of operation to the last follow-up date, and the avascular necrosis of the femoral head, malignant or nonunion of the fracture, was recorded at the last follow-up. Harris hip scoring (HHS) system was used to measure the hip function. The quality of fracture reduction is divided into anatomical reduction and non-anatomical reduction. The non-anatomical reduction is divided into Goffried positive support reduction and negative support reduction.

Statistical analysis

SPSS software was used to take the statistical analysis, Normal distribution of data tested using the Shapiro–Wilk W-test. The patient's age, follow-up time, and Harris score were normally distributed data,

exhibited homogeneity of variance. Analyses were carried out using one-way ANOVA in 3 groups. If the difference was statistically significant, then the SNK-q test was used to compare the two groups. $P < 0.05$ considered that the difference was statistically significant significance.

Clinical Outcome

The average follow-up periods in the three groups were (22.4 ± 10.7)□(22.1 ± 11.2)□□22.8 ± 11.6□months, which showed no statistical difference($F = 0.053$, $P = 0.964$). There was no wound infection, fracture nonunion, and implant failure in either group. No significant differences were noted preoperatively between the three groups regarding age, time of operation, gender, and average time of follow-up (($P > 0.05$). There was no statistically significant difference in the femoral head necrosis rate among the three groups ($P = 0.156$). At the last follow-up, the Harris scores in group A and group B were significantly higher than group c, and the difference was statistically significant ($P < 0.05$, Table 2).

Table 1
Basic characteristics of patients

Group Case		Mean age $\varvec{x} \pm \varvec{s}$	Gender male	female	Classification (Garden) □	□	□	□	follow-up time (month) $\varvec{x} \pm \varvec{s}$
A	21	49.7 ± 11.6	12	9	7	5	4	5	22.4 ± 10.7
B	24	48.6 ± 11.3	14	10	8	6	5	5	22.1 ± 11.2
C	22	48.3 ± 12.4	13	9	4	7	5	6	22.8 ± 11.6
Group A : Anatomical reduction group,									
group B : Gofffied positive buttress reduction group,									
Group C: Gotfried negative buttress reduction group									

Table 2
The incidence of femoral head necrosis and Harris score at last follow-up

Group	Case	AVN(case,%)	Harris score
A	21	4(4/21, 19.05%)	85.6 ± 6.7
B	24	5(5/24,20.83%)	84.5 ± 6.2
C	22	5(5/22,22.73%)	74.3 ± 8.3
Group A : Anatomical reduction group,			
group B : Gofffied positive buttress reduction group,			
Group C: Gotfried negative buttress reduction group			
AVN: avascular necrosis			

Discussion

The treatment of femoral neck fracture in young patients faces many challenges, and if clinicians fail to provide improper treatment, it may lead to catastrophic consequences for patients[2–5, 12–14]. The proportion of patients with femoral neck fractures under 65 years who underwent total hip arthroplasty increased from 1.4–13.1% from 1999 to 2011[14]. However, due to the longevity of the hip joint and the high activity requirements, arthroplasty surgery is not the best option[3, 4, 10]. For younger patients (under 65 years), anatomical reduction, rigid fixation, and preservation of their hip joints are the primary treatment goals, especially to those who have an abundance of daily activities[6, 7, 10, 15]. In a survey of 540 orthopedic surgeons, 78% of surgeons prefer to use multiple cannulated screws for the treatment of nondisplaced femoral neck fracture. For displaced fractures, multiple screws (46%) and sliding hip screws (SHS, 49%) were first taken into consideration for the majority of orthopedic surgeons[12]. Most of the studies were reported higher rates of avascular necrosis, premature epiphyseal fusion, and heterotopic ossifications after open reduction[8]. The closed reduction has the advantages of less trauma, less intraoperative bleeding, and shorter operation time theoretically reduced the risk of postoperative surgical complications[16].

Consequently, closed reduction and internal fixation of fracture is the preferred method of treatment. The repeated reduction should be avoided as much as possible to preserve the blood supply and reduce surgical trauma. Once the closed reduction fails, we should consider adopting open reduction and internal fixation.

The inadequate reduction is the leading cause of complications such as femoral head necrosis, fracture nonunion, femoral neck shortening, etc. There is a large body of literature repeatedly emphasized the importance of reduction. It has been regarded as a key to effective treatment [6, 12, 17]. To achieve

anatomical reduction, many scholars have made many attempts and explored some techniques, such as Whitman, Leadbetter, Deyerler reduction method.

Although achieving anatomical reduction is the goal of treating femoral neck fractures, it does not guarantee a good prognosis. To achieve anatomical reduction, it probably requires repeated manipulations but instead appears to increase the odds of femoral head necrosis and fracture nonunion[9]. Therefore, Gotfried et al. believe that anatomical reduction is not strictly necessary[11]. The anatomical reduction may not promote fracture healing and reduce the occurrence of femoral head avascular necrosis[18]. In a group of young patients, there is a good reduction in postoperative radiography. However, Nonunion occurred in 8%, 11.5% of avascular necrosis of the femoral head[1]. Gotfried et al. proposed the concept of "non-anatomical reduction of femoral neck fractures" and expounded the following concepts in his literature:1. Positive Buttress Position a displaced subcapital femoral position, anteroposterior(AP) view, in which the distal femoral neck fragment is positioned medially to the lower-medial edge of the proximal fracture fragment; Negative Buttress Position a displaced subcapital femoral position, (AP) view, in which the proximal fracture fragment (femoral neck and head) is displaced medially to the upper medial edge of the distal femoral neck fragment. Negative Buttress Position is highly correlated with failure of reduction.

The direction of forces reflects on the development of the trabecular lines of the femoral neck, which increased bone mineral density to specific areas of the hip. Ward's area, or Ward's triangle as initially called, is the space localized at the femoral neck formed by the intersection of three trabecular bundles, namely the principal compressive, the secondary compressive, and the tensile trabeculae. Adam's arch plays an essential role in sustaining the stability of the femoral neck. The main strength of the neck resides in an arch of compact tissue, which begins small where the globular head joins the under part of the neck, but which gradually enlarges downwards towards the lesser for the stability of the proximal femur[19].

In the present study, Gotfrired reduction and all cases cannulated screw fixation were taken in all cases. The Harris score in patients with positive support was significantly better than those in the negative support group, close to that of the anatomical reduction group. There was no significant difference in the short-term efficacy between the Gotfried positive support group and the anatomical reduction group.

Conclusion

Therefore, for patients who have achieved positive support and valgus reduction, they may not need to pursue an anatomical reduction. Excessive pursuit of anatomical reduction will damage the blood supply and may cause femoral head necrosis. We recommend that if you do not use open reduction, you need to pay attention to 1. To get an anatomical reduction as much as possible; 2. if anatomical reduction cannot be obtained, to get a positive reduction as much as possible 3. Avoid negative support.

Abbreviations

AVN: Avascular osteonecrosis of the femoral head

HHS: Harris hip scoring

THR: Total hip replacement

AP: Anteroposterior

Declarations

Availability of data and materials

The datasets used and/or analyzed during the current study are available from the corresponding author on reasonable request.

Ethics declarations

Ethics approval consent to participate

This study was approved by the medical ethics committee of our institution. All of the enrolled patients had written informed consent before participating in this study.

Consent for publication

All of the collected patients had written informed consent before participating in this study, and the consent of publication was obtained from patients.

Competing for publication

The authors declare that they have no competing interests

Acknowledgements

Not applicable

Funding

Not applicable

References

1. Duckworth AD, Bennet SJ, Aderinto J, Keating JF. Fixation of intracapsular fractures of the femoral neck in young patients: risk factors for failure. J Bone Joint Surg Br. 2011;93:811–6. DOI 10.1302/0301-620X.93B6.26432.

2. Zlowodzki M, Ayieni O, Petrisor BA, Bhandari M. Femoral Neck Shortening After Fracture Fixation With Multiple Cancellous Screws: Incidence and Effect on Function. The Journal of Trauma: Injury Infection Critical Care. 2008;64:163–9. DOI 10.1097/01.ta.0000241143.71274.63.
3. Damany DS, Parker MJ, Chojnowski A. Complications after intracapsular hip fractures in young adults. A meta-analysis of 18 published studies involving 564 fractures. Injury. 2005;36:131–41. DOI 10.1016/j.injury.2004.05.023.
4. Haidukewych GJ, Rothwell WS, Jacofsky DJ, Torchia ME, Berry DJ. Operative treatment of femoral neck fractures in patients between the ages of fifteen and fifty years. J Bone Joint Surg Am. 2004;86-A:1711–6.
5. Lee CH, Huang GS, Chao KH, Jean JL, Wu SS. Surgical treatment of displaced stress fractures of the femoral neck in military recruits: a report of 42 cases. Arch Orthop Trauma Surg. 2003;123:527–33. DOI 10.1007/s00402-003-0579-8.
6. Kang JS, Moon KH, Shin JS, Shin EH, Ahn CH, Choi GH. Clinical Results of Internal Fixation of Subcapital Femoral Neck Fractures. Clin Orthop Surg. 2016;8:146–52. DOI 10.4055/cios.2016.8.2.146.
7. Slobogean GP, Sprague SA, Scott T, McKee M, Bhandari M. Management of young femoral neck fractures: is there a consensus? Injury. 2015;46:435–40. DOI 10.1016/j.injury.2014.11.028.
8. Ly BTV. (2015) Treatment of Femoral Neck Fractures.
9. Ghayoumi P, Kandemir U, Morshed S. Evidence based update: open versus closed reduction. Injury. 2015;46:467–73. DOI 10.1016/j.injury.2014.10.011.
10. Florschutz AV. Femoral neck fractures current management. J Orthop Trauma. 2015;29:121–9. DOI 10.1097/BOT.0000000000000291.
11. Gotfried Y. (2013) Nonanatomical Reduction of Displaced Subcapital Femoral Fractures (Gotfried Reduction). J Orthop Trauma.
12. Slobogean GP, Stockton DJ, Zeng B, Wang D, Ma BT, Pollak AN. Femoral Neck Fractures in Adults Treated With Internal Fixation: A Prospective Multicenter Chinese Cohort. J Am Acad Orthop Surg. 2017;25:297–303. DOI 10.5435/JAAOS-D-15-00661.
13. Mahajan RH, Kumar S, Mishra B. Technique for gentle accurate reproducible closed reduction of intracapsular fracture of neck of femur. Injury. 2017;48:789–90. DOI 10.1016/j.injury.2016.10.030.
14. Miller BJ, Callaghan JJ, Cram P, Karam M, Marsh JL, Noiseux NO. Changing trends in the treatment of femoral neck fractures: a review of the american board of orthopaedic surgery database. J Bone Joint Surg Am. 2014;96:e149. DOI 10.2106/JBJS.M.01122.
15. Li M, Cole PA. Anatomical considerations in adult femoral neck fractures: how anatomy influences the treatment issues? Injury. 2015;46:453–8. DOI 10.1016/j.injury.2014.11.017.
16. Su Y, Chen W, Zhang Q, Li B, Li Z, Guo M, Pan J, Zhang Y. An irreducible variant of femoral neck fracture: a minimally traumatic reduction technique. Injury. 2011;42:140–5. DOI 10.1016/j.injury.2010.05.008.

17. Stacey SC, Renninger CH, Hak D, Mauffrey C. Tips and tricks for ORIF of displaced femoral neck fractures in the young adult patient. Eur J Orthop Surg Traumatol. 2016;26:355–63. DOI 10.1007/s00590-016-1745-3.
18. Campenfeldt P, Hedström M, Ekström W, Al-Ani AN. Good functional outcome but not regained health related quality of life in the majority of 20–69 years old patients with femoral neck fracture treated with internal fixation. Injury. 2017;48:2744–53. DOI 10.1016/j.injury.2017.10.028.
19. Panteli M, Rodham P, Giannoudis PV. Biomechanical rationale for implant choices in femoral neck fracture fixation in the non-elderly. Injury. 2015;46:445–52. DOI 10.1016/j.injury.2014.12.031.

Figures

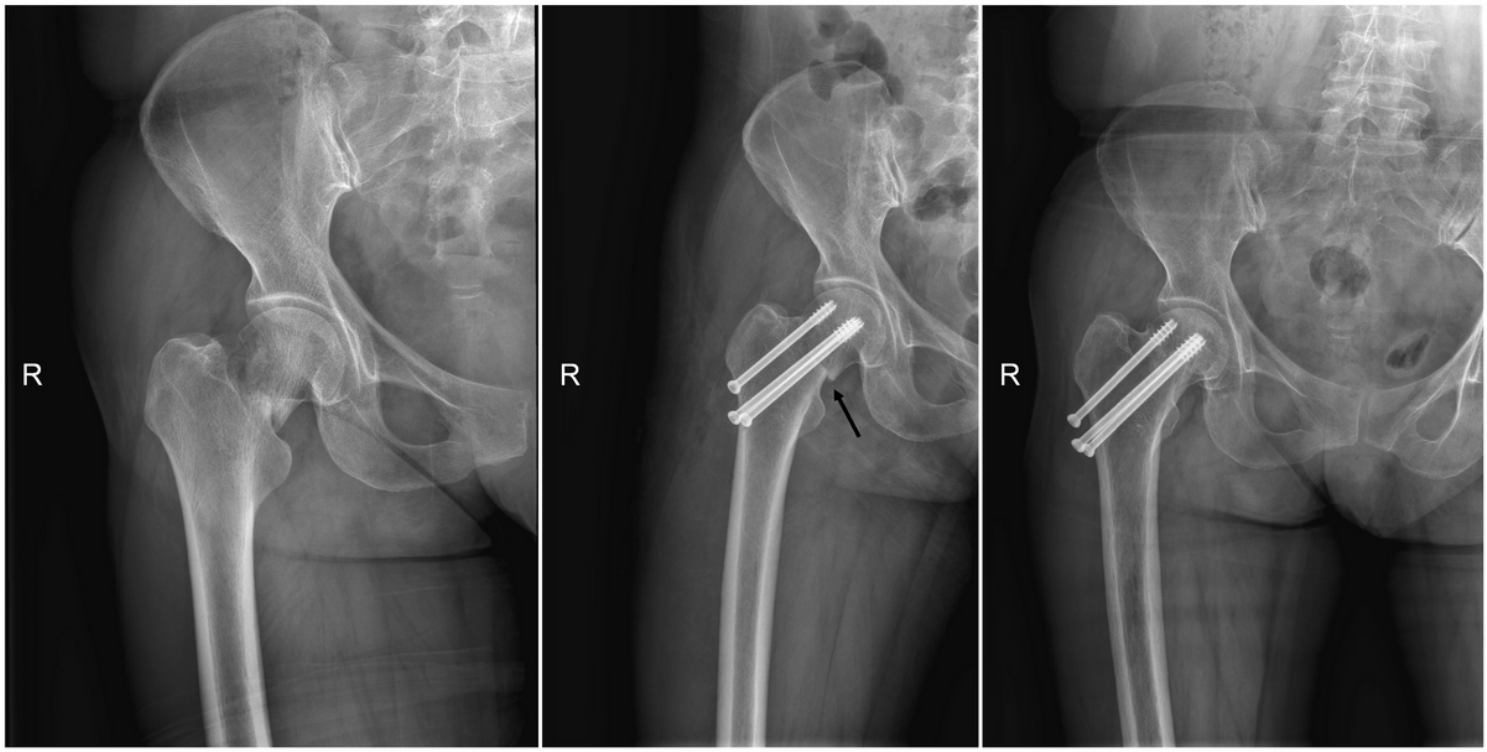

Figure 1

a Preoperative radiography b postoperative radiography and the arrow indicate negative buttress c After a two-year follow-up the radiography shows femoral neck shortening and varus deformity.

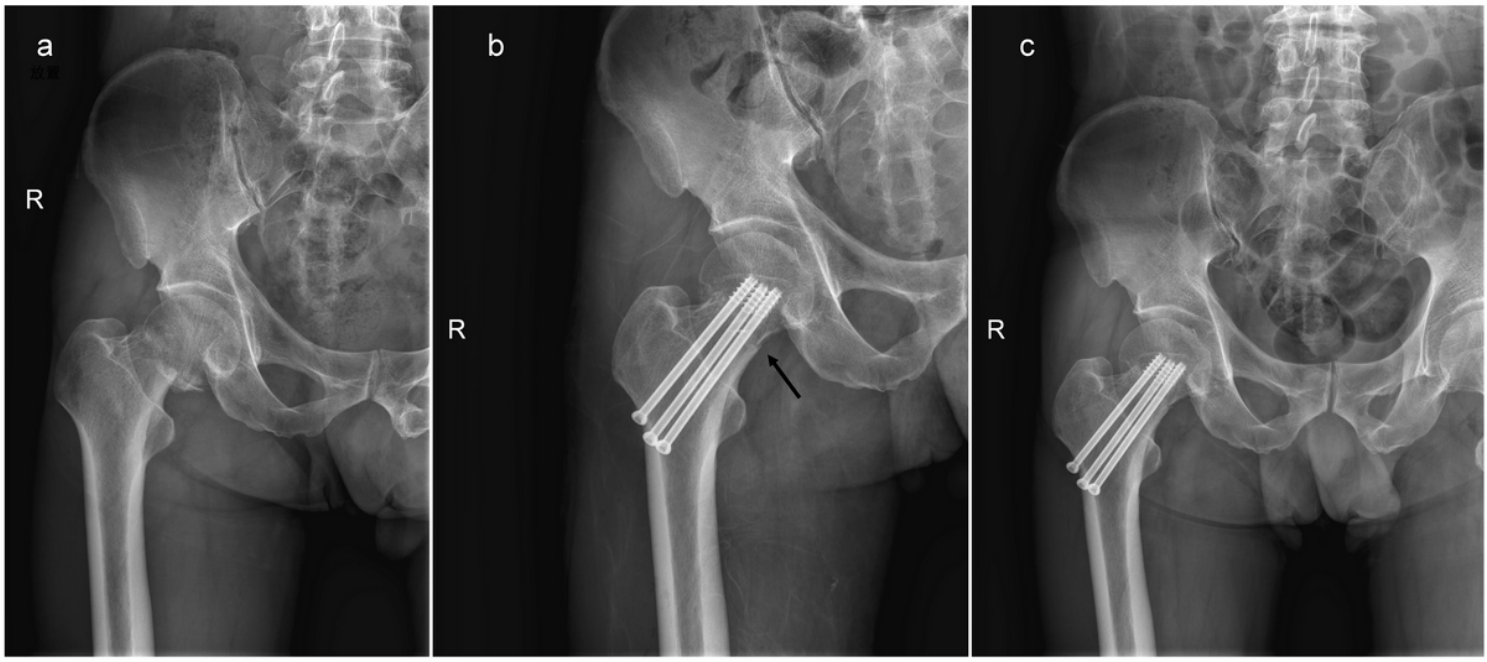

Figure 2

a Preoperative radiography b postoperative radiography and the arrow indicate positive buttress c After a two-year follow-up the radiography shows good fracture union without malunion.