The simple surgery to safely extend the anhepatic time to 30 minutes for rat liver transplantation

Gaofeng Tang
Henan Provincial People's Hospital
Jiabin Zhang
Capital Medical University Affiliated Beijing Friendship Hospital
Huibo Zhao
Henan Provincial People's Hospital
Sidong Wei
Henan Provincial People's Hospital
shaotang Zhou (zhoust71@163.com)
Henan Provincial People's Hospital https://orcid.org/0000-0002-1391-3517
Guoyong Chen
Henan Provincial People's Hospital

Methodology article

Keywords: orthotopic rat liver transplantation, anhepatic time, diaphragmatic ring

Posted Date: July 9th, 2020

DOI: https://doi.org/10.21203/rs.3.rs-38945/v1

Abstract

Background

Orthotopic rat liver transplantation (OLT) is widely used, it remains complicated although many renovations have been made.

Methods

OLT was performed for tolerance induction, including whole graft OLTs from close male Sprague Dawley (SD) rat to male SD (whole graft group, n = 21) and 30 minute anhepatic time group (AHT group, n = 11), OLT was performed from 50% male Lewis allograft to male Brown Norway (BN) rats to induce tolerance (half graft group, n = 28), Cyclosporine A was injected once daily for 14 days.

Results

For whole graft group, 30-day survival rate was 85.5% (18/21), the reasons of death were gas embolism due to the missed suturing in 2 cases, blood loss in 1 case. For AHT group, 30-day survival rate 72.7% (8/11), the causes of death were respiratory failure in 1 case, unknown in 2 cases. For tolerance group, 30-day survival rate was 64.3% (18/28), the reasons of death were diarrhea in 4 cases, wound dehiscence in 6 cases. There were no differences in survival in 3 groups ($p = 0.289$).

Conclusion

The anhepatic time can be extended simply through the change of clamping the diaphragm, which facilitates its application in the research.

Introduction

Rat OLT is well-accepted model on immunology, ischemia-reperfusion injury and regeneration since Lee and his colleagues developed [1,2], nowadays it is complicated requiring microsurgical techniques, especially for new microsurgeons although many valuable modifications have come into use [3–5]. It is documented that the short anhepatic time plays a critical role of the success of LT and improves survival greatly, and that cardiac arrest in the recipient frequently occurred when AHT was more than 26 minutes[6,7]. Higher mortality rate during AHT necessitates researchers to extend AHT. Here we first introduced the simplest method to extend AHT to 30 minutes while facilitating this complicated procedure.

Methods And Materials

For our project, OLT was performed to study liver regeneration and immunological tolerance through stem cells (detail out of scope).Following the procedure of literature, we observed that clamping the diaphragm would lead to abnormal breathing and rat death (supplemental video 1), and that the change of clamping the diaphragm would benefit this microsurgery and rat survival, it is generalized in this procedure. Whole OLT were performed from close male SD to male SD with different AHT, partial OLT performed with male Lewis to male BN as the acute rejection model (Table 1).

Table 1
data for recipients of 3 groups. other*for unknown reasons. AHT, 30- minute anhepatic time

	Anhepatic time	30-day survival rate	Death reasons
whole graft (n = 21)	≤ 20 min	85.5% (18/21)	missed suture(2),bleed(1)
AHT group (n = 11)	30 min	72.7% (8/11)	respiratory failure(1),other*(2)
half graft (n = 28)	≤ 20 min	64.3%(18/28)	diarrhea(4),wound(6)

Animal

Rats including close SD, Lewis (weighing 200–400 g) and BN were used as donors and recipients purchased from Beijing Vital River Laboratory Animal Technology Corporation. The animals were maintained in a temperature and light-controlled environment, freely access to a standard chow diet and water, they were fasted 12 h before the operation. All experiments were conducted in compliance with the standards for animal use and care set by the Institutional Animal Care Committee of Henan Provincial People’s Hospital.

Surgical Procedure

Under isoflurane inhalation anesthesia with a few modifications, a transverse incision was made to enter the abdominal cavity of rats. In the donor procedure, the liver was flushed through the aorta with lactated Ringer's solution, and then reflushed through the portal vein (PV). The graft was immersed in lactated Ringer's solution. Cuffs were prepared for PV and infra-hepatic vena cava (IVC). For 50% graft, the caudate lobes, the left lateral one and the left portion of the median lobe were removed at the back table. Cold storage time was less than 3 hours in all cases. In the recipient part, after the abdominal cavity was opened like the donor, all ligaments of the liver were cut. The proper liver artery was ligated proximally, and the accessory liver artery was ligated and cut, a blunt separation behind the liver was made to create a tunnel. The left sub-diaphragmatic vein was ligated closed to the diaphragm. The recipient PV and IVC were cross-clamped with microvascular clamps, and isoflurane was immediately decreased to 0.3 volume %. A mosquito forceps was placed through the tunnel on the part of diaphragm ring (left side) to occlude SHVC and stabilized (Fig. 1), SHVC was anastomosed with 8 – 0 polypropylene running suture (Fig. 2), when this anastomosis was completed, the forceps was replaced with a vascular bulldog on the real

SHVC while the diaphragm ring was declamped (Fig. 3), the anhepatic time was generally less than 20 minutes. PV was reconnected with the cuff, followed by blood flow restoration once the clamp on the PV was released. The IVC reconnection was made as was for PV. For 30 minute AHT group, the clamp on the PV was waited and released until 30 minutes. Proximal ligation of the gastroduodenal artery was made with a suture and an opening was made on the anterior wall of the common hepatic artery into which the stent in the donor hepatic artery was inserted and secured with 8 – 0 silk suture and fixed from both ends (Fig. 4, supplemental video 2), bile duct continuity was made when a tube in the donor bile duct was inserted into the recipient bile duct. The abdomen was closed with two layers and the animals were kept in a cage under an infrared light. Tape water and 10% glucose solution were both supplied for first 24 hours, and later regular food and tape water were offered. Antibiotic was injected subcutaneously once a day, 4 days in total. For half graft group, cyclosporine A was subcutaneously injected once daily for 14 days and ceased afterwards.

Results

For the whole graft, 30-day survival rate was 85.5% (18/21), the reasons of death were gas embolism due to missed suturing during the anastomosis in 2 cases, blood loss in 1 case. For AHT group, 30-day survival rate 72.7% (8/11), the causes of death were respiratory failure in one case, unknown reasons were in 2 cases. For half graft group, 30-day survival rate was 64.3% (18/28) (Fig. 5), the reasons of death were diarrhea in 4 cases, BN rats ate themselves in 6 cases. There were no differences for survival for 3 groups($p = 0.289$).Histological examination revealed almost normal structures of liver without fibrosis, ductopenia, thickened wall in the liver arterioles and venules in half graft group (H&E staining not shown).

Discussion

Since Kamada introduced the cuff method for OLT, it has greatly benefited OLT in basic and clinical medicine[1,2,6]. AHT as a surgical skill has been prioritized to minimize as soon as possibly by clinicians and microsurgeons who perform liver transplantation. Clinically it ranged from 37 to 321 minutes, it was reported that over 100-minute AHT was associated with a higher incidence of graft dysfunction [6,8]. Experimentally, the AHT ceiling of rat OLT is 26 minutes in the literature [1,6]. For our report, it is safely prolonged to 30 minutes, or even 35 minutes whereas survival rates were not significantly different, in the time-efficient manner, the different anhepatic time has little impact on recipients and survival.

Continuous suture and cuff method comprise the reconnection of SHVC [1.2.9–14], suturing should be completed rapidly while SHVC is blocked and it necessitates clamping the diaphragmatic ring a little more without ventilator assisting. The diaphragm is to maintain respiratory movement, once clamped, that dramatically affects respiratory and causes rats to move due to compromised respiration (supplemental video 1), some surgeons might add anesthesia, consequently the rats will die, especially under plain and simple mask anesthesia inhalation (ether etc), this is the reason that cardiac arrest occurred and higher mortality came forth during AHT [7]. Cuff method efficiently shortens SHVC

anastomosis, but it is not universally applicable due to short SHVC in length. Magnetic ring is a cuff method in nature and precludes future MRI examination [13,14].

Pharmaceutics extension AHT came forth in some centers, prostaglandin and its analogue were used to extend AHT and improve survival [15,16]. Liu et al reported that clamping the supra-celiac aorta one minute can effectively improve rat OLT by increasing the tolerable time of AHT [6], this maneuver does not surpass the AHT ceiling. Our maneuver is surgically easy and effectively extends AHT to 30 minutes. A few references were reviewed to reveal that the diaphragm was clamped much more [17,18], we followed that procedure which led to irregular breathing (supplemental video 1). In the literature almost no attention has been paid to how to clamp SHVC or the diaphragm on the reconnection of SHVC, our report is the first description of clamping the diaphragm. As to tolerance induction in our report, it is ongoing research of our project and beyond the scope here.

In summary, OLT can be safely performed with 30 minute AHT extended through the change of clamping the diaphragm; this procedure facilitates its application in the research.

Abbreviations

orthotopic liver transplantation, OLT; anhepatic time, AHT; Sprague Dawley, SD; Brown Norway, BN; portal vein, PV; supra-hepatic vena cava, SHVC; infra-hepatic vena cava, IVC

Declarations

Ethics approval and consent to participate

All experiments were conducted in compliance with the standards for animal use and care set by the Institutional Animal Care Committee of Henan Provincial People's Hospital.

Consent for publication

N/A

Availability of data and materials

All data and materials are available on request

Competing interests

The authors have no conflicts of interest to declare

Funding

Sponsored by Project 23456 of Henan Provincial People's Hospital

Authors' contributions

GF.Tang wrote the draft. JB.Zhang discussed and revised the draft. HB.Zhao collected data and caring.SD. Wei performed the statistical analysis. ST Zhou performed OLT, conceived, designed and finalized the study. GY. Chen funded the study.

Acknowledgements

N/A

References

1. Lee. S, Charters. A C, Chandler. J G, Orloff. M J. A technique for orthotopic liver transplantation in the rat. Transplantation 1973;16:664-669.
2. Kamada, N, & Calne, R. Y. Orthotopic liver transplantation in the rat. Technique using cuff for portal vein anastomosis and biliary drainage. Transplantation 1979; 28(1): 47-50.
3. Kamada N, Calne RY: A surgical experience with five hundred thirty liver transplants in the rat. Surgery 1983;93: 64-69.
4. Miyata, M, Fischer, J. H, Fuhs, M, Isselhard, W, & Kasai, Y. A simple method for orthotopic liver transplantation in the rat. Cuff technique for three vascular anastomoses. Transplantation 1980;30(5):335-338.
5. Kashfi, A, Mehrabi, A, Pahlavan, P, et al. A review of various techniques of orthotopic liver transplantation in the rat. Transplantation Proceedings 2005; 37(1): 185-188.
6. Liu C, Tsai HL, Chin T, Loong CC, Hsia CY, Wei C. Clamping the supra-celiac aorta can effectively increase the success rate of orthotopic rat liver transplantation by increasing the tolerable time of the anhepatic phase. J Surg Res 2006 ;136(1):116-119.
7. Cao D, Liu Y, Li J, et al. Isoflurane: An Ideal Anesthetic for Rodent Orthotopic Liver Transplantation Surgery? Transplant Proc 2016; 48(8):2815-20.
8. Alexander J. C. IJtsma, Christian S. van der Hilst, Marieke T. de Boer, et al. The Clinical Relevance of the Anhepatic Phase During Liver Transplantation. Liver transplantation 2009 ;15:1050-1055.
9. Oldani. G, Maestri. M, Gaspari. A, et al. A novel technique for rat liver transplantation using quick linker system: A preliminary result. Journal of Surgical Research 2008;149(2):303-309.
10. Ariyakhagorn. V, Schmitz. V, Olschewski. P, et al. Improvement of microsurgical techniques in orthotopic rat liver transplantation. Journal of Surgical Research 2009; 153(2):332-339.
11. Aller MA, Arias N, Prieto I, et al. A half century (1961-2011) of applying microsurgery to experimental liver research. World journal of hepatology 2012; 4: 199-208.
12. Tan F, Chen Z, Zhao Y, Liang T, Li J, Wei J. Novel technique for suprahepatic vena cava reconstruction in rat orthotopic liver transplantation. Microsurgery. 2005;25(7):556-560.

13. Jamshidi. R, Stephenson. J T, Clay. J G, Pichakron. K O, Harrison. M. R. Magnamosis: magnetic compression anastomosis with comparison to suture and staple techniques. Journal of pediatric surgery 2009;44: 222-228.
14. Shi Y, Zhang W, Deng YL, *et al.* Magnetic ring anastomosis of suprahepatic vena cava: novel technique for liver transplantation in rat. Transplant int 2015; 28: 89-94.
15. Xu HS, Rosenlof LK, Pruett TL, Jones RS. Prostaglandin E1 increases survival with extended anhepatic phase during liver transplantation. Ann Surg. 1994;220(1):53-58.
16. Goto S, Shimizu Y, Lord R, et al. The beneficial effect of the prostacyclin analogue (OP 2507) on rat liver transplantation subjected to an extended anhepatic phase. Transpl Int. 1996;9(6):607-610.
17. Hongdong Wang, Chonghui Li , Hongbin Xu,et al. Precise reconstruction of veins and bile ducts in rat liver transplantation.Cell Biochem Biophys 2014 ;68(1):55-65.
18. Nagai K, Yagi S, Uemoto S, Tolba RH. Surgical procedures for a rat model of partial orthotopic liver transplantation with hepatic arterial reconstruction. J Vis Exp. 2013;(73):e4376. doi: 10.3791/4376.

Figures

Figure 1

The mosquito forceps and the bulldog for occlusion of SHVC.

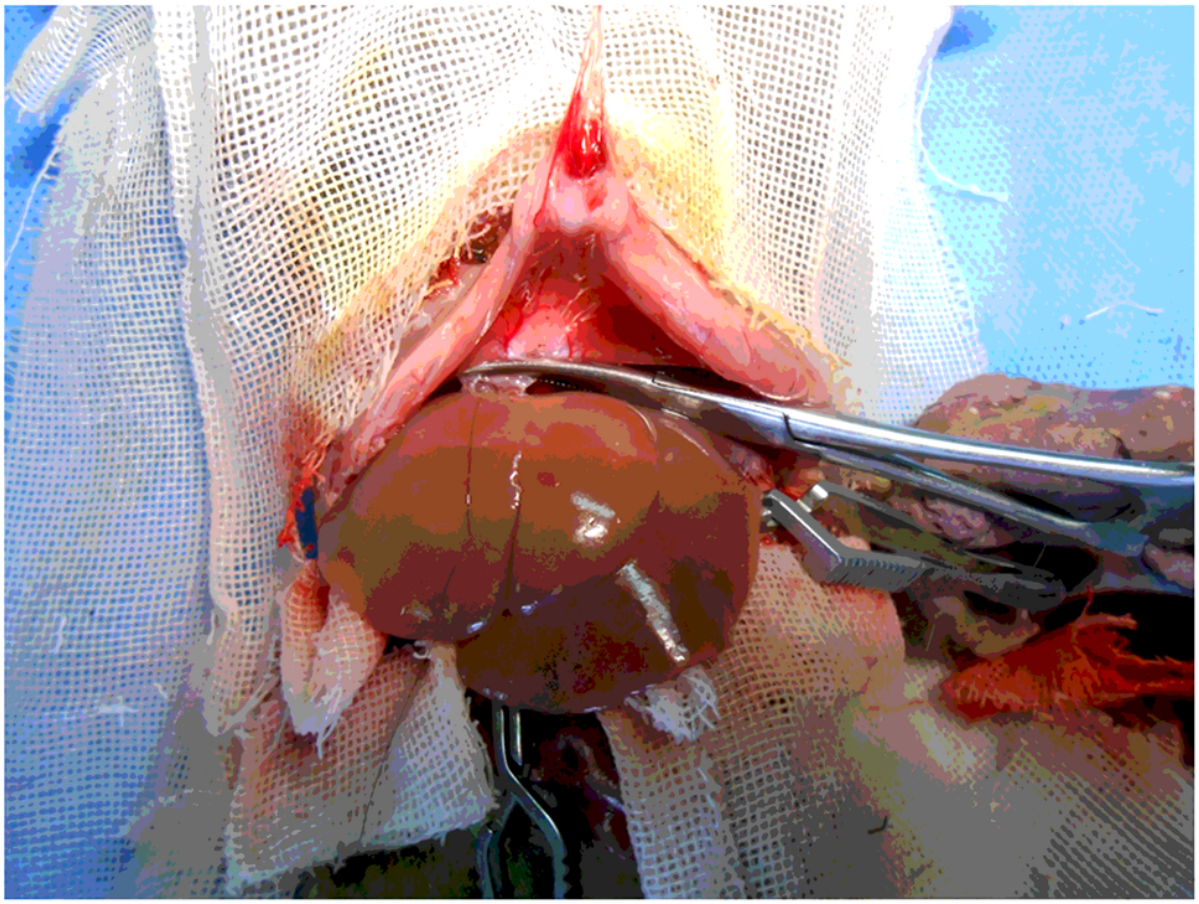

Figure 2

Clamping the diaphragmatic ring with the mosquito forceps.

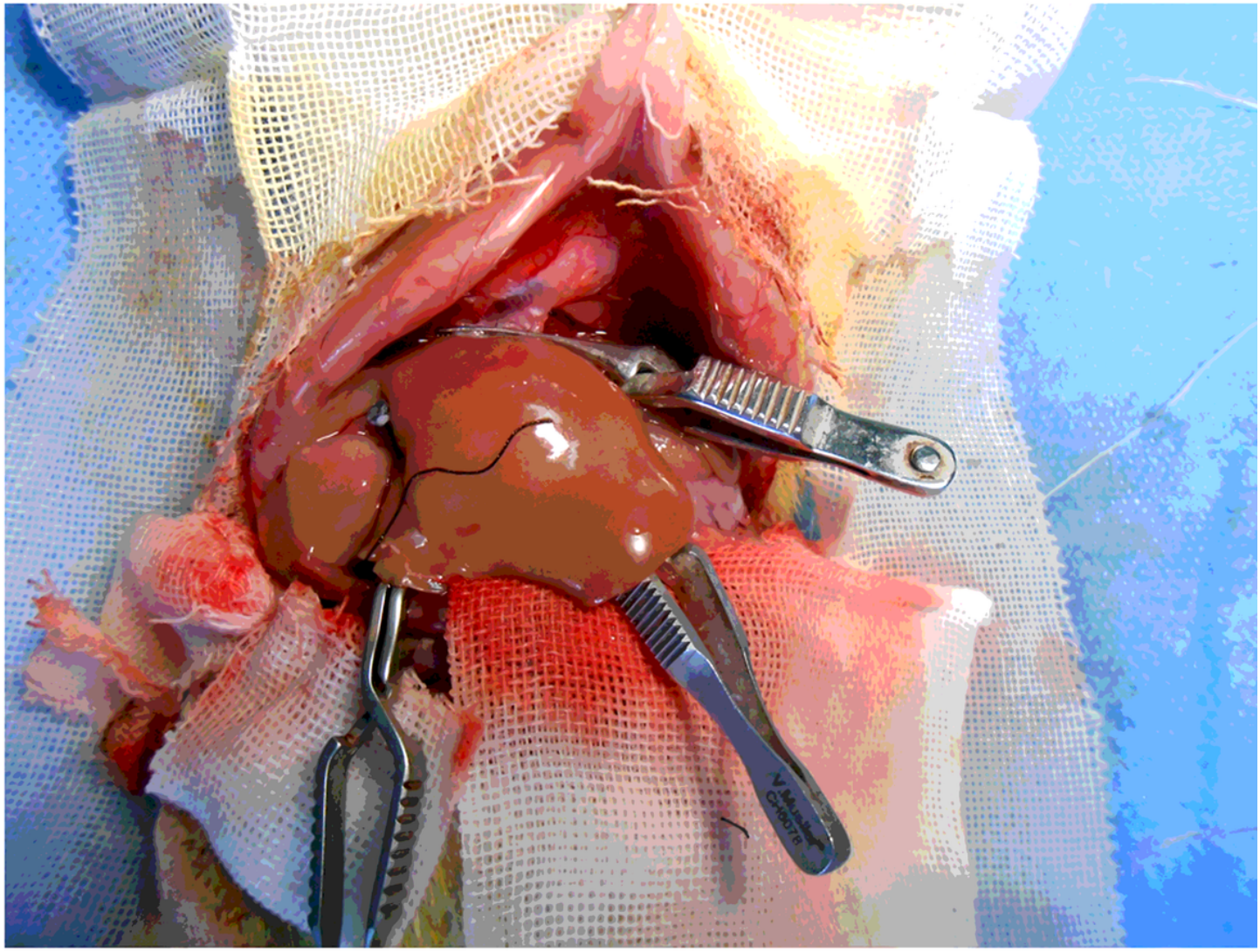

Figure 3

The diaphragmatic ring declamped with the bulldog.

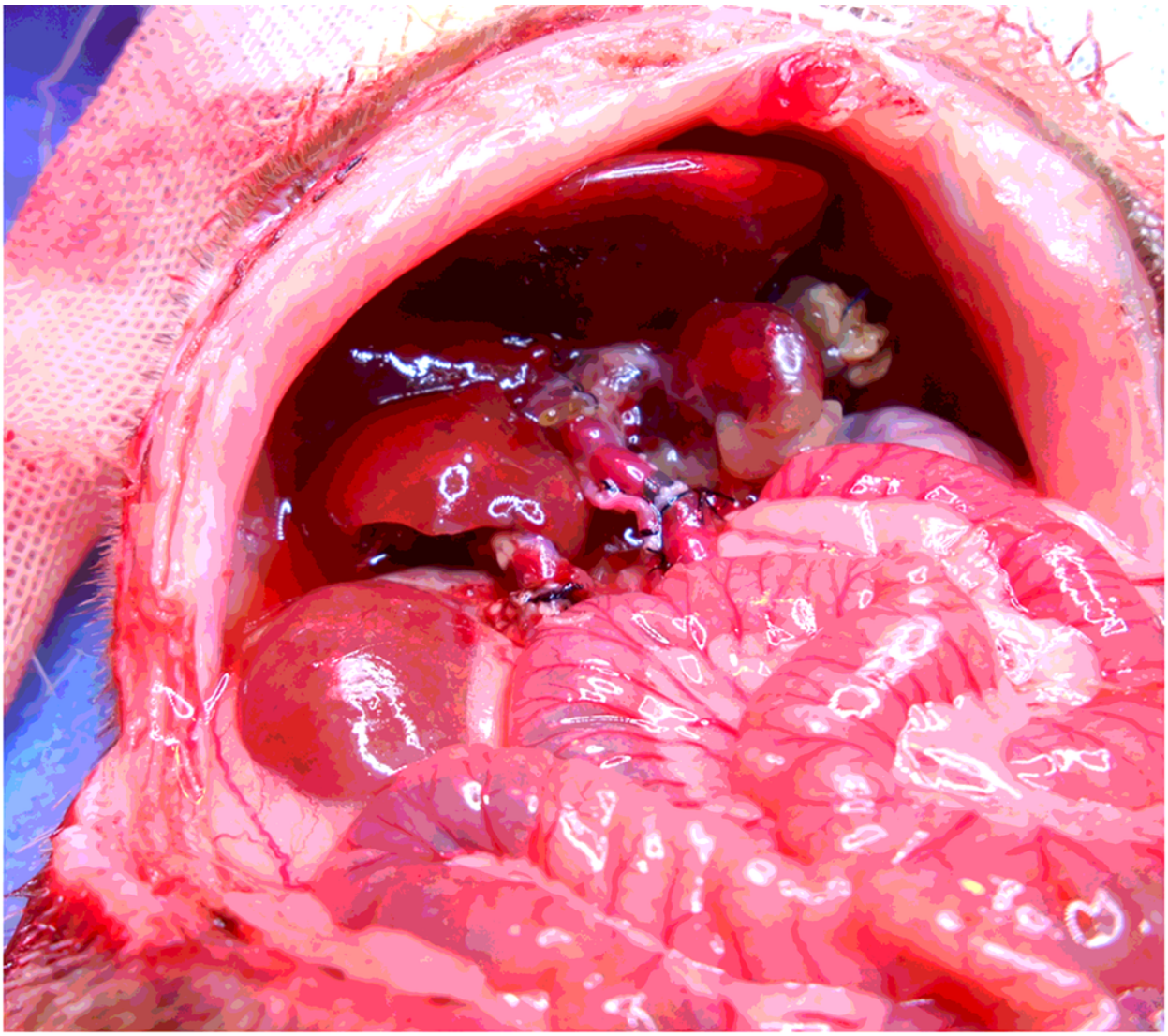

Figure 4

Intraoperative view. The hepatic artery was reconnected

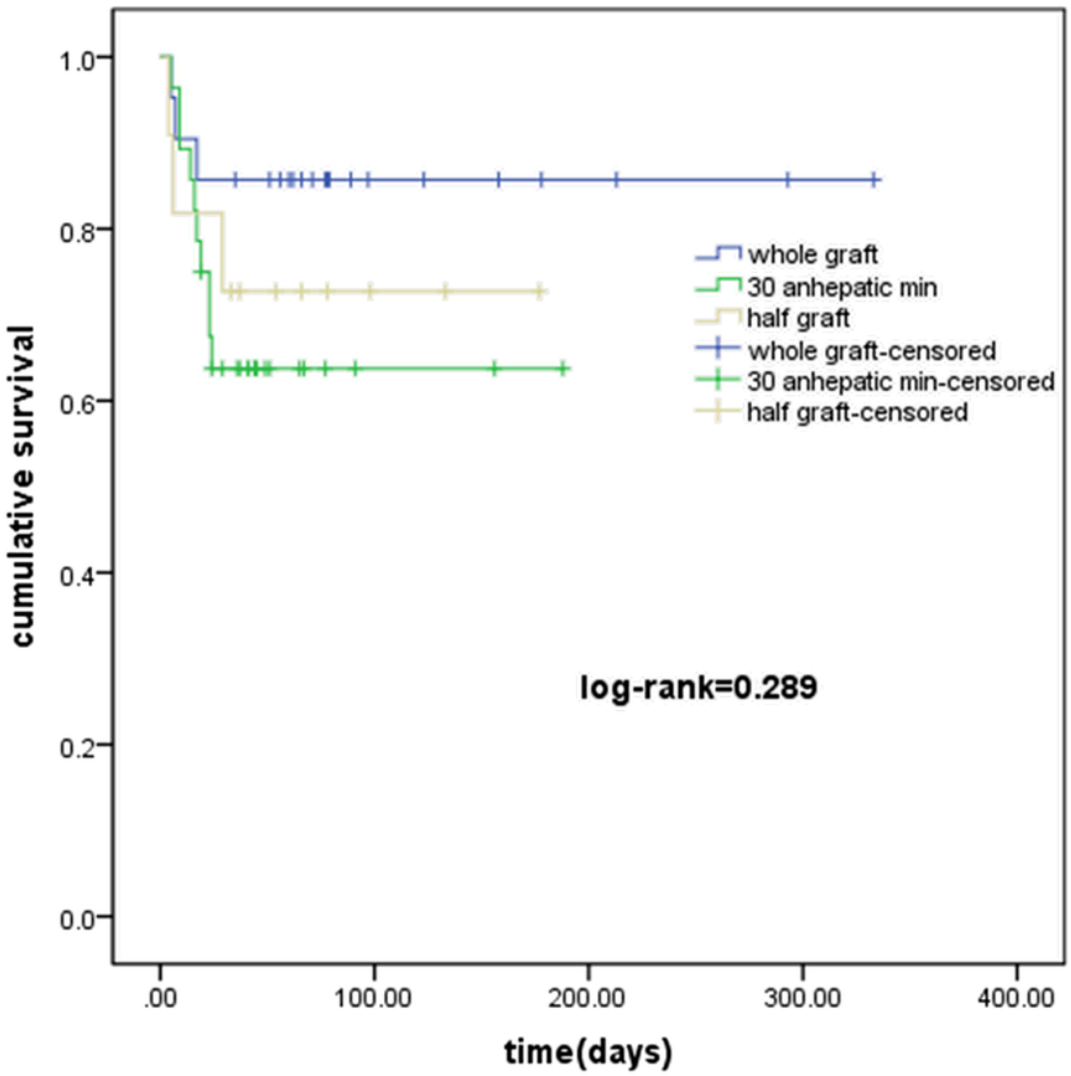

Figure 5

Survivals for different groups.

Supplementary Files

This is a list of supplementary files associated with this preprint. Click to download.

- viewafterarteryreconnection.mp4