Different managements of vertical gas breakthrough in femtosecond laser assisted LASIK

Chenghua Wei (weichenghua32@126.com)
Wannan Medical College https://orcid.org/0000-0002-0824-0311

Pengfei Zhang
The First Affiliated Hospital of Wannan Medical College

Yao Ge
The First Hospital of Wannan Medical College

Lixin Mei
The First Affiliated Hospital of Wannan Medical College

E Song
Lixiang Eye Hospital of Soochow University

Case report

Keywords: Femtosecond laser, Laser in situ keratomileusis, Vertical gas breakthrough

Posted Date: February 22nd, 2019

DOI: https://doi.org/10.21203/rs.2.392/v1

Abstract

Background To describe the different management of vertical gas breakthrough during FSL-LASIK. Cases presentation We present three cases that experienced a vertical gas breakthrough (VGB) during the flap creation for femtosecond laser assisted laser in situ keratomileusis (FSL-LASIK). All the cases were remedied using a femtosecond laser without the occurrence of adverse events during the second flap creation. Conclusions FSL-LASIK could be performed as a remedy for VGB in patients without obvious corneal lesions.

Background

Femtosecond laser (FSL) assisted laser in situ keratomileusis (LASIK) has been popularized due to its greater accuracy and predictability[1]. However, the FSL procedure involves a risk of unique complications including some gas bubble-related complications. Vertical gas breakthrough（VGB）is a rare and serious complication that occurs during flap creation. Some surgeons have reported that VGB was treated with a microkeratome[2] or photorefractive keratectomy[3]. To our knowledge, FSL-LASIK has not been reported as a remedy for VGB and we present three VGB cases that were successfully salvaged using FSL-LASIK.

Case Reports

Case 1

A 23-year-old man without a remarkable medical or ocular history underwent FSL-LASIK for the correction of myopia and astigmatism. No corneal abnormalities were detected upon slit lamp examination. The manifest refraction (MR) before surgery was -7.75+0.50×100 in the right eye and -7.25+0.50×70 in the left eye. The corneal curvature was 44.75@93 and 43.75@3 in the right eye, and the curvature in the left eye was 44.50@88 and 43.5@178. Pre-operative ultrasound pachymetry was 580μm in the right eye and 575μm in the left eye. The corrected distance visual acuity (CDVA) was 20/20 in both eyes. The pre-operative examination with Oculyzer (Alcon Laboratories, Inc, Fort Worth, TX, USA) was also normal.

FSL-LASIK was performed using FS200 Wave-light femtosecond laser (Alcon Laboratories, Inc, Fort Worth, TX, USA). The preset parameters for the right eye were as follow: flap thickness, 100μm; flap diameter, 8.5mm; canal width, 1.7mm; canal length offset, 0.6mm; spot and line separation, 8.0μm in the bed cut; pulse energy in the bed cut, 0.87 mJ. A gas bubble appeared between the cornea and the applanation cone shortly after the canal was cut (Figure 1). The operation was aborted after the flap creation due to the buttonhole of the cornea. The left eye underwent FSL-LASIK using parameters for flap creation similar to those of the right eye without any adverse events.

Four months later, the patient was followed-up and there were no changes in the MR, uncorrected distance visual acuity (UDVA), CDVA. FSL-LASIK was performed again on the right eye using the FS-200 machine (Figure 2). The preset parameters for re-operation in the right eye were as follows: flap thickness, 100μm; flap diameter, 8.7mm; canal length offset, 0.6mm; pulse energy in the bed and side cut, 0.82mJ.

The flap was created and lifted successfully. The excimer ablation and flap repositioning were performed as is typical for FSL-LASIK. The patients were prescribed Levofloxacin Eye Drops (Santen Pharmaceutical Co., Ltd, Osaka, Japan) 4 times daily for 1 week and Fluorometholone Eye Drops (Santen Pharmaceutical Co., Ltd, Osaka, Japan) 4 times daily, tapered for 4 weeks.

The UDVA was 20/20 on the first day after re-operation. The MR was +0.25 DS at the second month examination. No haze or other complications were detected.

This was the first VGB that I had encountered, and I performed FSL-LASIK to treat the condition 4 months later.

Case 2

A 19-year-old man without any medical or ocular history required FSL-LASIK. The cornea was unremarkable during slit lamp examination. The MR was -6.00 DS+0.50 DC×90 in the right eye and -5.75DS in the left eye. The corneal curvature was 43.00@89 and 41.75@179 in the right eye, and the curvature in the left eye was 42.75@153 and 42.00@63. The CDVA were 20/20 in both eyes. Pre-operative ultrasound pachymetry was 552μm in the right eye and 550μm in the left eye. Keratoconus was excluded by the examination of Oculyzer.

The flap was created by FS-200 FSL. The preset parameters for the right eye were as follows: flap thickness, 95μm; flap diameter, 8.5mm; canal length offset, -0.1mm; pulse energy in the bed and side cut, 0.80 mJ. A gas bubble appeared between the cornea and the applanation cone at the beginning of bed cutting (Figure 3). The operation was aborted temporarily after the side cut was completed. The left eye underwent FSL-LASIK using similar parameters without the occurrence of adverse events.

The FSL-LASIK operation of the right eye was repeated immediately after the left eye surgery was completed. The preset parameters during flap creation were as follows: flap thickness, 95μm; flap diameter, 8.5mm; canal length offset, 0.3mm; pulse energy in the bed and side cut, 0.80 mJ. The flap was created and lifted successfully (Figure 4). After excimer laser ablation, the flap repositioning required careful alignment because of the two side cuts.

The prescribed post-operative regimen was same as that in case 1. On post-operative day 1, the UDVA was 20/25 in the right eye and 20/20 in the left eye, while the epithelium was edematous in the inferior part of the right cornea. By post-operative day 3, the edema in the right eye vanished and the UDVA was 20/20. Two months after surgery, the UDVA was still 20/20 and the MR was +0.25 DC×47. Mild interface haze was observed one month after surgery, which vanished following prescribed administration of Fluorometholone Eye Drops 3 times daily tapered for 3 weeks. There were no other adverse events.

This was the second VGB I encountered and I performed the FSL-LASIK immediately after it occurred. Due to the two side cuts, the flap lifting and alignment was rather complicated.

Case 3

A 25-year-old female patient without any medical or ocular history underwent bilateral FSL-LASIK using FS-200 FSL. The MR was -6.50 DS+0.50 DC×50 in the right eye and -6.75DS in the left eye. The corneal curvature was 47.00@72 and 45.75@162 in the right eye, and the curvature was 46.50@100 and 45.50@10 in the left eye. The CDVA were 20/20 in both eyes. Pre-operative ultrasound pachymetry was 532μm in the right eye and 530μm in the left eye. Slit-lamp and Oculyzer examination were normal before surgery.

The flap was created using FS-200 FSL. The preset parameters for the right eye were as follows: flap thickness, 110μm; flap diameter, 8.3mm; canal length offset, 0.1mm; pulse energy in the bed and side cut, 0.84 mJ. A gas bubble appeared between the cornea and the applanation cone at the beginning of bed cutting (Figure 5), and the operation was aborted when 93% of the treatment was completed without a side cut. The left eye underwent the FSL-LASIK using similar parameters without adverse events.

FSL-LASIK operation of the right eye was repeated immediately after completion of surgery in the left eye. The preset parameters during flap creation were as follows: flap thickness, 110μm; flap diameter, 8.3mm; canal length offset, 0.7mm; pulse energy in the bed and side cut, 0.85 mJ (Figure 6). The flap was created and lifted successfully, and repositioned easily after excimer ablation.

The prescribed post-operative regimen was same as that in case 1. On post-operative day 1, the UDVA was 20/20 in both eyes, and the MR of the right eye was -0.25 DS. 3 months after surgery the UDVA was sill 20/20 and the MR was -0.25 DC×130. Mild interface haze was observed two months after surgery, which vanished following prescribed administration of Fluorometholone Eye Drops 4 times daily tapered for 4 weeks. There were no other adverse events.

This was the third VGB that I encountered. I stopped the FSL treatment without performing a side cut. The re-operation of FSL-LASIK was performed immediately. Since only one side cut was performed, lifting and repositioning of the flap was very easy just like a typical FSL-LASIK.

Discussion And Conclusions

Chang reported 3 cases of VGB thought to be associated with corneal abrasions, that were treated using microkeratome assisted LASIK[2]. Ribeiro reported 1 case of binocular VGB that was treated with mitomycin-C assisted photorefractive keratectomy[3]. To our knowledge, FSL-assisted LASIK has not been reported as a remedy for VGB so far.

In case 1, we carefully performed the re-operation after 4 months follow-up. The parameters for the corneal flap setting were similar to those of the first operation. Considering that the flap of the first operation was similar to a button hole, we used a same flap thickness during the re-operation. The lifting and repositioning of the flap was very easy.

Based on the experience of case 1, we performed FSL-assisted LASIK as a remedy for case 2 immediately after the first operation. However, because of the two side cuts, it was more troublesome to align and

reposition the flap edge.

Having experience from the two previous cases, we stopped the flap creation immediately upon encountering the third VGB, when only 93% of the flap creation was completed. Since the first flap creation did not carry on to the side cut, only one side cut was performed in the two flap creations. The re-operation was performed very easily, and the corneal flap lifting and repositioning was no different from a typical FSL-LASIK.

Unlike the cases reported by Ribeiro which had bilateral VGB with anterior basement membrane dystrophy[3], the three cases we reported had no corneal lesions. Before the first operation, they were supposed to have an intact anterior elastic layer. Moreover, the anterior elastic layers of case 2 and 3 were probably damaged after they underwent VGB. The VGB did not recur during the re-operation. Therefore, we think that damage of the anterior elastic layer may not be the necessary cause of VGB. Some investigators believe that VGB is related to thin corneal flap[4]. Since the three patients showed high myopia, we created thin corneal flaps to maintain more corneal stroma. This may have been the cause of VGB since the gas bubble diffused through the thin corneal flap to the applanation cone, instead of through the canal.

In summary, FSL-assisted LASIK was performed successfully as a remedy in 3 VGB cases. No adverse events occurred during the second flap creation. Two cases experienced a mild haze during the rehabilitation process. The predicted values of UDVA, CDVA and refraction were all achieved post-operatively. FSL-LASIK could be a remedy for VGB in patients without obvious corneal lesions. More studies about the cause and management of VGB are needed.

Abbreviations

VGB: vertical gas breakthrough; FSL: femtosecond laser; LASIK: laser in situ keratomileusis; MR: manifest refraction; CDVA: corrected distance visual acuity; UDVA: uncorrected distance visual acuity; DS: diopter of sphericle; DC: diopter of cylinder.

Declarations

Ethics approval and consent to participate

Not applicable.

Consent for publication

Written informed consents were obtained from the patients for publication of this case report and any accompanying images. A copy of the written consents is available for review by the Editor of this journal.

Availability of data and materials

All the data supporting our findings is contained within the manuscript.

Competing interests

The authors declare that they have no competing interests.

Funding

This work was supported by the National Natural Science Fund of China in 2017 [grant number 81700867] and the Wannan Medical College training fund project of key scientific research project in 2017 [grant number WK2017ZF05]

Authors contributions

CW drafted the manuscript. PZ carried out the initial figure reviewing. LM participated in the report's overall design. YG was one of the primary physicians involved in the case. ES added details to the initial case report. All authors read and approved the final manuscript.

Acknowledgements

We would like to thank Qiaoyun Dai for providing her figure for use in this study.

References

1. Torky MA, Al Zafiri YA, Khattab AM, Farag RK, Awad EA.Visumax femtolasik versus Moria M2 microkeratome in mild to moderate myopia: efficacy, safety, predictability, aberrometric changes and flap thickness predictability. BMC Ophthalmol. 2017;17:125.
2. Chang JS, Lau S. Intraoperative flap re-cut after vertical gas breakthrough during femtosecond laser keratectomy. J Cataract Refract Surg 2010;36:173-7.
3. Ribeiro GC, Krueger RR. Management of bilateral gas-bubble breakthrough during femtosecond LASIK in the presence of anterior basement membrane dystrophy. J Cataract Refract Surg 2014;40:1736-9.
4. Srinivasan S, Herzig S. Sub-epithelial gas breakthrough during femtosecond laser flap creation for LASIK. Br J Ophthalmol 2007;91:1373.

Figures

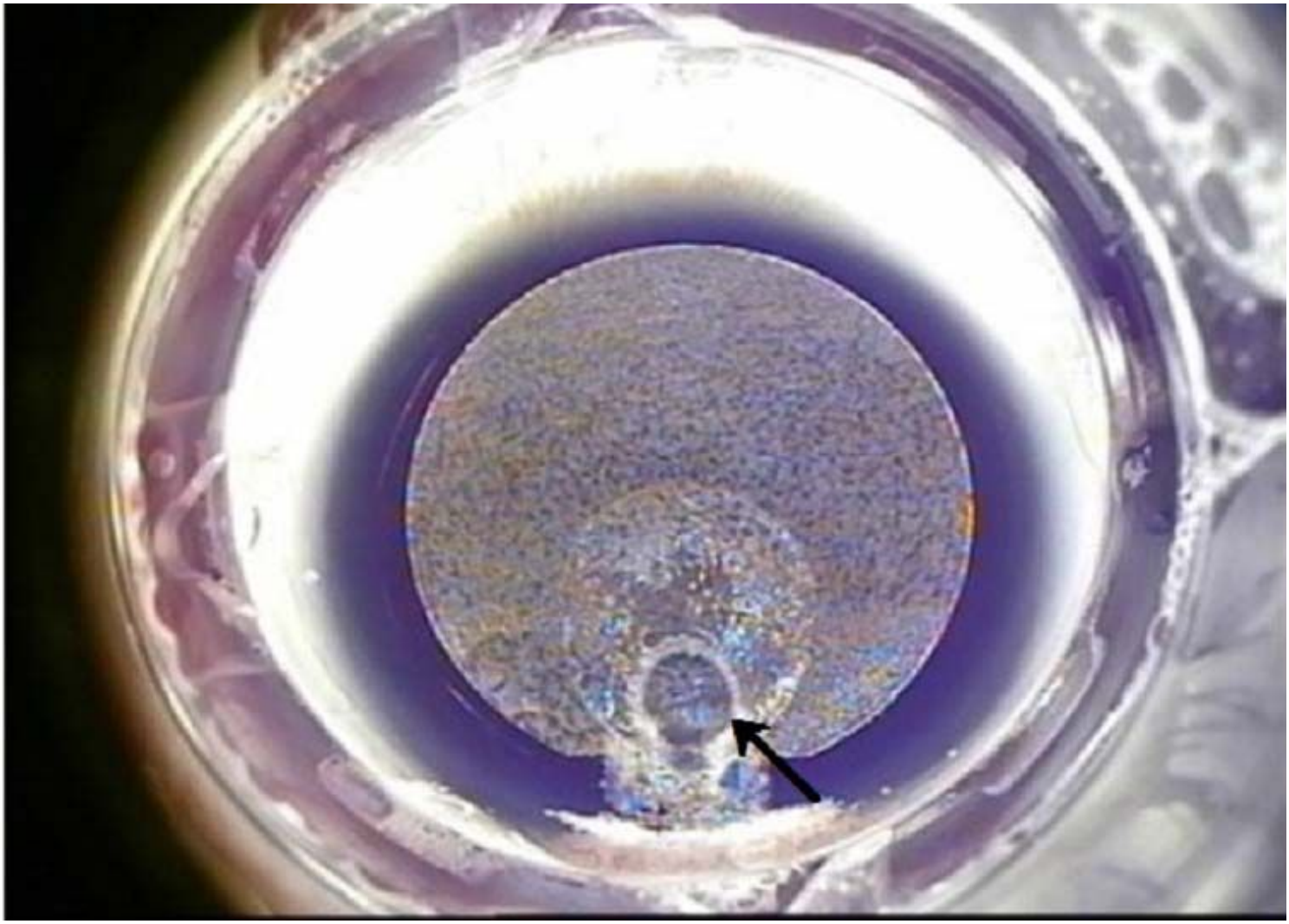

Figure 1

Flap figure of case 1. Gas bubble in the superior part of the corneal bed indicated by the black arrow.

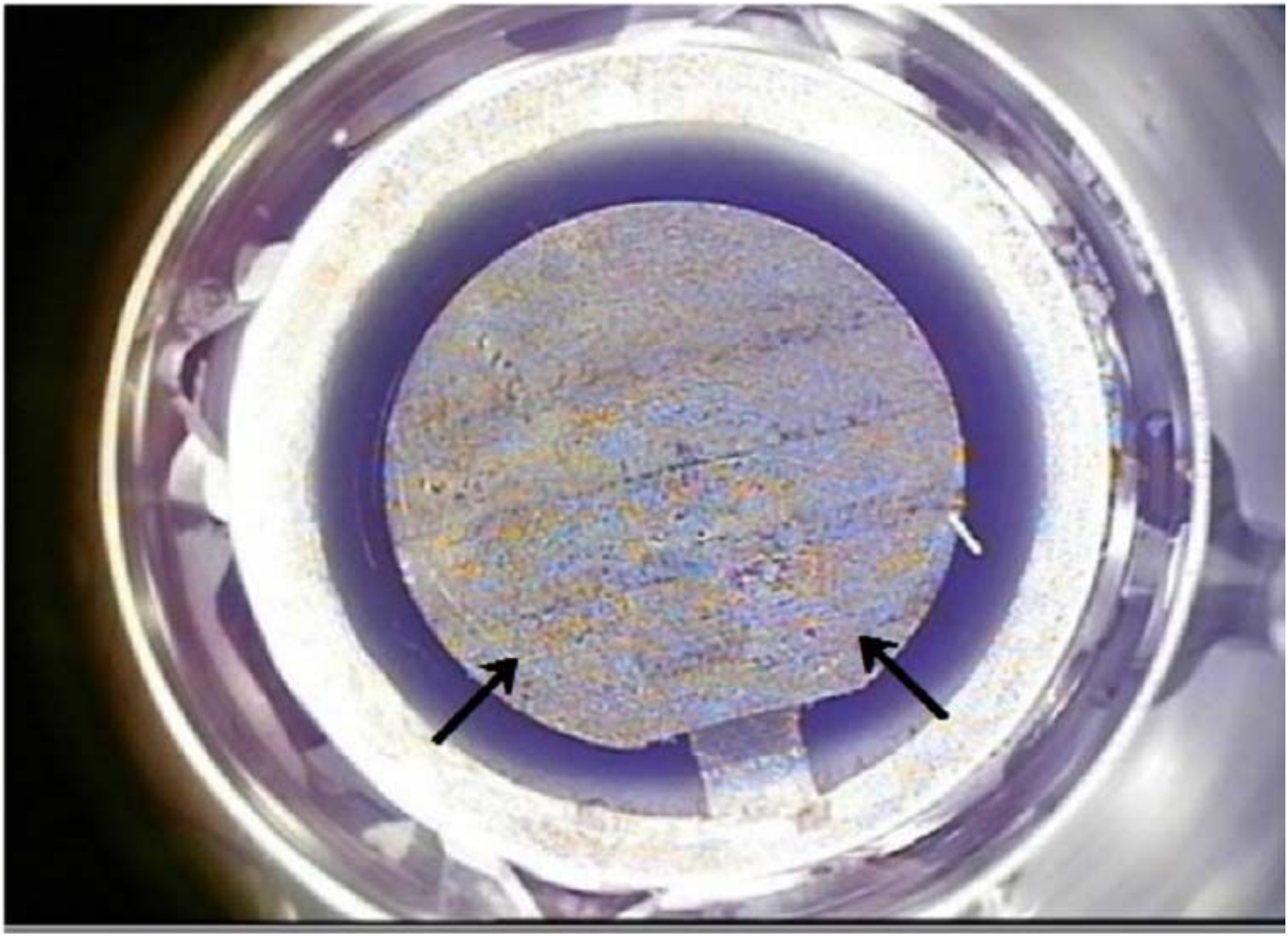

Figure 2

Flap figure of re-cut in case 1. Black arrow indicates the margin of the first cut.

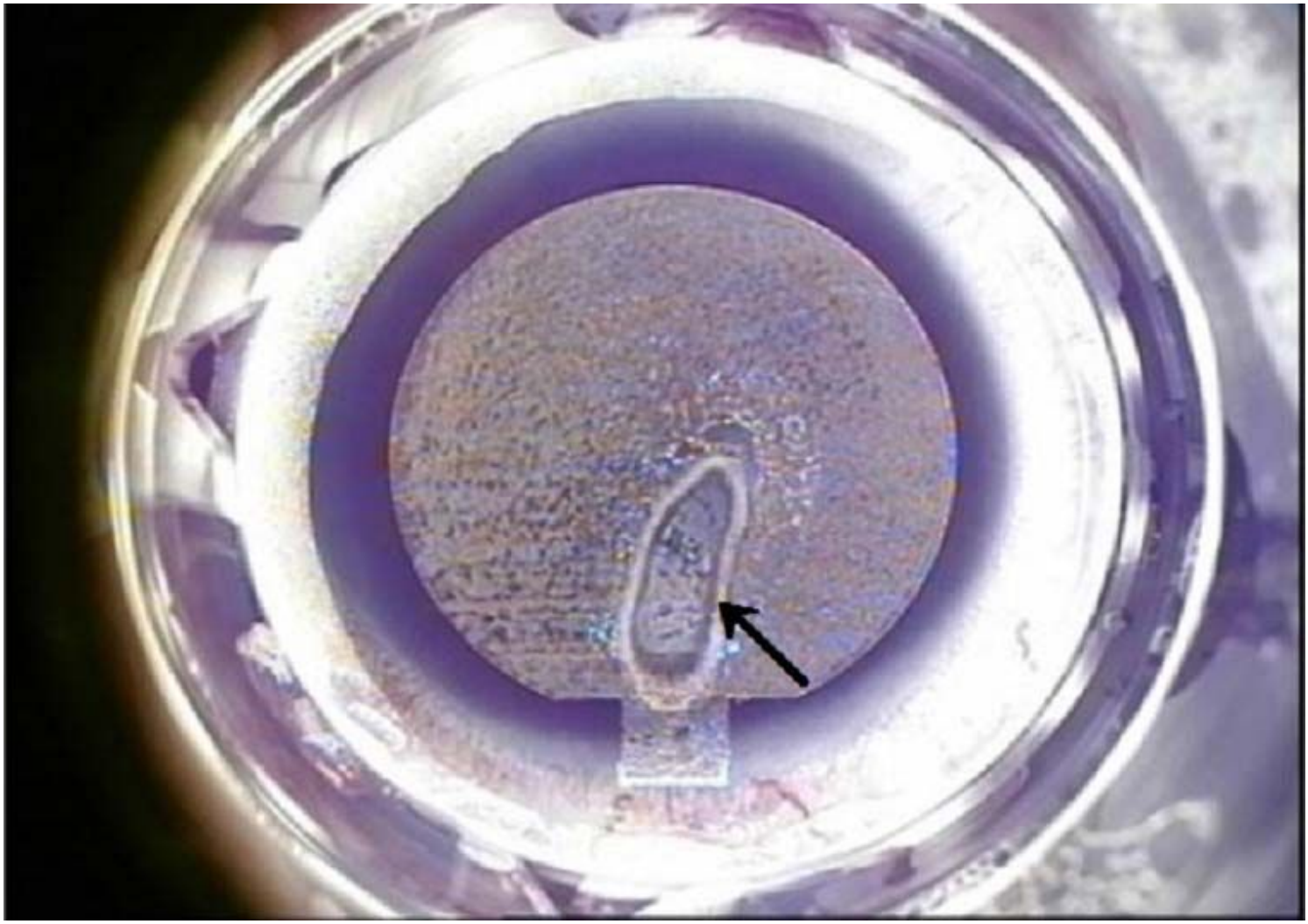

Figure 3

Flap figure of case 2. A long oval gas bubble in the superior part of the corneal bed indicated by the black arrow.

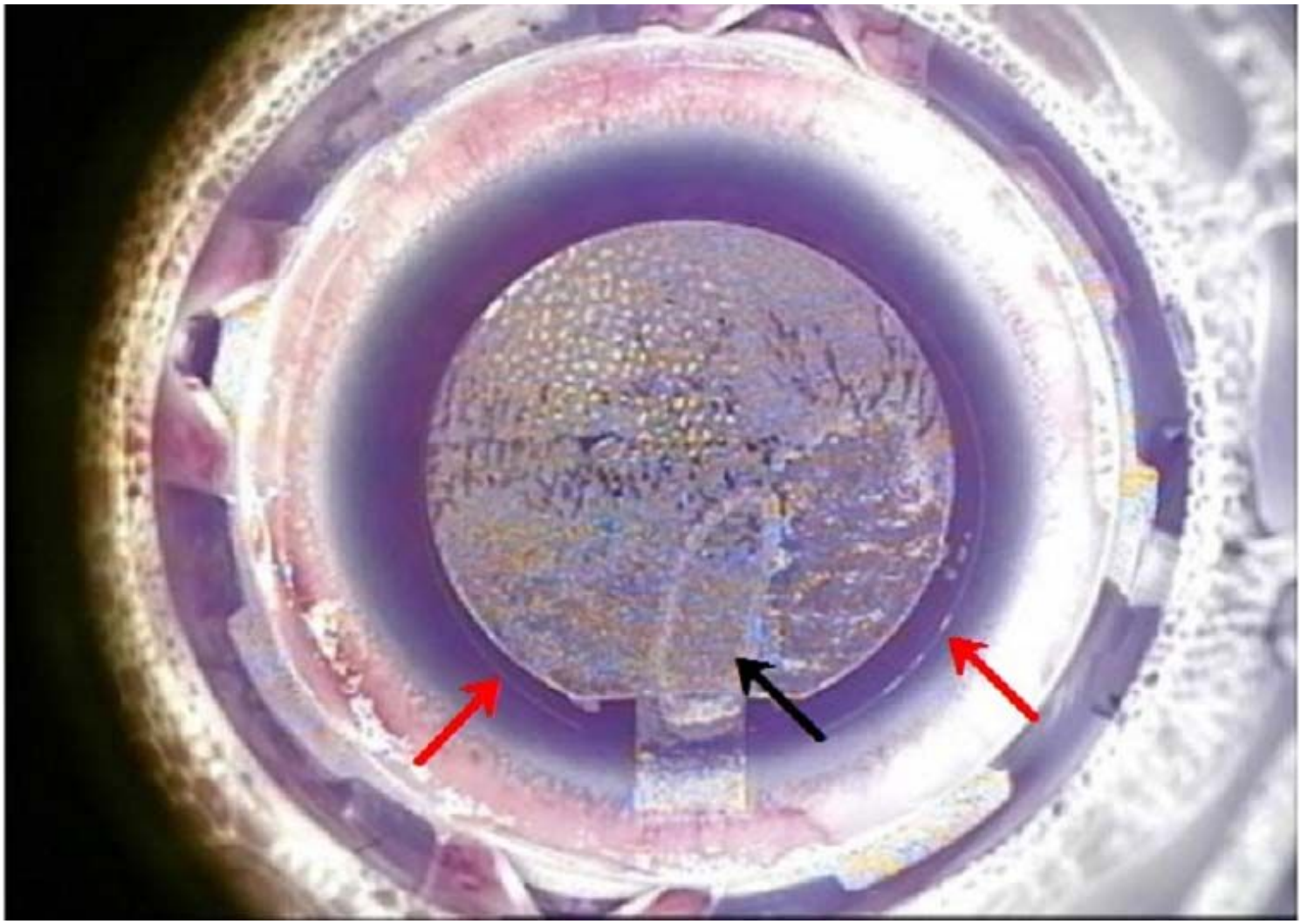

Figure 4

Flap figure of re-cut in case 2. Red arrow indicates the margin of the first cut. Black arrow indicates the margin of the button hole.

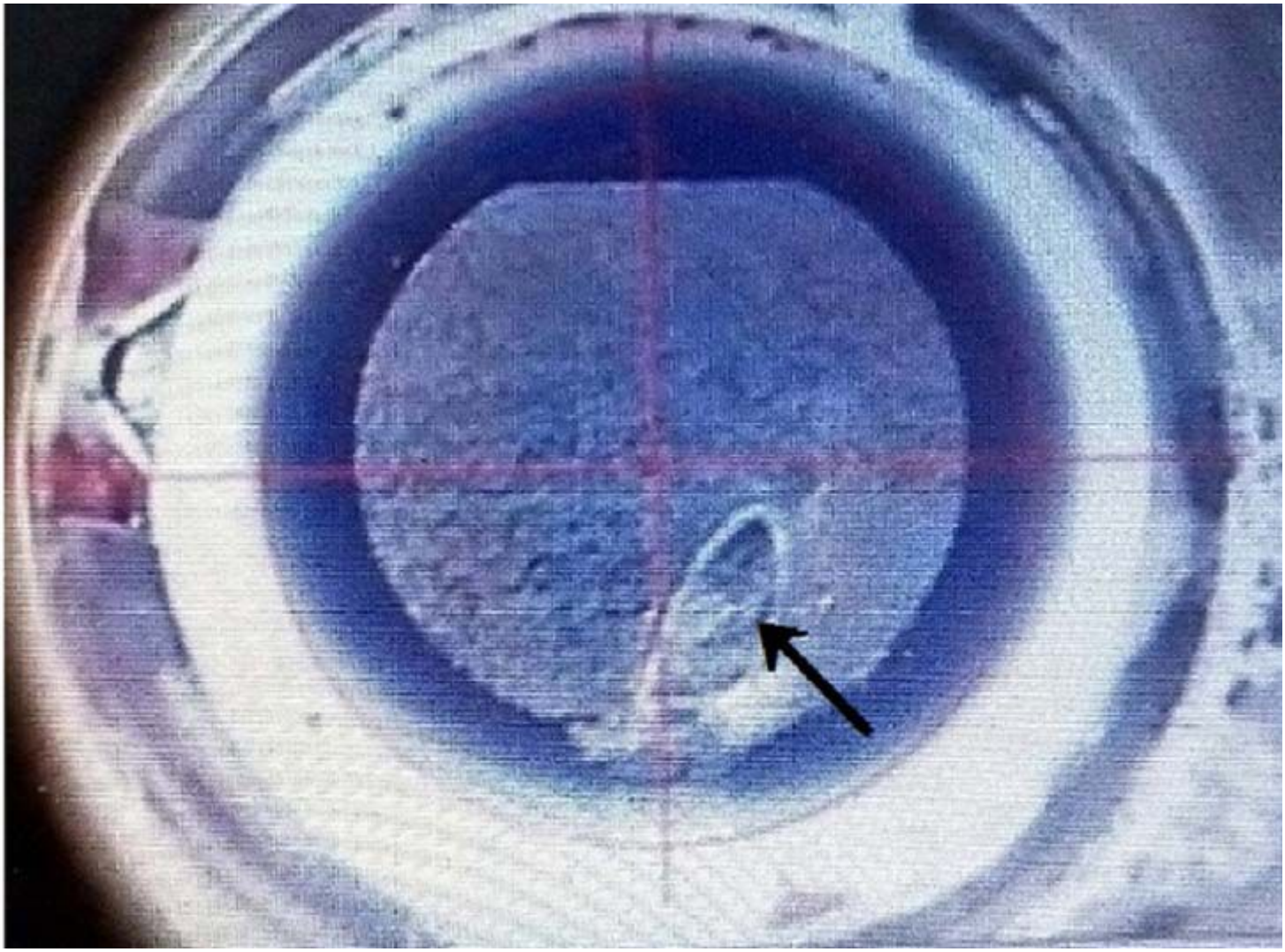

Figure 5

Flap figure of case 3. A long oval gas bubble in the superior part of the corneal bed indicated by the black arrow.

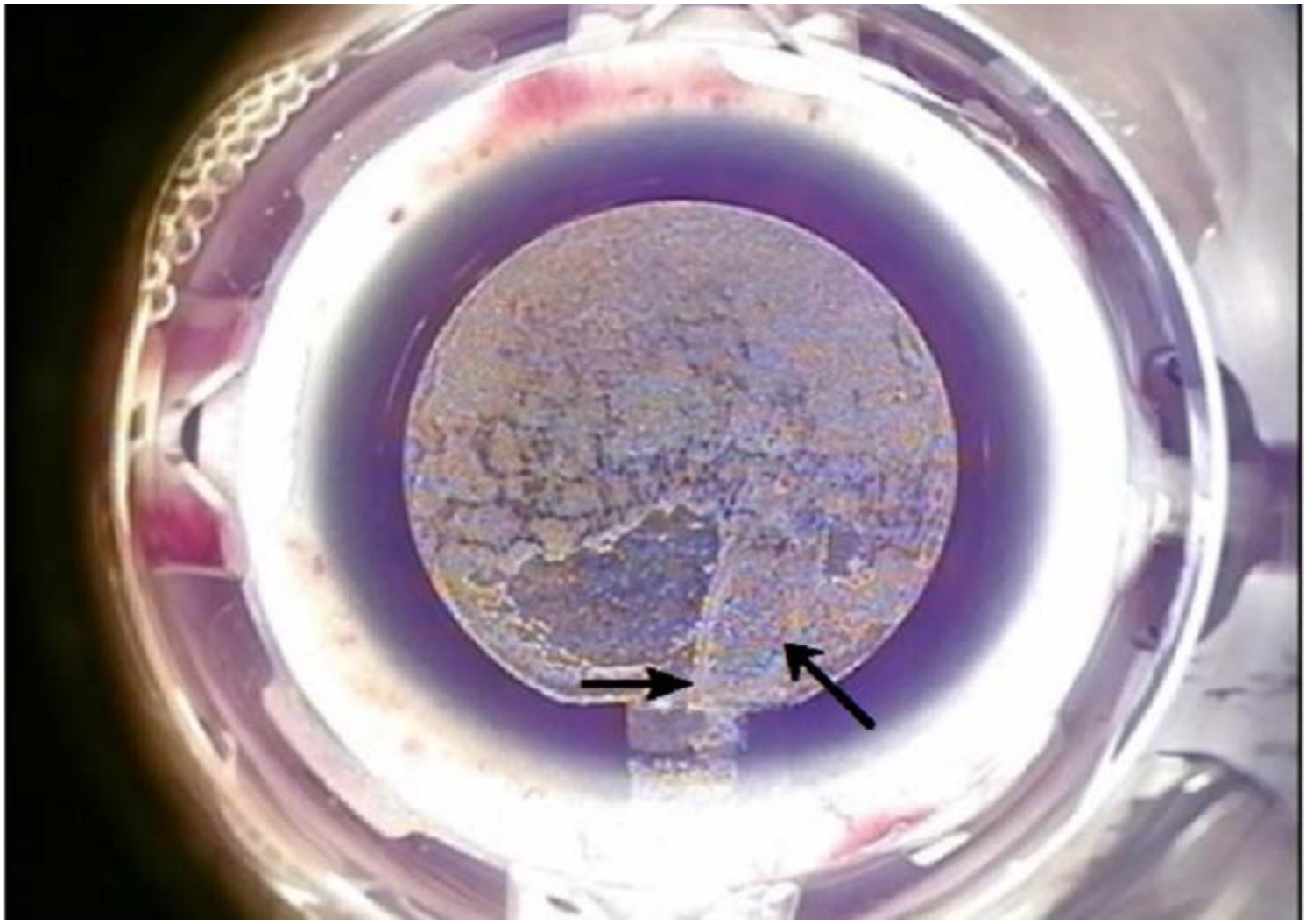

Figure 6

Flap figure of the re-cut in case 3. Black arrow indicates the margin of button hole.

Supplementary Files

This is a list of supplementary files associated with this preprint. Click to download.

- CARE.pdf